

Case report

Dual thyroid ectopia with submental thyroid excision using Sistrunk procedure: A case report

Li Xian Lim^{a,*}, Grace Tim-Yan Kwok^a, Eva Wong^b, Gary J. Morgan^a^a Head and Neck Unit, Westmead Hospital, 166-174 Hawkesbury Road, Westmead, NSW 2145, Australia^b Head and Neck Cancer Service, Crown Princess Mary Cancer Centre, 166-174 Hawkesbury Road, Westmead, NSW 2145, Australia

ARTICLE INFO

Article history:

Received 26 March 2021

Received in revised form 16 April 2021

Accepted 16 April 2021

Available online 27 April 2021

Keywords:

Ectopic thyroid
Submental thyroid
Lingual thyroid
Sistrunk procedure
Case report

ABSTRACT

Introduction and importance: Having two or more sites of simultaneous ectopic thyroid tissue is a rare phenomenon. Thyroid ectopia should be considered in congenital hypothyroidism where no eutopic thyroid gland is found.

Case presentation: This case describes an incidental finding of dual ectopic thyroid tissue on computer tomography scan in an adult with known congenital hypothyroidism that was previously attributed to thyroid agenesis. The decision was made to proceed with a Sistrunk procedure to excise the ectopic submental thyroid as it became more noticeable after weight loss following bariatric surgery, and to monitor the remaining lingual thyroid with a combination of clinical symptomatology, imaging and thyroid function studies given its challenging location.

Clinical discussion: The literature on pathophysiology, imaging modalities, and common considerations for surgical extirpation is reviewed.

Conclusion: The utility of thyroid scintigraphy may be limited in patients with known thyroid ectopia; other investigative modalities are helpful. The Sistrunk procedure was used to excise an ectopic thyroid, based on its embryological migration from the foramen caecum to the usual pretracheal position along the thyroglossal tract, and is a suitable technique for excision of submental thyroid tissue causing an unsightly mass and where thorough histopathological examination is required to exclude malignancy.

© 2021 The Author(s). Published by Elsevier Ltd on behalf of IJS Publishing Group Ltd. This is an open access article under the CC BY-NC-ND license (<http://creativecommons.org/licenses/by-nc-nd/4.0/>).

1. Introduction

Thyroid ectopy is where there is thyroid tissue present outside of its usual pretracheal location, anterior to the second to fourth tracheal rings [1]. Lingual thyroid is the most common ectopic location with prevalence estimates ranging from 1 in 469 to 1 in 100,000 people [2], although a post-mortem study revealed a much higher rate in the asymptomatic euthyroid population – up to 10% [3]. Having two or more simultaneous sites of ectopic thyroid tissue is a rare phenomenon, with a variety of management strategies [1,2,4].

Generally, where no eutopic thyroid gland is found, the patient should be worked up to assess for athyreosis or ectopy [5]. While thyroid scintigraphy is helpful in this instance, its utility is debatable in this case where the anatomic locations of thyroid ectopia are already known. Computer tomography (CT) imaging and fine needle aspirate (FNA) can help decide management strategy. This case report describes a patient with congenital hypothyroidism who was incidentally found to have dual thyroid ectopia as an adult, and was managed in a major tertiary referral and teaching hospital. It highlights that thyroid ectopia

should be assessed for in congenital hypothyroidism, as it relates to symptom monitoring and treatment decisions later in life. Thyroid scintigraphy was not required for this case after the ectopic thyroids were localised on CT. This case also reports on the successful use of the Sistrunk procedure in extirpation of ectopic submental thyroid tissue. It has been reported in line with the SCARE criteria [6].

2. Presentation of case

A 35-year-old female presented to the Emergency Department following a presyncopal episode while receiving iron infusion for anaemia relating to menorrhagia. As part of her workup, a CT head and neck was performed, which incidentally showed two well-circumscribed globular-shaped enhancing lesions in the base of tongue and sublingual areas (Fig. 1). She was born overseas with no prior neck surgeries or radiotherapy. She has no known allergies and has no significant family history. She had been diagnosed with congenital hypothyroidism from thyroid agenesis and prescribed levothyroxine since infancy, but had a history of poor compliance due to her busy lifestyle. She reported being obese previously, and would intermittently awaken at night with a choking sensation; these symptoms were relieved by sitting upright. She underwent gastric sleeve surgery, lost 38 kg in weight, and

* Corresponding author.

E-mail addresses: lixian.lim1@health.nsw.gov.au (L.X. Lim), grace.kwok@health.nsw.gov.au (G.T.-Y. Kwok).

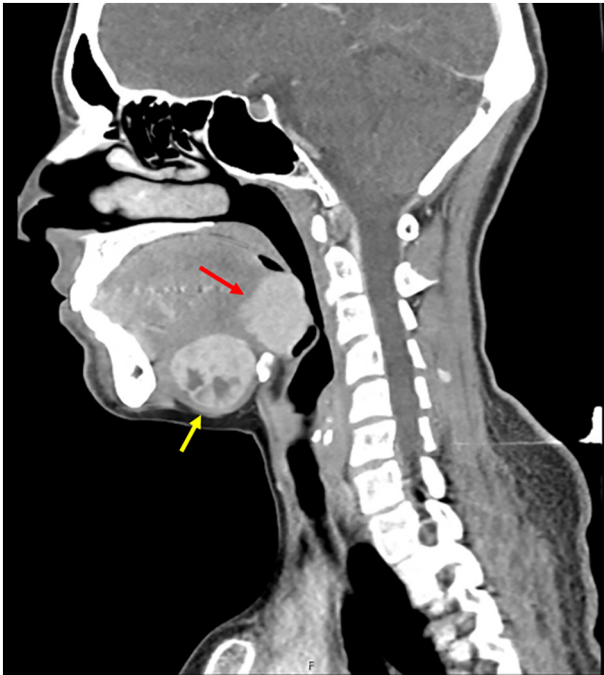


Fig. 1. Sagittal view of lingual and sublingual dual thyroid ectopia. This CT image shows two contrast-enhancing lingual (red arrow) and sublingual (yellow arrow) masses, measuring 3.0×3.4 cm and 3.2×3.1 cm in the anteroposterior and craniocaudal dimensions respectively. Scattered hypodense areas within the sublingual mass likely represent cystic changes. There is no ectopic thyroid gland. (For interpretation of the references to colour in this figure legend, the reader is referred to the web version of this article.)

subsequently noticed a submental lump; it was otherwise asymptomatic.

On examination, there was a midline submental swelling of about 2×2 cm; it had a smooth contour and firm consistency. Movement with deglutition or tongue protrusion was minimal. Serum thyroid-stimulating hormone (TSH) was 9.65 mIU/L (normal 0.40–3.50), free thyroxine was 13.5 pmol/L (normal 9.0–19.0), and free triiodothyronine was 5.5 pmol/L (normal 2.6–6.0), suggestive of subclinical hypothyroidism. FNA was performed on the submental lump; cytology demonstrated Bethesda II thyroid tissue. The lingual thyroid was examined with fiberoptic nasendoscopy. There were no signs of airway compromise, and its radiologic appearance was reassuring for a benign lesion. Following discussions with a multidisciplinary team and the patient herself, the decision was made to continue monitoring the lingual

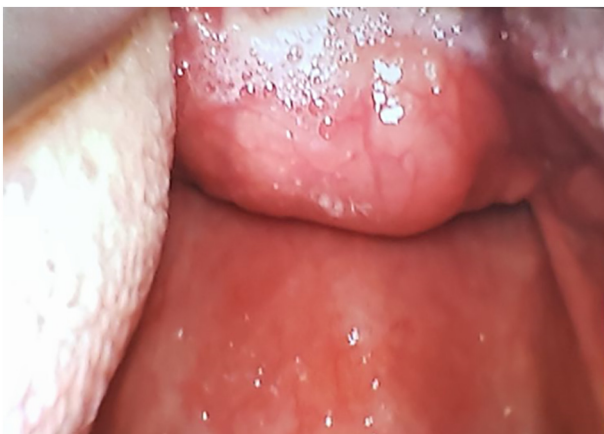

Fig. 2. Lingual thyroid at the tongue base seen via video laryngoscopy during intubation.

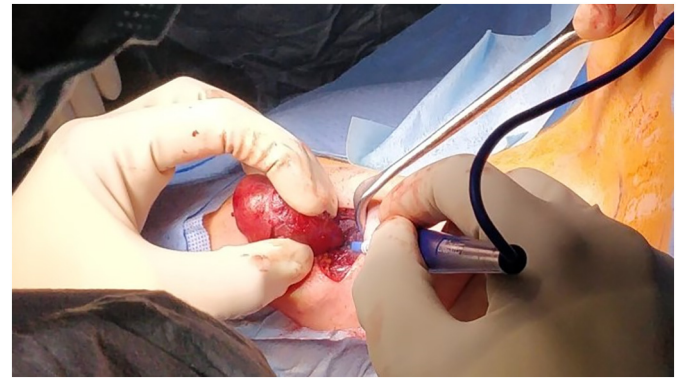


Fig. 3. A transverse incision was made at the level of the hyoid bone. With skin and platysma retracted away, the ectopic thyroid tissue was exposed and retracted cranially.

thyroid based on symptomatology, ultrasound surveillance and thyroid function studies, as surgical access would be difficult given its location. A Sistrunk procedure was offered to remove the submental ectopic thyroid tissue, given its impact on cosmesis.

The patient had her operation four months following diagnosis. The surgery was performed by a fully qualified senior trainee surgeon, under the supervision of a consultant Head and Neck surgeon. Tracheal intubation was successfully achieved using video laryngoscopy (Fig. 2). Intraoperatively, the lump was enucleated down toward the hyoid bone (Figs. 3 and 4), where it became separated from its attachment. The mid-portion of the hyoid bone was resected to complete the procedure (Fig. 5). The lingual thyroid was readily palpable and mobile. There were no operative complications, and the patient was discharged home the same day. Histopathology of the submental lump showed thyroid tissue with features of multinodular goitre but without any obvious ductal structure, suggesting true thyroïdal ectopy instead of a sequestered thyroid nodule within a thyroglossal duct. At follow-up three weeks and four months post operation, her choking sensations had decreased in frequency, making them unlikely to be attributable to a stable, unchanging lingual thyroid.

3. Discussion

The thyroid gland is typically located in the anterior lower neck below the thyroid cartilage [7]. It develops around the 24th day of embryogenesis, with the median anlage arising from the apex of the foramen caecum as a mass of endoderm and migrating caudally through neck tissues via the transient thyroglossal duct, which is usually obliterated by the tenth week. This thyroid primordium then bifurcates and undergoes bilobation, fusing with ultimobranchial bodies, which are derived from the lateral thyroid anlagen from the fourth pharyngeal pouch. The lateral lobes are connected by the thyroid isthmus crossing the upper trachea [8]. Thyroid dysgenesis during its passage from the foramen caecum can result in the presence of ectopic thyroid tissue [9].

Functional thyroid tissue may be found anywhere along the thyroglossal tract [10]. About 90% of ectopic thyroids are found in the lingual area; other sites include sublingual, cervical, mediastinal, intracardiac and even porta hepatis [11,12]. Having two simultaneous ectopic foci is considered a rare phenomenon, occurring in about 1 in 50,000–70,000 live births.

Ectopic thyroids have been shown to continue performing thyroid hormone biosynthesis, albeit in reduced quantities [9]. In 70% of patients, it may be the only thyroid tissue present [13]. Hence care must be taken when planning surgical excision to avoid removing the only functional thyroid tissue and rendering the patient profoundly hypothyroid [14]. Up to a third of patients with thyroid ectopia present with congenital hypothyroidism [13]. Hypothyroidism can remain subclinical [11]. In fact, ectopic thyroids tend to present with new-onset swelling when there is increased thyroid hormonal demand such as

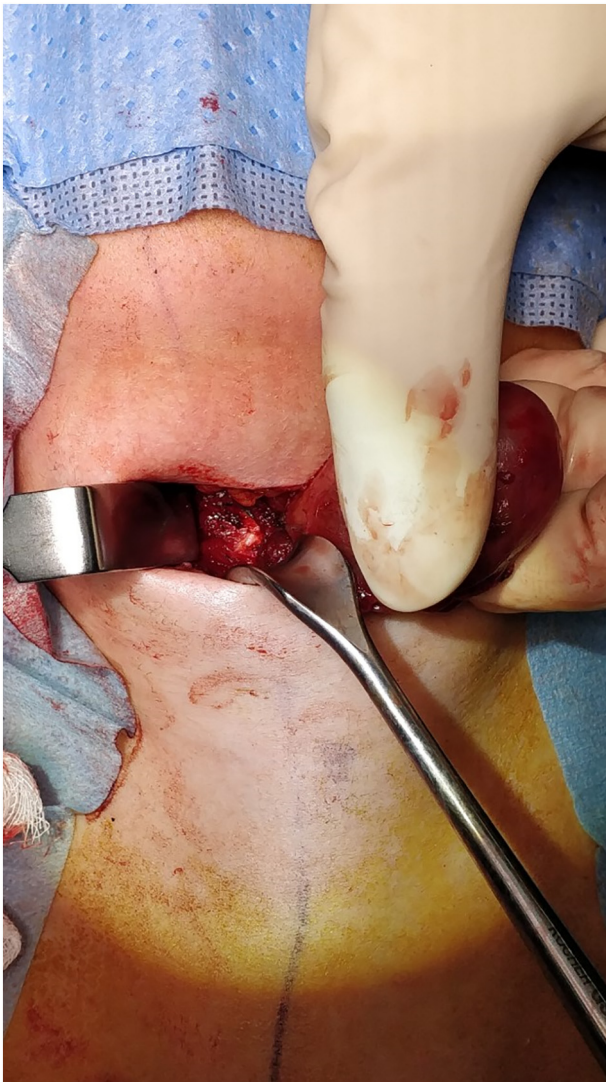


Fig. 4. The mylohyoid raphe was divided and the ectopic thyroid tissue was enucleated down to its attachment to the hyoid bone. In this photograph, the ectopic thyroid has been retracted to the left of the patient, to expose the mid portion of the hyoid bone. No tract was identified extending from the hyoid bone to the foramen caecum.

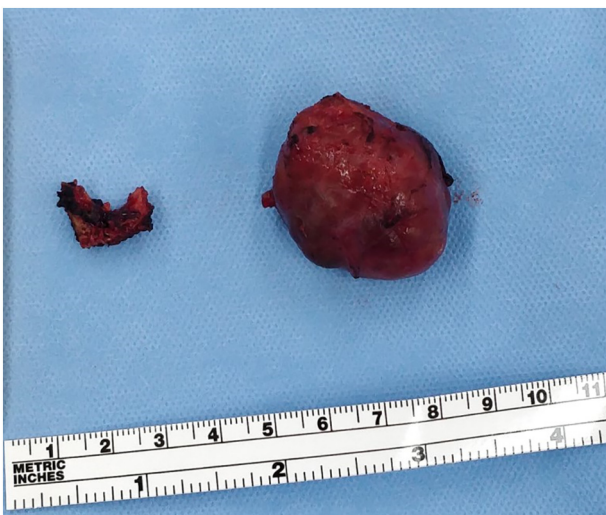

Fig. 5. Mid-portion of hyoid bone (left) and submental ectopic thyroid tissue (right).

during puberty or pregnancy, whereby the thyroid tissue hypertrophies secondary to TSH stimulation under the activation of the hypothalamic-pituitary-adrenal axis [11]. It has been postulated that the higher prevalence of symptomatic lingual thyroids in the female population (up to a ratio of 7:1 to males) [15], whereas autopsy and imaging case series have not demonstrated this predilection [3,11]. In dual thyroid ectopia, the foci may respond differently to TSH stimulation, as evidenced by their different sizes within the one subject [11]. Clinical manifestations of their goitrous enlargement include an anterior neck lump along the path of descent of the median thyroid anlage, obstructive symptoms such as a choking sensation, dyspnoea, dysphonia and dysphagia, and secondary haemorrhage or ulceration, all of which may be accompanied by vague symptoms reflecting a hypothyroid state [15,16].

Although thyroid ultrasounds are useful in assessing for eutopic thyroids, they lack sensitivity in diagnosing ectopia [5]. Thyroid scintigraphy, which can be done using ^{123}I or $^{99\text{m}}\text{Tc}$ pertechnetate, is helpful in topographically locating ectopic thyroid tissue to confirm the diagnosis of ectopic thyroid and assess for presence of a eutopic gland. It can aid in differentiating thyroid ectopia and other causes of anterior midline neck lump such as thyroglossal duct cyst, lymphadenopathy, lipoma, sebaceous cyst, vascular anomalies and non-thyroid malignancy. Drawbacks of a radionuclide scan are that it may not clearly demonstrate small volume thyroid tissue or non-functioning thyroid vestiges, and depending on the chosen isotope, its accuracy may be hindered by thyroid replacement therapy or iodine-containing contrast media [5,16]. CT scans can provide more anatomical and morphological detail, especially with the use of hybrid SPECT/CT [17]. In this case, a combination of contrast CT with FNA helped to diagnose thyroid ectopy.

A rapid increase in size of an anterior neck lump may be the only symptom of thyroid carcinoma at any site, and although exceedingly rare, follicular and papillary carcinomas in ectopic thyroids have been documented [16,18]. If so, resection of other thyroid tissue should be considered to help with treatment, staging and monitoring of metastases and disease recurrence [19]. FNA or core biopsy can assist in distinguishing between benign versus malignant lesions, keeping in mind that aspiration cytology may be prone to sampling error [9].

Treatment of ectopic thyroid depends on size, symptomology, complications or suspected malignancy [15]. Thyroid hormone replacement and maintaining a euthyroid status can reduce the size of ectopic thyroid tissue by suppressing TSH¹². Many advocate a trial of medical management as initial therapy, but surgery is indicated if the lesion was large causing persistent obstructive symptoms, demonstrating haemorrhagic or cystic degeneration, or suspicious for malignancy [2,13,15]. The Sistrunk technique, initially developed to excise all remaining thyroglossal tract tissue to prevent thyroglossal cyst recurrence [10], was employed in this case to safely and systematically remove the submental thyroid, and enable physical examination of the lingual thyroid tissue. In cases where the ectopic thyroid is the only functioning thyroid tissue, or when the remaining thyroid tissue is thought to be insufficient, autotransplantation has been performed to restore euthyroidism [20], but this seems unlikely to be helpful in the senior authors' opinion.

The patient was satisfied with the removal of the unsightly submental mass and the decrease in frequency of her choking sensations. Longer term follow-up is still required to monitor the outcome of the lingual thyroid. The case report is limited by time constraints.

4. Conclusion

This case highlights the importance of assessing for thyroid ectopia in congenital hypothyroidism where no eutopic thyroid gland is found. Armed with the knowledge that a hypothyroid state could worsen symptoms related to thyroid tissue hypertrophy, patients may be more compliant with thyroxine replacement therapy. The Sistrunk procedure can be used to excise an ectopic submental thyroid.

Sources of funding

None.

Ethical approval

The study is exempt from ethical approval at this institution, as per page 4 of the policy directive 'Research - Ethical & Scientific Review of Human Research in NSW Public Health Organisations' [PD2010 055].

Consent

Written informed consent was obtained from the patient for publication of this case report and accompanying images. A copy of the written consent is available for review by the Editor-in-Chief of this journal on request.

Research registration

N/A.

Guarantor

Gary J. Morgan.

Provenance and peer review

Not commissioned, externally peer-reviewed.

CRediT authorship contribution statement

- Author 1: Writing - original draft, Writing - review & editing, Visualisation.
- Author 2: Writing - review & editing.
- Author 3: Conceptualisation, Supervision, Resources.
- Author 4: Supervision, Writing - review & editing.

Declaration of competing interest

None.

References

- [1] C. Perdoni, M.E. Eustaquio, Ectopic thyroid presenting as a submental mass: a case report, *Otolaryngol. Case Rep.* 4 (2017) 9–11, <https://doi.org/10.1016/j.xocr.2017.07.001>.
- [2] F.W. Neinas, C.A. Gorman, K.D. Devine, L.B. Woolner, Lingual thyroid. Clinical characteristics of 15 cases, *Ann. Intern. Med.* 79 (2) (1973) 205–210, <https://doi.org/10.7326/0003-4819-79-2-205>.
- [3] J.J. Sauk Jr., Ectopic lingual thyroid, *J. Pathol.* 102 (4) (1970) 239–243, <https://doi.org/10.1002/path.1711020408>.
- [4] S. Wildi-Runge, S. Stoppa-Vaucher, R. Lambert, S. Turpin, G. Van Vliet, J. Deladoëy, A high prevalence of dual thyroid ectopy in congenital hypothyroidism: evidence for insufficient signaling gradients during embryonic thyroid migration or for the polyclonal nature of the thyroid gland? *J. Clin. Endocrinol. Metab.* 97 (6) (2012) E978–E981, <https://doi.org/10.1210/jc.2011-3156>.
- [5] E. Karakoc-Aydiner, S. Turan, I. Akpınar, et al., Pitfalls in the diagnosis of thyroid dysgenesis by thyroid ultrasonography and scintigraphy, *Eur. J. Endocrinol.* 166 (1) (2012) 43–48, <https://doi.org/10.1530/EJE-11-0140>.
- [6] R.A. Agha, T. Franchi, C. Sohrabi, G. Mathew, for the SCARE Group, The SCARE 2020 guideline: updating consensus Surgical CAse REport (SCARE) guidelines, *Int. J. Surg.* 84 (2020) 226–230.
- [7] G.E. Christopher, J.R. Cantrell, W.B. Allan, The surgical treatment of lingual thyroid, *Ann. Surg.* 139 (5) (1954) 536–546, <https://doi.org/10.1097/00000658-195405000-00002>.
- [8] M. Nilsson, H. Fagman, Development of the thyroid gland, *Development.* 144 (12) (2017) 2123–2140, <https://doi.org/10.1242/dev.145615>.
- [9] T. Gu, B. Jiang, N. Wang, F. Xia, L. Wang, A. Gu, F. Xu, Y. Han, Q. Li, Y. Lu, New insight into ectopic thyroid glands between the neck and maxillofacial region from a 42-case study, *BMC Endocr. Disord.* 15 (2015) 70, <https://doi.org/10.1186/s12902-015-0066-6>.
- [10] R.H. Allard, The thyroglossal cyst, *Head Neck Surg.* 5 (2) (1982) 134–146, <https://doi.org/10.1002/hed.2890050209>.
- [11] M. Chawla, R. Kumar, A. Malhotra, Dual ectopic thyroid: case series and review of the literature, *Clin. Nucl. Med.* 32 (1) (2007) 1–5, <https://doi.org/10.1097/01.rlu.0000249590.70176.58>.
- [12] A. Sood, V. Sood, D.R. Sharma, R.K. Seam, R. Kumar, Thyroid scintigraphy in detecting dual ectopic thyroid: a review, *Eur. J. Nucl. Med. Mol. Imaging* 35 (4) (2008) 843–846, <https://doi.org/10.1007/s00259-007-0672-2>.
- [13] V.T. Yeung, E.P. Loong, C.S. Cockram, Cretinism and lingual thyroid presenting in an adult, *Postgrad. Med. J.* 63 (744) (1987) 881–883, <https://doi.org/10.1136/pgmj.63.744.881>.
- [14] G.E. Ward, J.R. Cantrell, W.B. Allan, The surgical treatment of lingual thyroid, *Ann. Surg.* 139 (5) (1954) 536–546, <https://doi.org/10.1097/00000658-195405000-00002>.
- [15] J.G. Batsakis, A.K. El-Naggar, M.A. Luna, Thyroid gland ectopias, *Ann. Otol. Rhinol. Laryngol.* 105 (12) (1996) 996–1000, <https://doi.org/10.1177/000348949610501212>.
- [16] R.T. Long, A.M. Evans, J.H. Beggs, Surgical management of ectopic thyroid: report of a case with simultaneous lingual and subhyoid median ectopic thyroid, *Ann. Surg.* 160 (5) (1964) 824–827, <https://doi.org/10.1097/00000658-19641000-00007>.
- [17] V. Marković, G. Glavina, D. Eterović, A. Punda, D. Brdar, Dual ectopic thyroid gland: sonography and scintigraphy of lingual and sublingual thyroid, *Clin. Nucl. Med.* 39 (6) (2014) 556–558, <https://doi.org/10.1097/RLU.0000000000000415>.
- [18] L. Ling, S.H. Zhou, S.Q. Wang, L.J. Wang, Misdiagnosed ectopic thyroid carcinoma: report of two cases, *Chin. Med. J.* 117 (10) (2004) 1588–1589.
- [19] N. Balalaa, M. Megahed, M.A. Ashari, F. Branicki, Thyroglossal duct cyst papillary carcinoma, *Case Rep. Oncol. Med.* 4 (1) (2011) 39–43, Published 2011 Jan 29 <https://doi.org/10.1159/000324405>.
- [20] S.S. Palaniswamy, P. Subramanyam, Dual thyroid ectopia and heterotopic thyroid autotransplantation, *Clin. Nucl. Med.* 45 (8) (2020) 623–625, <https://doi.org/10.1097/RLU.00000000000003162>.