

Gastric Peroral Endoscopic Myotomy as a Therapeutic Option in Refractory Gastroparesis: A Step-By-Step Description

Carolina Chálim Rebelo Nuno Nunes Diogo Bernardo Moura
Francisca Corte-Real José Renato Pereira Maria Antónia Duarte

Gastroenterology Department, Hospital do Divino Espírito Santo de Ponta Delgada, Ponta Delgada, Portugal

Keywords

Gastric peroral endoscopic myotomy · Endoscopic pyloromyotomy · Refractory gastroparesis · Pyloroplasty

G-POEM como opção terapêutica na gastroparesia refratária – uma descrição passo a passo

Palavras Chave

Miotomia endoscópica gástrica per-oral · Gastroparesia refratária · Píloromiotomia endoscópica · Píloroplastia

Gastroparesis is a chronic disorder characterized by delayed gastric emptying without evidence of stomach or proximal small intestine obstruction [1]. Its pathophysiology is unclear, although gastric arrhythmias, fundal and antral hypocontractility, pylorospasm, and antropyloroduodenal incoordination might be involved [1]. Dietary modifications and prokinetics are first-line treatments. When refractory gastroparesis is present, surgical or endoscopic treatment must be considered.

We present a case of a 68-year-old female patient, followed in gastroenterology consult due to nausea, persistent postprandial vomiting, early satiety, and belching.

She has no relevant past medical or surgical history or medication. Esophagogastroduodenoscopy revealed food stasis but was otherwise normal. Gastric emptying scintigraphy (GES) showed emptying of 30% at 156 min, 46% at 217 min, and 54% at 260 min, with significant radiopharmaceutical retention (46% at 4 h 18 min), translating scintigraphic evidence of delayed gastric emptying (Fig. 1). The diagnosis of gastroparesis was made, and medical therapy was optimized. She had no improvement after 6 months, traducing a Gastroparesis Cardinal Symptom Index (GCSI) score of 3.33 points (0–5 points) [2]. Idiopathic refractory gastroparesis was admitted, and gastric peroral endoscopic myotomy (G-POEM) was proposed.

The procedure was performed with an endoscope (GIF-HQ190; Olympus Medical Systems, Tokyo, Japan), with a transparent distal cap (DH28GR; Fujifilm, Tokyo, Japan) and insufflation with CO₂. The patient was under general anesthesia and orotracheal intubation. The VIO[®]3 (Erbe Elektromedizin GmbH, Tuebingen, Germany) was used as the electrosurgical unit. Antibiotic (cefotaxime 1 g) was administered. The procedure began with submucosal injection, in the greater gastric curvature, 5 cm proximal to the pylorus with a solution of 100

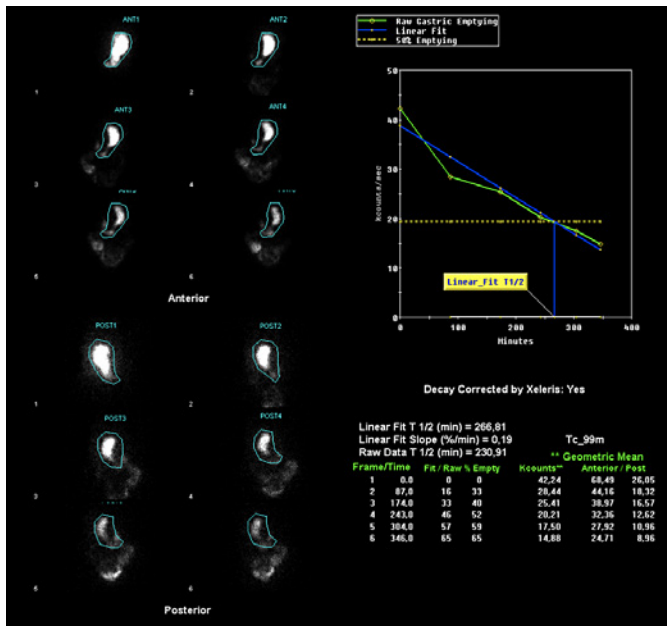


Fig. 1. Scintigraphic images before the G-POEM, with evidence of delayed gastric emptying.

mL normal saline, 1 mL indigo carmine, and 1 mL adrenaline, followed by a mucosal longitudinal incision with a triangle-tip knife, using dry-cut current effect 2. Then, a submucosal tunnel was created from the mucosal incision to the pylorus, with spray-coagulation current. Full-thickness pyloromyotomy involving circular and oblique muscle bundles was performed, from the pylorus extending 3 cm proximally toward the antrum (using triangle-tip and IT-nano™ knives [KD-640L, KD-612L/U; Olympus] with spray-coagulation and Endocut Q currents). The mucosal incision was closed with several clips (online suppl. video; see www.karger.com/doi/10.1159/000527016 for all online suppl. material; Fig. 2a–f). The procedure was uneventful. On the day after, a gastro-duodenal transit excluded leakage. She started a liquid diet, with good tolerance, and was discharged on the second day, medicated with 40 mg pantoprazole bid and ciprofloxacin for 7 days. She was on a soft diet for 1 week and then proceeded to small meals low in fiber and fat.

Three months post-procedure, the GCSI score was of 2.11 points. Reassessment scintigraphy showed 29% gastric emptying at 50 min, 64% at 113 min, and 95% at 194

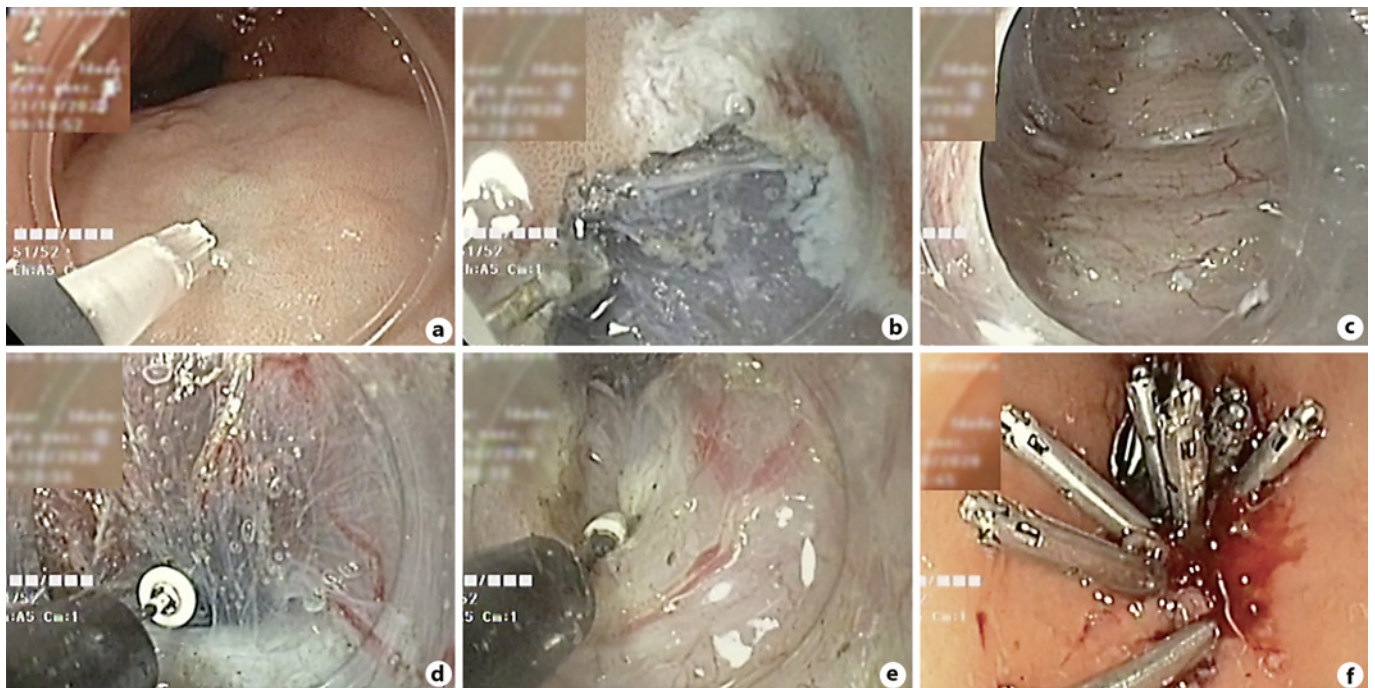


Fig. 2. **a** Submucosal injection 5 cm proximal to the pylorus. **b** Mucosal longitudinal incision. **c** Submucosal tunnel creation from the mucosal incision to the pylorus. **d, e** Full-thickness pyloromyotomy – from the pylorus extending 3 cm proximally toward the antrum. **f** Mucosal incision closed with clips.

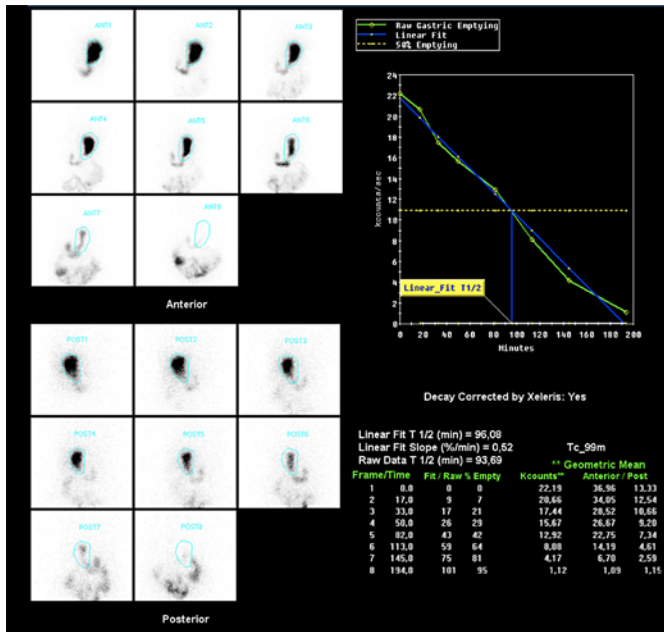


Fig. 3. Scintigraphic images after the G-POEM, with no evidence of delayed gastric emptying at any time.

min, with no evidence of delayed gastric emptying at any time (Fig. 3).

G-POEM has a reported clinical success rate of 56–90% [3, 4], with described clinical improvement sustained up to 12–18 months after the procedure [3, 5]. Most adverse events are mild, being capnoperitoneum the most common [1, 3]. When compared to surgical pyloroplasty, G-POEM has similar clinical success in terms of GCSI score and GES, with comparable adverse events [1]. According to a multicentric prospective study, G-POEM should be considered in patients with more severe symptoms along with significant retention on GES [3]. The G-

POEM represents an advance in the endoscopic approach of refractory gastroparesis, with the advantage of being a minimally invasive technique.

Statement of Ethics

Ethical approval was not required for this study in accordance with local/national guidelines. The patient gave her written informed consent to publish this case and images.

Conflict of Interest Statement

The authors have no conflicts of interest to declare.

Funding Sources

None

Author Contributions

Carolina Chálim Rebelo is responsible for writing the clinical case and review of literature, and edited the video and script of the manuscript. Nuno Nunes performed the procedure, gave important scientific input, and reviewed the manuscript. Diogo Bernardo Moura and Francisca Corte-Real contributed with review of the literature. José Renato Pereira and Maria Antónia Duarte guaranteed the accuracy of the content and did the final review before submitting.

Data Availability Statement

All data generated or analyzed during this study are included in this article and its online supplementary material files. Further inquiries can be directed to the corresponding author.

References

- Chung CS, Huang TY, Lin CL, Chiang CH, Chen KC, Wu JM, et al. Efficacy and safety of gastric peroral endoscopic myotomy (G-POEM) for refractory gastroparesis: 3-year follow up results. *J Formos Med Assoc.* 2021; 121(7):1334–41.
- Revicki DA, Rentz AM, Dubois D, Kahrilas P, Stanghellini V, Talley NJ, et al. Development and validation of a patient-assessed gastroparesis symptom severity measure: the Gastroparesis Cardinal Symptom Index. *Aliment Pharmacol Ther.* 2003;18(1):141–50.
- Vosoughi K, Ichkhanian Y, Benias P, Miller L, Aadam AA, Triggs JR, et al. Gastric per-oral endoscopic myotomy (G-POEM) for refractory gastroparesis: results from an international prospective trial. *Gut.* 2022;71(1):25–33.
- Kamal F, Khan MA, Lee-Smith W, Sharma S, Acharya A, Johwar D, et al. Systematic review with meta-analysis: one-year outcomes of gastric peroral endoscopic myotomy for refractory gastroparesis. *Aliment Pharmacol Ther.* 2022;55(2):168–77.
- Mekaroonkamol P, Dacha S, Wang L, Li X, Jiang Y, Li L, et al. Gastric peroral endoscopic pyloromyotomy reduces symptoms, increases quality of life, and reduces health care use for patients with gastroparesis. *Clin Gastroenterol Hepatol.* 2019;17(1):82–9.