

Adrenal Angiomyolipoma: A Case Report

Mohamed Ahmed ¹, Ahmed Mahmoud ², Amarseen Mikael ², Rasha Saeed ³, Dina Elias ⁴

1. Surgery, University of California, Riverside, USA 2. Surgery, Riverside Community Hospital, Riverside, USA 3. Surgery, Arrowhead Regional Medical Center, Fontana, USA 4. Trauma, Riverside Community Hospital, Riverside, USA

Corresponding author: Mohamed Ahmed, maamsmd@yahoo.com

Abstract

Angiomyolipoma (AML) is a mesenchymal tumor that arises from perivascular epithelioid cells most commonly seen in the kidney and rarely in extrarenal sites. Adrenal AML is a rare clinical entity with only 16 cases reported in the literature according to the World Health Organization report in 2017. We present a 68-year-old male evaluated in our emergency room with worsening chronic right upper quadrant abdominal pain. Computerized tomography (CT) revealed a large right adrenal mass. Adrenalectomy was performed, and the histopathology report confirmed the diagnosis and the tumor size was the largest ever reported. Patient was discharged uneventfully.

Categories: Endocrinology/Diabetes/Metabolism, Pathology, General Surgery

Keywords: angiomyolipoma, adrenal mass

Introduction

Angiomyolipoma (AML) is a mesenchymal tumor derived from perivascular epithelioid cells and consist of blood vessels, muscle cells, and fat tissue [1]. Extrarenal AML is most commonly found to occur in the liver and less commonly in the spleen, lungs, retroperitoneum, bone, and ovaries [2-3]. Adrenal AML is very rare with only 16 reported worldwide, five of which in the English literature [4-5]. It is usually asymptomatic and incidentally diagnosed on a radiological investigation of the abdomen [6]. We present a case of right-sided giant adrenal AML found in a patient presented with right-sided abdominal pain.

Case Presentation

A 68-year-old male presented to our emergency room with acute on chronic right upper quadrant pain physical examination revealed a right upper quadrant mass with discomfort on deep palpation. Past medical history includes diabetes mellitus, renal insufficiency, and hypertension requiring multiple medications to control. CT revealed a 17.3 x 14.6 x 16 cm fat-containing mass originating from the right adrenal gland (Figure 1).

Received 12/09/2019

Review began 12/11/2019

Review ended 02/02/2020

Published 02/04/2020

© Copyright 2020

Ahmed et al. This is an open access article distributed under the terms of the Creative Commons Attribution License CC-BY 4.0., which permits unrestricted use, distribution, and reproduction in any medium, provided the original author and source are credited.

How to cite this article

Ahmed M, Mahmoud A, Mikael A, et al. (February 04, 2020) Adrenal Angiomyolipoma: A Case Report. Cureus 12(2): e6881. DOI 10.7759/cureus.6881

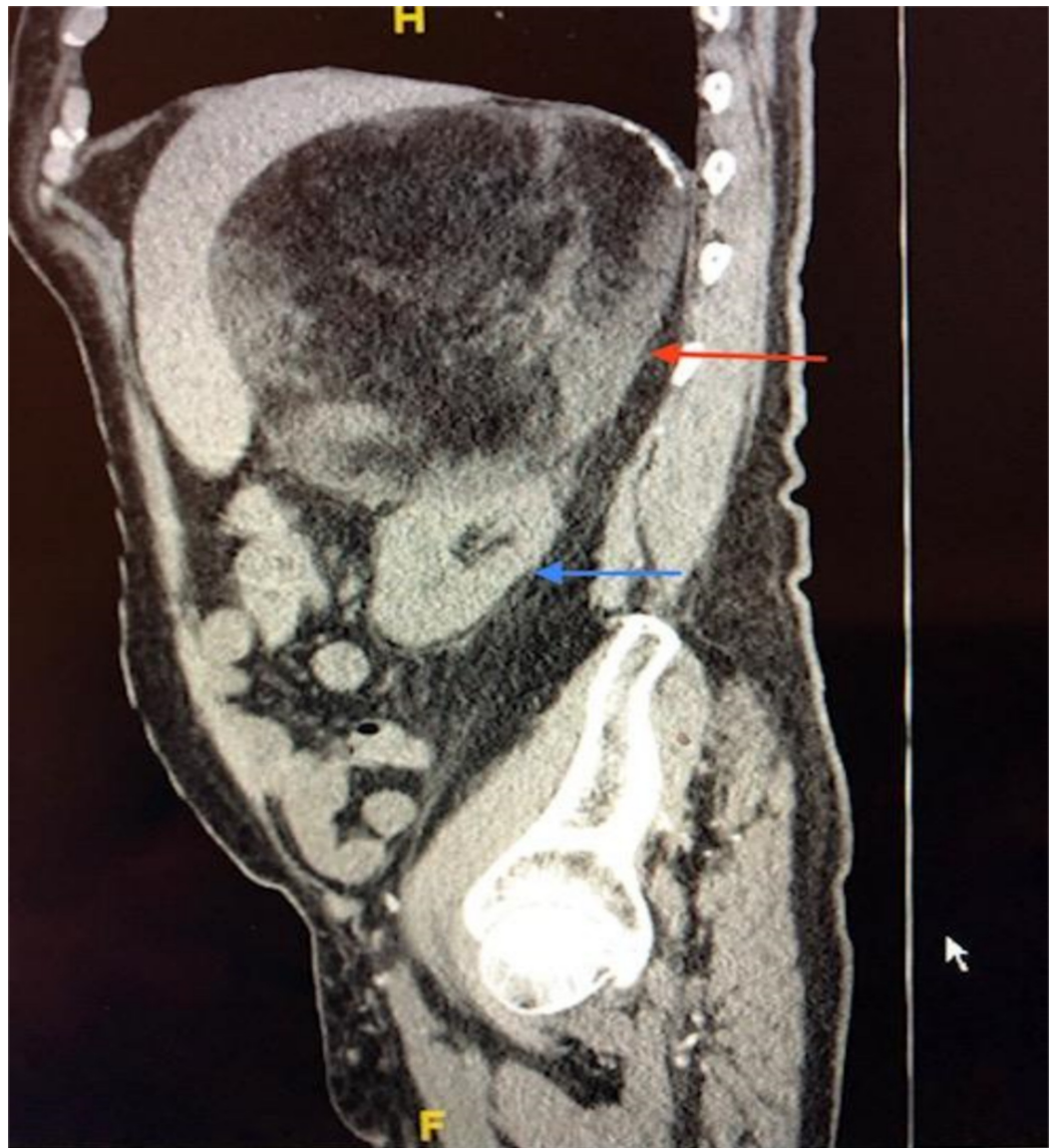

FIGURE 1: Computed tomography of the abdomen and pelvis

Adrenal mass (red arrow); Kidney (blue arrow)

Patient was admitted to the hospital and it was determined to be a nonfunctioning adrenal mass after a series of testing to include renin activity of 0.449 ng/ml/hr (0.167-5.380), aldosterone (1.0 ng/dL (0.0-30.0), cortisol 13.25 mcg/dL (3.1-22.4), ACTH 40.3 pg/mL (7.2-63.3), plasma metanephrine 12 pg/mL (0-62), plasma normetanephrine 104 pg/mL (0-145). Urine 24-h metanephrine 48 ug/24hr (45-290), urine 24-h normetanephrine 244 ug/24hr (82-500). Patient was taken to the operating room and a right adrenalectomy was performed (Figure 2).

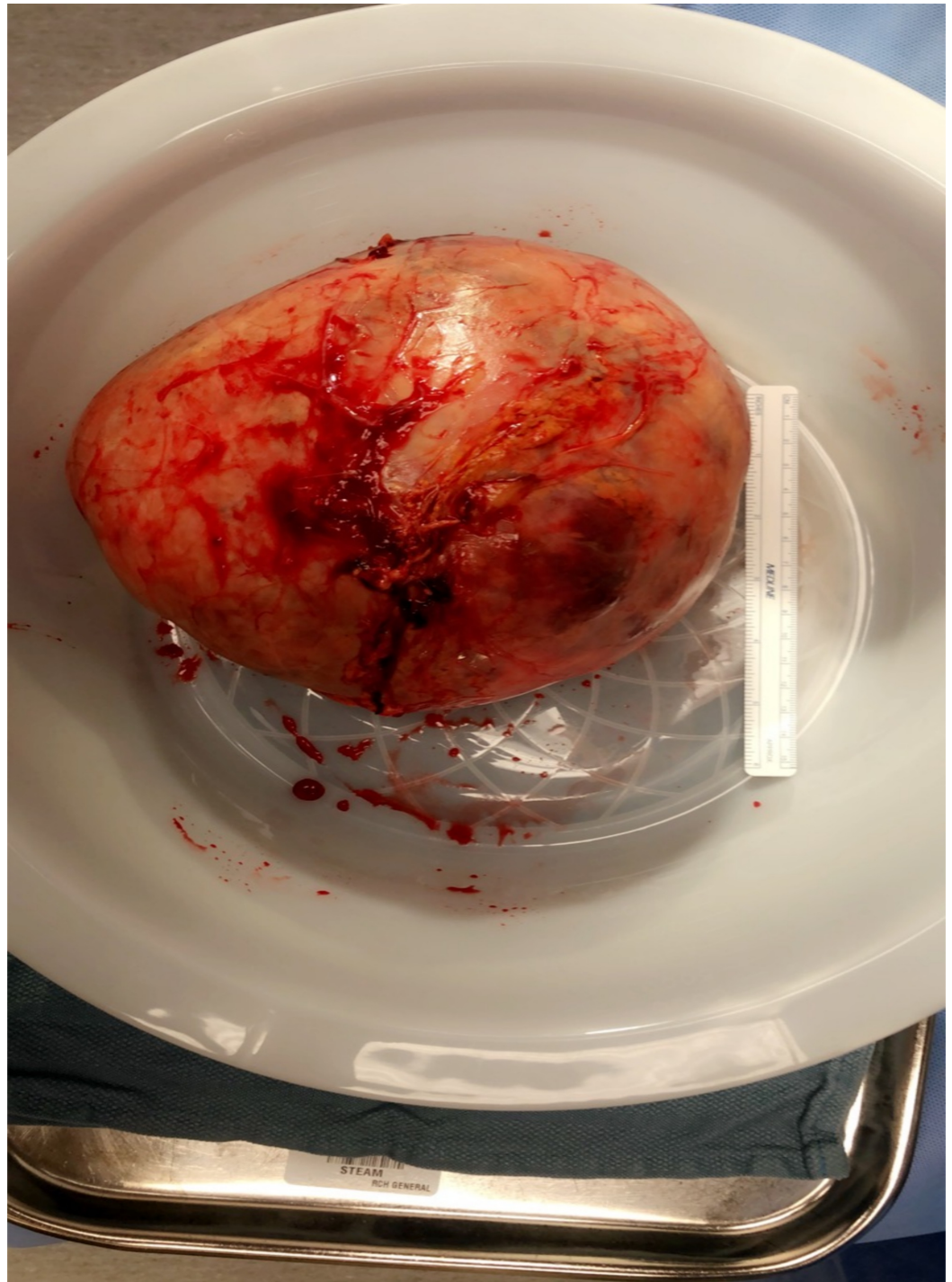


FIGURE 2: Adrenal gland tumor

Large adrenal mass

Histopathology confirmed the diagnosis (Figure 3).

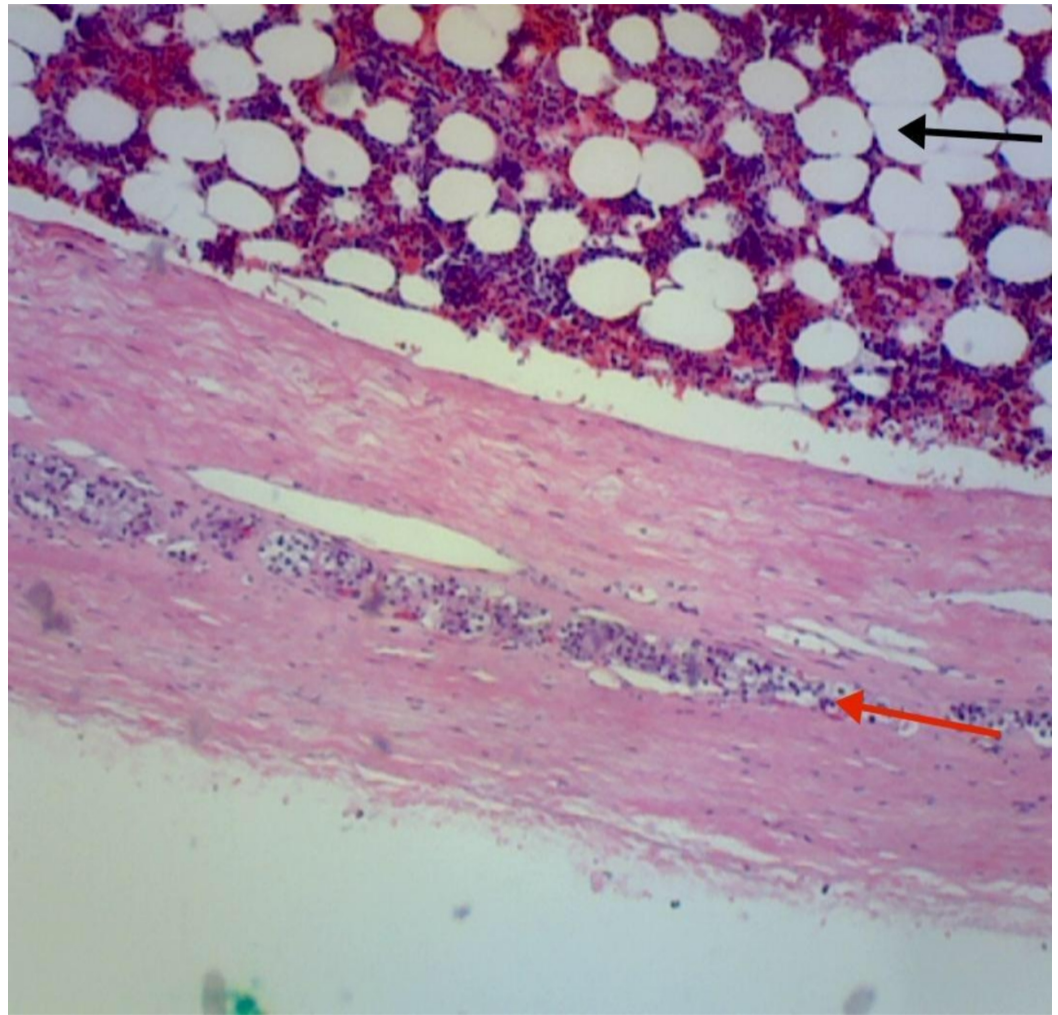


FIGURE 3: Histopathology

Red arrow: Fibrous capsule with a thin band of compressed adrenal cortex.

Black Arrow: Hematopoietic tissue.

The patient had an uneventful recovery and was discharged from the hospital.

Discussion

In 1951, Morgan described a benign renal tumor composed of blood vessels, muscle, and fat and the term "angiomyolipoma" was introduced [7]. The use of better imaging techniques has been associated with a surge of incidental adrenal lesions. Lipomatous tumors of the adrenal gland are uncommon and account for roughly 5% of primary adrenal tumors [8]. It includes myelolipoma, lipomas, teratoma, liposarcoma, and rarely AML [9]. Adrenal AML is an extremely uncommon tumor usually detected incidentally. Small asymptomatic tumors may be managed with active serial imaging surveillance, however, large asymptomatic AML should be removed to avoid spontaneous rupture due to the presence of abnormal elastin in the tumor [10]. Symptomatic tumor treatment includes excision, angioembolization, or cryotherapy. In our case, the tumor size was 20 x 16 cm and the largest ever reported was 15x16 cm [11].

Conclusions

AML is a mesenchymal tumor usually found in the kidney. Extrarenal AML is uncommon, with the adrenal gland being an exceedingly rare location. They are often misdiagnosed as sarcomatoid carcinoma, carcinoma or sarcoma and are known to be diagnostic challenges to pathologists. The tumor can grow to a significant size, and we believe our case is the largest ever reported. An asymptomatic small tumor can be managed with active surveillance; however, large or symptomatic tumors should be resected to avoid complications including spontaneous rupture likely due to the presence of abnormal elastin. Angioembolization or cryotherapy are considered as other options of therapy.

Additional Information

Disclosures

Human subjects: Consent was obtained by all participants in this study. **Conflicts of interest:** In compliance with the ICMJE uniform disclosure form, all authors declare the following: **Payment/services info:** All authors have declared that no financial support was received from any organization for the submitted work. **Financial relationships:** All authors have declared that they have no financial relationships at present or within the previous three years with any organizations that might have an interest in the submitted work. **Other relationships:** All authors have declared that there are no other relationships or activities that could appear to have influenced the submitted work.

References

1. Flum A, Hamoui N, Said M: Update on the diagnosis and management of renal angiomyolipoma. *J Urol.* 2016, 195:834-46. [10.1016/j.juro.2015.07.126](https://doi.org/10.1016/j.juro.2015.07.126)
2. Elsayes K, Narra V, Lewis J: Magnetic resonance imaging of adrenal angiomyolipoma. *J Comput Assist Tomogr.* 2005, 29:80-2. [10.1097/01.rct.0000152863.97865.47](https://doi.org/10.1097/01.rct.0000152863.97865.47)
3. D'Antonio A, Caleo A, Caleo O: Monotypic epithelioid angiomyolipoma of the adrenal gland: An unusual site for a rare extrarenal tumor. *Ann Diagn Pathol.* 2009, 13:347-50. [10.1016/j.anndiagpath.2009.02.010](https://doi.org/10.1016/j.anndiagpath.2009.02.010)
4. Lam A: Lipomatous tumours in adrenal gland: WHO updates and clinical implications. *Endocr Relat Cancer.* 2017, 24:R65-79. [10.1530/ERC-16-0564](https://doi.org/10.1530/ERC-16-0564)
5. Antar A, Boyle A, Patel T: Angiomyolipoma of the adrenal gland: A case presentation and a review of adrenal lipomatous tumors. *Urol Case Rep.* 2017, 12:59-61. [10.1016/j.eucr.2016.11.004](https://doi.org/10.1016/j.eucr.2016.11.004)
6. Godara R, Vashist M, Singla S: Adrenal angiomyolipoma: A rare entity. *Indian J Urol.* 2007, 23:319-20. [10.4103/0970-1591.33734](https://doi.org/10.4103/0970-1591.33734)
7. Morgan G, Straumf J, Hall E: Angiomyolipoma of the kidney. *J Urol.* 1951, 65:525-7. [10.1016/s0022-5347\(17\)68515-x](https://doi.org/10.1016/s0022-5347(17)68515-x)
8. Lam K, Lo C: Adrenal lipomatous tumours: a 30 year clinicopathological experience at a single institution. *J Clin Pathol.* 2001, 54:707-712.
9. Abdulkader M, Abercrombie J, McCulloch T: Colonic angiomyolipoma with a monotypic expression and a predominant epithelioid component. *J Clin Pathol.* 2005, 58:1107-1109. [10.1136/jcp.2004.025130](https://doi.org/10.1136/jcp.2004.025130)
10. Makino E, Yamada J, Tada J: Cutaneous angiolipoleiomyoma. *J Am Acad Dermatol.* 2006, 54:167-71. [10.1016/j.jaad.2004.03.029](https://doi.org/10.1016/j.jaad.2004.03.029)
11. Hu H, Xi X: Giant adrenal angiomyolipoma. *J Clin Endocrinol Metab.* 2012, 97:3835-6.