

Can Ultrasound Predict Malignancy in Patient with Thyroid Cold Nodule?

Joko Wiyanto, Achmad Hussein Sundawa Kartamihardja, Trias Nugrahadi

Department of Nuclear Medicine and Molecular Imaging, Dr. Hasan Sadikin General Hospital, Universitas Padjadjaran, Bandung, Indonesia

Abstract

Thyroid nodule is one of the most common endocrine diseases in the world; it occurs in 4–7% of the general population. Depending on the method of discovery, 4–8% nodules are discovered using palpation, 10–41% with ultrasound (US), and 50% through autopsy where only 20% or less of cold thyroid nodules are caused by cancerous lesions. The aim of this study was to assess US as supporting modality for thyroid scintigraphy to predict malignancy in patient with thyroid cold nodules. In a retrospective study between 2009 and 2013, we analyzed 399 subjects with cold thyroid nodule, where 39 subjects (36 women and 3 men) presented with malignant thyroid cold nodule and 19 subjects underwent US. The US showed malignancy parameters in 8 (42.11%) subjects, while the rest of the 11 (57.89%) subject were benign. Out of all the subjects who underwent US in this study, only 8 (42.11%) subjects shown malignancy characteristics in cold thyroid nodule with papillary thyroid cancer (PTC). That means US parameters of malignant thyroid nodule do not always show up in malignant cold thyroid nodule.

Keywords: Cold nodule thyroid, thyroid scintigraphy, ultrasound thyroid malignancy

Introduction

Thyroid nodule is one of the most common endocrine diseases in the world. It affects approximately 4–7% of the general population in the iodine-sufficient areas, with a markedly increased incidence in iodine-deficient regions. Thyroid nodules are classified as adenomas, carcinomas, or hyperplastic lesions based on their macroscopic and microscopic histological features.^[1,2]

Adenomas consist of encapsulated lesions derived from the follicular epithelium, and they may be present in isolated, macrofollicular (colloid), microfollicular (fetal), and trabecular/solid (embryonic) forms.^[2,3] Adenomas may be functioning (autonomous), in which case they are proportionally larger than the rest of the parenchyma

and they produce excessive thyroid hormones; or they may be nonfunctioning, in which case hormone levels are unchanged. Autonomous adenomas can occur at any age, but they are rarely toxic in individuals under 60 years of age. These nodules are generally considered benign, with rare cases of malignancy.^[4]

Nodular hyperplastic lesions are characteristically present in multinodular goiter (MNG) and are caused by follicular cell hyperplasia. In some cases, hyperplastic nodules can grow and become autonomous even in the absence of external stimuli.^[5]

Differentiated thyroid carcinomas (DTCs), which encompass papillary and follicular carcinomas, are relatively uncommon tumors. They are generally associated with a good prognosis, with an estimated incidence rate of 1–10 cases per 100,000 people per year.

Address for correspondence:

Dr. Joko Wiyanto,
Jl. Pasir Kaliki No 192, Bandung - 40161, Indonesia.
E-mail: new.baru@outlook.com

Access this article online

Quick Response Code:



Website:
www.wjnm.org

DOI:
10.4103/1450-1147.174704

This is an open access article distributed under the terms of the Creative Commons Attribution-NonCommercial-ShareAlike 3.0 License, which allows others to remix, tweak, and build upon the work non-commercially, as long as the author is credited and the new creations are licensed under the identical terms.

For reprints contact: reprints@medknow.com

How to cite this article: Wiyanto J, Kartamihardja AH, Nugrahadi T. Can ultrasound predict malignancy in patient with thyroid cold nodule?. World J Nucl Med 2016;15:179-83.

They are the most common endocrine neoplasm in the world, but they represent only 1% of all malignancies.^[6,7]

Undifferentiated or anaplastic carcinomas represent approximately 5% of all thyroid carcinomas, and medullary thyroid carcinoma (MTC), which is derived from parafollicular cells, may occur sporadically or familiarly.^[8]

Due to the increased use of ultrasonography (US) and the increased access to cytology analysis through fine-needle aspiration biopsy (FNAB) guided by US (US-FNAB), the number of small-sized thyroid gland carcinoma diagnoses has increased in many other countries.^[5,9]

Scintigraphy and thyroid uptake have been utilized for over 60 years. They are valuable procedures for investigating a number of thyroid dysfunctions, such as destructive thyroiditis, ectopic thyroid, and hyperfunctioning nodules. However, they have limited diagnostic value for iso- or hypo functioning thyroid nodules.^[9]

Scintigraphy [and thyroid uptake with radioactive iodine or Technetium-99m (Tc-99m) pertechnetate when TSH is subnormal] is recommended for evaluating functional nodules. Hyperfunctioning nodules are almost always benign, while nonfunctioning nodules carry estimated malignancy risk rates of 10–20%.^[10] Additionally, scintigraphy is indicated for determining the functional status of nodules with indeterminate cytology; the goal is to detect hot nodules that are probable follicular adenomas and to differentiate between the nodules in MNGs.^[11] Cervical ultrasound (US) is the method of choice for studying thyroid nodules, and it enables the evaluation of the size, location, and characteristics suggestive of malignancies.^[12]

According to Leenhardt *et al.*,^[13] hypoechogenicity has a moderate positive predictive value (50–63%) for malignancy in thyroid nodules, with high sensitivity (75%) and specificity (61–83%) for US examination. Li *et al.*^[14] reviewed the US features of 115 nodules in 104 patients with PTC and found that microcalcifications, central flow, and irregular borders were directly associated with malignant thyroid nodules. Gonzalez-Gonzales^[15] studied the US characteristics of 341 thyroid nodules and found that microcalcifications were the only variable that was significantly associated with malignancy.

Moon *et al.*^[16] analyzed 1,083 thyroid nodules and found that the central flow is the most common distinction between benign and malignant nodules. Of the 1,083 nodules studied, 814 were benign and 269 were malignant. Intranodular vascularity was frequently

observed in the benign nodules, and vascularity was more typically absent in the malignant nodules.

According to the literature, the malignancy rate in thyroid nodules that are 4 cm or larger, with indeterminate cytology, varies from 10% to 30%.^[17,18] Rosa rio *et al.*^[19] found malignancies in 23.5% of the cases with indeterminate cytology. They found suspicious characteristics in the USs of 76% of these nodules, compared with 6.5% of the nodules with no suspicious aspects. In a recent analysis, Kihara *et al.*^[20] found no association between nodule size or thyroglobulin level and malignancy risk in 137 surgically treated patients. However, they observed that malignancy was directly associated with suspicious US findings. These findings were similar to those of Maia *et al.*,^[21] who assessed the correlations among the cytological variables of the Bethesda system and the clinical, US, and scintigraphic data from patients with thyroid nodules with indeterminate cytology. Malignancy was found in 68.4% of the nodules with suspicious US characteristics versus 14.8% of those with normal US findings. After the multivariate analysis, border irregularity as observed by US and Bethesda IV category were able to accurately predict malignancy in 76.9% of the thyroid nodules with indeterminate cytology. The multivariate model showed nodule size 2 cm, microcalcifications, and border irregularity based on US study were predictive factors for malignancy, with a combined accuracy of 81.7%.

The management of patients with solitary “cold” thyroid nodules remains controversial due to the high incidence of nodules contrasted with the relative infrequency of cancer and the low morbidity and mortality associated with thyroid malignancy. Radionuclide imaging serves to confirm the presence of the nodule within the thyroid, to identify the functional characteristics of the nodule, and to demonstrate the presence of multiple nodules. Although thyroid malignancies do not effectively concentrate radioisotopes, only 20% or less of “cold” thyroid nodules are caused by cancerous lesions. The remaining 80% arise from thyroid adenomas, colloid nodules, degenerative nodules, nodular hemorrhage, simple cysts, inflammatory nodules (including Hashimoto’s thyroiditis and De Quervain’s thyroiditis), infiltrative disorders (including amyloid or hemochromatosis), or nonthyroid neoplasms. Surgery is generally required to provide a definitive diagnosis, although needle biopsies have been used in some major medical centers.^[22]

For the detection of thyroid nodular disease US examinations of the neck play a dominant role. As potential predictors for malignancy several US features have been described, such as calcifications, taller than wide shape, irregular margins, hypoechogenicity, and increased flow in Power Doppler examinations [Figure 1].

The sensitivity and specificity have been found to be relatively low for each of these findings resulting in a diagnostic accuracy of far below 100%. In a recent US consensus statement the panel has identified important unanswered questions that merit future research in thyroid nodular disease.

Besides growth dynamics and selection of nodules for FNAB, the panel points toward the question whether there is a combination of US characteristics that might be used to direct management. There is abundant scientific work using US examinations in a series of thyroid nodules that includes both benign and malignant neoplasms. Sonographic work has also been done in malignant thyroid nodules with inconsistent different histologic differentiation. US criteria for papillary carcinomas have been compiled in a multicenter study.^[23]

The aim of this study was to assess US as supporting modality for thyroid scintigraphy to predict malignancy in patient with thyroid cold nodules.

Materials and Methods

In a retrospective clinical study conducted between 2009 and 2013, we analyzed 399 subjects with cold thyroid nodule, where 39 subjects (36 women and 3 men) with malignant thyroid cold nodule and 19 subjects underwent US. The study analyzed 19 patients (16 women and 3 men), who underwent thyroid scintigraphy, US, and histopathology.

Scintigraphy was performed in the Department of Nuclear Medicine And Molecular Imaging, Dr. Hasan Sadikin Hospital, using Siemens and GE two-head gamma camera (Bandung) according to the standard application protocol Tc-99m pertechnetate.

US and cytology of the thyroid was performed in another department. The inclusion criterion is as follows: Patients with cold thyroid nodules and US result confirmed malignancies by histopathologic examination.

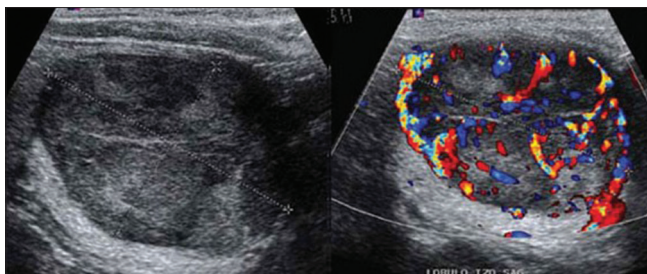


Figure 1: Transverse ultrasound scan shows a well-defined, homogeneous, solid iso-hypoechoic oval-shaped thyroid nodule, suggestive of a follicular lesion

Results

On thyroid scintigraphy, all of the 19 patients (100%) were found to have cold thyroid nodules and in histopathological examination they were diagnosed with papillary carcinoma thyroid [Figure 2]. Out of the 19 patients who underwent US, 3 (15.79%) were diagnosed with isoechoic nodules, 2 (10.53%) with isoechoic nodules with cystic degeneration, 4 (21.05%) were diagnosed with an anechoic formation with thickened wall, 7 (36.84%) were diagnosed with hypoechoic nodules, and 8 (42.11%) were diagnosed with irregular border hypoechoic nodules with calcification [Table 1].

Discussion

Nodular thyroid diseases are common. They are present in around 4–7% of the general population. Out of the total number cancer is diagnosed in 5–20% cases. The primary goal in the examination of the thyroid is to determine whether it has benign or maligning nodules, in order for patients with cancer to be timely diagnosed and be adequately treated in the early stages of the disease, reducing morbidity and mortality rates and avoiding unnecessary procedures, including unnecessary surgical treatments of benign changes.

It is known that US-FNAB is the best individual diagnostic procedure for diagnosing malignant nodules, due to its high sensitivity and specificity. However, taking into consideration a large percentage of nodule occurrences, it is necessary to make a selection of nodules to be diagnosed through the aforementioned method. Analyzing the gathered results, the study proved that there was no statistically significant connection between scintigraphy exam results and cytology exam results with cold nodules.

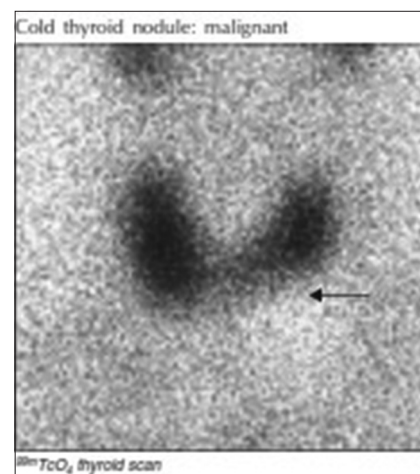


Figure 2: Papillary carcinoma: A nonfunctioning nodule in the lower pole of the left lobe of thyroid (arrow). Fine-needle aspiration was suspicious for papillary carcinoma that was confirmed on histology

Table 1: Finding ultrasound appearance parameters of malignancy in cold thyroid nodule with carcinoma papillary thyroid

	Cold Thyroid Nodule With Carcinoma Papillary Thyroid		Total
	+	-	
Ultrasound	8	11	19

However, a statistically significant connection has been found amongst warm nodules (all showed thyroid follicular cell proliferations in goiter). Frederico *et al.*^[24] in their research stated that 62% of cold nodule cases were malignant and 76.9% were benign. Warm cases were not showing presence of cancer. Furthermore, they proved no statistically significant difference ($P = 0.33$) in scintigraphy exam results between benign and malignant nodules. Out of the total number of examinees, half, 73 (54.9%), were diagnosed with isoechoic nodules with cystic degenerations. Furthermore, 24 (18.0%) of examinees were diagnosed with hypoechoic nodules; 19 (14.3%) were diagnosed with anechoic formations with thickened wall; 14 (10.5%) examinees were diagnosed with isoechoic nodules; while in 3 (2.3%) examinees irregular border hypoechoic nodules with calcification were noticed.

In this study, three (15.79%) examinees were diagnosed with isoechoic nodules; two (10.53%) were diagnosed with isoechoic nodules with cystic degeneration; four (21.05%) were diagnosed with anechoic formation with thickened wall; seven (36.84%) were diagnosed with hypoechoic nodules; and eight (42.11%) were diagnosed with irregular border hypoechoic nodules with calcification.

Frederico FR Maia *et al.* (2011) in their study stated that US was proven very effective against differentiation of malignant nodules on the basis of their US characteristics such as irregular margins, hypoechoic, and the presence of microcalcification in 82% of the cases.

British scientists Jones *et al.* in their research got the following values for specific diagnostic modalities: FNAB sensitivity, specificity, positive predictive value for thyroid cancer, as follows: 92%, 85%, 41%, scintigraphy 82%, 34%, 11%, US 75%, 61%, 19%.

Kovacevic *et al.*^[25] in their research showed that US characteristics related to malignancy are hypoechoic, irregular margins, calcification, absence of hypoechoic margin. The difference in echoic of malignant and benign lesions was not statistically significant. Authors from the USA Iannuccilli *et al.*^[25] stated that comparison of US characteristics of benign and malignant nodules resulted in defining of microcalcification as the only statistically

significant indicator of malignancy (35.3% sensitivity, 94.4%, $P > 0.005$).

Hong *et al.*^[25] stated that US characteristics for cancer are considered positive when the presence of microcalcification, absence of halo sign and hypoechoic lesions were recognized. Sensitivity and specificity of US in their research is 81% and 70%, and FNAB 87.62%. Gul *et al.* in Turkey stated that US characteristic hypoechoic, microcalcification and irregular margins were the most important in determining malignancy.

Kim *et al.* stated that sensitivity, specificity, positive predictive value, negative predictive value of US were as follows: 93%, 66%, 56%, 95.9%. Tramalloni *et al.* stated the importance of US in estimation of outspread to regional lymph nodes on the basis of US characteristics of malignancy, being round lymph nodes, loss of normal echogenicity, loss of normal hilar vascularization, microcalcification, cystic component and hyperechogenicity of lymph nodes.

Conclusions

The primary goal in examination of the thyroid nodule is to determine whether it has benign or maligning nodules, in order for the patients with cancer to be timely diagnosed and be adequately treated in early stages of the disease, reducing morbidity and mortality, and avoiding unnecessary procedures.

On US eight (42.11%) subjects from this study shown characteristics suggestive of malignancies in cold thyroid nodule with PTC. That means US parameters of malignant thyroid nodule do not always show up in case of malignant cold thyroid nodule.

Financial support and sponsorship

Nil.

Conflicts of interest

There are no conflicts of interest.

References

1. Welker MJ, Orlov D. Thyroid nodules. *Am Fam Physician* 2003;67:559-66.
2. Zeiger MA, Dackiw AP. Follicular thyroid lesions, elements that affect both diagnosis and prognosis. *J Surg Oncol* 2005;89:108-13.
3. De Groot LJ. Multinodular goiter. In: DeGroot LJ, editor. *The Thyroid: A Practical Approach*. 3rd ed. Philadelphia: WB Saunders Company; 1995. p. 611-33.
4. Corvilain B. The natural history of thyroid autonomy and hot nodules. *Ann Endocrinol (Paris)* 2003;64:17-22.
5. Studer H, Derwahl M. Mechanisms of nonneoplastic endocrine hyperplasia—a changing concept: A review focused on the thyroid

- gland. *Endocr Rev* 1995;16:411-26.
6. Cerci C, Cerci SS, Eroglu E, Dede M, Kapucuoglu N, Yildiz M, *et al.* Thyroid cancer in toxic and non-toxic multinodular goiter. *J Postgrad Med* 2007;53:157-60.
 7. Eng CY, Quraishi MS, Bradley PJ. Management of thyroid nodules in adult patients. *Head Neck Oncol* 2010;2:1-5.
 8. Maia AL, Ward LS, Carvalho GA, Graf H, Maciel RM, Maciel LM, *et al.* Thyroid nodules and differentiated thyroid cancer: Brazilian consensus. *Arq Bras Endocrinol Metabol* 2007;51:867-93.
 9. Coeli CM, Brito AS, Barbosa FS, Ribeiro MG, Sieiro AP, Vaisman M. Incidence and mortality from thyroid cancer in Brazil. *Arq Bras Endocrinol Metabol* 2005;49:503-9.
 10. Loy TJ, Sundram FX. Diagnostic management of solitary thyroid nodules. *Ann Acad Med Singapore* 1989;18:658-64.
 11. Davies L, Welch HG. Increasing incidence of thyroid cancer in the United States, 1973-2002. *JAMA* 2006;295:2164-7.
 12. Lew JI, Rodgers SE, Solorzano CC. Developments in the use of ultrasound for thyroid cancer. *Curr Opin Oncol* 2010;22:11-6.
 13. Leenhardt L, Tramalloni J, Aurengo H, Delbot T, Guillausseau C, Aurengo A. Ultrasound of thyroid nodules: The sonographer Help the requirements of clinician. *Presse Med* 1994;23:1389-92.
 14. Li QS, Chen SH, Xiong HH, Xu XH, Li ZZ, Guo GQ. Papillary thyroid carcinoma on sonography. *Clin Imaging* 2010;34:121-6.
 15. González-González A, Mate Valdezate A, Parra Arroyo A, Tenías Burillo JM. Diagnostic efficiency of sonographic findings of thyroid nodules in the detection of malignancy. *Endocrin Nutr* 2010;57:240-4.
 16. Hegedüs L. Clinical practice. The thyroid nodule. *N Engl J Med* 2004;351:1764-71.
 17. Cooper DS, Doherty GM, Haugen BR, Kloos RT, Lee SL, Mandel SJ, *et al.*; American Thyroid Association (ATA) Guidelines Taskforce on Thyroid Nodules and Differentiated Thyroid Cancer. Revised American Thyroid Association management guidelines for patients with thyroid nodules and differentiated thyroid cancer. *Thyroid* 2009;19:1167-214.
 18. Gemenjäger E, Staub JJ, Girard J, Heitz P. Preclinical hyperthyroidism in multinodular goiter. *J Clin Endocrinol Metab* 1976;43:810-6.
 19. Kim SJ, Kim BH, Jeon YK, Kim SS, Kim IJ. Limited diagnostic value of dual-time-point (18) F FDG PET/CT for differentiation of incidentally detected thyroid nodules. *Ann Nucl Med* 2011;25:347-53.
 20. Kihara M, Ito Y, Hirokawa M, Masuoka H, Yabuta T, Tomoda C, *et al.* Role of ultrasonography in patients with cytologically follicular thyroid tumor. *Auris Nasus Larynx* 2011;38:508-11.
 21. Rago T, Di Coscio G, Basolo F, Scutari M, Elisei R, Berti P, *et al.* Combined clinical, thyroid ultrasound and cytological features help to predict thyroid malignancy in follicular and Hurthle cell thyroid lesions: Results from a series of 505 consecutive patients. *Clin Endocrinol (Oxf)* 2007;66:13-20.
 22. Patton JA, Sandler MP, Partain CL. Prediction of benignancy of the solitary "cold" thyroid nodule by fluorescent scanning. *J Nucl Med* 1985;26:461-4.
 23. Cordes M, Kondrat P, Horstrup K, Kuwert T, Sasiadek MJ. Size dependent ultrasound characteristics in histologically confirmed papillary thyroid carcinomas: A multivariate analysis. *Medical Imaging Journal* 2012;6:97-102.
 24. Maia FF, Zantut-Wittmann DE. Thyroid nodule management: Clinical, ultrasound and cytopathological parameters for predicting malignancy. *Clinics (Sao Paulo)* 2012;67:945-54.
 25. Sehovic S, Begic A, Juric N, Celam M. Comparison between ultrasound, scintigraphy and cytological puncture in diagnostics of thyroid gland nodules. *Med Arch* 2013;67:198-201.