

[CASE REPORT]

Development of Pulmonary Arterial Hypertension in a Patient Treated with Qing-Dai (Chinese Herbal Medicine)

Kayo Misumi¹, Takeshi Ogo^{1,2}, Jin Ueda¹, Akihiro Tsuji¹, Sigefumi Fukui¹, Nao Konagai¹, Ryotaro Asano¹ and Satoshi Yasuda¹

Abstract:

Pulmonary arterial hypertension (PAH) is a rare, devastating disease, characterized by elevated pulmonary arterial pressure due to pulmonary microvascular obstruction, which can result in heart failure and death. PAH can be associated with exposure to certain drugs or toxins. We herein report a case in which PAH developed in a patient with refractory ulcerative colitis during treatment with “Qing-Dai,” a Chinese herbal medicine. The patient’s PAH improved after the discontinuation of Qing-Dai.

Key words: Qing-Dai, Chinese herbal medicine, pulmonary arterial hypertension, ulcerative colitis, drug-induced pulmonary arterial hypertension

(Intern Med 58: 395-399, 2019)

(DOI: 10.2169/internalmedicine.1523-18)

Introduction

Pulmonary arterial hypertension (PAH) is a rare devastating disease, characterized by elevated pulmonary arterial pressure and pulmonary vascular resistance due to pulmonary microvascular obstruction, which results in right ventricle failure and death if left untreated (1, 2). PAH is associated with certain drugs, such as appetite suppressants. These forms of PAH are categorized as drug-induced PAH (3).

“Qing-Dai,” a Chinese herbal medicine that includes natural indigo, has traditionally been used to treat ulcerative colitis (UC) (4). In Japan, Qing-Dai has also been empirically used to treat UC that is refractory to standard evidence-based UC treatment regimens, without scientific evidence or complication surveillance. Recent clinical studies have shown the benefit of Qing-Dai in the treatment of UC (5, 6). However, a possible link between Qing-Dai and PAH has drawn attention and concern (7). Two cases of pulmonary hypertension in association with Qing-Dai treatment were reported at the Japanese Pulmonary Circulation and Pulmonary Hypertension annual meeting in 2017 (8). Thus, the Japanese Ministry of Health, Labour and Welfare issued a public health warning regarding the possible causal link be-

tween Qing-Dai and PAH in 2016 (9). We herein report a case in which PAH developed in a patient with refractory UC during treatment with Qing-Dai, and improved after the discontinuation of Qing-Dai.

Case Report

The patient was a 59-year-old woman who had suffered from UC for 18 years. She had been treated with a number of standard and evidence-based treatments, including 5-aminosalicylates, predonema enema, infliximab, gemcitabine and leukocytapheresis, for 17 years. Because her UC was refractory to standard treatment, the patient had been treated with Qing-Dai, Chinese herbal medicine, as an off-label prescription, which she received from a clinic for UC. Notably, the patient’s UC improved during treatment with Qing-Dai. At 7 months before beginning Qing-Dai, the patient had no symptoms and electrocardiogram (normal axis deviation and no abnormal findings) and echocardiogram findings [normal right atrial and ventricular chamber size and normal trans-tricuspid pressure gradient (TRPG) of 22 mmHg] were normal (Fig. 1A, 2A and B). An echocardiogram obtained 18 months after Qing-Dai treatment showed a slight increase in the TRPG (28 mmHg). At 20 months of

¹Department of Cardiovascular Medicine, National Cerebral and Cardiovascular Center, Japan and ²Department of Advanced Medicine in Pulmonary Hypertension, National Cerebral and Cardiovascular Center, Japan

Received: May 13, 2018; Accepted: June 10, 2018; Advance Publication by J-STAGE: September 12, 2018

Correspondence to Dr. Takeshi Ogo, tak@ncvc.go.jp

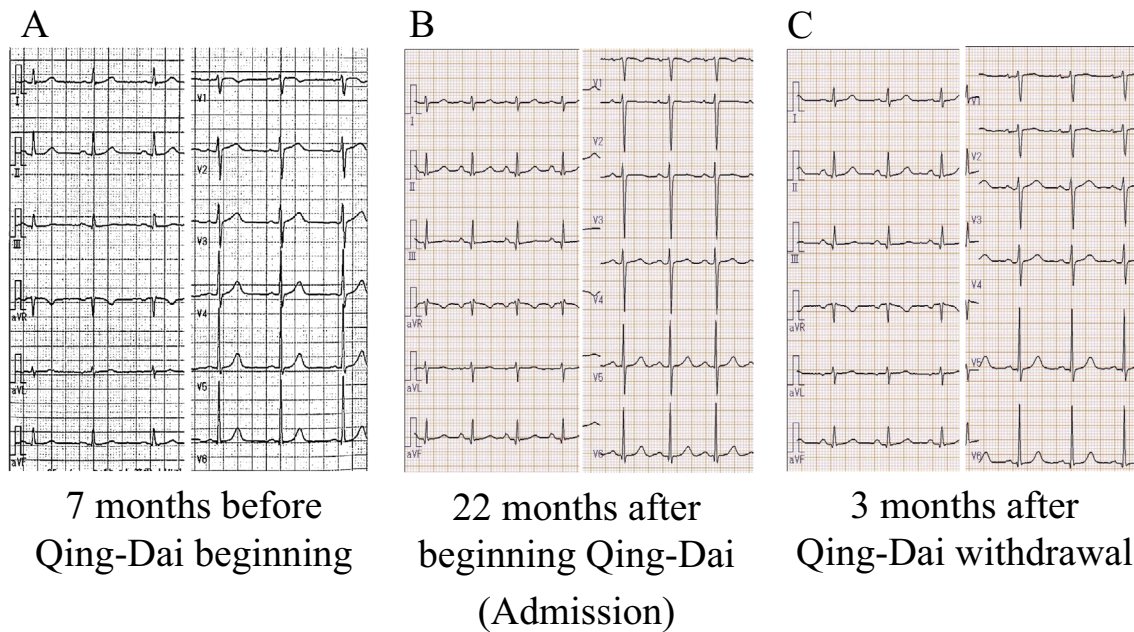


Figure 1. Electrocardiography before Qing-Dai treatment, on admission due to worsening pulmonary hypertension, and 3 months after the discontinuation of Qing-Dai. **A:** Electrocardiography 7 months before the initiation of Qing-Dai treatment showed a regular sinus rhythm with normal axis deviation. **B:** Right axis deviation on admission (22 months after the initiation of Qing-Dai treatment). **C:** Normal axis deviation at 3 months after the withdrawal of Qing-Dai.

Qing-Dai treatment, she experienced shortness of breath (World Health Organization functional class: WHO-FC II) and echocardiography showed a significant increase in the TRPG (45 mmHg). After 22 months of Qing-Dai treatment, her shortness of breath had worsened to WHO-FC III, and she was referred to our center due to suspected pulmonary hypertension (PH) (Fig. 3). There was no familial history of PAH and the only medication that the patient had been taking was Qing-Dai. A physical examination revealed the following findings: heart rate 92 beats/min and regular; blood pressure 131/70 mmHg; body temperature 37.0°C; and SpO₂ 99% on room air. On auscultation, acceleration of S₂ and pan-systolic murmur at the 4th left sternal border were audible; no rales were heard over the lungs. No leg edema was observed. Her serum brain natriuretic peptide (BNP) level was elevated to 118.9 pg/mL, while blood tests were negative for D-dimer. Human immunodeficiency virus testing revealed a negative result. Chest radiography showed mild pulmonary artery dilation and mild cardiomegaly with a cardiothoracic ratio of 51%. Electrocardiography showed right axis deviation (Fig. 1B). Echocardiography showed right atrial and ventricular dilation [right ventricular end-diastolic dimension (RVDD) 37 mm], and moderate tricuspid regurgitation, with an elevated TRPG of 85 mmHg and compression of the left ventricle [left ventricular ejection fraction 65%; LV deformity index (LVdef) 0.74] (Fig. 2C and D), without an intracardiac shunt. Pulmonary embolism was not detected on contrast computed tomography. Lung ventilation and perfusion scintigraphy revealed no evidence of ventilation perfusion mismatch. Her respiratory function was nor-

mal. Right heart catheterization showed pre-capillary PH [pulmonary arterial wedge pressure 3 mmHg; pulmonary arterial pressure (PAP) 54/20 mmHg; mean PAP 32 mmHg; pulmonary vascular resistance (PVR) 7.1 wood units; cardiac index (CI) 2.80 L/min/m² without O₂ step-up]. Her hepatic vein wedge pressure was not elevated (4 mmHg). Her six-minute walk distance was 475 meters. These check-ups for the diagnosis of PH could exclude World Health Organization classification groups 2-5. Underlying PAH-associated diseases, such as connective tissue disease, congenital heart disease, portal hypertension, schistosomiasis and HIV infection, were also excluded. We discontinued Qing-Dai on the first day of admission due to a possible causal link between Qing-Dai and PAH, after confirming that the patient's UC was stable and discussing the risk of UC deterioration with the patient and a gastroenterologist. In addition to the discontinuation of Qing-Dai, we prescribed PAH-specific medications, including an endothelin receptor antagonist (Macitentan: 10 mg/day), a phosphodiesterase-5 inhibitor (Tadalafil: 40 mg/day), and an oral long-acting prostacyclin analogue (Beraprost sodium: 180 µg/day), as initial oral triple combination therapy. At two weeks after the initiation of PAH-specific medication and the termination of the Qing-Dai therapy, we observed the improvement of right heart enlargement (RVDD 33 mm) and left ventricular deformity (LVdef 0.95), and the TRPG was 48 mmHg.

At 3 months after the discontinuation of Qing-Dai, the patient's shortness of breath disappeared and right heart catheterization data showed that the mean PAP had normalized (11 mmHg) and the CI improved from 2.8 to 5.35 L/

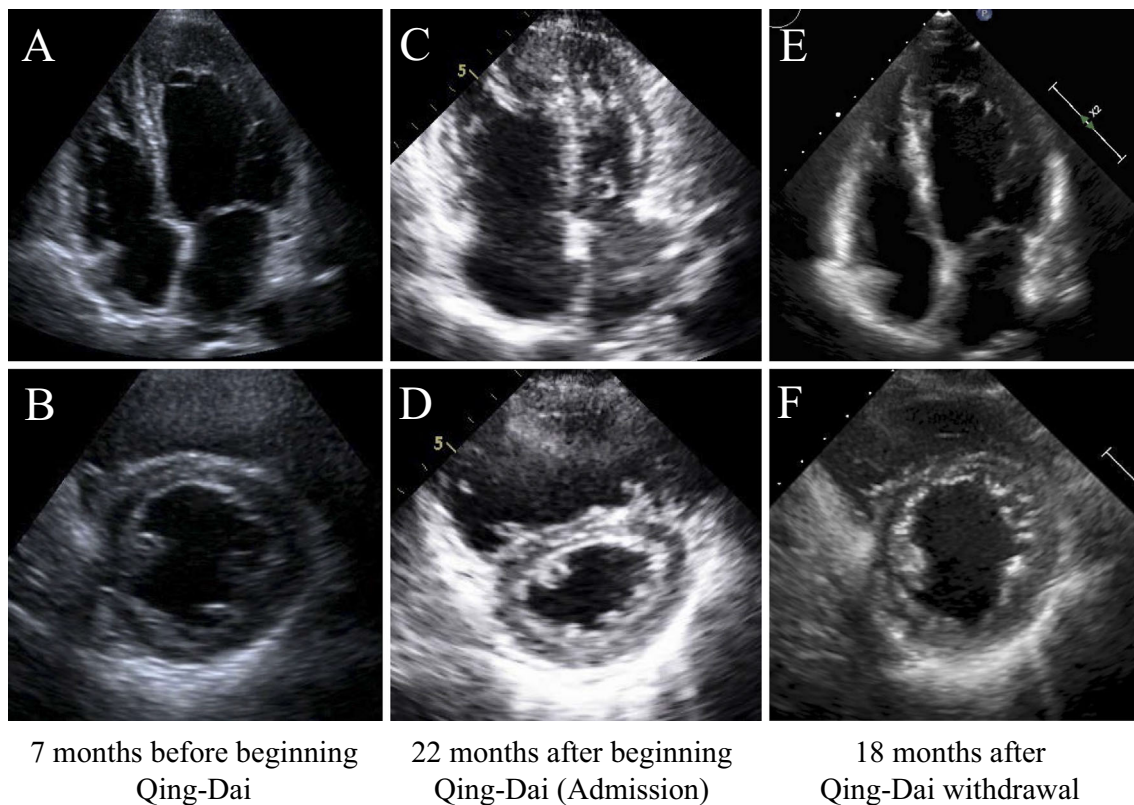


Figure 2. Echocardiography before Qing-Dai treatment, on admission due to worsening pulmonary hypertension, and 18 months after the discontinuation of Qing-Dai. A, B: The right atrial and ventricular chamber were of normal size and the trans-tricuspid pressure gradient was normal (22 mmHg) at 7 months before the initiation of Qing-Dai treatment. C, D: Right atrium and ventricular dilation, and deformity of the left ventricle on admission (22 months after the initiation of Qing-Dai treatment). E, F: Right atrial and ventricular dilation and deformity of the left ventricle disappeared at 18 months after the discontinuation of Qing-Dai and 6 months after the withdrawal of pulmonary hypertension-specific therapy.

min/m². The patient's serum BNP level decreased from 118.9 to 22.9 pg/mL. Chest radiography showed that the patient's cardiomegaly had improved with a cardiothoracic ratio of 47%. The patient's right axis deviation returned to normal on an electrocardiogram (Fig. 1C). Right ventricular dilatation (RVDd 27 mm) and her left ventricle compression (LVdef 0.88) was further improved on echocardiography. Her TRPG decreased from 48 mmHg to 25 mmHg.

Each PAH-specific medication was gradually withdrawn over the following 5 months. All PAH-specific medications were discontinued after an additional 7 months without a worsening of the patient's symptoms. At 3 months after the discontinuation of all PAH-specific medications, clinical and hemodynamic assessments showed WHO-FC I, low BNP (28.9 pg/mL), and no exercise intolerance (six-minute walk distance: 647 meters) (Table). Echocardiography showed a normal right ventricular chamber size (RVDd 22 mm) and no left ventricular compression (LVdef 0.97) with a TRPG in the normal range (23 mmHg) (Fig. 2E and F). A follow-up right heart catheter examination showed normal hemodynamics (mean PAP 12 mmHg; CI 3.03 L/min/m²; PVR 2 wood units). No deterioration in the patient's echocardiogram findings was observed at 28 months after the discon-

tinuation of Qing-Dai and 16 months after the discontinuation of all PAH medications (Fig. 3). The patient showed no recurrence of UC under treatment with mesalazine and prednisolone, even after the withdrawal of Qing-Dai.

Discussion

In the present case, the patient developed PAH after 22 months of treatment with Qing-Dai for refractory UC. The PAH was reversible after the discontinuation of Qing-Dai and the patient has been free from PH-specific medications for more than one year.

Recently, a case report suggested a possible association between the Chinese herbal drug, natural indigo, and PAH (7), and two cases of pulmonary hypertension in association with Qing-Dai treatment were reported at the Japanese Pulmonary Circulation and Pulmonary Hypertension annual meeting in 2017 (8). In a previous Chinese report, indirubin, which is an ingredient in Qing-Dai, was reported to be associated with the development of PAH in three patients undergoing leukemia treatment (10). This is the first case report to describe the detailed clinical course of a PH patient receiving Qing-Dai with serial data from electrocar-

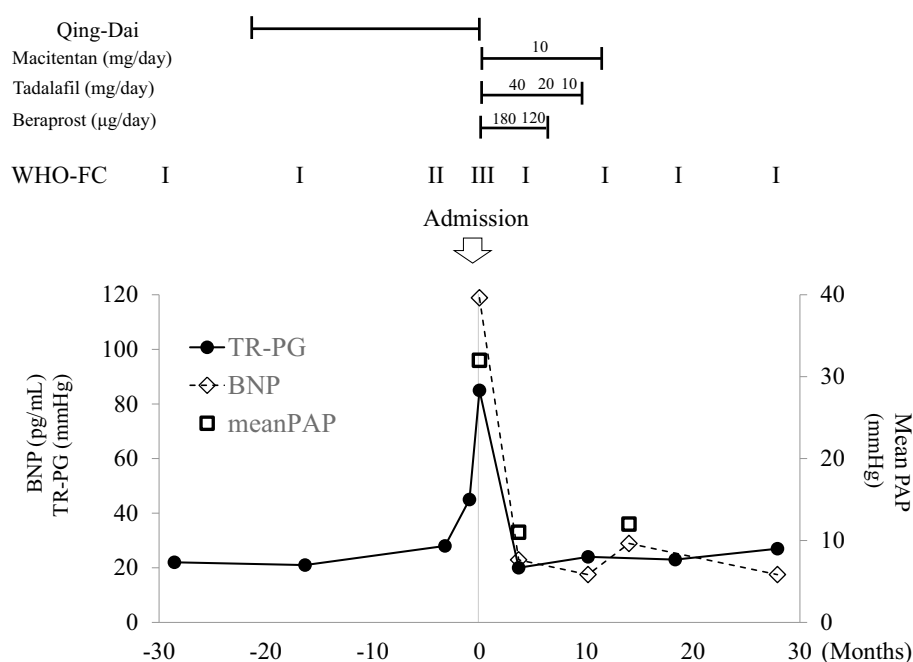


Figure 3. Treatments and changes in clinical parameters. No symptoms or signs of pulmonary hypertension were observed before Qing-Dai treatment. PAH developed at 20 months after the initiation of Qing-Dai treatment. The improved after the withdrawal of Qing-Dai and PAH-specific treatment. No clinical deterioration was found at more than 1 year after the discontinuation of Qing-Dai and the patient was free from PAH-specific medications.

Table. Changes in Clinical and Hemodynamic Parameter after the Admission.

Months after the admission	0	3	14
Qing-Dai	+	-	-
PH specific drugs	-	Macitentan 10 mg/day Tadalafil 40 mg/day Beraprost 180 μg/day	-
WHO-FC	III	I	I
6MWD (m)	475	660	647
BNP (pg/mL)	118.9	22.9	28.9
RAP (mmHg)	2	1	1
Mean PAP (mmHg)	32	11	12
PAWP (mmHg)	3	3	3
CI (L/min/m ²)	2.8	5.35	3.03
PVR (wood unit)	7.1	1.02	2

PH: pulmonary hypertension, WHO-FC: World Health Organization functional class, 6MWD: six-minute-walk distance, BNP: brain natriuretic peptide, RAP: right atrial pressure, PAP: pulmonary arterial pressure, PAWP: pulmonary arterial wedge pressure, CI: cardiac index, PVR: pulmonary vascular resistance

diography, echocardiography and right heart catheterization. This may support a potential association between Qing-Dai treatment and pulmonary hypertension.

The mechanisms underlying the development of Qing-Dai-associated PH are unknown since Chinese herbal medicine often includes many molecules. The leading components in Qing-Dai are indigo and indirubin (11). The molecular structure of indigo carmine resembles two molecules of serotonin (5-HT), arranged as mirror images of each other (12). Serotonin is a pulmonary vasoconstrictor that can

promote PAH, and is a well-known anorexic agent (13). One possible mechanism underlying the development of PAH in patients treated with Qing-Dai may be that indigo mimics the structure of serotonin, which may act as pulmonary vasoconstrictor. It has also been pointed out that indigo and indirubin are potent aryl hydrocarbon receptor (AhR) ligands, which is another possible explanation (14). Vascular endothelial growth factor (VEGF) inhibitor, which is a well-known trigger in a rat model of PAH (15), is also a ligand of AhR (16). Moreover, indirubin inhibits BMP signal-

ing (17), which is a widely known underlying mechanism of heritable PAH with BMP signal mutations, as well as other forms of PAH.

In the present case, it should be also noted that PAH may be reversible after the discontinuation of Qing-Dai. The development of PAH after 22 months of Qing-Dai treatment, and subsequent recovery from PAH after the withdrawal of Qing-Dai, indicate a potential association between Qing-Dai and PAH. Moreover, this case suggests that the discontinuation of Qing-Dai is the most important aspect of management for Qing-Dai-induced PAH, since PAH did not recur even after PAH-specific medication was discontinued. The further accumulation of cases and data is needed for the management of patients who develop PAH in association with Qing-Dai treatment. Currently, routine PAH screening should be considered during Qing-Dai treatment. Large multi-center surveillance is needed to confirm and investigate the clinical course and management of Qing-Dai-associated PAH.

The authors state that they have no Conflict of Interest (COI).

References

1. Hoepfer MM, Bogaard HJ, Condliffe R, et al. Definitions and diagnosis of pulmonary hypertension. *J Am Coll Cardiol* **62**: D42-D50, 2013.
2. Galie N, Humbert M, Vachiery JL, et al. 2015 ESC/ERS Guidelines for the diagnosis and treatment of pulmonary hypertension: The Joint Task Force for the Diagnosis and Treatment of Pulmonary Hypertension of the European Society of Cardiology (ESC) and the European Respiratory Society (ERS): Endorsed by: Association for European Paediatric and Congenital Cardiology (AEPC), International Society for Heart and Lung Transplantation (ISHLT). *Eur Heart J* **37**: 67-119, 2016.
3. Simonneau G, Gatzoulis MA, Adatia I, et al. Updated clinical classification of pulmonary hypertension (vol 62, pg D34, 2013). *J Am Coll Cardiol* **63**: 746-746, 2014.
4. Fukunaga K, Hida N, Ohnishi K, et al. A suppository Chinese medicine (xilei-san) for refractory ulcerative proctitis: a pilot clinical trial. *Digestion* **75**: 146-147, 2007.
5. Suzuki H, Kaneko T, Mizokami Y, et al. Therapeutic efficacy of the Qing Dai in patients with intractable ulcerative colitis. *World J Gastroenterol* **19**: 2718-2722, 2013.
6. Naganuma M, Sugimoto S, Mitsuyama K, et al. Efficacy of indigo naturalis in a multicenter randomized controlled trial of patients with ulcerative colitis. *Gastroenterology* **154**: 935-947, 2018.
7. Nishio M, Hirooka K, Doi Y. Chinese herbal drug natural indigo may cause pulmonary artery hypertension. *Eur Heart J* **37**: 1992, 2016.
8. Nakayama N, Komura N, Sugano T, et al. Japanese Pulmonary Circulation and Pulmonary Hypertension annual meeting, Japan, 2017. Available from: <http://jpcphs.org/meeting/pdf/jpcphs2017.pdf> (Abstract in Japanese).
9. Ministry of Health, Labour and Welfare, Japan, 2016. Available from: <http://www.mhlw.go.jp/file/06-Seisakujouhou-11130500-Shokuhinanzendu/0000147453.pdf> (in Japanese).
10. Jiang SZ. Adverse effects of indirubin on cardiovascular system. *Chinese J Hematol* **7**: 30, 1986 (in Chinese).
11. Damiens E, Baratte B, Marie D, Eisenbrand G, Meijer L. Antimitotic properties of indirubin-3'-monoxime, a CDK/GSK-3 inhibitor: induction of endoreplication following prophase arrest. *Oncogene* **20**: 3786-3797, 2001.
12. Erickson JC 3rd, Lauron F. Vasopressor effect of indigo carmine. A preliminary report. *Guthrie Clin Bull* **30**: 30-35, 1960.
13. Abenhaim L, Moride Y, Brenot F, et al. Appetite-suppressant drugs and the risk of primary pulmonary hypertension. International Primary Pulmonary Hypertension Study Group. *N Engl J Med* **335**: 609-616, 1996.
14. Kawai S, Iijima H, Shinzaki S, et al. Indigo Naturalis ameliorates murine dextran sodium sulfate-induced colitis via aryl hydrocarbon receptor activation. *J Gastroenterol* **52**: 904-919, 2017.
15. Abe K, Toba M, Alzoubi A, et al. Formation of plexiform lesions in experimental severe pulmonary arterial hypertension. *Circulation* **121**: 2747-2754, 2010.
16. Mezrich JD, Nguyen LP, Kennedy G, et al. SU5416, a VEGF receptor inhibitor and ligand of the AHR, represents a new alternative for immunomodulation. *PLoS One* **7**: e44547, 2012.
17. Cheng X, Alborzinia H, Merz KH, et al. Indirubin derivatives modulate TGFbeta/BMP signaling at different levels and trigger ubiquitin-mediated depletion of nonactivated R-Smads. *Chem Biol* **19**: 1423-1436, 2012.

The Internal Medicine is an Open Access journal distributed under the Creative Commons Attribution-NonCommercial-NoDerivatives 4.0 International License. To view the details of this license, please visit (<https://creativecommons.org/licenses/by-nc-nd/4.0/>).