

Recovery from acute pediatric complex regional pain syndrome type I after ankle sprain by early pharmacological and physical therapies in primary care: a case report

Yuzuru Takahashi
Takuya Tominaga
Kohei Okawa
Kohei Tanaka

Sannoh Orthopedic Clinic, Pain Clinic
and Rehabilitation for Musculoskeletal
Disorders, Sannoh Hospital, Chiba,
Japan

Background: Complex regional pain syndrome type I (CRPS I) in children is a serious condition disrupting the family and school life of patients with the condition after it fully develops. It has been emphasized that early diagnosis is closely associated with earlier reduction of pain leading to preferable outcomes.

Objectives: To report a case of acute CRPS I in a boy who was found to develop this condition by a routine visual analog scale (VAS) pain monitoring and who recovered from CRPS I at an early phase by prompt pharmacological, physical, and educational therapies.

Study design: Case report.

Case report: A 12-year-old boy sprained his left ankle while playing soccer and was referred to our clinic 4 days after the injury. At the first visit, he could walk, reporting motion pain with a VAS scale of 80 mm. On day 5, pain intensity increased to 100 mm, and a diagnosis of acute CRPS I was made. On day 7, he could not move the injured ankle; therefore celecoxib and pregabalin were administered, and physical and educational therapies started. On day 35, pain intensity was 0 mm and he could walk and run normally.

Conclusion: Routine monitoring of VAS for every patient in pain is useful to discover an abnormal transition of VAS, enabling the early diagnosis of CRPS I. Inflammation and peripheral or central sensitization are postulated for early development of CRPS I. The present case suggested a combination of physical therapy and pharmacological intervention with celecoxib and pregabalin reduced peripheral and central sensitization.

Keywords: pediatric complex regional pain syndrome type I, pediatric CRPS I, ankle sprain, visual analog scale, VAS, nonsteroidal anti-inflammatory drug, NSAID, pregabalin, physical treatment, educational therapy

Introduction

Complex regional pain syndrome (CRPS) is an intractable painful condition resistant to various therapies. Two types of CRPS are recognized, CRPS type-I (CRPS I), which arises after minor injuries or without any preceding events, and CRPS type II (CRPS II), which arises after direct severe trauma to the peripheral or central nervous systems. CRPS I often arises after injuries in the distal limb.¹ Primary physicians see patients in early phases of CRPS I as it begins with common minor injuries. Most studies of the treatment of CRPS I have been reported by specialized pain clinicians while their patients are in a chronic phase of the disease. Patients who are diagnosed with CRPS I by primary physicians are referred to specialized institutions after some time from

Correspondence: Yuzuru Takahashi
Sannoh Orthopedic Clinic, 160-1
Sannoh-cho, Inage-ku, Chiba City, Chiba
263-0002, Japan
Tel +81 422 1011
Fax +81 422 1700
Email yzrtaka@nifty.com

the onset; meanwhile the serious condition of CRPS I may have already developed. It has been emphasized that early interventions for CRPS I lead to a preferable outcome.^{2,3} We consider it is important for primary physicians to be aware of the onset of CRPS I in its acute phase.

Pediatric CRPS I has a more favorable outcome than adult CRPS I.⁴⁻⁶ Early and prompt diagnosis of CRPS I leads to a quicker and more favorable outcome in children.^{2,4,6} However, pediatric CRPS I can be accompanied by serious disruptions to family and school life^{5,7,8} and occasionally leads to subsequent psychosocial problems.⁸ Pediatric CRPS I has several notable features: it is prevalent in girls around the age of 12 and occurs in the lower limbs^{2,5,6} with a tendency to occur after ankle sprain.¹ It is not impossible to prevent the onset or development of CRPS I in primary care with the awareness of these features.²

We report a case of CRPS I in a 12-year-old boy who presented with typical signs, but was completely cured within 5 weeks with early pharmacological, physical, and educational therapies. An abnormal clinical course of his ankle sprain pain intensity was discovered by routine recording of pain intensity that is used for every patient with pain in our clinic. Here we describe the clinical importance of awareness of CRPS I at an early phase that can be achieved by routine recording of pain intensity using a visual analog scale (VAS) for every patient with pain.

The patient and his parent gave their written informed consent to publish the episode and clinical data in medical journals. Clinical data from 18 other patients with ankle sprain who visited our clinic were cited following National guidelines for clinical studies from the Ministry of Health, Labor and Welfare in Japan, which does not demand written informed consent from patients for presenting measured values obtained using noninvasive methods such as VAS.

A new monitoring system for VAS score

At our clinic, patients are routinely asked about their pain intensity at every visit. Patients demonstrate their pain intensity using *SuperVAS* before a physician's examination. *SuperVAS* is a system for recording and displaying VAS scores that was developed independently by our clinic. *SuperVAS* comprises a touch panel for recording VAS score, a wireless local area network, and a monitor display to present the VAS score in a dispensary room and rehabilitation room. The touch panel displays two 100 mm horizontal bars to indicate pain intensity at rest and in motion. The patient and the physician can see the VAS score history together on a display monitor. A detailed description of the system including its specifications

is described elsewhere.^{9,10} Abnormal progress of pain intensity deviating from a normal course can be easily discovered from a graph of the VAS score history.

Case report

A 12-year-old boy sprained his left ankle by forced inversion while playing soccer. He and his mother were referred to our clinic 2 days after the injury. No issues were noted in his family history, developmental history, or psychological conditions. He was a right-handed active Japanese boy with normal physical development, 140 cm tall, weighing 31 kg. He suffered from the same left ankle sprain 3 months before the present injury, although he recovered completely within a few days at that time.

At the first visit, he could walk using his left foot, reporting pain in the lateral aspect of the ankle during motion at an intensity of 85 mm on a 100 mm VAS. X-ray images showed no abnormal changes in the ankle joint or surrounding bones. An analgesic poultice was prescribed and he was allowed to walk with the diagnosis of a grade-1 ankle sprain. Running, sports, and physical activity were prohibited and the patient was requested to revisit 1 week later. Two days after the first examination the patient visited again, reporting increasing pain with a 94 mm VAS score. The painful area had expanded to the entire foot. He could not bear weight on his left foot with allodynia and hyperpathia in the sole. These were obviously unusual signs for a grade-1 ankle sprain. A supporting band was worn and non-weight-bearing ambulation using a pair of crutches was instructed by a physical therapist. Oral acetaminophen (400 mg/day) was prescribed, but was ineffective. On the fifth day, VAS score increased to 100 mm both in motion and at rest. Intense allodynia and mild edema were observed in the entire foot. The patient reported difficulty standing on his left foot because of fear of evoking pain induced by touching his foot on the floor. Subcutaneous bleeding suggestive of underlying ligamentous ruptures was not seen anywhere in the foot. CT performed to detect deep injuries, such as bone contusions, revealed normal findings in bony structures and soft tissues. Trophic and thermal changes were unclear. A diagnosis of CRPS I was made, being compatible with items 2 (motor dysfunction), 3 (abnormal pain processing), and 5 (asymmetric edema) of the Japanese Clinical Diagnostic Criteria of the Japanese CRPS I Research Group (Table 1).¹¹ Celecoxib (100 mg/day) and pregabalin (25 mg/day) tablets were prescribed to alleviate the symptoms suggestive of inflammatory and sensitized conditions. Physical treatments including assisted active and passive range of motion (ROM) exercise and ice-massage, hot packs, and gradual weight

Table 1 Japanese CRPS I diagnostic criteria for clinical purposes

- A.1.** Must report at least one symptom in two or more of the following five categories, at some time.
1. Trophic changes: reports of trophic changes of hair and/or skin and/or nail and/or bone.
 2. Motor dysfunctions: reports of decreased range of motion and/or motor dysfunction (muscle weakness, tremor, dystonia).
 3. Abnormal sensory processing: reports of pain disproportionate to the inciting event and/or burning pain and/or hyperesthesia.
 4. Asymmetric sudomotor activity: reports of sweating changes and/or sweating asymmetry.
 5. Asymmetric edema: reports of edema.
- A.2.** Must display at least one sign in two or more of the five following categories, at the physical examination.
1. Trophic changes: evidence of trophic changes of hair and/or skin and/or nail and/or bone.
 2. Motor dysfunctions: evidence of decreased range of motion and/or motor dysfunction (muscle weakness, tremor, dystonia).
 3. Abnormal sensory processing: evidence of hyperalgesia (to pinprick) and/or allodynia (to light touch).
 4. Asymmetric sudomotor activity: evidence of sweating changes and/or sweating asymmetry.
 5. Asymmetric edema: evidence of edema.

Note: Sumitani M, Shibata M, Sakaue G, Mashimo T; Japanese Complex Regional Pain Syndrome Research Group. Development of comprehensive diagnostic criteria for complex regional pain syndrome in the Japanese population. *Pain*. 2010;150(2):243–249; <https://www.ncbi.nlm.nih.gov/pubmed/20451323>.¹¹

Abbreviation: CRPS I, complex regional pain syndrome type I.

bearing were started to obtain graded desensitization. These physical treatments lasting 20 minutes in each session were conducted once a day and were continued until the final visit. The physician and physical therapists instructed the patient and his mother in CRPS I and the validity of the treatments at every visit. On the 11th day, VAS score for pain during motion was reduced to 53 mm and the patient was able to move his ankle and touch the sole of his foot on the floor. On the 22nd day, VAS was remarkably reduced to 2 mm and allodynia and edema were completely gone. The administration of celecoxib and pregabalin was terminated. On the 35th day, he reported no pain. He could walk naturally, run, and jump with the injured foot. Therefore, outpatient care was discontinued. No recurrent events have occurred for 2 years after the final visit to date. Thus, he recovered from acute CRPS I in its early phases.

Figure 1 shows the transitions of VAS scores and treatment modalities.

Comparison with other young patients with normal ankle sprain

Figure 2 shows the transitions of VAS scores for pain during motion for 18 pediatric patients in our clinic who suffered unilateral ankle sprain without resulting CRPS I in the 5 years since the inception of the clinic (Table 2). Normal patients reported an early and rapid reduction of VAS scores that reached a remission level (VAS < 30 mm). By contrast, the present patient showed an increase in VAS score at the second and third visits. Ultimately, the patient recovered within a similar period as the other normal patients with ankle sprain.

Discussion

Features of pediatric CRPS I

Pediatric CRPS I occurs frequently in girls, around the age of 12 or 13 years, after minor injuries of lower limbs with

a predisposition for the foot and ankle.^{2,5–7,12,13} Symptoms include severe pain disproportionate to the inciting injury, allodynia, hyperpathia, edema, occasionally paralysis and occasionally involuntary movements as in the adult CRPS I. Psychological or familial backgrounds are associated with the development of pediatric CRPS I.^{14–17}

Early detection of CRPS I by VAS monitoring

The prognosis of CRPS I is better with an earlier than a later diagnosis.^{6,18} Early diagnosis and treatments are pivotal for children, leading to complete recovery.^{4,6,19} Early treatments increase the thickness of the brain cortex in pediatric patients with CRPS I, suggestive of an active neural plasticity in children.²⁰ This phenomenon may be related to either development or improvement in pediatric CRPS I with early active treatments.

Primary physicians see patients from the start of their disease, and therefore play an important role in preventing the development of CRPS I. Primary physicians should remember specific features of pediatric CRPS I such as sex (female), age (around 12 years), injured site (lower limb), and side (left) indicated by the present study, and psychological, developmental, and familial issues. However, these features are not exclusive to CRPS I, which has a very low incidence. Although historical problems may be revealed by meticulous inquiry or specialized questionnaires,¹⁴ conducting them routinely for all patients may not be feasible in primary medicine.

Every patient in our clinic is routinely asked about pain intensity using the *SuperVAS* system. Almost all patients can understand the concept of VAS score and the purpose of VAS score monitoring, and are therefore compliant in recording VAS score on the touch panel. Our clinic succeeds in routine VAS monitoring of most pediatric patients over 6 years old.

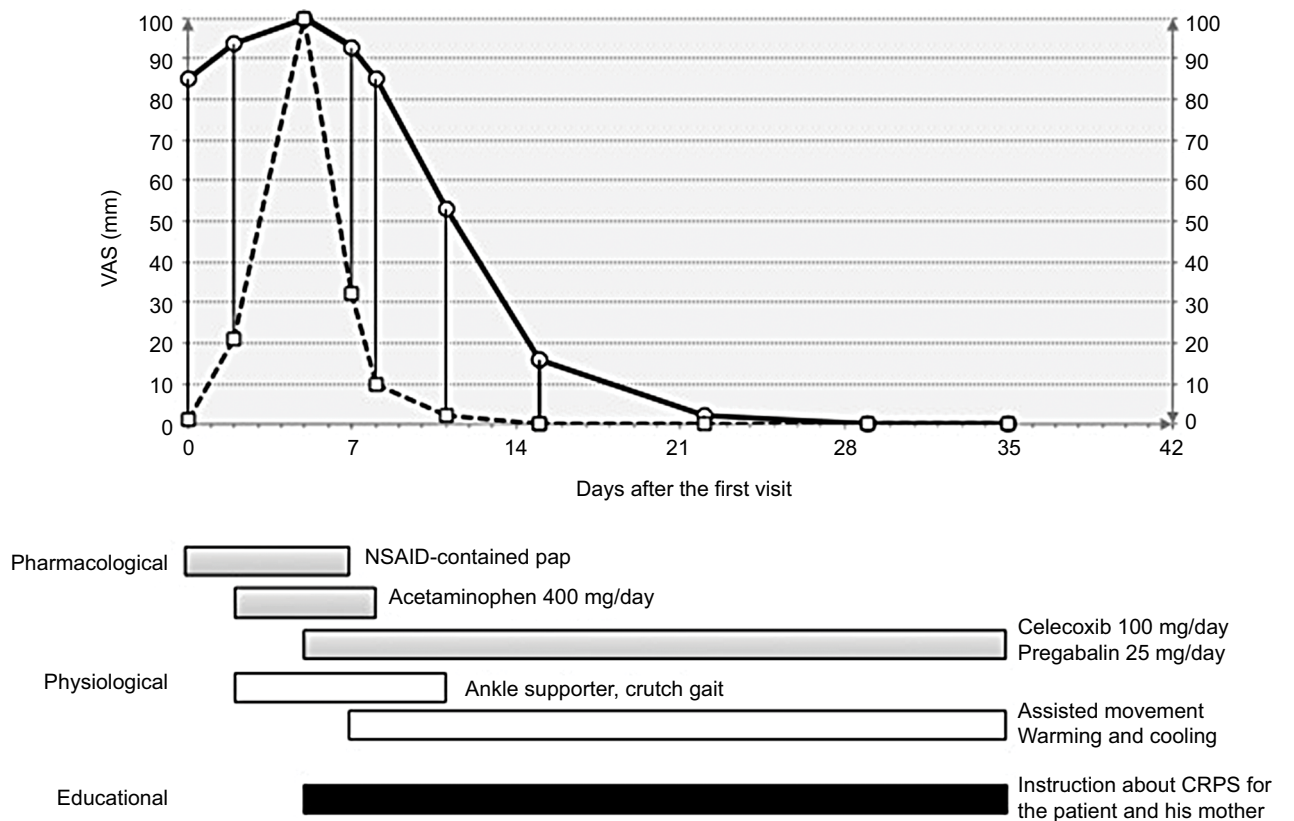


Figure 1 The VAS graph on the *SuperVAS* display monitor of the present patient showing the transition of the pain intensities experienced during motion (circles and solid line) and during rest (squares and hashed lines). Treatments are represented below the graph as horizontal bars.

Notes: The VAS score of pain during motion increased from 85 to 100 mm after the first visit until day 5. The VAS score of pain during rest also increased to 100 mm at day 5. The VAS score began to decrease after pharmacotherapy with celecoxib and pregabalin, and physical and educational therapies.

Abbreviations: VAS, visual analog scale; CRPS I, complex regional pain syndrome type I; NSAID, nonsteroidal anti-inflammatory drug.

A substantial amount of VAS data has been accumulated for various musculoskeletal painful diseases including ankle sprain. An abnormal transition of VAS score deviating from the normal pattern of a disease can be quickly discovered from the graph of VAS score history on the display monitor in the examination room. We found an abnormal transition of the present patient's VAS score before examination on their second visit. The routine monitoring of pain intensity is an important and useful tool to discover the onset of CRPS I in primary medicine. *SuperVAS* or the routine monitoring of VAS score is advocated for primary physicians who see patients with pain.

Inflammation and sensitization

Inflammation and enhanced sensitivity in the sensory nervous system may play a pivotal role in the initiation of CRPS I in early phases after injury.^{18,21,22} Inflammation and peripheral sensitization per se are normal pathological reactions for healing of damaged tissues. Peripheral sensitization is generated at the nerve terminal of nociceptive fibers as an inflammatory reaction. Signals initiated by mechanical and

chemical nociceptors are enhanced by the binding of prostaglandin to its receptors at the nerve terminal. Pain because of inflammation and peripheral sensitization is necessary for wound healing. Inflammatory pain is adaptive and not a serious problem when it is balanced with the inciting injury and settled in an appropriate period. Sympathetic vasomotor phenomena such as edema and hypo or hyperthermia can also be regarded as normal reactions for healing.

Severe pain, hyperpathia, allodynia, edema, and vasomotor changes as found in CRPS I are common in early phases of severe injuries, suggesting that these symptoms and signs per se should not be considered as abnormal. CRPS I is a condition where symptoms and signs of inflammation, sensory sensitization, and sympathetic reactions are abnormally exaggerated in strength, enlarged spatially, and elongated chronologically. Neurogenic inflammation has been speculated to play a role in early phases of CRPS I.²³ Increased local levels of proinflammatory cytokines were demonstrated from blister fluids of the wrist and ankle of adult patients with acute CRPS I.^{21,22} Inflammatory profiles

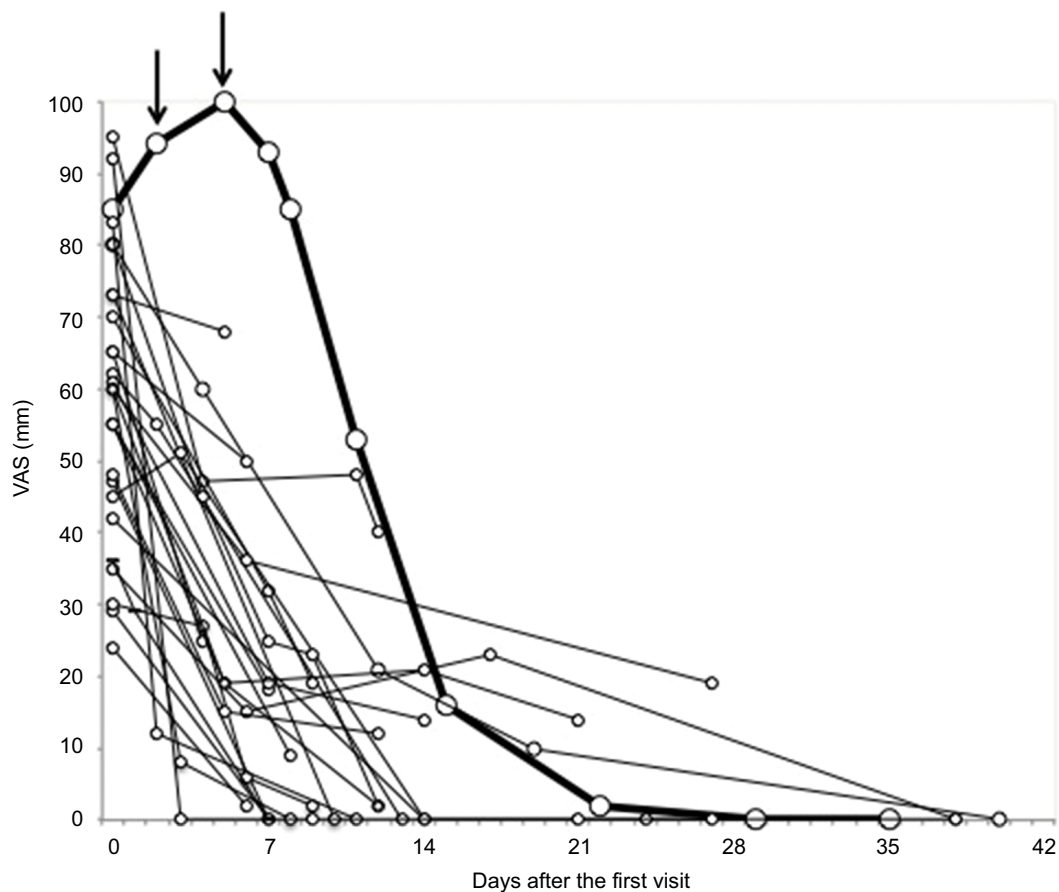


Figure 2 A graph showing the history of VAS score of pain during motion of the present patient (thick line) and 18 pediatric patients with ankle sprain in our clinic who presented a standard clinical course (thin lines).

Notes: The unique difference is apparent for the present patient in the transition of VAS score in that he showed an increase (arrows) in the second and third visit within a week after the first visit, while other patients showed a marked early decrease in their VAS score.

Abbreviation: VAS, visual analog scale.

Table 2 Young patients with ankle sprain within the past 5 years in our clinic (N=18)

Age	Mean: 12.5 years, range 9–15 years.
Sex	Male:female =9:9
Injured side	Right:left =12:6

differ between acute and chronic phases of CRPS I.²¹ CRPS I can be regarded as a condition in which silencing of early inflammatory reactions fails. Corticosteroids^{18,21,24–26} and nonsteroidal anti-inflammatory drugs (NSAIDs)²⁷ successfully improve pediatric CRPS I. NSAIDs are administered to children with CRPS I before invasive management.⁴

Sensitization of the nociceptive system is a potent mechanism for CRPS I.²⁸ Sensitization is induced at various sites in the sensory nervous system. Sensitization concerning primary afferent fibers occurs peripherally at the nerve endings in damaged tissues and occurs centrally at the projection

field of the dorsal horn of the spinal cord.²⁸ Prostaglandin from inflammatory cells enhances afferent impulses from nociceptors. NSAIDs inhibit the generation of prostaglandin from arachidonic acid. Thus, NSAIDs act as inhibitors of peripheral sensitization. Central sensitization is associated with spatial enlargement of painful areas.²⁹ Pregabalin acts as an inhibitor of central sensitization by blocking calcium channels on nociceptive fibers in the dorsal horn of the spinal cord. NSAIDs and pregabalin reduce hyperactivity of primary nociceptive fibers peripherally and centrally. NSAIDs²⁷ and pregabalin^{7,30} have been administered to children with CRPS I.

Oral analgesics are not needed for pediatric patients with normal ankle sprain in our clinic. The present patient reported aggravation of symptoms and an abnormal increase in VAS value at the second visit, 2 days after his first visit. At that time, acetaminophen was administered, but was revealed as ineffective on the next visit 3 days later. We administered

celecoxib and pregabalin to the patient with the consideration of the pathophysiology of acute CRPS I. The patient recovered after taking celecoxib and pregabalin, suggesting that these drugs successfully impaired sensitization in the early phase of CRPS I.

Physical therapy

Treatment with intensive physical therapy is recommended for patients with CRPS I, in particular for children.^{1,12} Various therapeutic techniques such as assisted ROM exercise,¹ joint mobilization,^{1,12,31} stretching,^{1,8,31} strain and counterstrain,^{8,31} gradual weight bearing, gait training,⁸ massage,¹² heating and cooling (contrast bath),^{27,31} and transcutaneous electrical stimulation³¹ have been performed for pediatric CRPS I. However, no technique has shown superiority over the others. The specific therapy sessions were not standardized and were variable.¹² Specific selection of these techniques for each patient has not been fully clarified. Pain relief mechanisms underlying physical treatments are unclear and are not associated with inflammation or peripheral and central neuronal mechanisms.

Pain related fear³² can underlie the deterioration and chronicity of pain in children. We kept in mind not to induce pain that may evoke pain-related fear and to promote self-confidence so that the patient could stand and walk without pain during physical therapy. In particular, we endeavored to effect gentle maneuvers. For the present patient, we conducted assisted active and ROM exercise, ice massage, hot packs, and gradual weight bearing for the purpose of grading desensitization. Some or all of these treatments might have attenuated the development of central sensitization in our patient.

Educational therapy

We conducted educational therapy concurrently in the outpatient examination room and in the physical therapy sessions. We instructed the patient and his mother in the entity and pathophysiology of CRPS I and the effectiveness of pharmacological and physical therapies, showing illustrations depicting the mechanism of pain and providing published medical articles about pediatric CRPS I. With these educational interventions and a graph of his *SuperVAS* score history, the patient and his mother understood the abnormal transition of ankle sprain, and they could accept the diagnosis of CRPS I and pharmacological (NSAIDs and pregabalin) treatments, which are unusual for children with normal ankle sprain. We felt the educational therapy was an indispensable factor for the successful outcome in the present patient.

Deviation in laterality

Ankle sprain is the most common injury in active children and young adults.¹ Ankle sprain may be expected to arise symmetrically considering its causative traumatic events in sports and daily living. However, the injured side was 12 on the right and six on the left among 18 pediatric patients with ankle sprain in our clinic (Table 2). This suggests a double dominance for the right side in normal ankle sprain. Ankle sprain may be prone to be on the right, dominant side. By contrast, reported pediatric CRPS I after ankle sprain predominated in the left side across different ethnic groups (Table 3). The reason underlying the high frequency of the left, nondominant side is unknown. The central sensory system of the nondominant side, ie, the right brain, may be less developed and predisposed to dysfunction such as CRPS I in children. Further studies of this issue in the study of CRPS I are warranted.

Conclusion

The onset of acute CRPS I after ankle sprain can be revealed by data from routine VAS score monitoring of every patient with pain. Symptoms and signs of CRPS I may be reduced by early pharmacological intervention with celecoxib and pregabalin suggesting that inflammation and peripheral and central

Table 3 Reported cases of pediatric (age ≤16 years old) CRPS I after ankle sprain

Authors	Pub. year	Country	Age ^a	Sex	Laterality
Frost ³⁰	2003	USA	10	F	Left
Walia et al ¹	2004	USA	13	M	Left
Darure et al ³³	2005	France	15	Not noted	Left
			13	Not noted	Left
			13	Not noted	Right
			12	Not noted	Left
			13	Not noted	Right
			16	Not noted	Left
			13	Not noted	Left
			15	Not noted	Right
Collins ⁸	2007	USA	13	M	Left
Harada et al ³⁴	2007	Japan	14	F	Left
Pearson and Bailey ¹⁵	2011	USA	8	F	Left
Kato et al ²⁹	2011	Japan	9	F	Left
Gokan et al ³⁵	2013	Japan	9	F	Left
Kojima et al ³⁶	2013	Japan	10	M	Left
Chiba et al ¹⁷	2014	Japan	9	F	Left
Ushida et al ¹⁶	2014	Japan	9	F	Left
Demirdal et al ³¹	2014	Turkey	10	M	Left
Takahashi et al (present study)	2018	Japan	12	M	Left

Note: ^aAge, age at injury.

Abbreviation: CRPS I, complex regional pain syndrome type I.

sensitization promote the development of acute CRPS I. We consider that the combined early pharmacological, physical, and educational therapies in the initial phase of acute CRPS I resulted in early recovery from the development of acute CRPS I in the present patient.

CRPS I may be prevented in its early phase in primary clinics by knowledge of this disease entity and routine monitoring of pain intensity.

Author contributions

All authors participated in the treatment of the present patient. Dr Y Takahashi (MD) conducted the medical and radiological examinations, decision making in the diagnosis of CRPS I, and pharmacological treatments and directed educational therapies. T. Tominaga (main therapist), K. Okawa, K. Tanaka conducted physical and educational treatments. All authors contributed to drafting or critical revision of the manuscript, or both, and approved the final version and took responsibility for its content. All authors contributed toward data analysis, drafting and revising the paper and agree to be accountable for all aspects of the work.

Disclosure

The authors report no conflicts of interest in this work.

References

- Walia KS, Muser DE, Raza SS, Griech T, Khan YN. A management of early CRPS I caused by ankle sprain: a case report. *Pain Pract*. 2004;4(4):303–306.
- Kachko L, Efrat R, Ben Ami S, Mukamel M, Katz J. Complex regional pain syndromes in children and adolescents. *Pediatr Int*. 2008;50(4):523–527.
- Pandita M, Arfath U. Complex regional pain syndrome of the knee – a case report. *BMC Sports Sci Med Rehabil*. 2013;5:12.
- Rodriguez MJ, Fernandez-Baena M, Barroso A, Yanez JA. Invasive management for pediatric complex regional pain syndrome: literature review of evidence. *Pain Physician*. 2015;18:621–630.
- Weissmann R, Uziel Y. Pediatric complex regional pain syndrome: a review. *Pediatr Rheumatol Online J*. 2016;14(1):29.
- Low AK, Ward K, Wines AP. Pediatric complex regional pain syndrome. *J Pediatr Orthop*. 2007;27(5):567–572.
- Abu-Arafah H, Abu-Arafah I. Complex regional pain syndrome in children: incidence and clinical characteristics. *Arch Dis Child*. 2016;101(8):719–723.
- Collins CK. Physical therapy management of complex regional pain syndrome I in a 14-year-old patient using strain counterstrain: a case report. *J Man Manip Ther*. 2007;15(1):25–41.
- Takahashi Y. Effect on pain with elcatonin or teriparatide for the osteoporotic vertebral fracture based on the analysis of multiple VAS data. *J Jpn Osteopor Soc*. 2015;1(1):49–55.
- Takahashi Y. Conditions of chronic low back pain in primary medicine: analysis with the serial VAS displaying system. *Seikeigeka*. 2015;66(1):43–49.
- Sumitani M, Shibata M, Sakaue G, Mashimo T; Japanese Complex Regional Pain Syndrome Research Group. Development of comprehensive diagnostic criteria for complex regional pain syndrome in the Japanese population. *Pain*. 2010;150(2):243–249.
- Dietz FR, Compton SP. Outcomes of a simple treatment for complex regional pain syndrome type I in children. *Iowa Orthop J*. 2015;35:175–180.
- Tan EC, Zijlstra B, Essink ML, Goris RJ, Severijnen RS. Complex regional pain syndrome type I in children. *Acta Paediatr*. 2008;97(7):875–879.
- Sherry DD, Weisman R. Psychologic aspects of childhood reflex neurovascular dystrophy. *Pediatrics*. 1988;81(4):572–578.
- Pearson RD, Bailey J. Complex regional pain syndrome in an 8-year-old female with emotional stress during deployment of a family member. *Mil Med*. 2011;176(8):876–878.
- Ushida T, Nishihara M, Shimo K. A case of CRPS with familial problems. *Pract Pain Manag*. 2014;5(1):52–53.
- Chiba T, Date H, Takiguchi N. Two cases of pediatric complex regional pain syndrome. *Mansei Totsu*. 2014;33(1):217–221.
- Winston P. Early treatment of acute complex regional pain syndrome after fracture or injury with prednisone: why is there a failure to treat? A case series. *Pain Res Manag*. 2016;2016:7019196.
- Matsui H, Ohmori K, Kanamori M, Ishihara H, Tsuji H. Significance of sciatic scoliotic list in operated patients with lumbar disc herniation. *Spine (Phila Pa 1976)*. 1998;23(3):338–342.
- Erpelding N, Simons L, Lebel A, et al. Rapid treatment-induced brain changes in pediatric CRPS. *Brain Struct Funct*. 2016;221(2):1095–1111.
- Parkitny L, McAuley JH, Di Pietro F, et al. Inflammation in complex regional pain syndrome: a systematic review and meta-analysis. *Neurology*. 2013;80(1):106–117.
- Huygen FJ, De Bruijn AG, De Bruin MT, Groeneweg JG, Klein J, Zijlstra FJ. Evidence for local inflammation in complex regional pain syndrome type I. *Mediators Inflamm*. 2002;11(1):47–51.
- Goldschneider KR. Complex regional pain syndrome in children: asking the right questions. *Pain Res Manag*. 2012;17(6):386–390.
- Papadopoulos GS, Xenakis TA, Arnaoutoglou E, Tefa L, Kitsoulis PB. The treatment of reflex sympathetic dystrophy in a 9 year-old boy with long standing symptoms. *Minerva Anesthesiol*. 2001;67(9):659–663.
- Fischer SG, Zuurmond WW, Birklein F, Loer SA, Perez RS. Anti-inflammatory treatment of complex regional pain syndrome. *Pain*. 2010;151(2):251–256.
- Kingery WS. A critical review of controlled clinical trials for peripheral neuropathic pain and complex regional pain syndromes. *Pain*. 1997;73(2):123–139.
- Badri T, Ben Jennet S, Fenniche S, Benmously R, Mokhtar I, Hammami H. Reflex sympathetic dystrophy syndrome in a child. *Acta Dermatovenerol Alp Pannonica Adriat*. 2011;20(2):77–79.
- Reimer M, Rempe T, Diedrichs C, Baron R, Gierthmühlen J. Sensitization of the nociceptive system in complex regional pain syndrome. *PLoS One*. 2016;11(5):e0154553.
- Kato J, Gokan D, Ueda K, Shimizu M, Suzuki T, Ogawa S. Successful pain management of primary and independent spread sites in a child with CRPS type I using regional nerve blocks. *Pain Med*. 2011;12(1):174.
- Frost SG. Treatment of complex regional pain syndrome type I in a pediatric patient using the lidocaine patch 5%: a case report. *Curr Ther Res Clin Exp*. 2003;64(8):626–629.
- Demirdal ÜS, Bükülmez A, Solak Ö. Complex regional pain syndrome type I in a pediatric patient: case report. *Türk Pediatri Ars*. 2014;49(1):77–80.
- Simons LE. Fear of pain in children and adolescents with neuropathic pain and CRPS. *Pain*. 2016;157(Suppl 1):S90–97.
- Dadure C, Motais F, Ricard C, Raux O, Tronc R, Capdevila X. Continuous peripheral nerve blocks at home for treatment of recurrent complex regional pain syndrome I in children. *Anesthesiology*. 2005;102(2):387–391.
- Harada H, Fujiwara M, Wadayama B, Nakai K, Yoshida K, Ishikawa M. Effectiveness of psycho-orthopaedic approach to RSD in children. *Cent Jpn J Orthop Traumat*. 2007;50(3):493–494.
- Gokan D, Ueda K, Kondo Y, Ehara T, Kato J, Ogawa S. Pain management of pediatric patients with intractable pain: a report of four cases. *J Jpn Soc Pain Clin*. 2013;1(1):24–27.
- Kojima K, Taguchi H, Nakao M, Masuzawa M, Singuh K. Effective use of oral clonazepam in a child with complex regional pain syndrome. *J Jpn Soc Pain Clin*. 2013;20(1):36–39.

Journal of Pain Research

Dovepress

Publish your work in this journal

The Journal of Pain Research is an international, peer reviewed, open access, online journal that welcomes laboratory and clinical findings in the fields of pain research and the prevention and management of pain. Original research, reviews, symposium reports, hypothesis formation and commentaries are all considered for publication.

The manuscript management system is completely online and includes a very quick and fair peer-review system, which is all easy to use. Visit <http://www.dovepress.com/testimonials.php> to read real quotes from published authors.

Submit your manuscript here: <https://www.dovepress.com/journal-of-pain-research-journal>