


## Case Report

# Deterioration of bladder compliance after botulinum toxin A injection and discontinuation of medication for overactive bladder

Naoki Wada,  Mayumi Ishikawa, Masaya Nagabuchi, Shogo Makino, Kotona Miyauchi, Noriyuki Abe and Hidehiro Kakizaki

<sup>1</sup>Department of Renal and Urologic Surgery, Asahikawa Medical University, Asahikawa, Japan

### Abbreviations & Acronyms

BTX-A = botulinum toxin type A  
 CMG = cystometrogram  
 CT = computed tomography  
 DO = detrusor overactivity  
 FDV = first desire to void  
 NDV = normal desire to void  
 OAB = overactive bladder  
 Pabd = abdominal pressure  
 Pdet = detrusor pressure  
 Pves = vesical pressure  
 SDV = strong desire to void  
 VCUG = voiding cystourethrography  
 VUR = vesicoureteral reflux

**Correspondence:** Naoki Wada M.D., Ph.D., Department of Renal and Urologic Surgery, Asahikawa Medical University 2-1-1-1 Midorigaoka Higashi, Asahikawa 078-8510, Japan. Email: [nwada@asahikawa-med.ac.jp](mailto:nwada@asahikawa-med.ac.jp)

**How to cite this article:** Wada N, Ishikawa M, Nagabuchi M *et al.* Deterioration of bladder compliance after botulinum toxin A injection and discontinuation of medication for overactive bladder. *IJU Case Rep.* 2022; 5: 384–388.

This is an open access article under the terms of the Creative Commons Attribution License, which permits use, distribution and reproduction in any medium, provided the original work is properly cited.

Received 23 March 2022; accepted 8 June 2022. Online publication 20 June 2022

**Introduction:** We report a case of deterioration of bladder compliance after botulinum toxin type A injection and discontinuation of medication for overactive bladder.

**Case presentation:** A female patient with overactive bladder in her sixties had been visiting our outpatient clinic regularly for 4 years. She had received posterolateral spondylus fusion twice, which resulted in a compression fracture. She had been receiving a combination therapy of anticholinergics and  $\beta$ 3-adrenoceptor agonist for the management of overactive bladder. She received botulinum toxin type A injection for refractory overactive bladder and discontinued medical treatment for overactive bladder. Three months after botulinum toxin type A injection, cystometry revealed the deterioration of bladder compliance. Renal dysfunction, hydronephrosis, and vesicoureteral reflux were shown. Renal function and hydronephrosis were improved after restarting anticholinergics and  $\beta$ 3-adrenoceptor agonist therapy and inserting a temporary transurethral catheter.

**Conclusion:** Deterioration of bladder compliance may occur after botulinum toxin type A injection and discontinuation of overactive bladder medication in some patients with underlying neurological disease.

**Key words:** botulinum toxin type A, low compliance bladder, overactive bladder.

## Keynote message

Discontinuation of preceding medications for overactive bladder, including anticholinergics and  $\beta$ 3-adrenoceptor agonist, after botulinum toxin type A (BTX-A) treatment may reveal the pre-existing low compliance bladder in patients with underlying neurological disease. It is necessary to be attentive to the possibility that some patients need to continue anticholinergics and/or  $\beta$ 3-adrenoceptor agonist even after BTX-A treatment to prevent deterioration of bladder compliance.

## Introduction

Refractory OAB is defined as the condition where patients have tried one or more anticholinergics and/or  $\beta$ 3-adrenoceptor agonist drugs for urgency and urgency leakage, yet their condition remains unimproved due to insufficient efficacy or intolerable side-effects. Intradetrusor injection of BTX-A inhibits acetylcholine release and suppresses involuntary contraction of the bladder.<sup>1</sup> The efficacy of BTX-A injection is well established.<sup>2</sup> Herein, we present a case of deterioration of bladder compliance after BTX-A injection and discontinuation of medication for OAB.

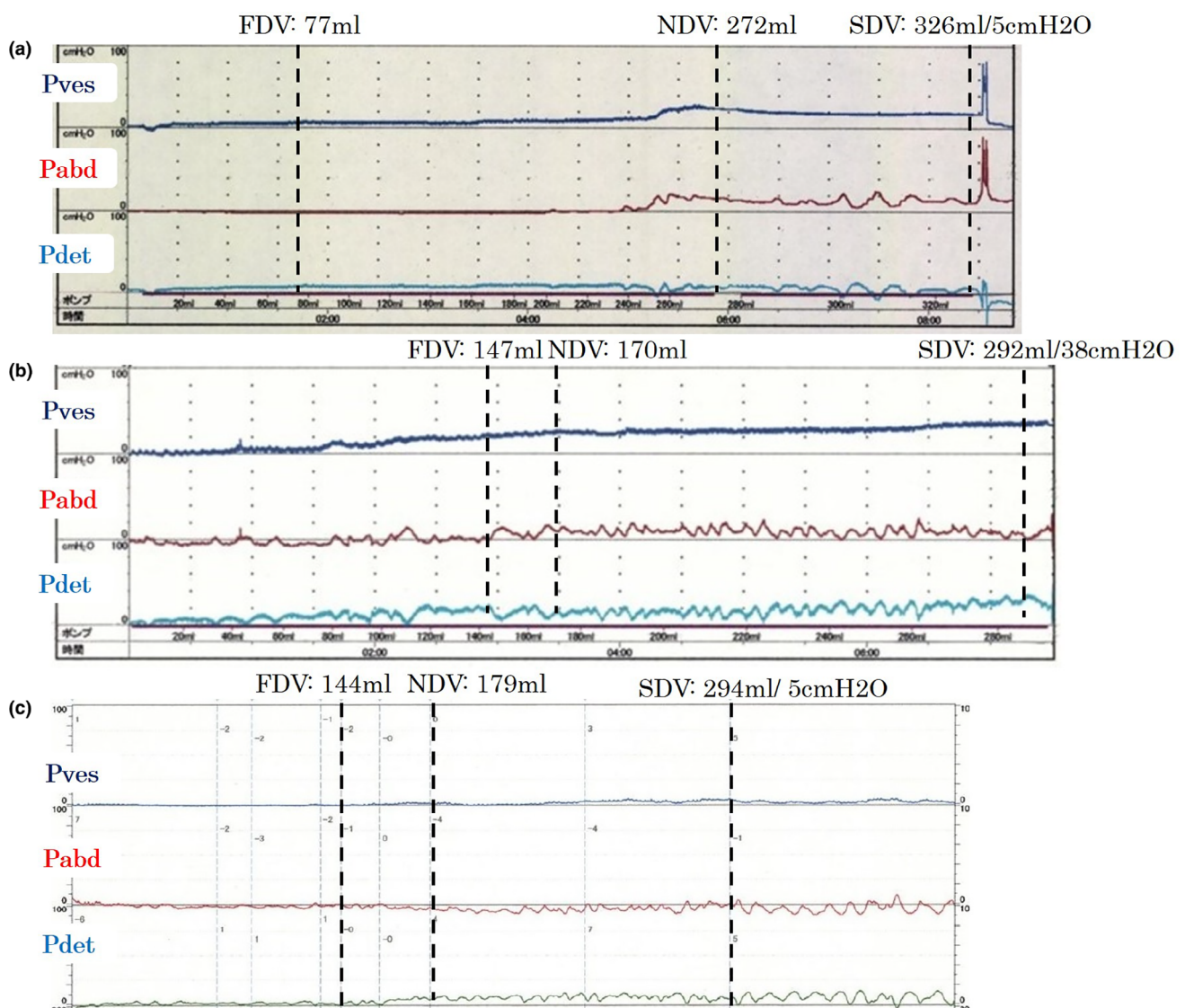
## Case report

This case report focuses on a female patient in her sixties suffering from OAB symptoms with histories of chronic rheumatoid arthritis and Sjogren syndrome. The patient had been visiting our outpatient clinic regularly for 4 years. She received lumbar posterolateral spondylus fusion twice for severe lumbar spinal canal stenosis 9 and 13 years ago and experienced a

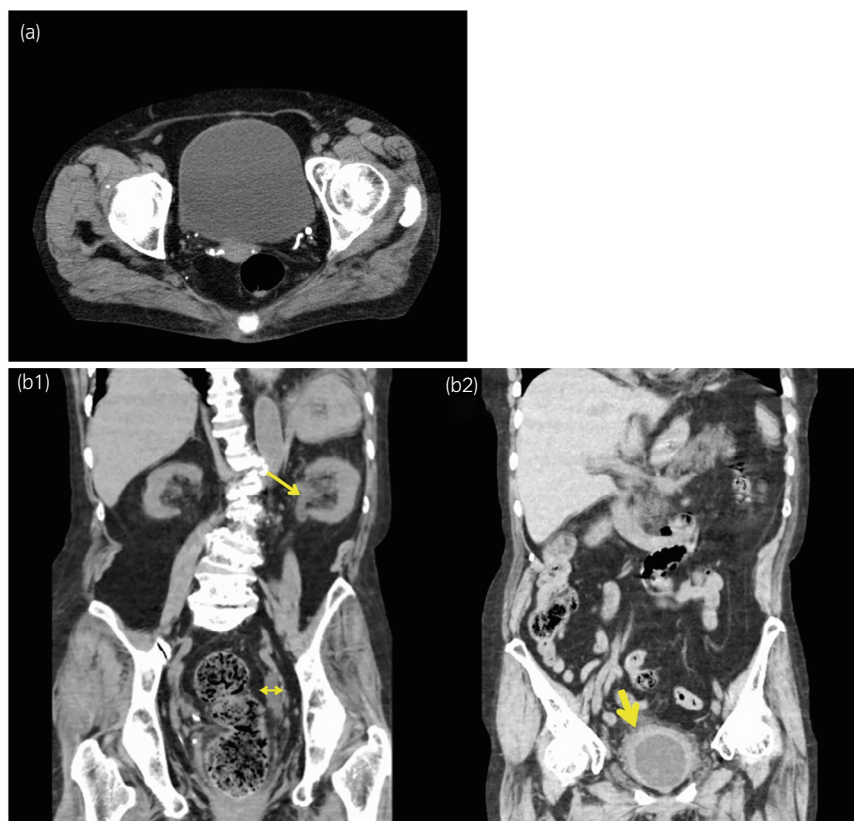
compression fracture 2 years ago. She had been receiving a combination therapy of anticholinergics (fesoterodine) and  $\beta_3$ -adrenoceptor agonist (mirabegron) for OAB symptoms, but anticholinergics therapy was sometimes discontinued due to dry mouth. This approach did not significantly improve OAB symptoms. The mean and maximum voided volume on frequency-volume charts were below 100 and 140 mL, respectively, with 20–40 mL of postvoid residual urine. Cystometry before BTX-A injection under administration of anticholinergics and  $\beta_3$ -adrenoceptor agonist showed no DO and 5 cmH<sub>2</sub>O of Pdet at 326 mL of maximum cystometric bladder capacity (compliance = 65 mL/cmH<sub>2</sub>O) (Fig. 1a). The bladder wall was not thick on CT scan (Fig. 2a). We administered 100 units of BTX-A into the bladder wall to manage refractory idiopathic OAB. At the same time, anticholinergics

and  $\beta_3$ -adrenoceptor agonist were discontinued. Bladder mucosal abnormalities, such as Hunner lesion, were not detected on cystoscopy.

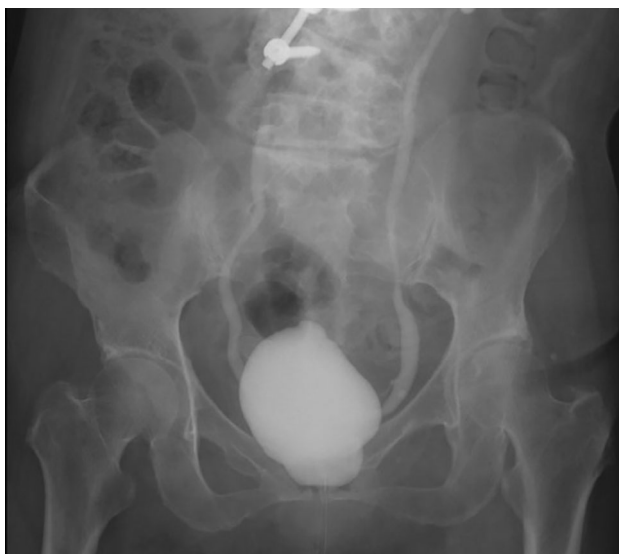Three months after BTX-A injection, her OAB symptoms were poorly improved with only a slight improvement in urinary frequency. OAB symptom score was changed from 13 (Q1: 2, Q2: 3, Q3: 4, Q4: 4) to 9 (Q1: 1, Q2: 3, Q3: 3, Q4: 2). Cystometry showed no DO and 38 cmH<sub>2</sub>O of Pdet at 292 mL of maximum cystometric bladder capacity (compliance = 7.7 mL/cmH<sub>2</sub>O) (Fig. 1b). Mirabegron was resumed, but a few weeks later, serum creatinine level was elevated from 1.05 to 1.46 mg/dL. At this time, a CT scan showed hydronephrosis and bladder wall thickness. Continuous pyuria was found in this patient both before and after BTX-A injection. Bilateral VUR was noted on VCUG (Fig. 3). Serum



**Fig. 1** Cystometrogram before and after BTX-A injection. (a) Cystometry before BTX-A injection under administration of anticholinergics and  $\beta_3$ -adrenoceptor agonist therapy showed no DO and 5 cmH<sub>2</sub>O of Pdet at 326 mL of maximum cystometric bladder capacity (compliance = 65 mL/cmH<sub>2</sub>O). (b) Cystometry performed again at 3 months after BTX-A injection showed no DO and 38 cmH<sub>2</sub>O of Pdet at 292 mL of bladder capacity (compliance = 7.7 mL/cmH<sub>2</sub>O). (c) Cystometry performed after restarting  $\beta_3$ -adrenoceptor agonist and anticholinergics therapy and inserting a temporary transurethral catheter showed no DO and 5 cmH<sub>2</sub>O of Pdet at 294 mL of bladder capacity (compliance = 59 mL/cmH<sub>2</sub>O).



**Fig. 2** Serial CT images. (a) A CT image obtained at 9 months before BTX-A injection showed no bladder wall thickness. (b) CT image obtained at 3 months after BTX-A injection showed left hydronephrosis (arrow), ureteral dilatation (double-headed arrow) (b1), and bladder wall thickness (big arrow) (b2).



**Fig. 3** VCUG performed at 3 months after BTX-A injection showed bilateral moderate VUR.

creatinine level and hydronephrosis were immediately improved after restarting anticholinergics therapy and inserting a temporary transurethral catheter for a period of 6 weeks (Fig. 4). Bladder compliance was also normalized at that point (Fig. 1c). After this episode, the patient received BTX-A injection twice (100 and 200 units, respectively) again with concurrent anticholinergics and  $\beta$ 3-adrenoceptor agonist therapies, and no hydronephrosis or renal dysfunction was developed.

## Discussion

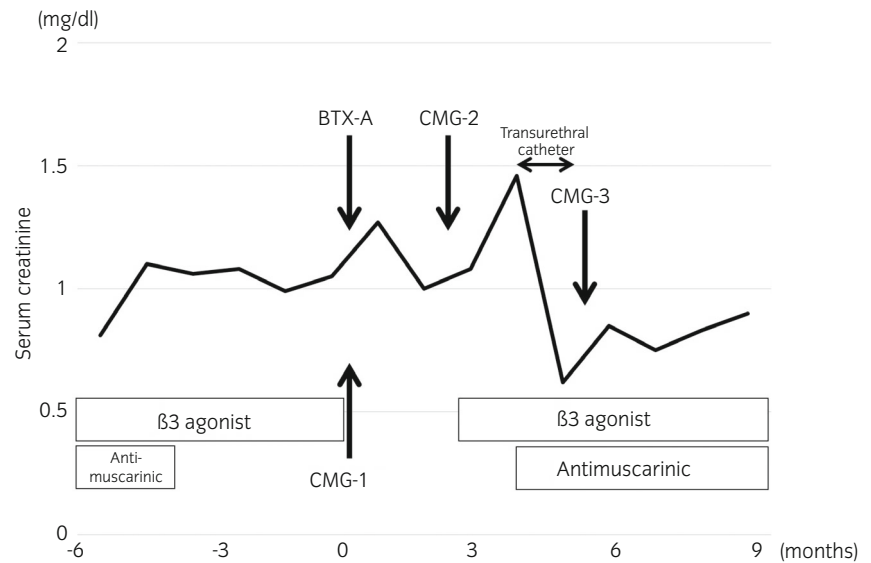
Herein, we present a case of deterioration of bladder compliance and upper urinary tract after BTX-A injection and discontinuation of medication for OAB. It is speculated that a combination therapy of anticholinergics and  $\beta$ 3-adrenoceptor agonist plays a significant role in maintaining bladder compliance even after BTX-A treatment in this patient. The key messages in this case report are that deterioration of bladder compliance and upper urinary tract may occur after BTX-A injection and discontinuation of OAB medication in some patients with underlying neurological diseases.

Assessment of the bladder wall thickness after BTX-A injection might indicate the possibility of bacterial infection of the bladder. However, continuous pyuria was present in this patient both before and after BTX-A injection. Thus, we speculated that this change was independent of bacterial infection.

The Japanese phase III, randomized, double-blind, placebo-controlled trial in OAB patients who had been inadequately managed with medications demonstrated the BTX-A group had significantly greater decreases in the mean number of daily urinary incontinence episodes, number of episodes of micturition, urgency, and nocturia from the baseline compared with the placebo group without preceding OAB medication.<sup>2</sup> In real-world practice, most patients receiving BTX-A injections discontinue preceding OAB medication after BTX-A treatment. The large real-world data on BTX-A efficacy and safety of treatment showed that only 52 of 504 patients (10.3%) intended to continue using OAB medications following BTX-A treatment, and very few patients actually continued OAB medication.<sup>3</sup> Discontinuation of preceding



**Fig. 4** Scheme of the clinical course of the patient. The patient had received a combination treatment of  $\beta$ 3-adrenoceptor agonist and anticholinergics for the management of OAB symptoms. Only  $\beta$ 3-adrenoceptor agonist had been used without anticholinergics due to dry mouth for 3–4 months before BTX-A injection. At the time of BTX-A injection, cystometry showed normal bladder compliance (Fig. 1a) (CMG-1). Three months after BTX-A injection, cystometry demonstrated the deterioration of bladder compliance (Fig. 1b) (CMG-2) and only  $\beta$ 3-adrenoceptor agonist was resumed. Following 1 month, renal dysfunction and bilateral VUR were noted. Anticholinergic therapy was also resumed, and a temporal urethral catheter was inserted for 6 weeks, which improved renal function and bladder compliance (Fig. 1c) (CMG-3).



medication for OAB, including anticholinergics and  $\beta$ 3-adrenoceptor agonist, after BTX-A treatment may reveal the pre-existing low compliance bladder in some patients with underlying neurological disease.

BTX-A injections improve bladder compliance in some patients with neurogenic low compliance bladders who are refractory to oral medications.<sup>4–6</sup> However, it seems that the effectiveness of this method is lower in both adults and children with spinal disorders and low compliance bladder.<sup>4–6</sup> O'Connor *et al.* evaluated patients with refractory impaired bladder compliance secondary to spinal myelopathy treated with 300 units of BTX-A injection.<sup>4</sup> Bladder compliance was improved only in 22 of 71 (31%) patients, leaving the remaining patients (69%) as non-responders. Peyronnet *et al.* also demonstrated that all urodynamic parameters, including bladder compliance, were significantly improved after BTX-A injection in patients with spina bifida; however, the clinical success rate was lower in patients with low compliance bladder.<sup>5</sup> Danacioglu *et al.* reported that children with a neurogenic bladder due to myelomeningocele, who had low compliance bladder without DO, showed poor therapeutic responses.<sup>6</sup> Thus, the effectiveness of BTX-A therapy for low compliance bladder is limited, and it may depend on the baseline bladder compliance.

It is unclear which of the  $\beta$ 3-adrenoceptor agonist, anticholinergics, or their combination contributed the most to improving bladder compliance and renal function after the insertion of a temporal transurethral catheter. We speculated that the  $\beta$ 3-adrenoceptor agonist contributed more to the improvement in bladder compliance, because deterioration of bladder compliance and renal function had not been detected when using only the  $\beta$ 3-adrenoceptor agonist (without anticholinergics due to dry mouth symptoms) for several months before BTX-A injection (Fig. 4). Several studies have reported supportive findings regarding the efficacy of monotherapy or the combination therapy of  $\beta$ 3-adrenoceptor agonist with anticholinergics for neurogenic low compliance bladder.<sup>7–9</sup>

We did not perform cystometry or VCUG when we first evaluated this patient. In addition, it may be necessary to

perform urodynamic evaluation in OAB patients with underlying neurological disease. Bladder compliance and upper urinary tract should be monitored in patients with neurogenic OAB who receive BTX-A injections and discontinue preceding OAB medications.

## Conclusion

Patients with underlying neurological diseases may need to continue anticholinergics and/or  $\beta$ 3-adrenoceptor agonist therapy even after BTX-A injections to prevent deterioration of bladder compliance and upper urinary tract.

## Author contributions

Naoki Wada: Conceptualization; data curation; writing – original draft. Mayumi Ishikawa: Investigation; resources. Masaya Nagabuchi: Investigation; resources. Shogo Makino: Investigation; resources. Kotona Miyauchi: Investigation; resources. Noriyuki Abe: Investigation; resources. Hidehiro Kakizaki: Supervision; writing – review and editing.

## Conflict of interest

The authors declare no conflict of interest.

## Approval of the research protocol by an Institutional Reviewer Board

Not applicable.

## Informed consent

Not applicable.

## Registry and the Registration No. of the study/trial

Not applicable.

## References

- 1 Coelho A, Dinis P, Pinto R *et al*. Distribution of the high-affinity binding site and intracellular target of botulinum toxin type A in the human bladder. *Eur. Urol.* 2010; **57**: 884–90.
- 2 Yokoyama O, Honda M, Yamanishi T *et al*. Onabotulinumtoxin A (botulinum toxin type A) for the treatment of Japanese patients with overactive bladder and urinary incontinence: results of single-dose treatment from a phase III, randomized, double-blind, placebo-controlled trial (interim analysis). *Int. J. Urol.* 2020; **27**: 227–34.
- 3 Hamid R, Lorenzo-Gomez MF, Schulte-Baukloh H, Boroujerdi A, Patel A, Farrelly E. OnabotulinumtoxinA is a well tolerated and effective treatment for refractory overactive bladder in real-world practice. *Int. Urogynecol. J.* 2021; **32**: 65–74.
- 4 O'Connor RC, Johnson DP, Guralnick ML. Intradetrusor botulinum toxin injections (300 units) for the treatment of poorly compliant bladders in patients with adult neurogenic lower urinary tract dysfunction. *Neurourol. Urodyn.* 2020; **39**: 2322–8.
- 5 Peyronnet B, Even A, Capon G *et al*. Intradetrusor injections of botulinum toxin A in adults with spinal dysraphism. *J. Urol.* 2018; **200**: 875–80.
- 6 Danacioglu YO, Keser F, Ersoz C *et al*. Factors predicting the success of intradetrusor onabotulinum toxin-A treatment in children with neurogenic bladders due to myelomeningocele: the outcomes of a large cohort. *J. Pediatr. Urol.* 2021; **17**: e1–7.
- 7 Wada N, Shimizu T, Takai S *et al*. Combinational effects of muscarinic receptor inhibition and  $\beta$ 3-adrenoceptor stimulation on neurogenic bladder dysfunction in rats with spinal cord injury. *Neurourol. Urodyn.* 2017; **36**: 1039–45.
- 8 Wada N, Okazaki S, Kobayashi S *et al*. Efficacy of combination therapy with mirabegron for anticholinergic-resistant neurogenic bladder: videourodynamic evaluation. *Hinyokika Kyo* 2015; **61**: 7–11.
- 9 Kamei J, Furuta A, Akiyama Y *et al*. Video-urodynamic effects of mirabegron, a  $\beta$ 3-adrenoceptor agonist, in patients with low-compliance bladder. *Int. J. Urol.* 2015; **22**: 956–61.