

## Short Communication

# Ability to knit may be impaired following right temporal lobe resection for drug-resistant epilepsy☆☆☆☆

Sallie Baxendale\*

Department of Clinical and Experimental Epilepsy, Institute of Neurology, UCL, United Kingdom of Great Britain and Northern Ireland



## ARTICLE INFO

## Article history:

Received 19 September 2018

Received in revised form 3 October 2018

Accepted 12 October 2018

Available online 30 October 2018

## 1. Introduction

There is a substantial literature documenting the cognitive changes following temporal lobe surgery for drug-resistant epilepsy [1]. Memory difficulties are most frequently reported following resections of dominant and non-dominant mesial temporal structures in group studies, although the nature and extent of postoperative cognitive change in an individual depend on the complex interaction of pre, peri and postoperative factors. Analyses of large datasets mean that surgical candidates at high risk of a significant postoperative decline in cognitive function can be identified prior to surgery and counselling, and preparation for any expected deterioration should form part of their routine preparation for surgery [2]. However, some surgical candidates have areas of special interest or expertise upon which there is little empirical data on the impact of surgery. Candidates and clinicians alike are often concerned about how surgery may impact these special abilities, since postoperative impairments in the ability to pursue these interests can have a significant impact on quality of life. In the absence of clinical data, clinicians are reliant on extrapolating from

neuropsychological models of brain–behaviour relationships. There is therefore an important place in the case study literature for the reporting of the impact of epilepsy surgery on special areas of function. In this paper we present the impact of a right temporal lobe resection on an adult female who was a passionate and creative knitter prior to undergoing a right temporal lobe resection for drug-resistant epilepsy.

## 2. Case report

## 2.1. Clinical history

KP had no previous neurological or psychiatric history prior to her first generalized tonic–clonic seizure which occurred at the age of 41. She experienced a second generalized tonic clonic seizure a few days later. She commenced anti-seizure medication which controlled her generalized seizures but she developed focal seizures with impairment of consciousness which continued, despite medication. She reported two different seizure types. In the first type she reported loss of awareness, followed by orofacial automatisms and right arm twitching. These seizures lasted 1–2 min in duration. These were associated with some post-ictal confusion and occurred 2–3 times a month. She also experienced weekly episodes lasting 1–2 min where she became confused and had non-sensical speech.

## 2.2. Presurgical evaluation

KP was referred for a surgical evaluation at the age of 48, seven years after the onset of her epilepsy. At the time of surgery she was taking Lamotrigine 350 mg bds and Acetazolamide, 250 mg bds.

## 2.2.1. Neurological examination

Her neurological examination was normal.

## 2.2.2. Neuroradiology

No abnormalities were evident on high resolution MRI with an epilepsy surgery protocol. An FDG PET study demonstrated hypometabolism in the inferolateral aspect of the right temporal lobe. Some mild reduced uptake was also noted in the anterior medial aspects of both frontal lobes.

## 2.2.3. Neurophysiology

KP's interictal EEG revealed interictal spikes with phase reversal over the right anterior/inferior temporal lobe representing more than 95% of

☆ Conflict of Interest: None.

☆☆ Ethical Statement: This paper presents non-identifiable data collected as part of routine clinical care. It was not classified as research by the National Health Service Health Research Authority and did not require specific ethical approval to submit for publication.

★ Consent: No personally identifiable data is included in this paper. KP has given her informed, signed consent for images of her work to be published within this paper. Copies available on request.

★★ KP has given her permission for the publication of the figures in this manuscript to be published.

\* ESRC Epilepsy Society, Chesham Lane, Chalfont St Peter, Buckinghamshire, SL9 0RJ, United Kingdom of Great Britain and Northern Ireland

E-mail address: [s.baxendale@ucl.ac.uk](mailto:s.baxendale@ucl.ac.uk)

the epileptiform discharges with 5% of discharges seen in the corresponding area over the left. Two focal seizures with impaired awareness were recorded during a one week video telemetry study. Both seizures were characterized by behavioral arrest at onset followed by oral automatisms and KP became unresponsive to the staff on the ward. In the first seizure, subtle right upper arm tremor (non-clonic) was evident. In both seizures a right inferior/anterior temporal ictal epileptiform discharge was seen on the EEG, 10 s after the clinical onset. However electroclinically the seizures were noted to be atypical for a mesial onset.

The non-invasive studies suggested a non-lesional, right hemispheric focal epilepsy, likely arising from the temporal area, or possibly from orbitofrontal area. Therefore she underwent a right frontotemporal intracranial implantation to further localize the region of seizure onset. The implantation scheme included 8 stereo-EEG electrodes in the right hemisphere targeting the amygdala, anterior hippocampus, posterior hippocampus, posterior cingulate, anterior cingulate, medial orbitofrontal cortex, lateral orbitofrontal cortex and inferior frontal gyrus (see Fig. 1). During this recording she had four seizures, all with oral and manual automatisms and loss of awareness. Two of the seizures began with behavioral arrest, prior to the onset of automatisms. Posturing was seen in the left hand. In two seizures, fast activity was seen in the right hippocampal contacts at onset which then propagated to other temporal regions, posterior cingulate and orbitofrontal cortex. However, in two seizures, this activity was preceded by a 5-second build-up of rhythmic slow activity and spiking seen in mesio-temporal and orbitofrontal regions. Subclinical seizures in sleep with a focal ictal pattern in the right hippocampus were also recorded. Interictally spikes were seen in the right hippocampus, right medial orbitofrontal cortex and the right posterior cingulate. No complications followed the electrode removal.

Overall, the findings from the intracranial EEG study were felt to be keeping with focal epilepsy arising from the right hippocampus. However, the more widespread build-up of rhythmic slow and spikes, also affecting orbitofrontal regions in two seizures indicated the possibility of a more extensive epileptogenic zone.

#### 2.2.4. Neuropsychology

KP is right handed. She functioned in the high average range intellectually with no evidence of any general intellectual decline. Within her intellectual profile she demonstrated relative weaknesses in verbal reasoning (WAIS-IV Similarities sub test score 9th percentile), and spatial construction (WAIS-IV Block Design sub test score: 9th percentile). Her verbal learning was weak (10–25th percentile) and she demonstrated accelerated forgetting of verbal material over time. Her visual learning and retention was a relative strength within her profile of scores on the memory tests (90th percentile). Overall her neuropsychological profile was not thought to be concordant with a right, non-dominant temporal lobe focus.

An fMRI language study was suboptimal due to movement artifact and KP's claustrophobia. The data from a single paradigm (verbal fluency) indicated left language dominance.

#### 2.2.5. Psychiatry

KP had no psychiatric history prior to the surgery. She had never self-harmed, taken an overdose or attempted suicide. She had never needed counselling or psychotherapy or antidepressants. She had never had any contact with mental health services or a psychiatric admission. She did not use illicit substances and did not drink alcohol. On examination she was polite, friendly and appropriate in manner with no symptoms of thought disorder, anxiety or depression. There were no psychiatric contraindications to epilepsy surgery.

#### 2.2.6. Social situation

At the time of the surgical evaluation KP was unemployed, having been made redundant from her job in customer services shortly after she was diagnosed with epilepsy. She hoped that a successful outcome following surgery would allow her to return to work. In her spare time she was a very keen knitter and created her own designs, developing the pattern from her ideas of how the final piece would look, as she worked. She had a particular speciality in creating dolls which she would customise with detailed costumes and uniforms. See Fig. 2.

#### 2.3. Surgical outcome

In view of these atypical features, KP was offered a right temporal lobe resection with reduced odds of being seizure free (40–50%). She was noted to be at high risk of a postoperative decline in memory function, particularly in visual learning, and was counselled accordingly about these risks prior to surgery. KP underwent a right temporal lobe resection at the age of 51. The surgery was uneventful and there were no medical postoperative complications. A postoperative scan conducted 3 months after the surgery demonstrated the extent of the resection. No other abnormalities were evident. See Fig. 3.

Neuropathological examination of the resected specimen revealed evidence of the previous intracranial recording but no evidence of hippocampal sclerosis or other focal pathology, although not all sub-fields were represented.

Four months after the surgery she continued to experience seizures with a frequency of 2 seizures a week. She reported memory difficulties which had a significant impact on her everyday function. She also reported elevated levels of anxiety (HADS Anxiety score = 16). Her scores on tests of verbal memory were less efficient than recorded preoperatively. On tests of visual memory her scores fell below the second percentile, representing a very significant deterioration in function on a test that she had functioned at the 90th percentile in, prior to surgery.

Six months after the surgery she taped her Acetazolamide and commenced Zonisamide 25 mg bds. She continued with pre-operative doses of Lamotrigine 350 mg bds.

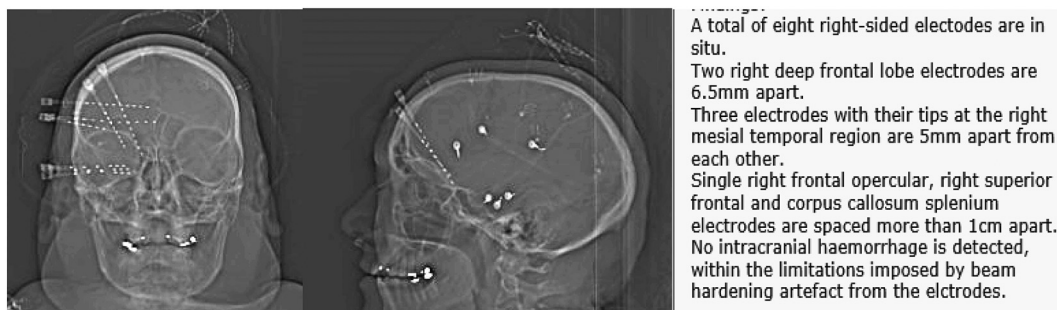

Fig. 1. Electrode placement for the intracranial study.



**Fig. 2.** Drumming Soldier: an example of one the knitted figures.

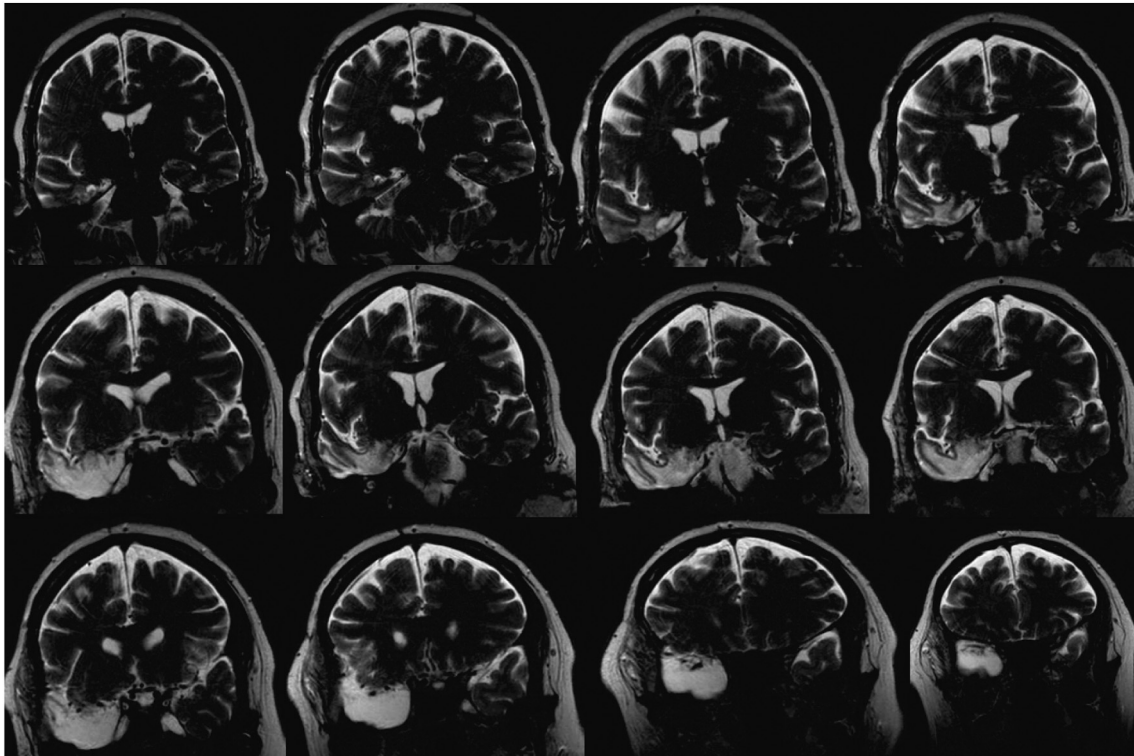
At her one-year postoperative assessments KP continued to experience seizures approximately twice a week. The postoperative declines in verbal and particularly visual memory functions which were evident at the four-month postoperative assessment remained apparent. She continued to report significant memory difficulties in everyday life. She forgets conversations and reports episodes of disorientation and difficulties navigating when she is out. She now finds it difficult to read for pleasure as she cannot commit the characters to memory. Her anxiety has reduced but she has been unable to return to work due to these difficulties.

Following surgery KP reported that she had lost the ability to knit. In the immediate postoperative months she reported that her ability to coordinate the knitting needles was impaired and she would lose her place, drop stitches and be unable to recover from errors, even when attempting to create a simple square. Over the twelve months following surgery her manual dexterity with the needles returned but she has lost her ability to create designs whilst working and continues to find it very difficult to follow a pattern. This is a significant loss in her life.

### 3. Discussion

KP was an atypical surgical candidate in a number of respects; she had late onset epilepsy (age 41) and was MRI negative. Although there was some evidence to support a right temporal lobe focus for her seizures, her interictal EEG changes were not typical for mesial temporal lobe epilepsy. The MRI and her neuropsychological profile indicated that her right hippocampus was intact in terms of both function and structure and this impression was confirmed by the histopathological examination of the surgical specimen. The surgical removal of the right hippocampus resulted in a significant postoperative deterioration in verbal and visual memory function and the loss of KP's ability to knit. The reduction of verbal memory skills following a right, non-dominant resection is not a new finding and has been reported in numerous group studies but deserves underlining in this individual case given the persisting dominance of the material specific module of memory function in clinical practice [3]. To the best of our knowledge the loss of the ability to knit following a non-dominant temporal lobe resection has not been previously reported in the literature.

Knitting is a complex skill requiring more than just bimanual dexterity. Following a knitting pattern is more akin to navigating a map than reading text, since the pattern represents salient points within a spatial framework. The simultaneous development of a design whilst creating a piece involves the formation of mental map which the knitter must constantly monitor and adapt to ensure success. In this case, the removal of



**Fig. 3.** Postoperative MR T2 weighted images in the coronal plane demonstrating the extent of the right temporal lobe resection.

the intact right mesial temporal structures appears to have had a significant impact on this process. Whilst the initial impact on KP's procedural memory of how to manipulate her knitting needles has resolved, her ability to read a pattern remains significantly compromised and she remains unable to create her own designs. It is tempting to relate this loss to the considerable literature in animal and patient studies linking spatial navigation to right hippocampal function [4]. We have been unable to find much in the literature on the neurobiological processes that underpin knitting (most of the literature on knitting relates to rather gruesome incidents involving knitting needles [5–9]) however a competence in knitting and other similar craft activities has been linked to preserved spatial processing in ageing populations [10]. KP's difficulties in knitting are unlikely to represent the drug changes she underwent 6 months after the surgery since her difficulties became apparent immediately after the operation and before these changes were implemented. Similarly, there is no evidence of any postoperative complication such as a bleed or infection that may be responsible for this loss of function.

From a clinical standpoint, knitting is gaining popularity with the young [11] as part of the wider resurgence of interest in craft activities and has been reported to have significant therapeutic benefits in both healthy and patient populations [12–14]. As such it is likely that more people who come to surgery may have interests and skills in knitting or similar craft activities as a pastime or hobby. KP's experience indicates that a right temporal lobe resection may result in postoperative deterioration in the ability to engage in this activity, particularly if investigations indicate that the hippocampus is functionally or structurally intact. We present this case to alert clinicians and prospective surgical

candidates alike of this previously undocumented consequence of non-dominant temporal lobe resection.

## References

- [1] Baxendale S. The impact of epilepsy surgery on cognition and behavior. *Epilepsy Behav* 2008;12:592–9.
- [2] Baxendale S, Thompson P, Harkness W, Duncan J. Predicting memory decline following epilepsy surgery: a multivariate approach. *Epilepsia* 2006;47.
- [3] Saling MM. Verbal memory in mesial temporal lobe epilepsy: beyond material specificity. *Brain* 2009;132:570–82.
- [4] Maguire EA. Hippocampal involvement in human topographical memory: evidence from functional imaging. *Philos Trans R Soc Lond B Biol Sci* 1997;352:1475–80.
- [5] Payne EE. Unusual fatal brain injury due to knitting-needle. *Br Med J* 1966;2:807–8.
- [6] Wisser F. Severe damage of middle and internal ear, caused by a knitting needle (author's transl). *Laryngol Rhinol Otol (Stuttg)* 1981;60:444–5.
- [7] Peschanski N, Clamageran C, Dardel N, Vianney A, Lapostolle F. Two knitting needles in the thorax in a suicide attempt diagnosed on day 6 and treated conservatively. *Ann Thorac Surg* 2011;91:305.
- [8] Andrade-Alegre R. Penetrating cardiac injury from a wooden knitting needle. *J Emerg Med* 2012;43:719.
- [9] Tamburrini A, Rehman SM, Votano D, Malvindi PG, Nordon I, Allison R, et al. Penetrating trauma of the thoracic aorta caused by a knitting needle. *Ann Thorac Surg* 2017;103:e193.
- [10] Bailey SKT, Sims VK. Self-reported craft expertise predicts maintenance of spatial ability in old age. *Cogn Process* 2014;15:227–31.
- [11] How wool got cool|Life and style|The Guardian n.d. <https://www.theguardian.com/lifeandstyle/2015/oct/08/how-wool-knitting-cool>
- [12] Clave-Brule M, Mazloum A, Park RJ, Harbottle EJ, Birmingham CL. Managing anxiety in eating disorders with knitting. *Eat Weight Disord* 2009;14:e1–5.
- [13] Fraser C, Keating M. The effect of a creative art program on self-esteem, hope, perceived social support, and self-efficacy in individuals with multiple sclerosis: a pilot study. *J Neurosci Nurs* 2014;46:330–6.
- [14] Marutani M, Yamamoto-Mitani N, Kodama S. Public health nurses' activities for suicide prevention in Japan. *Public Health Nurs* 2016;33:325–34.