

# Atypical clinical and laboratory features of fish-tank granuloma: A case report

SAGE Open Medical Case Reports  
JCMS Case Reports  
SOMCR Volume 6: 1–3  
© The Author(s) 2018  
Article reuse guidelines:  
sagepub.com/journals-permissions  
DOI: 10.1177/2050313X18804071  
journals.sagepub.com/home/sco



Michael Sander<sup>1</sup>, Judith L Isaac-Renton<sup>2</sup> and Megan A Sander<sup>3</sup>

## Abstract

We report a case of cutaneous *Mycobacterium marinum* infection with the unusual reported features of pruritus and paresthesia. In addition, we report a lack of in-vivo response to antibiotics based on in-vitro susceptibility testing.

## Keywords

Cutaneous, *Mycobacterium marinum*, fish-tank granuloma

## Introduction

Cutaneous infections caused by *Mycobacterium marinum*, a member of the non-tuberculous mycobacteria (NTM) group, occur only rarely. *M. marinum* virtually always causes cutaneous disease through direct inoculation. This typically occurs following exposure of a traumatic injury to a contaminated environmental source. The risk factors for *M. marinum* infection include exposure to fresh or salt water,<sup>1</sup> swimming in non-chlorinated swimming pools,<sup>2</sup> owning fish tanks,<sup>3</sup> and handling fish.<sup>4</sup> Typically, *M. marinum* infections initially present with a single asymptomatic papule or nodule, often with subsequent sporotrichoid spread. We report a patient who presents with the unusual initial symptoms of pruritus and paresthesia. Once the diagnosis of fish-tank granuloma has been established, the standard approach to treatment is oral antibiotic therapy based on susceptibility testing. Our patient did not respond to antibiotic therapy as expected based on in-vitro susceptibility testing results.

## Case report

A previously healthy 50-year-old male was referred to a dermatologist for assessment of a pruritic plaque on his left hand. This started as a small, erythematous papule with central vesiculation. The papule slowly increased in size over the course of several months to become a larger, scaly plaque. In addition to pruritus, the patient began to experience a tingling sensation within the affected skin. A variety of topical steroids had been previously prescribed by his family physician, as well as by another dermatologist. These brought temporary relief of his pruritus and paresthesia; however, the plaque did not resolve.

On examination of the dorsal aspect of the patient's left fifth digit, a 2 cm × 2.5 cm, well-circumscribed, erythematous to slightly violaceous plaque was noted with a small amount of adherent white scale. His surrounding skin was entirely normal. Due to its unusual morphology, a biopsy was performed. The pathology report revealed spongiotic dermatitis compatible with nummular dermatitis. Based on this report, a more potent topical steroid was prescribed. However, as before, this brought only temporary flattening of the plaque.

Several months later, the patient returned with a significant change: ulceration had occurred within the centre of the plaque (Figure 1). In addition, approximately half a dozen tender, subcutaneous nodules were noted, extending from his left fifth digit superiorly to his elbow in a sporotrichoid pattern (Figure 2). His symptoms of pruritus and paresthesia were persistent. At this time, further history was obtained, and it was determined that the patient had a salt-water fish tank containing tropical fish. Furthermore, he reported that many of his fish had died several weeks after the onset of his symptoms. Unfortunately, the deceased fish were not available for necropsy.

<sup>1</sup>Springbank Hill Dental, Calgary, AB, Canada

<sup>2</sup>Department of Pathology and Laboratory Medicine, Faculty of Medicine, The University of British Columbia, Vancouver, BC, Canada

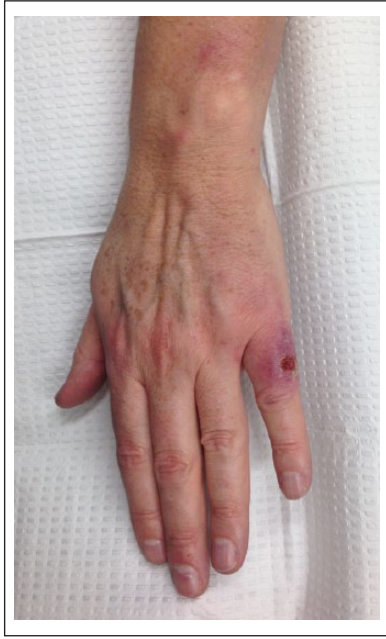<sup>3</sup>Section of Dermatology, Department of Medicine, University of Calgary, Calgary, AB, Canada

## Corresponding Author:

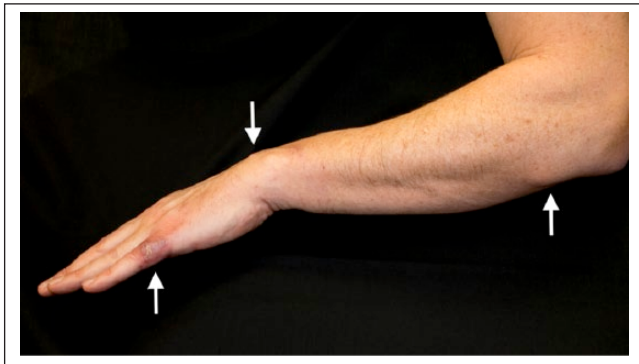
Megan A Sander, #510-1100, 1st Street SE, Calgary, AB T2G 1B1, Canada.

Email: msander@ucalgary.ca





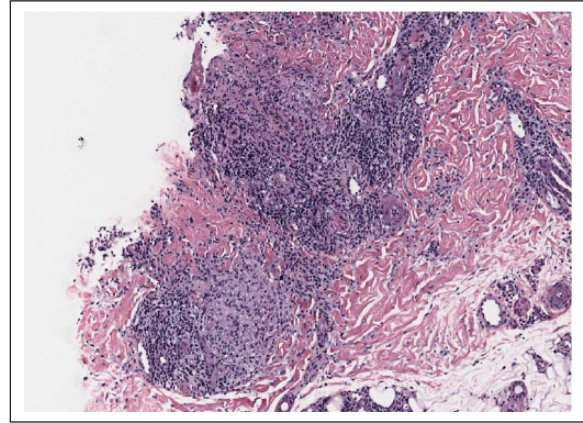
**Figure 1.** Overlying the patient's left fifth digit, an erythematous, ulcerated plaque is noted.



**Figure 2.** To the patient's left hand, wrist, and arm, scattered papulonodules are noted with a sporotrichoid pattern.

Based on this history, two additional punch biopsies of the ulcerated plaque were obtained; one biopsy was sent for culture and the other biopsy was sent for histopathological examination. The biopsy sent for culture grew *M. marinum*, confirming the diagnosis of fish-tank granuloma. Ultimately, the biopsy sent for histopathology revealed a dermal granulomatous infiltrate supporting this diagnosis (Figure 3).

Antimicrobial susceptibility testing for the cultured strain of *M. marinum* showed sensitivity to amikacin, clarithromycin, doxycycline, ethambutol, moxifloxacin, rifabutin, and rifampin. This particular isolate of *M. marinum* was resistant to ciprofloxacin and trimethoprim-sulfamethoxazole. Based on these susceptibility results, the patient was started on doxycycline at a dose of 100 mg twice daily in combination with azithromycin at a dose of 250 mg once daily. However, despite



**Figure 3.** Within the dermis of the biopsy specimen, a granulomatous infiltrate is seen, compatible with the diagnosis of fish-tank granuloma.

immunocompetence, after 3 months of continuous therapy, the patient's ulcerated plaque and sporotrichoid nodules remained unchanged. At this time, the patient's antibiotic therapy was changed to moxifloxacin at a dose of 400 mg once daily in combination with clarithromycin at a dose of 1000 mg once daily. In addition, the patient began applying local heat to the affected skin several hours per day using a reusable heat pack. The patient was also referred to a plastic surgeon for excision of the subcutaneous nodules on his hand, wrist, and arm. After excision of these nodules, and further 3 months of the new antibiotic regime, the patient's ulcerated plaque healed, and the excised subcutaneous nodules did not recur. Clinical resolution of the patient's disease was confirmed 17 months after the initial appearance of the papule overlying his left fifth digit.

## Discussion

*M. marinum* infections are most commonly asymptomatic, but patients may occasionally present with pain and tenderness.<sup>5-8</sup> Clinically, *M. marinum* infections present with a single papule or nodule – occasionally a pustule or abscess – that is clinically non-specific. However, with time, the primary lesion characteristically ulcerates and sporotrichoid spread occurs. While not pathognomonic for *M. marinum*, when a sporotrichoid pattern develops, there should be an increased suspicion for an NTM infection. Sporotrichoid presentations have been reported in 20%–81% of cases of *M. marinum* infection.<sup>1,6,9-13</sup>

In the reported case, there are several distinguishing features. First, one of the presenting symptoms was pruritus, which has only been rarely reported.<sup>10,14,15</sup> Second, we were unable to find previous reports of the symptom of paresthesia. We postulate that this symptom may have occurred secondary to perineural inflammation. Based on this single case report, we cannot definitively ascertain that these atypical features of pruritus and paresthesia are due specifically to *M. marinum*; however, we conclude that these symptoms should

not dissuade the clinician from pursuing the diagnosis of an NTM infection.

The patient described herein failed to respond to doxycycline and azithromycin, despite supporting in-vitro susceptibility testing results. There is limited data correlating NTM in-vitro susceptibility testing to in-vivo antibiotic efficacy. Since *M. marinum* is not considered a part of the normal skin flora, and is always considered pathogenic, most laboratories will automatically perform susceptibility testing. If a clinician practices in a region where this is not considered standard of care, we recommend that susceptibility testing be requested of the laboratory. Although our patient did not respond to the initial combination of antibiotics, he ultimately responded to a different antimicrobial regimen supported by the susceptibility report. Therefore, based on our case, we conclude that it may be worth considering alternative antibiotics if the patient does not respond to several months of susceptibility-based antimicrobial therapy. While large trials evaluating optimal therapy for NTM infections are lacking, reports indicate that a combination of antibiotics should be used, with or without additional modalities, such as local heat application.<sup>16–18</sup> For invasive disease, such as tenosynovitis, debridement is recommended.<sup>19</sup>

### Acknowledgement

The authors thank Dr M. Schneider for providing the photograph of the histopathology.

### Declaration of conflicting interests

The author(s) declared no potential conflicts of interest with respect to the research, authorship, and/or publication of this article.

### Funding

The author(s) received no financial support for the research, authorship, and/or publication of this article.

### Informed consent

Informed consent for the publication of patient information and images was obtained.

### References

- Jolly HW and Seabury JH. Infections with *Mycobacterium marinum*. *Arch Derm* 1972; 106: 32–36.
- Elston D. Nontuberculous mycobacterial skin infections. *Am J Clin Dermatol* 2009; 10: 281–285.
- De Groote MA and Johnson P. Skin, bone and soft tissue infections. In: Pedley S, Bartram S, Rees S, et al. (eds) *Pathogenic Mycobacteria in Water: A Guide to Public Health Consequences*. London: World Health Organization, IWA Publishing, 2004, pp. 104–114.
- Sia TY, Taimur ST, Blau DM, et al. Clinical and pathological evaluation of *Mycobacterium marinum* group skin infections associated with fish markets in New York City. *Clin Infect Dis* 2016; 62: 590–595.
- Collins CH, Grange JM, Noble WC, et al. *Mycobacterium marinum* infections in man. *J Hyg Camb* 1985; 94: 135–149.
- Edelstein H. *Mycobacterium marinum* skin infections. *Arch Intern Med* 1994; 154: 1359–1364.
- Kang GC, Gan AW, Yam A, et al. *Mycobacterium abscessus* hand infections in immunocompetent fish handlers: case report. *J Hand Surg Am* 2010; 35: 1142–1145.
- Gray SF, Smith RS, Reynolds NJ, et al. Fish tank granuloma. *BMJ* 1990; 300: 1069–1070.
- Gonzalez-Santiago TM and Drage LA. Nontuberculous mycobacteria: skin and soft tissue infections. *Dermatol Clin* 2015; 33(3): 563–577.
- Dodiuk-Gad R, Dyachenko P, Ziv M, et al. Nontuberculous mycobacterial infections of the skin: a retrospective study of 25 cases. *J Am Acad Dermatol* 2007; 57(3): 413–420.
- Aubry A, Chosidow C, Caumes E, et al. Sixty-three cases of *Mycobacterium marinum* infection: clinical features, treatment and antibiotic susceptibility of causative isolates. *Arch Intern Med* 2002; 162: 1746–1752.
- Casal M and del Mar Casal MM. Multicenter study of incidence of *Mycobacterium marinum* in humans in Spain. *Int J Tuberc Lung Dis* 2001; 5(2): 197–199.
- Flemming P and Keystone JS. *Mycobacterium marinum* infection with sporotrichoid spread from fish tank exposure. *Can Med Ass J* 2017; 189(2): E76.
- Lee WJ, Kang SM, Sung H, et al. Non-tuberculous mycobacterial infections of the skin: a retrospective study of 29 cases. *Jour Dermatol* 2010; 37: 965–972.
- Hummer D, Pitlik S, Block C, et al. Aquarium-borne *Mycobacterium marinum* infection. *Arch Dermatol* 1986; 122: 698–703.
- Hisamiehi K, Hiruma M, Yamazaki M, et al. Efficacy of oral minocycline and hyperthermic treatment in a case of atypical mycobacterial skin infection by *Mycobacterium marinum*. *Jour Dermatol* 2002; 29(12): 810–811.
- Wiegell SR, Kongshoj B and Wulf HC. *Mycobacterium marinum* infection cured by photodynamic therapy. *Arch Dermatol* 2006; 142(9): 1241–1242.
- Gong N, Tan Y, Li M, et al. ALA-PDT combined with antibiotics for the treatment of multiple skin abscesses caused by *Mycobacterium fortuitum*. *Photodiagnosis Photodyn Ther* 2016; 15: 70–72.
- Wang SH and Pancholi P. Mycobacterial skin and soft tissue infection. *Curr Infect Dis Rep* 2014; 16: 438–445.