



Since January 2020 Elsevier has created a COVID-19 resource centre with free information in English and Mandarin on the novel coronavirus COVID-19. The COVID-19 resource centre is hosted on Elsevier Connect, the company's public news and information website.

Elsevier hereby grants permission to make all its COVID-19-related research that is available on the COVID-19 resource centre - including this research content - immediately available in PubMed Central and other publicly funded repositories, such as the WHO COVID database with rights for unrestricted research re-use and analyses in any form or by any means with acknowledgement of the original source. These permissions are granted for free by Elsevier for as long as the COVID-19 resource centre remains active.



Case Report

Acute Myocardial Infarction From Embolized Left Ventricular Thrombus in Coronavirus Disease 2019

Anna R. Samuel

A B S T R A C T

Keywords:

acute myocardial infarction
COVID-19
LV thrombus
STEMI
thrombotic occlusion

A 44-year-old man with a late presentation of coronavirus disease 2019 (COVID-19) pneumonia developed a left ventricular apical thrombus resulting in an asymptomatic anterior myocardial infarction due to extensive thrombosis of the left anterior descending artery. There are increasing reports of thrombotic complications in patients infected with COVID-19. This case highlights the risk of thrombotic events caused by severe acute respiratory syndrome-related corona virus-2 and the associated challenges in management. The objective of this case report is to generate primary literature and raise awareness and appreciation for cardiac manifestations of COVID-19.

© 2022 Elsevier Inc. All rights reserved.

Introduction

This is a case report of a 44-year-old man who was admitted with a late presentation of coronavirus disease 2019 (COVID-19) with persistent shortness of breath. A large left ventricular (LV) apical thrombus developed, resulting in an anterior myocardial infarction (MI) due to extensive embolic thrombosis of the left anterior descending (LAD) artery. This case highlights the risk of thrombotic events caused by severe acute respiratory syndrome-related corona virus-2 (SARS-CoV-2).

Case Presentation

In August 2021, a 44-year-old unvaccinated White man with no past medical history, who was exposed to COVID-19 14 days prior, presented to the emergency department with complaints of sore throat, dry cough, and shortness of breath associated with extreme fatigue of 12 days' duration. Additional symptoms included high-grade fevers, headaches, arthralgias, anosmia, and hypogeusia. He tested positive for COVID-19 in the outpatient setting 6 days before presentation.

The patient monitored his oxygen saturation at home and noted it was approximately 75%, which prompted him to seek medical attention. A chest radiograph showed a pattern of lobar consolidation consistent with COVID pneumonia. He was admitted to monitored bed and treated with supplemental oxygen and systemic steroids. It was felt that remdesivir would not have any meaningful impact given that he was more than 10 days from symptom onset.¹ Empiric antibiotics were initiated due to increasing oxygen requirements and sputum production. Subcutaneous enoxaparin was used for venous thromboembolic prophylaxis.

His symptoms gradually improved over the course of a week. However, during the early morning hours of day 7 of hospitalization, acute ST segment abnormalities were noted on telemetry monitoring while the patient was asleep. The patient was awakened to have an electrocardiogram (ECG) performed, which showed significant ST segment changes consistent with a ST elevation MI (STEMI), as seen in [Figure 1](#). Serial ECGs confirmed these changes, and high-sensitivity troponin was elevated at 14,000 ng/L. The patient, however, was completely asymptomatic. He denied chest discomfort, pain, tightness, heaviness, or pressure, abdominal or back pain, weakness, or any worsening dyspnea. He stated he was sleeping comfortably until he was awakened for the ECG.

Past Medical History

The patient was otherwise healthy and had no known diabetes, hypertension, hyperlipidemia or other cardiac history, operations, or hospitalizations. He had no known drug allergies. He denied any family history of coronary artery disease and denied tobacco, alcohol, or substance use. No significant risk factors for coronary artery disease were identified.

A 12-point review of systems was negative, except for what was noted above.

Physical Examination

The patient was a well-developed male with body mass index of 26 kg/m² in no acute distress. Vital signs were oral temperature, 98.1°F; pulse, 115 beats/min; respirations, 20 breaths/min; oxygen saturation was 93% with 6 liters through a high-flow cannula; and blood pressure was 132/80 mm Hg. There were no carotid bruits or

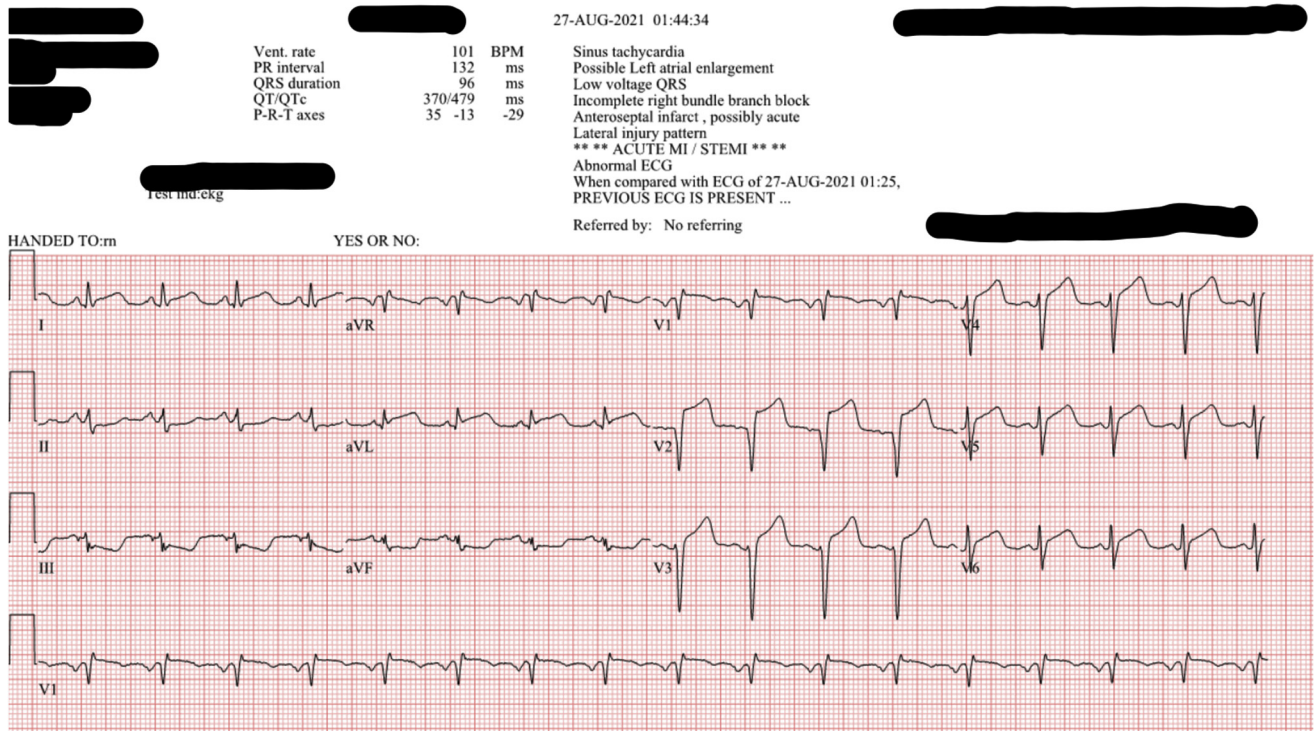


Figure 1. An electrocardiogram on early morning of day 7 demonstrates 3+ mm ST elevations in the anterior leads with reciprocal ST depressions in the inferior leads.

jugular venous distension. The cardiovascular examination was significant for slightly tachycardic but regular S1, S2, point of maximal impulse nondisplaced with no murmur, gallops, or rubs. Lung auscultation revealed a few wheezes bilaterally. Extremities were not found to have cyanosis, clubbing, or edema.

Diagnostic Studies

Table 1 summarizes laboratory findings, of which elevation in high-sensitivity troponins during the MI were most remarkable, with a peak level of 20,384 ng/L. A computed tomography angiogram of the chest showed no evidence of pulmonary embolism (PE) or aortic aneurysm but demonstrated diffuse bilateral focal and confluent ground-glass opacities with additional consolidative opacities compatible with persistent viral pneumonia. Heart and mediastinal structures had normal size and appearance, with no mass lesions. A retrospective review of images showed no evidence of LV thrombus, and the inferior vena cava was compressible, without evidence of thrombosis.

An ECG on admission showed sinus tachycardia with an incomplete right bundle branch block and no acute ST/T abnormalities (Figure 2). Subsequent ECGs showed ST elevation, as previously mentioned. Because the patient was completely asymptomatic, without any evidence of hemodynamic instability upon identification of STEMI on ECG, he was classified as stable but guarded, and the decision was made not to rush to emergent coronary angiography. This occurred at a time when cardiac manifestations of COVID-19 or the management thereof were still obscure.

An urgent echocardiogram was ordered. The rationale for this decision was a thromboembolic process rather than atherosclerotic plaque erosion or rupture was strongly suspected in this otherwise healthy adult with no known cardiac risk factors. The echocardiogram revealed a very large LV thrombus (Figure 3). Left and right ventricular systolic function was normal, with an ejection fraction

of 55% to 60% and grade 1 diastolic dysfunction. The left and right atria had normal dimensions. Acute coronary syndrome protocol was initiated. An unfractionated heparin infusion was initiated, and the enoxaparin was discontinued. The patient was given full-dose aspirin, atorvastatin, and metoprolol.

Owing to the suspicion that part of the thrombus had embolized down a coronary artery, causing the ECG changes, a coronary

Table 1
Results of Laboratory Studies

Laboratory Test	Result (Reference Range)	Units
SARS-CoV-2 real-time RT-PCR assay	Positive	
White blood cell count	11.43 (4.00-10.0)	$\times 10^3/\mu\text{L}$
Hemoglobin	13.4	g/dL
Hematocrit	41.3	%
Platelet count	221	$\times 10^3/\mu\text{L}$
Glucose	105	mg/dL
Sodium	138	mmol/L
Potassium	4.0	mEq/L
Creatinine	0.7	mg/dL
Blood urea nitrogen	18	mg/dL
Albumin level	decreased from 3.2 to 2.5	g/dL
Total protein	5.4	g/dL
Total bilirubin	1.9 (0.3-1.3)	mg/dL
Aspartate aminotransferase	45 (14-40)	IU/L
Alanine aminotransferase	150 (10-49)	IU/L
Creatine kinase	1179 (46-171)	IU/L
Brain natriuretic peptide	69	ng/L
High-sensitivity troponins		
At admission	5- >7- >8	ng/L
During myocardial infarction	14,109 > 12,396 > 20,384 (0.00-53.48)	ng/L
C-reactive protein	9 (2.3-3.5)	mg/dL
Prothrombin time	15.5	sec
Partial thromboplastin time	24	sec
International normalized ratio	1.4	
D-dimer	0.39 (0.19-0.49)	mg/L

RT-PCR = reverse-transcriptase polymerase chain reaction; SARS-Cov-2 = severe acute respiratory syndrome-related corona virus-2.

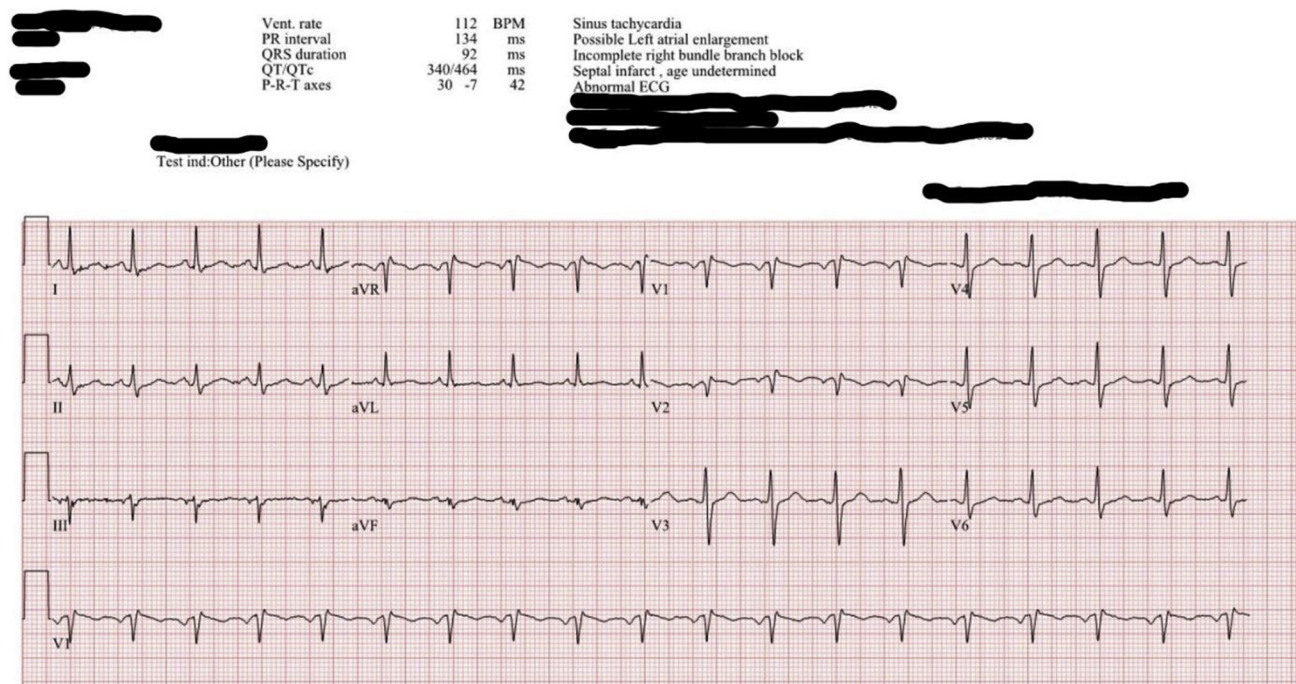


Figure 2. An electrocardiogram on admission shows sinus tachycardia with incomplete right bundle branch block.

angiogram was then performed and confirmed an acute 100% thrombotic occlusion of the ostial LAD artery. A part of this thrombus extended into the ostium of the left circumflex (LCx) artery, but the LCx artery had thrombolysis in myocardial infarction grade 3 (TIMI-3) and the right coronary artery had a normal appearance. TIMI is a grading system used in interventional cardiology to indicate the patency of the arterial vessel lumen. Values can range from 0= no flow to 3= widely patent. An attempt at intracoronary thrombolysis with tissue plasminogen activator (tPA) was unsuccessful. At this point, the patient was classified as high risk for further thromboembolic events and arrhythmias or cardiogenic shock and was admitted to the cardiovascular critical

care unit while and multidisciplinary heart team consultation was initiated to discuss management options.

Discussion

Since the outbreak of the pandemic, there is increasing evidence suggestive of a high incidence of thrombotic complications in patients infected with COVID-19 such as deep vein thrombosis, PE, and microvascular thrombosis. A case of a large right atrial thrombus with right ventricular failure managed with percutaneous thrombectomy and right ventricular mechanical support and another in a patient with deep vein thrombosis and suspected PE in the setting of COVID-19 was reported in May 2020.² Woehl et al³ reported multiple cases of aortic thrombosis in patients admitted with COVID-19 infection.

Most STEMI events are caused by thrombotic occlusion secondary to plaque erosion or rupture. A coronary embolic phenomenon is quite rare but is being increasingly recognized as an etiology of acute MI.⁴ Nevertheless, a fully asymptomatic development of LV thrombus and subsequent embolization down the coronary arteries resulting in a STEMI caught on telemetry was a novel exposure for all involved in the care of this patient and posed unique challenges in his management. Unlike this case, other case reports of LV thrombus with STEMI in COVID-19 have evidence of LV dysfunction, hemodynamic and electrophysiologic compromise, and are symptomatic on presentation.⁵ Aspects that make this case unique include:

- sudden onset 3- to 4-mm ST elevation with no hemodynamic compromise or symptoms;
- large size of the LV thrombus without significant wall motion abnormalities with normal left and right ventricular systolic function;
- the coronary angiographic findings of an acute 100% thrombotic occlusion of the ostium of the LAD and a part of the same thrombus extending into the ostium of the LCx artery with TIMI-3 flow; and

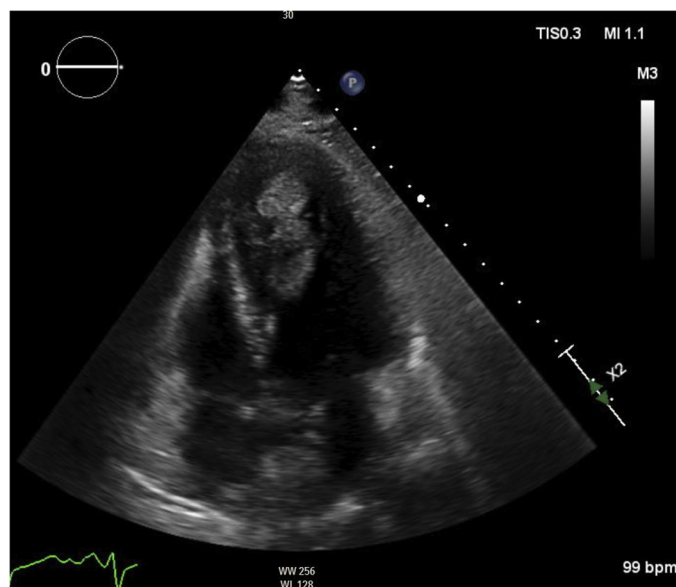


Figure 3. An echocardiographic image demonstrates a large left ventricular apical thrombus.

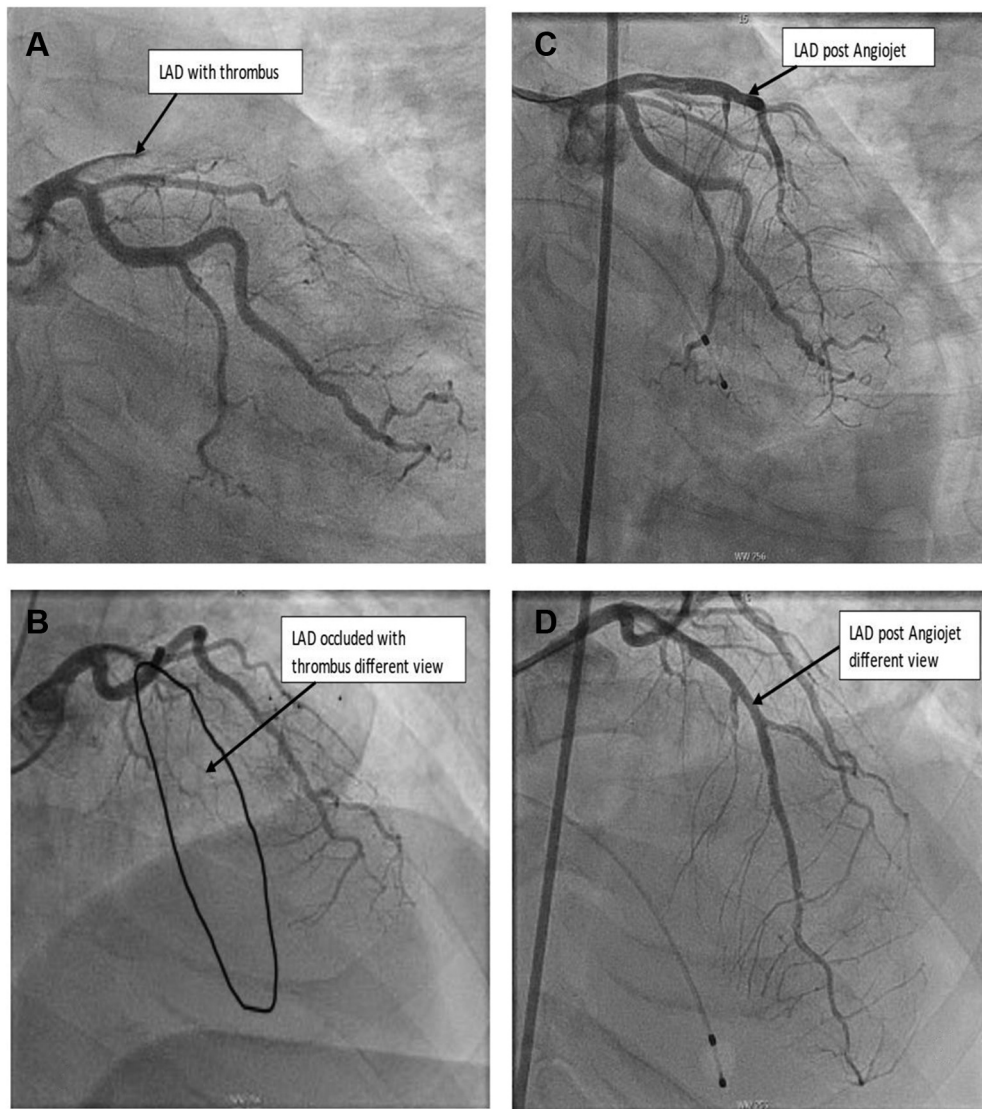


Figure 4. Angiographic images demonstrate left anterior descending artery thrombus and revascularization.

- otherwise smooth, normal angiographic appearance of the coronary arteries as seen after thrombectomy.

The above factors support the notion that the thrombus that lodged in the coronary ostia consisted of pieces that detached and embolized from the large LV thrombus. The LV being a dynamic chamber, a large thrombus could readily embolize and travel down the aorta.

It is worth noting that this patient developed a large LV thrombus despite negative D-dimer and being placed on an appropriate prophylactic dose of enoxaparin as recommended by American Society of Hematology.⁶ Multiple factors, such as symptoms, comorbidities, size of infarct, delay to presentation, hemodynamic stability, infectivity, and protection of the care team, must be considered while determining the best reperfusion strategy for a patient with COVID-19 and STEMI.⁷ This patient was out of his 10-day quarantine period and was hemodynamically stable.

Pathophysiology

There are much available data suggesting the existence of a hypercoagulable state in patients affected by SARS-CoV-2 and increased

risk of death associated with the coagulopathy.^{8,9} Venous thromboembolic events are much more common and well described in COVID-19.² However, the specific mechanism of LV thrombus formation in COVID-19 is not well defined,¹⁰ but is believed to be due to the hypercoagulability and local myocardial inflammation leading to the presence of relatively static blood resulting in thrombus formation.¹¹ The Virchow's triad consisting of 3 major contributors to clot formation; namely, endothelial injury, stasis, and hypercoagulable state; applies to severe COVID-19 infection. Multiple processes¹² have been cited as the mechanism for the hypercoagulability in patients affected by SARS-CoV-2 and may include

- Direct infection of type II pneumocytes and endothelial cells increasing permeability. SARS-CoV-2 uses angiotensin-converting enzymes 2 receptors, which are predominantly in the pneumocytes and endothelial cells, as the entry point into human cells, and may play a role in endothelial cell activation and dysfunction.
- Low-grade disseminated intravascular coagulation combined with pulmonary microvascular damage.
- Cytokine storm/inflammatory responses in the form of activation of T cells, neutrophils, monocytes, macrophages, and

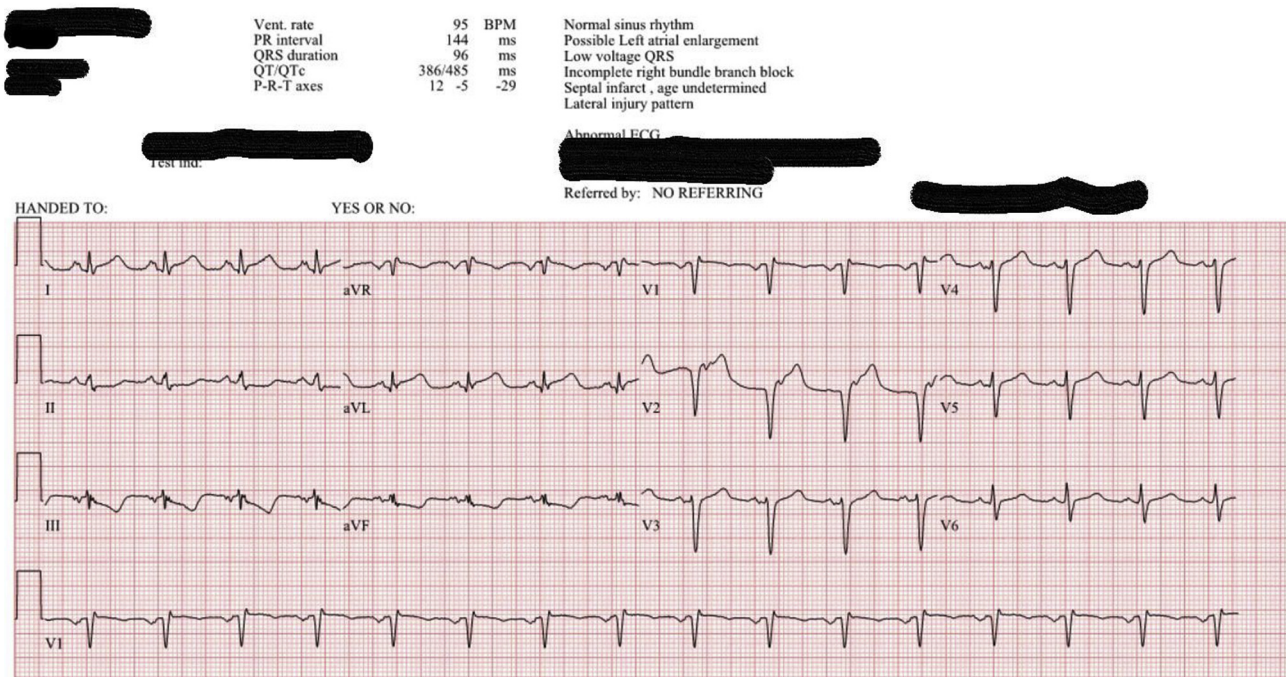


Figure 5. An electrocardiogram after thrombectomy shows resolving ST changes.

platelets resulting in increased concentrations of proinflammatory cytokines, such as tumor necrosis factor- α and interleukins, and plasminogen activator inhibitor-1 culminating in the development of microvascular and macrovascular thrombi composed of fibrin, neutrophil extracellular traps, and platelets that subsequently initiate coagulation activation and thrombin generation as well as instigation of the fibrinolytic system.

- Higher levels of inflammatory biomarkers, such as C-reactive protein, which was high in this patient, antiphospholipid antibodies, and markers of fibrinolysis, such as D-dimer, have been reported in COVID-19 patients with a STEMI. Additionally, the mean peak high-sensitivity troponins are higher in STEMI patients with COVID-19.¹³

The differential diagnoses of ST elevation in a patient with COVID-19 may include but are not limited to thrombotic occlusions of 1 or more coronary arteries,¹³ PE, occlusion of coronary vessels from underlying atherosclerotic plaque, coronary spasms, myocarditis, pericarditis, and Takotsubo cardiomyopathy.⁷

Management

A multidisciplinary heart team approach was used in the decision regarding the best course of action in the given complex situation. After the initial coronary angiogram and unsuccessful thrombolysis with intracoronary tissue plasminogen activator, cardiovascular surgery consultants did not believe a surgical intervention would help this patient. Rheolytic thrombectomy of the clot in the LAD artery with use of the AngioJet device (Boston Scientific) was proposed as a conceivable option. The AngioJet device is a mechanical thrombectomy device used for percutaneous coronary intervention patients with large thrombus burden. However, due to a very high risk of embolization, particularly to the brain, it was decided to bring the patient back to the catheterization laboratory and place a Sentinel device (Boston Scientific) for

cerebral embolic protection before attempting thrombectomy. The Sentinel device has 2 attached filters that capture and remove thrombus/debris and is generally used during transcatheter aortic valve replacement (TAVR) procedures.

After a thorough discussion with the patient and his family members regarding the patient's clinical situation, they understood the risks involved. Next, a temporary pacemaker wire was inserted, and rheolytic thrombectomy of the LAD artery using the AngioJet device was performed. There was significant improvement in thrombotic burden after thrombectomy, leading to TIMI-3 flow in the LAD artery (Figure 4).

A repeat ECG after the thrombectomy on day 8 was consistent with resolving ST changes compared with the day before (Figure 5). An echocardiogram 3 days later showed a moderate-size apical thrombus, but compared with the previous echocardiogram, thrombus size was smaller and less mobile. The patient remained hemodynamically stable and asymptomatic and was transferred to the step-down intensive care unit.

Dual-antiplatelet therapy (DAPT) with clopidogrel and aspirin was initiated. A heparin drip was continued postprocedure. The patient was started on long-term anticoagulation with Coumadin (Warfarin; Bristol Myers Squibb) for the LV thrombus. β -Blockade was also continued to avoid ectopy and tachycardia. His respiratory and constitutional symptoms continued to improve. He did not experience any further complications and was discharged in stable condition 1 week after the complex thrombectomy procedure. The patient was given recommendations to follow-up in the cardiology clinic to discuss projected duration of DAPT and Coumadin therapy.

Follow-up

A follow up echocardiogram 3 months later in the cardiology clinic demonstrated complete dissolution of thrombus, with an ejection fraction of 60% to 65%. Warfarin therapy was discontinued,

but DAPT continued. His hypercoagulable workup results were within normal limits. The patient returned to usual activities.

Conclusion

Increased thrombotic risk is a well-recognized complication of COVID-19. Management of acute MI complicated by extensive thrombus burden in patients with COVID-19 is yet to be described and presents particular challenges regarding to procedural technique and choice of adjunct pharmacotherapy.¹⁴ Several prospective randomized clinical trials and cohort studies are ongoing aimed at developing evidence based management strategies for cardiovascular patients affected by the virus.¹⁵ Contemporary guidelines from the American College of Cardiology/American Heart Association/Society of Cardiovascular Angiography and Interventions recommend a multidisciplinary, patient-centered heart team concept, capitalizing on the collective experience of the team that offers a balanced, shared decision-making approach to revascularization decisions for patients for whom the optimal treatment strategy is unclear.¹⁶ The heart team is primarily made up of general and interventional cardiologists and cardiovascular surgeons, augmented by referring providers, nurses, advanced practice providers, and incorporates patient preferences and goals. While the standard of care in STEMI is an immediate trip to the cardiac catheterization laboratory, the heart team decision was crucial in this dynamic clinical situation, which led to early diagnosis and selection of treatment options as evidenced by the excellent outcome and myocardial performance at 3 months.

This case report is an excellent testament of the cardiovascular community including technicians, nurses, advanced practice providers, and cardiologists playing a key role in the management and treatment of patients affected by COVID-19, which continues to display its various manifestations. Nurse practitioners are an integral part of the heart team and are often involved in assessment, diagnosis, and management decisions of patients showing cardiovascular manifestations of COVID-19. This case report not only generates primary literature and provokes thought and appreciation of the relentless display by SARS-CoV-2 but is also a source of humility and pride for the cardiovascular clinician.

Acknowledgments

Anna Samuel thank all the staff of Texoma Medical Center involved in the care of this patient. I especially thank Dr. Sudhir Thotakura, MD, the primary and interventional cardiologist who guided and proof-read this paper, as well as Dr. Mukesh Sheth, MD, FACC who encouraged me to write this report for publication. Additionally, I acknowledge my Doctor of Nursing Practice faculty at University of Texas Medical Branch, Galveston for their guidance in scholarly writing.

References

1. Paranjape N, Husain M, Priestley J, Koonjah Y, Watts C, Havlik J. Early use of remdesivir in patients hospitalized with COVID-19 improves clinical outcomes: a retrospective observational study. *Infect Dis Clin Pract (Baltim Md)*. 2021;29(5):e282–e286. <https://doi.org/10.1097/IPC.0000000000001023>
2. Kaki A, Singh H, Cohen G, Schreiber T. A case report of a large intracardiac thrombus in a COVID-19 patient managed with percutaneous thrombectomy and right ventricular mechanical circulatory support. *Eur Heart J Case Rep*. 2020;4(6):1–5. <https://doi.org/10.1093/ehjcr/yttaa308>
3. Woehl B, Lawson B, Jambert L, Tusch J, Ghassani A, Hamade A. 4 cases of aortic thrombosis in patients with COVID-19. *JACC Case Rep*. 2020;2(9):1397–1401. <https://doi.org/10.1016/j.jaccas.2020.06.003>
4. Liu G, Yang P, He Y. Left ventricular mural thrombus and dual coronary embolization associated with hyperthyroid cardiomyopathy and atrial fibrillation: a case report. *BMC Cardiovasc Disord*. 2017;17(1):128.
5. Sisakian H, Martirosyan S, Shekoyan S, Terteryan A, Hovhannisyan M. Asymptomatic COVID-19 and ST-elevation myocardial infarction in young adults: lessons learned from two similar cases. *ESC Hear Fail*. 2022;9(1):775–781. <https://doi.org/10.1002/ehf2.13690>
6. Cuker A, Tseng EK, Nieuwlaar R, et al. American Society of Hematology 2021 guidelines on the use of anticoagulation for thromboprophylaxis in patients with COVID-19. *Blood Adv*. 2021;5(3):872–888. <https://doi.org/10.1182/bloodadvances.2020003763>
7. Pinto DS. COVID-19: Myocardial infarction and other coronary artery disease issues. *UpToDate*. Updated November 24, 2021. Accessed February 1, 2022. https://www.uptodate.com/contents/covid-19-myocardial-infarction-and-other-coronary-artery-disease-issues/print?source=history_widget
8. Levi M, Thachil J, Iba T, Levy JH. Coagulation abnormalities and thrombosis in patients with COVID-19. *Lancet Haematol*. 2020;7(6):e438–e440. [https://doi.org/10.1016/S2352-3026\(20\)30145-9](https://doi.org/10.1016/S2352-3026(20)30145-9)
9. Popovic B, Varlot J, Metzendorf PA, Jeulin H, Goehring F, Camenzind E. Changes in characteristics and management among patients with ST-elevation myocardial infarction due to COVID-19 infection. *Catheter Cardiovasc Interv*. 2021;97(3):E319–E326. <https://doi.org/10.1002/ccd.29114>
10. Cuker A, Peyvandi F. COVID-19: Hypercoagulability. *UpToDate*, 2021. Accessed February 1, 2022. <https://www.uptodate.com/contents/covid-19-hypercoagulability>
11. Nanthatanti N, Phusanti S, Chantrathammachart P, Thammavaranucupt K, Angchaisuksiri P, Sungkanuparph S. Left ventricular thrombus and pulmonary embolism: a case series of thrombosis in COVID-19 in Thai patients. *Res Pract Thromb Haemost*. 2020;4(7):1224–1229. <https://doi.org/10.1002/rth2.12435>
12. Colling ME, Kanthi Y. COVID-19–associated coagulopathy: an exploration of mechanisms. *Vasc Med*. 2020;25(5):471–478. <https://doi.org/10.1177/1358863X20932640>
13. Choudry FA, Hamshere SM, Rathod KS, et al. High thrombus burden in patients with COVID-19 presenting with ST-segment elevation myocardial infarction. *J Am Coll Cardiol*. 2020;76(10):1168–1176. <https://doi.org/10.1016/j.jacc.2020.07.022>
14. Harari R, Bangalore S, Chang E, Shah B. COVID-19 complicated by acute myocardial infarction with extensive thrombus burden and cardiogenic shock. *Catheter Cardiovasc Interv*. 2021;97(5):E661–E666. <https://doi.org/10.1002/ccd.2899>
15. Driggin E, Madhavan MV, Bikdeli B, et al. Cardiovascular considerations for patients, health care workers, and health systems during the COVID-19 pandemic. *J Am Coll Cardiol*. 2020;75(18):2352–2371. <https://doi.org/10.1016/j.jacc.2020.03.031>
16. Writing Committee Members, Lawton JS, Tamis-Holland JE, et al. 2021 ACC/AHA/SCAI Guideline for Coronary Artery Revascularization: a report of the American College of Cardiology/American Heart Association Joint Committee on Clinical Practice Guidelines. *J Am Coll Cardiol*. 2022;79(2):e21–e129. <https://doi.org/10.1016/j.jacc.2021.09.006>

Anna R. Samuel, MSN, ACNP, is a nurse practitioner at Texoma Medical Center, Denison, TX, and can be contacted at samuelannar@yahoo.com

In compliance with standard ethical guidelines, the author reports no relationships with business or industry that would pose a conflict of interest.