

Received: 2017.11.07
Accepted: 2017.11.20
Published: 2018.05.18

Association of Difference in Coronary Sinus Diameter by Computed Tomographic Angiography Between Patients in and Not in Stable Atherosclerotic Plaque(S)

Authors' Contribution:
Study Design A
Data Collection B
Statistical Analysis C
Data Interpretation D
Manuscript Preparation E
Literature Search F
Funds Collection G

AB 1 **Yancui Li**
CD 2 **Wen Liang**
EG 3 **Jianchun Zhang**
EF 1 **Ruchen Peng**

1 Department of Radiology, Beijing Luhe Hospital, Capital Medical University, Beijing, P.R. China
2 Department of Ultrasonography, Beijing Luhe Hospital, Capital Medical University, Beijing, P.R. China
3 Department of Cardiovascular, Beijing Luhe Hospital, Capital Medical University, Beijing, P.R. China

Corresponding Author: Ruchen Peng, e-mail: ruchenpeng@hotmail.com
Source of support: Departmental sources

Background: Pathological finding fail to describe the morphology of coronary arterial plaques. Retrograde cardiac arteriography is a complicated procedure and does not detect all left posterior and marginal veins of the heart. Magnetic resonance angiography has long scan time and low spatial resolution. The objective of the present study was to assess the possible utility of the difference in coronary sinus diameter to quantify stable atherosclerotic plaque(s) using 256-slice coronary computed tomographic angiography.

Material/Methods: A total of 336 patients were divided into 2 groups with 168 patients each. Patients who had heart failure were included in the study group and those who did not were included in the non-study group. Patients were subjected to cross-sectional study. Cardiovascular images were performed with 256-slice coronary computed tomographic angiography with a prospective electrocardiogram and clinical manifestation. Two-tailed paired *t* test following Dunnett's multiple comparison tests was performed for the quantitative measurement of coronary computed tomographic angiography and clinical manifestation at 99% confidence level.

Results: The clinical manifestation did not clearly show cardiac abnormality. The diameters of the superoinferior coronary sinus ostium was than that of the anteroposterior coronary sinus ostium, ($p < 0.0001$, $q = 26.325$). There was the difference in size of the coronary sinus ostium between patients in and not in heart failure ($p < 0.0001$). The study group patients had longer coronary sinuses than patients in the non-study group ($p < 0.0001$).

Conclusions: 256-slice computed tomographic angiography is a feasible and is non-invasive bio-tool for evaluation of coronary artery anatomy.

MeSH Keywords: **Cardiomyopathy, Hypertrophic • Cardiovascular Diseases • Coronary Sinus • Four-Dimensional Computed Tomography • Heart Septal Defects, Atrial**

Full-text PDF: <https://www.medscimonit.com/abstract/index/idArt/907934>

 1787

 4

 5

 34



Background

The stable atherosclerotic cardiovascular plaque is the most common cardiac disease [1]. Currently available techniques for detection of cardiac plaques are: pathological findings such as measurement of serum immunoglobulin 4 (IgG4) [2], alanine aminotransferase, aspartate aminotransferase, and bilirubin [3]. However, the pathology exam fails to evaluate the morphology of plaques [4]. Moreover, thermography [5], intravascular magnetic resonance [6], intravascular ultrasound [7], retrograde coronary sinus angiography [8,9], arterial phase coronary sinus angiography [10], and electron beam CT (computed tomography) [11] are also available for diagnosis. At present, cardiac resynchronization therapy is an important treatment for heart failure patients [12,13].

Retrograde cardiac arteriography is considered the criterion standard for studying cardiac arterial system anatomy. However, the procedure is complicated, congested, and does not fully succeed in outlining the anatomy of the cardiac arterial system [14]. Recent developments in diagnostic technology such as multi-slice CT have successfully shown the evolution of morphology of cardiac plaques [15] and have provided a three-dimensional view of the cardiovascular system [16]. Coronary CT angiography has allowed quantification, partial characterization, and detection of stable atherosclerotic plaques [17].

The objective of the present study was to assess differences in coronary sinus diameter between patients in and not in stable atherosclerotic plaque(s) using 256-slice coronary CT angiography in a Chinese population.

Material and Methods

Material

Metoprolol was purchased from Astrazeneca, Taizhou, Jiangsu, China. The contrast agent (Ioversol Injection) was purchased from Jiangsu Hengrui Medicine Co., Ltd., Jiangsu, China.

Ethics approval and consent to participate

An exemption was granted to the requirement to register the study with the Chinese Clinical Registry by the Central Research Radiological Society of China. The protocol of the study followed STARD 2015 guidelines and the Helsinki Declaration, and was approved by the Ethics Committee of Beijing Luhe Hospital, Capital Medical University, China for radiological research on human subjects. The study was carried out in compliance with the laws of P.R. China. Written informed consent was obtained from all enrolled patients. All subjects signed an informed consent form approved by the Ethics Committee

of Beijing Luhe Hospital, Capital Medical University, China for publication in all formats irrespective of time and language. Data were accessed from patients' DCOIM files of Beijing Luhe Hospital, Beijing, China.

Inclusion criteria

A total of 336 patients older who were 18 years and who were admitted to the Beijing Luhe Hospital, China for treatment of cardiac abnormalities from June 2014 to February 2017 were included in the study. Patients were allocated into 2 groups of 168 patients each. Patients who had heart failure were included in the study group and those who did not have heart failure were included in the non-study group. Patients with stable angina were included in the study group. Patients who had coronary artery diseases, abnormality of the electrocardiogram, or multiple cardiovascular risks(s) quantified by pathology were included in the study group. Patients who had systolic heart failure, reduced ejection fraction, diastolic heart failure, or high left ventricle filling pressures with normal or near-normal ejection fraction characterized by electrocardiogram were included in the study group. Demographic and angiographic parameters of included subjects are reported in Table 1.

Exclusion criteria

Patients who had a previous history of coronary artery interventions, bypass, or graft surgeries were excluded from the study group and non-study group. Patients who had inadequate image quality and ethical issues such as not signing the informed consent form or did not follow protocols were excluded from the study group and non-study group. Patients who had variant angina were excluded from the study group. Patients who had cardiac abnormalities were excluded from the non-study group.

Both groups were subjected to the non-randomized, non-experimental, cross-sectional study. The flowchart of research for patients enrolled in the study group is reported in Figure 1.

Coronary CT angiography method

Cardiovascular images were performed with 256-slice coronary CT angiography (Brilliance iCT, Philips, Cleveland, OH) with a prospective electrocardiogram. The instrument was operated at parameters of 120 kVp tube voltage, 900 mAs product of effective tube current-time, 0.18 pitch, and the detector had 128×0.625 mm configuration and rotation time of 270 ms. Heart rate was maintained at 70 beats/min by Metoprolol before coronary CT angiography. The Agent Ioversol was given in 3 distinct phases as 25 ml (saline), 70–85 ml (contrast agent), 20 ml (saline), and at 5 ml/s [8]. The high pressure injector HSCPF (Ulrich, GmbH&Co, KG, Germany) was used for

Table 1. Demographical and angiographical parameters of subjects.

Characters		Study group (n=168)	Non-study group (n=168)	Multivariate analysis	
				p Value	q Value
Gender	Male	92 (55)	89 (53)	0.0833	N/A
	Female	76 (45)	79 (47)		
Age (years)		50.71±9	50.47±7.86	0.8004	N/A
BMI(kg/m ²)		30.04±3.74	29.76±3.14	0.4745	N/A
Heart rate (bpm)		62.7±3.28	61.93±2.85	0.0243	N/A
Hypertension		89 (53)	5 (3)	<0.0001	14.286*
Dyslipidemia		88 (52)	7 (4)	<0.0001	13.298*
Diabetes		73 (43)	15 (9)	<0.0001	8.551*
Smoking status	Current smoker	30 (18)	7 (4)	<0.0001	6.881*
	Former smoker	40 (24)	12 (7)		
	No smoker	98 (58)	149 (89)		
Psychological stress		47 (28)	7 (4)	<0.0001	7.104*
Alcohol intake		26 (15)	3 (2)	<0.0001	5.32*

Categorical data were presented as Number (Percentage) and continuous data were presented as a mean ±SD. Two-tailed paired *t*-test following Dunnett's multiple comparison tests was used for statistical analysis. A $p < 0.01$ and $q > 4.145$ were considered as significant. N/A – not applicable. * Significant difference.

the ascending aorta to mark a region of interest (ROI) for the study. The ROI was focused on the chosen area of the coronary artery [18]. For aorto-pulmonary fenestration level, the scans were started 5 s after the attenuation of the signal at 130 HU (Hounsfield units) threshold [19]. Volume-rendered reconstructions was adopted for evaluation of anterior vein of inter-ventricle, posterior left ventricular vein, posterior vein of inter-ventricle, and the left vein of margin. In the crux cordis area, the angle that makes the coronary sinus to the right atrium is considered as 'ostium'. The diameter of the ostium of the coronary sinus in superoinferior and anteroposterior sides was detected by multiplanar reformatting. The initial diameter of the tributary was measured. The axial images were measured by the ostium. The length of tributaries, the ostium-to-tributaries distance, and the angle between the coronary sinus and the tributaries were measured [20]. The diameter of the plaque was calculated as the ratio of the smallest diameter of the lumen to the lumen diameter of the reference. Obstructive atherosclerotic cardiovascular disease was considered to be present if the contrast-enhanced lumen was narrowed to less than 50%. Symptoms and pathological finding of enrolled patients were also recorded.

Statistical analysis

The 2-tailed paired *t* test ($\alpha=0.01$ and $\beta=0.1$ for both tails) [21] following Dunnett's multiple comparison tests (considering critical value [q] > 4.145 as significant) [22] was performed for demographical and angiographical characteristics, the quantitative measurement of 256-slice coronary CT, and clinical manifestation. The Mann-Whitney *U* test [23] following Dunnett's multiple comparison tests (considering $q > 4.145$ as a significant level) [22] was performed to show that hypertension, dyslipidemia, and diabetes had higher chances of stable angina in study group patients. The statistical analysis was performed using InStat, GraphPad, Inc., US. The results were considered significant at 99% of the confidence level.

Results

Clinical electrocardiogram, the estimated glomerular filtration rate, blood cholesterol levels, and the other clinical data of study group patients indicated a stable atherosclerotic plaque in the study group subjects (Table 2).

The diameters of the superoinferior coronary sinus ostium was larger as compared to the anteroposterior coronary sinus ostium (Figure 2, $p < 0.0001$, $q = 26.325$). There was a difference

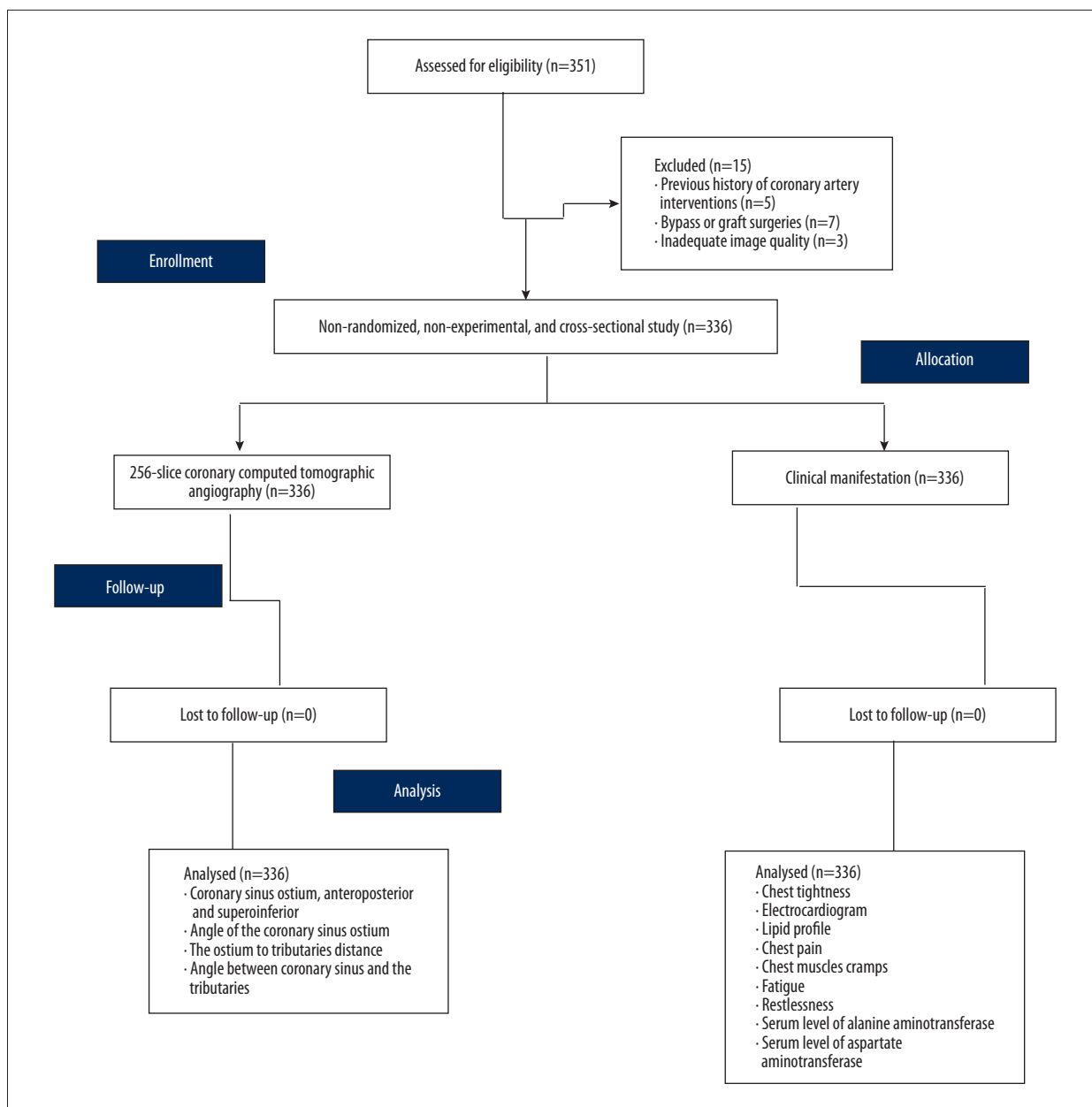


Figure 1. Flowchart of the non-randomized, non-experimental, and cross-sectional study of the enrolled patients.

in size of the coronary sinus ostium between patients in and not in stable atherosclerotic plaque ($p < 0.0001$). The angle for the coronary sinus to the tributaries were the same between groups. The quantitative measurement of 256-slice coronary CT is reported in Table 3.

Percentage prevalence of arterial plaque characteristics showed that hypertension (Figure 3, $p = 0.0041$, $q = 5.471$), dyslipidemia (Figure 4, $p = 0.0045$, $q = 4.982$), and diabetes (Figure 5, $p = 0.0038$, $q = 5.876$) had higher chances of stable angina in study group patients. Clinical manifestation of study group patients did not clearly show cardiac abnormality (Table 4).

Discussion

The present study compared quantitative coronary characteristics of study group patients to non-study group patients using 256-slice coronary CT angiography with a prospective electrocardiogram. At present, studies are available with 4-slice [24], 16-slice [8,15], 64-slice [25,26], 128-slice CT [27], and 320-slice [28] coronary CT angiography with a prospective electrocardiogram to compare quantitative coronary characteristics. Four-slice CT gives comparatively poor image quality [29], 256-slice CT gives more stable and significantly improved image quality at the same effective radiation dose as

Table 2. Clinical electrocardiogram, the estimated glomerular filtration rate, blood cholesterol levels of subjects.

Characters	Study group (n=168)	Non-study group (n=168)	Multivariate analysis		
			p Value	q Value	
eGFR (mL/min/1.73 m ²)	67.89±4.37	72.64±4.59	<0.0001	9.636*	
LDL (mg/dL)	110.02±3.15	102.5±2.3	<0.0001	26.364*	
HDL (mg/dL)	58.96±6.32	63.63±7.13	<0.0001	6.23*	
Triglyceride (mg/dL)	118.93±21.25	115.21±25.09	0.1182	N/A	
IgG4 (mg/dL)	37.5±12.16	31.82±12.65	<0.0001	4.168*	
Epicardial fat volume (mL)	108.07±17.47	83.46±12.25	<0.0001	15.889*	
Conditions of electrocardiogram	ST-segment depression	33 (20)	2 (1)	<0.0001	18.989*
	ST-segment elevation	31 (18)	2 (1)		
	T-wave inversion	29 (17)	2 (1)		
	Flattening of T-waves	22 (13)	2 (1)		
	Large Q-wave	26 (15)	2 (1)		
	Reduced R-wave	17 (10)	2 (1)		
	Normal	10 (7)	156 (94)		

Categorical data were presented as Number (Percentage) and continuous data were presented as a mean ±SD. eGFR – estimated glomerular filtration rate; LDL – low-density lipoprotein; HDL – high-density lipoprotein; IgG4 – Immunoglobulin G4. Two-tailed paired *t*-test following Dunnett’s multiple comparison tests was used for statistical analysis. A *p*<0.01 and *q*>4.145 were considered as significant. N/A – not applicable. * Significant difference.

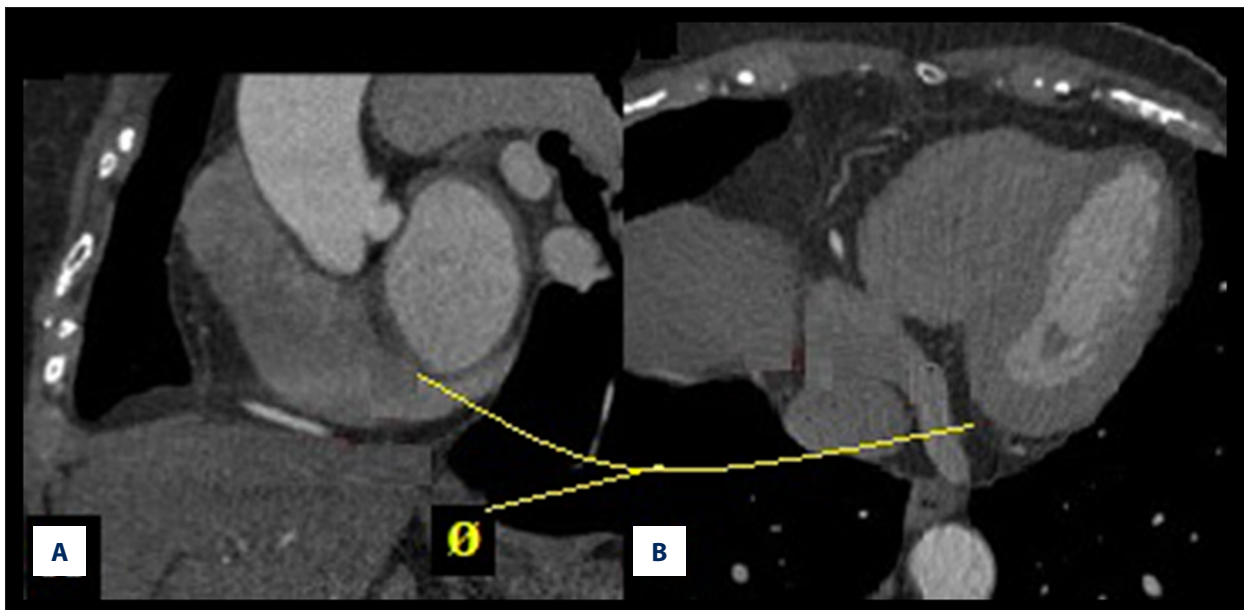


Figure 2. Coronary sinus diameter of study group patient. (A) Coronary sinus ostium, superoinferior, ϕ : 0.99±0.14 cm. (B) Coronary sinus ostium, anteroposterior, ϕ : 0.66±0.1 cm. ϕ : diameter. The diameters of coronary sinus ostium, superoinferior was larger as compared to coronary sinus ostium, anteroposterior (*p*<0.0001, *q*=26.325). The Mann-Whitney *U* test following Dunnett’s multiple comparison tests was used for statistical analysis. A *p*<0.01 and *q*>4.145 were considered as significant.

Table 3. Quantitative measurement Coronary computed tomographic angiography method.

Characters	Study group (n=168)	Non-study group (n=168)	p Value	q Value	
Diameter (cm)	Coronary sinus ostium, anteroposterior	0.82±0.07	0.66±0.1	<0.0001	16.475
	Coronary sinus ostium, superoinferior	1.08±0.13	0.99±0.14	<0.0001	5.581
	PVIV	0.66±0.1	0.5±0.13	<0.0001	12.568
	PLVV	0.49±0.06	0.31±0.05	<0.0001	28.783
	LVM	0.47±0.05	0.29±0.04	<0.0001	41.782
	AVIV	0.5±0.07	0.33±0.04	<0.0001	27.257
θ of the coronary sinus ostium (°)	68.86±5.43	60.91±4.87	<0.0001	14.131	
Length (cm)	PVIV	3.67±0.47	3.33±0.45	<0.0001	6.471
	PLVV	2.68±0.41	2.31±0.45	<0.0001	6.123
	LVM	2.42±0.49	2.25±0.44	<0.0001	3.287*
	AVIV	4.5±0.5	4.25±0.43	0.0001	4.892
The ostium to tributaries distance	PVIV	0.48±0.04	0.42±0.04	<0.0001	10.923
	PLVV	3.25±0.43	3.125±0.33	<0.0001	2.969*
	LVM	6.76±0.43	6.63±0.48	0.0049	2.633*
	AVIV	10.1±0.29	9.8±0.4	<0.0001	7.653
θ between coronary sinus and the tributaries (°)	PVIV	86.45±13.45	83.44±12.06	0.0292	2.16*
	PLVV	109.61±13.92	105.54±12.22	0.0008	2.862*
	LVM	121.64±17.88	119.66±16.48	0.1463	1.06*
	AVIV	130.42±9.91	134.04±11.46	0.0022	3.101*

PVIV – posterior vein of internal ventricle; PLVV – posterior left ventricular vein; LVM – left vein of margin; AVIV – anterior vein of internal ventricle; θ – angle. Data were represented as mean ±SD. The Mann-Whitney U test following Dunnett’s multiple comparison tests was used for statistical analysis. $p < 0.01$ and $q > 4.145$ were considered as significant. * Insignificant value.

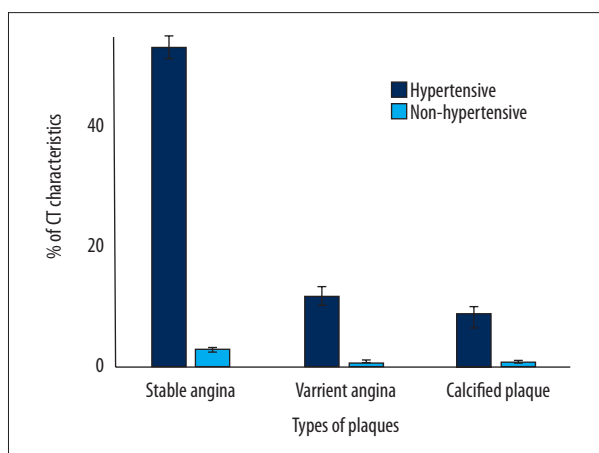


Figure 3. Percentage prevalence of arterial plaque characteristics for hypertension in study group subjects. Data are represented as mean ±SD. n=168. Hypertension had higher chances of stable angina ($p=0.0041$, $q=5.471$). The Mann-Whitney U test following Dunnett’s multiple comparison tests was used for statistical analysis. A $p < 0.01$ and $q > 4.145$ were considered as significant.

16-slice, 64-slice, and 128-slice CT [26], but 320-slice CT has a risk of development of radiation-induced malignancy [30]. With reference to the latest generation multi-slice CT, the method used in the study had reduced scanning time, breath-holding time, and dose of radiation.

There were 2 major findings of the current study. First, the angle of the coronary sinus ostium was greater in study group patients than in non-study group patients. Second, ostium

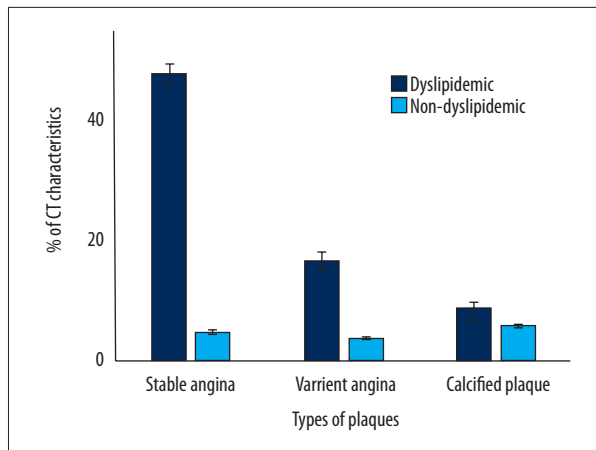


Figure 4. Percentage prevalence of arterial plaque characteristics for dyslipidemia in study group subjects. Data are represented as mean \pm SD. n=168. Dyslipidemia had higher chances of stable angina ($p=0.0045$, $q=4.982$). The Mann-Whitney U test following Dunnett's multiple comparison tests was used for statistical analysis. A $p<0.01$ and $q>4.145$ were considered as significant.

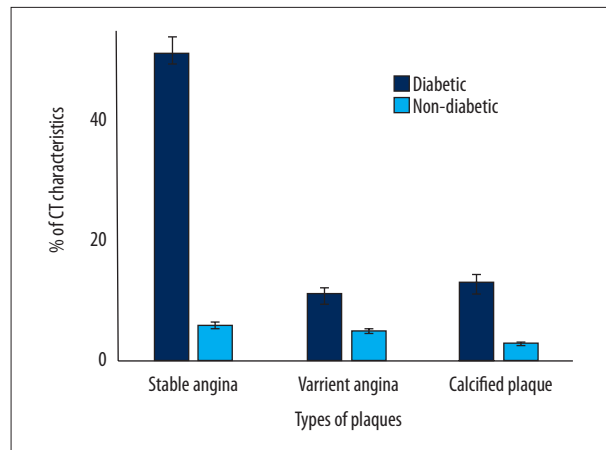


Figure 5. Percentage prevalence of arterial plaque characteristics for diabetes in study group subjects. Data are represented as mean \pm SD. n=168. Diabetes had higher chances of stable angina ($p=0.0038$, $q=5.876$). The Mann-Whitney U test following Dunnett's multiple comparison tests was used for statistical analysis. A $p<0.01$ and $q>4.145$ were considered as significant.

Table 4. Clinical manifestation of the enrolled patients.

Characters	Study group (n=168)	Non-study group (n=168)	p Value	q Value
Chest tightness	45 (27)	3 (2)	<0.0001	7.01
Suspected Cardiological abnormal	105 (63)	7 (4)	<0.0001	14.436
Abnormal lipid profile	69 (41)	8 (5)	<0.0001	8.799
Weight loss	8 (5)	2 (1)	0.0139	1.937*
Chest pain	22 (13)	6 (4)	<0.0001	3.282*
Chest muscles cramps	11 (7)	1 (1)	0.0014	3.005*
Physicians opinion referred for radiology	145 (86)	39 (23)	<0.0001	19.245
Fatigue	56 (33)	23 (14)	<0.0001	4.549
Restlessness	41 (24)	3 (2)	<0.0001	6.571
Abnormal serum level of alanine aminotransferase	49 (29)	2 (1)	<0.0001	7.817
Abnormal serum level of aspartate aminotransferase	63 (38)	3 (2)	<0.0001	11.763

Data were represented as a number (percentage). For statistical analysis, the presence of clinical symptom was considered as 1 and absence were considered as 0. The Mann-Whitney U test following Dunnett's multiple comparison tests was used for statistical analysis. A $p<0.01$ and $q>4.145$ were considered as significant. * Insignificant value.

diameter of tributaries was significantly larger in study group patients than in non-study group patients. Previous studies have shown that contrast-enhanced whole-heart coronary arteries have normal and variant anatomy [31]. In respect to the method used (CT), the result was superior to non-invasive evaluation technique.

The 256-slice coronary CT angiography with a prospective electrocardiogram is non-invasive, has higher imaging success rate, faster rotation time, and larger detector coverage. Cardiac arteriography is considered the criterion standard, but is invasive, technically complicated, risks coronary sinus trauma, has longer breath-holding time, and requires a much higher

volume of contrast agent [32]. Magnetic resonance angiography (MRA) is also non-invasive and does not require contrast material [14]. However, MRA has high scan time and low spatial resolution [19]. IgG4 [33], alanine aminotransferase, aspartate aminotransferase, and bilirubin activation be involved in cardiovascular diseases. However, it is not clear that patients with stable atherosclerotic plaque(s) have always higher IgG4 [2], alanine aminotransferase, aspartate aminotransferase, and bilirubin [3] levels than normal patients. In relation to the method used, the present study provided good guidance regarding diagnosis modality implantation.

The 256-slice coronary CT angiography with a prospective electrocardiogram provides a better visualization of coronary sinus angiography with no effect of contrast agent on patients after radiotherapy. Retrograde coronary sinus angiography does not detect all left posterior and marginal veins [8]. Small cardiac veins that directly drain into the atrium are not detected by retrograde coronary sinus angiography [34]. In respect to the method of the study, the findings provided a better overview, which is necessary for detection of stable atherosclerotic cardiovascular disease.

Percentage prevalence of arterial plaque characteristics showed that hypertension, dyslipidemia, and diabetes had higher chances of stable angina in study group patients. These data were in line with results of another available study [1].

References:

- Sakamoto A, Ishizaka N, Imai Y et al: Relationship between serum IgG4 concentrations and atherosclerotic coronary plaques assessed by computed tomographic angiography. *J Cardiol*, 2016; 67: 254–61
- Sakamoto A, Ishizaka N, Saito K et al: Serum levels of IgG4 and soluble interleukin-2 receptor in patients with coronary artery disease. *Clin Chim Acta*, 2012; 413: 577–81
- Kang SJ, Kim D, Park HE et al: Elevated serum bilirubin levels are inversely associated with coronary artery atherosclerosis. *Atherosclerosis*, 2013; 230: 242–48
- Oka T, Yamamoto H, Ohashi N et al: Association between epicardial adipose tissue volume and characteristics of non-calcified plaques assessed by coronary computed tomographic angiography. *Int J Cardiol*, 2012; 161: 45–49
- Toutouzias K, Drakopoulou M, Mitropoulos J et al: Elevated plaque temperature in non-culprit *de novo* atheromatous lesions of patients with acute coronary syndromes. *J Am Coll Cardiol*, 2006; 47: 301–6
- Wilensky RL, Song HK, Ferrari VA: Role of magnetic resonance and intravascular magnetic resonance in the detection of vulnerable plaques. *J Am Coll Cardiol*, 2006; 47: C48–56
- Sano K, Kawasaki M, Ishihara Y et al: Assessment of vulnerable plaques causing acute coronary syndrome using integrated backscatter intravascular ultrasound. *J Am Coll Cardiol*, 2006; 47: 734–41
- Knackstedt C, Muhlenbruch G, Mischke K et al: Imaging of the coronary venous system in patients with congestive heart failure: Comparison of 16 slice MSCT and retrograde coronary sinus venography: Comparative imaging of coronary venous system. *Int J Cardiovasc Imaging*, 2008; 24: 783–91
- De Martino G, Messano L, Santamaria M et al: A randomized evaluation of different approaches to coronary sinus venography during biventricular pacemaker implants. *Europace*, 2005; 7: 73–76
- Mischke K, Knackstedt C, Muhlenbruch G et al: Imaging of the coronary venous system: Retrograde coronary sinus angiography versus venous phase coronary angiograms. *Int J Cardiol*, 2007; 119: 339–43
- Mao S, Shinbane JS, Girsky MJ et al: Coronary venous imaging with electron beam computed tomographic angiography: Three-dimensional mapping and relationship with coronary arteries. *Am Heart J*, 2005; 150: 315–22
- Bank AJ, Gage RM, Olshansky B: On the underutilization of cardiac resynchronization therapy. *J Card Fail*, 2014; 20(9): 696–705
- Sutton MG, Plappert T, Hilpisch KE et al: Sustained reverse left ventricular structural remodeling with cardiac resynchronization at one year is a function of etiology: quantitative Doppler echocardiographic evidence from the Multicenter InSync Randomized Clinical Evaluation (MIRACLE). *Circulation*, 2006; 113: 266–72
- Ma H, Tang Q, Yang Q et al: Contrast-enhanced whole-heart coronary MRA at 3.0T for the evaluation of cardiac venous anatomy. *Int J Cardiovasc Imaging*, 2011; 27: 1003–9
- Motoyama S, Kondo T, Sarai M et al: Multislice computed tomographic characteristics of coronary lesions in acute coronary syndromes. *J Am Coll Cardiol*, 2007; 50: 319–26
- Helm RH, Byrne M, Helm PA et al: Three-dimensional mapping of optimal left ventricular pacing site for cardiac resynchronization. *Circulation*, 2007; 115: 953–61
- Achenbach S: Computed tomography coronary angiography. *J Am Coll Cardiol*, 2006; 48: 1919–28

Conclusions

We found that 256-slice coronary computed tomographic angiography is a non-invasive bio-tool for evaluation of coronary artery anatomy, and it has diagnostic applications such as predicting stable atherosclerotic cardiovascular disease.

Acknowledgements

The authors are thankful for all teaching, medical, and non-medical staff of the Beijing Luhe Hospital, Capital Medical University, PR China for their kind help during research work and for ensuring study success.

Conflict of interests

None.

18. Hahn J, Bruder H, Rohkohl C et al: Motion compensation in the region of the coronary arteries based on partial angle reconstructions from short-scan CT data. *Med Phys*, 2017; 44(11): 5795–813
19. Sun C, Pan Y, Wang H et al: Assessment of the coronary venous system using 256-slice computed tomography. *PLoS One*, 2014; 9(8): e104246
20. Ma H, Wang X, Xie H et al: Characterization of the cardiac venous system in heart failure patients using 256-slice CT. *Int J Cardiol*, 2016; 203: 447–48
21. Gao Z, Cui F, Cao X et al: Local infiltration of the surgical wounds with levobupivacaine, dexibuprofen, and norepinephrine to reduce postoperative pain: A randomized, vehicle-controlled, and preclinical study. *Biomed Pharmacother*, 2017; 92: 459–67
22. Padmanabhan P, Das J, Kumari RV et al: Comparative evaluation of apical microleakage in immediate and delayed post space preparation using four different root canal sealers: An *in vitro* study. *J Conserv Dent*, 2017; 20: 86–90
23. Schirinzi T, Di Lazzaro G, Sancesario GM et al: Levels of amyloid-beta-42 and CSF pressure are directly related in patients with Alzheimer's disease. *J Neural Transm (Vienna)*, 2017; 124(12): 1621–25
24. Leber AW, Knez A, Becker C et al: Non-invasive intravenous coronary angiography using electron beam tomography and multislice computed tomography. *Heart*, 2003; 89: 633–39
25. Van de Veire NR, Schuijff JD, De Sutter J et al: Non-invasive visualization of the cardiac venous system in coronary artery disease patients using 64-slice computed tomography. *J Am Coll Cardiol*, 2006; 48: 1832–38
26. Klass O, Walker M, Siebach A et al: Prospectively gated axial CT coronary angiography: Comparison of image quality and effective radiation dose between 64- and 256-slice CT. *Eur Radiol*, 2010; 20: 1124–31
27. Russo V, Garattoni M, Buia F et al: 128-slice CT angiography of the aorta without ECG-gating: Efficacy of faster gantry rotation time and iterative reconstruction in terms of image quality and radiation dose. *Eur Radiol*, 2016; 26(2): 359–69
28. Saremi F, Cen S, Tayari N et al: A correlative study of aortic valve rotation angle and thoracic aortic sizes using ECG gated CT angiography. *Eur J Radiol*, 2017; 89: 60–66
29. Sabarudin A, Sun Z, Ng KH: A systematic review of radiation dose associated with different generations of multidetector CT coronary angiography. *J Med Imaging Radiat Oncol*, 2012; 56: 5–17
30. Sun Z: Multislice CT angiography in coronary artery disease: Technical developments, radiation dose, and diagnostic value. *World J Cardiol*, 2010; 2: 333–43
31. Ma H, Liu J, Wang B et al: "One-stop-shop" cardiac MRI at 3.0T for the detection of coronary artery disease. *Int J Cardiol*, 2012; 160: e21–22
32. Arbelo E, Garcia-Quintana A, Caballero E et al: Usefulness of hyperemic venous return angiography for studying coronary venous anatomy prior to cardiac resynchronization device implantation. *Rev Esp Cardiol*, 2008; 61: 936–44
33. Kasashima S, Zen Y: IgG4-related inflammatory abdominal aortic aneurysms. *Curr Opin Rheumatol*, 2011; 23: 18–23
34. Wei Y, Xie P, Pang W et al: The relationship between the coronary sinus and coronary artery using multi-slice spiral computed tomography and conventional invasive angiography. *Int J Cardiol*, 2009; 137: 276–81