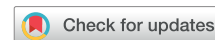



Original Research

Malar reshaping technique using bidirectional barb thread suspension procedure for 3-dimensional aging in Asian faces

Kwun Cheung Hau MBChB, MRCP, FHKCP, FHKAM, DCH^{a,*}, Suyog Jain MD^b^a Asian Medical Experts Academy, Dermatology and Minimally Invasive Aesthetic Surgery, Central, Hong Kong^b Medical Affairs, Menarini Asia-Pacific, Singapore

ARTICLE INFO

Article history:

Received 19 December 2020

Revised 16 July 2021

Accepted 4 August 2021

Keywords:

Aging
 malar reshaping technique
 suspension-barbed threads
 3-dimensional facial rejuvenation
 global aesthetic improvement scale
 Definissee

ABSTRACT

Background: Aging is a natural process that causes skin texture changes, facial volume loss, and altered 3-dimensional topography of the underlying tissues.

Objective: The aim of this study is to assess the malar reshaping strategy in Asian patients using bidirectional suspension-barbed threads.

Methods: A prospective interventional study was conducted on Asian patients presenting with mild-to-moderate facial aging who were treated with the Definissee double-needle thread in the Hong Kong Special Administrative Region. The primary endpoint was assessed using the Global Aesthetic Improvement Scale and scoring the benefit of anterior projection using a questionnaire. Patient safety was the secondary endpoint measured.

Results: Twenty Asian patients (4 men [20%] and 16 women [80%]; age <45 to ≥45 years) were included in the study. The patients experienced marked improvement (score 2) in their appearance, except for the follow-up after 1 month. One month after the procedure, patients scored 1 for optimal cosmetic improvement in their looks. The nasolabial fold disappeared in all patients (n=20 [100%]) and the face looked slimmer. Nine patients (45%) reported that the focus seemed centralized. Four patients (20%) reported prominence of the nose and chin. Redness, swelling, and bruising were the most common adverse events experienced by 75% of patients (n=15), followed by pain (n=6; 30%). All adverse events resolved within 4 weeks after their incidence. Because 80% of our patients were women, these positive cosmetic outcomes may be of interest across the aging female population.

Conclusion: Overall, 3-dimensional facial rejuvenation with the Definissee thread seems to be an effective, safe, and minimally invasive office-based procedure to achieve immediate and long-term effects. These absorbable barbed sutures used in the malar reshaping technique can result in satisfactory esthetic enhancement of 3-dimensional aging, including sagginess, jowling, central facial heaviness, and tissue descent in female and male Asian patients.

© 2021 The Author(s). Published by Elsevier Inc. on behalf of Women's Dermatologic Society.

This is an open access article under the CC BY-NC-ND license

(<http://creativecommons.org/licenses/by-nc-nd/4.0/>)

* Corresponding Author:

E-mail address: drkchauhongkong@gmail.com (K.C. Hau).

What is known about this subject in regard to women and their families?

- The process of aging and its results are different in Asian faces compared with Caucasian faces; therefore, treatment needs individualization.
- Barb threads are effective in mild-to-moderate facial aging with the malar reshaping technique.
- Limited published evidence exists on the efficacy and safety of the bidirectional barb thread suspension procedure in female Asian patients.

What is new from this study as messages for women and their families?

- This is one of the first prospective studies in female Asian patients.
- The results substantiate the effectiveness of the malar reshaping technique using bidirectional barb thread for esthetic enhancement in the Asian face.
- The use of this minimally invasive procedure by itself or in combination with other procedures should be encouraged to achieve desired outcomes.

Introduction

Aging is a natural process that involves factors of intrinsic (genetic and epigenetic) and external origin (nutrition, radiation, temperature, and stress) and gradually deteriorates the organs/organ systems in an organism (Jayanthi et al., 2010). The skin also ages like the organism itself, and this is an inevitable process (Kohl et al., 2011). The aging phenomenon affects the skin in numerous ways, and the molecular mechanisms involved mainly include oxidative stress, DNA damage, shortening of telomeres, dysregulation of miRNA, accumulation of advanced glycation end product, mutation in genes, and inflammation (Makrantonaki and Zouboulis, 2007; Zhang and Duan, 2018). Skin aging results in phenotypic, structural, and functional changes in the skin (Fig. 1; Zhang and Duan, 2018).

Aging: Effect on skin

In addition to intrinsic aging, exposed skin also undergoes extrinsic aging. Combined, these lead to phenotypic modifications in cutaneous cells coupled with structural and functional alterations in collagen, elastin, oligosaccharides, and proteoglycans, which are responsible for the tensile strength, elasticity, water retention, and hydration of the skin, respectively (Mora Huertas et al., 2016; Zhang and Duan, 2018).

Intrinsic skin aging is an inevitable chronological functional process that is characterized by cellular senescence (defined as reduced proliferation of keratinocytes, fibroblasts, and melanocytes cells in the basal cell layer), resulting in a thinner epidermis, decreased contact surface area between the dermis and epidermis, smaller exchange surface for nutrition supply to the epidermis, and further weakened ability of basal cell proliferation (Makrantonaki and Zouboulis, 2007; Moragas et al., 1993; Zhang and Duan, 2018). Aged skin also produces type I procollagen in lesser amount due to the downregulation of the transforming growth factor-beta/Smad signaling and its downstream connective tissue growth factor (Quan et al., 2010).

Approximately 80% of skin aging occurs due to exposure to ultraviolet radiation (Flament et al., 2013). Ultraviolet rays make the epidermis, especially the stratum corneum, thick as it fails to degrade corneocyte desmosomes. The expression of the differentiation marker involucrin in the stratum corneum and elastin is increased, as is that of cell-surface protein beta 1-integrin in basal

cells and types VII and I collagen in keratinocytes decrease (Zhang and Duan, 2018).

Three-dimensional perspective to facial aging

Various changes occur in the skin during aging, including reduction in fat volume and bone support, sagging of the skin, reduction in the skin's elasticity and thickness, accentuation of folds and ridges (mainly affected areas are nasolabial fold, labiomandibular fold, and malar mound), and the degeneration of the soft tissue-supporting ligaments (Palermo et al., 2019; Weinkle and Saco, 2017). Apart from the superficial signs of aging, such as textural changes in the skin and facial volume loss, there is also an altered 3-dimensional topography of the underlying structures, including soft tissues (subcutaneous fat, muscle, and fascia) and structural support (bones and teeth; Fig. 2). Many facial manifestations of aging reflect the combined effects of gravity, progressive bone resorption, decreased tissue elasticity, and redistribution of subcutaneous fullness (Fig. 3).

To assess the signs of aging, the face is divided into three parts (upper, middle, and lower part), among which the midface is of high importance in terms of esthetic approach. The midface includes the eyes, nose, lips, and cheek bones and therefore requires a 3-dimensional perspective of assessment of aging signs with the aim to restore a youthful 3-dimensional facial topography (Coleman and Grover, 2006).

Aging: Various treatment options and the 3-dimensional approach

There are various treatment options to help fight against skin aging, including antioxidants, stem cell therapy, and retinoids (Table 1; Ganceviciene et al., 2012; Zhang and Duan, 2018). Recently, an esthetic approach is being used where a 3-dimensional strategy is gaining popularity, because the approach uses nonsurgical procedures. This 3-dimensional approach aims to relax facial expression muscles, correct skin folds, replace lost volume,

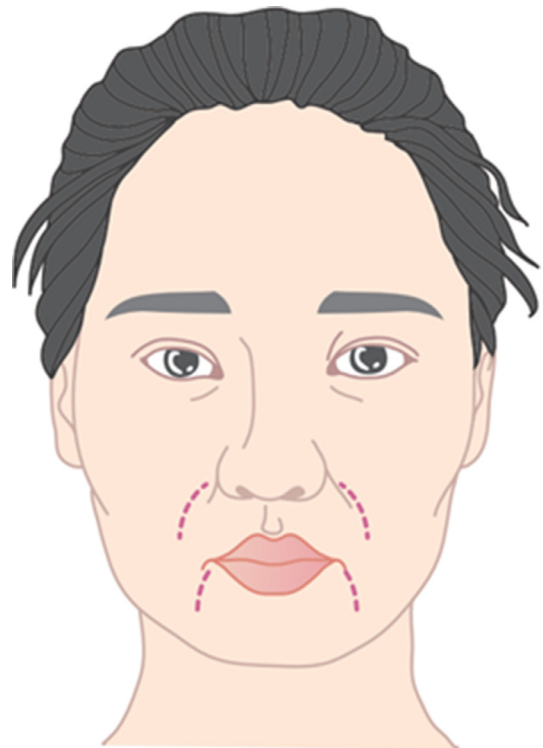

Fig. 1. Aging patterns in Caucasian and Asian skin.

Table 1
Various treatment options for aging skin

Anti-aging strategies	Treatment options	
Nonpharmacological therapies		
Self/noninvasive cosmetologic regime	<ul style="list-style-type: none"> • Daily skin care • Correct sun protection 	
Pharmacologic therapies		
Antioxidants	<ul style="list-style-type: none"> • Vitamin (B3, C, and E) • Ferulic acid • Antioxidative enzymes (superoxide dismutase, catalase, glutathione peroxidase, and coenzyme Q10) • Plant sources (green tea and aloe vera) • Phytocompounds (epigallocatechin gallate, <i>N</i>-acetylcysteine) 	
Stem cell therapy	<ul style="list-style-type: none"> • Adipose tissue transplantation • Increasing skin volume • Adipose-derived stem cells • Autologous fat grafting 	
Retinoids	<ul style="list-style-type: none"> • Chemically similar to vitamin A • Topical application of tretinoin 	
Hormone replacement therapy	<ul style="list-style-type: none"> • Hormone use to improve skin thickness, collagen content, and elasticity and enhance hydration • Increase breast cancer risk 	
Telomere modification	<ul style="list-style-type: none"> • Reverse skin aging by high-level expression of telomerase reverse transcriptase in skin fibroblasts and keratinocytes • Increase risks of epidermal carcinogenesis 	
Lifestyle modifications		
Diet restriction	Dos	Don'ts
	<ul style="list-style-type: none"> • Low-sugar food cooked with water (to reduce intake of preformed exogenous advanced glycation ends and endogenous production of physiologically glycosylated proteins) • Intake of culinary herbs and spices (cinnamon, cloves, oregano, and allspice) • Consumption of ginger, garlic, alpha-lipoic acid, carnitine, taurine, carnosine, flavonoids (e.g., green tea catechins), benfotiamine, alpha-tocopherol, niacinamide, pyridoxal, sodium selenite, selenium yeast, riboflavin, zinc, and manganese) 	<ul style="list-style-type: none"> • Smoking • Pollution • Solar ultraviolet irradiation • Stress • Malnutrition • No physical activity
Cosmetologic invasive procedures	<ul style="list-style-type: none"> • Chemical peelings • Visible light devices • Intense pulsed light • Ablative and nonablative laser photorejuvenation • Radiofrequency • Injectable skin biostimulation and rejuvenation 	

and treat the contours of the face, such as the temple, zygoma, mandible, nose, and chin (Palermo et al., 2019). The most common nonsurgical tools used for face rejuvenation are dermal fillers, Botulinum toxin, radiofrequency, mesotherapy, and cosmetic camouflage. However, these tools have disadvantages/drawbacks that restrict their use (Table 2; El-Domyati et al., 2012; Kalra, 2008).

Face volume repositioning and tissue support via thread: A better 3-dimensional approach for face rejuvenation

In comparison with other nonsurgical methods of face rejuvenation, the 3-dimensional aging signs can be relieved using a

Table 2
Disadvantages of most common nonsurgical tools for face rejuvenation

Nonsurgical procedures	Disadvantages
Botulinum toxin Fillers	Temporary results that last for 3 months Limited role because they provide limited volume and give temporary results lasting for only 1 to 2 years
Radio frequency	Limited role because only treat superficial wrinkles
Mesotherapy	No benefits on skin aging, mild improvement seen after long-term treatment
Cosmetic camouflage	Temporary change

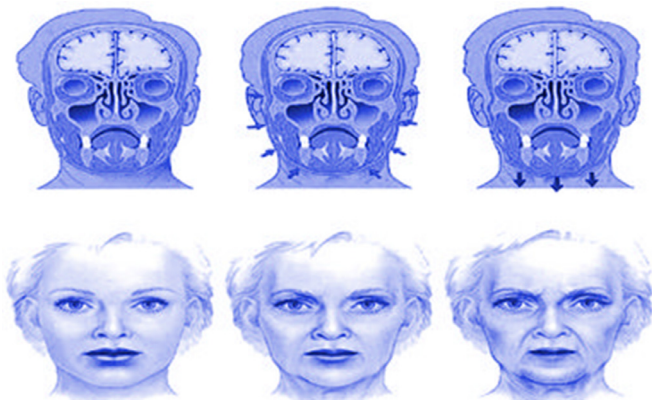


Fig. 2. Three-dimensional topography of underlying structure of skin. There is a reduction/loss of facial fullness as a sign of aging. Left face is a young face in which facial fullness masks subcutaneous fat deposits. As aging occurs, there is a progressive loss of facial fullness, and subcutaneous fat deposits and underlying soft tissue and skeletal structures become more prominent (center and right face; Coleman, 2004).

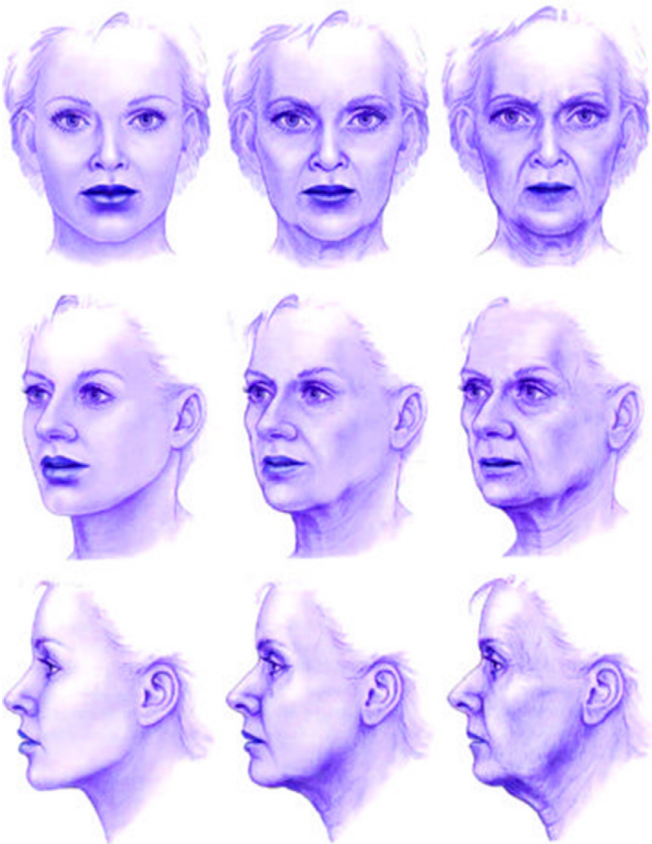

Fig. 3. Aging of female face. Representation of aging of a female face (left: ~20 years of age; center: ~50 years of age; right: ~75 years of age) due to loss of facial volume, involution, and eventual decline of soft tissues (Coleman, 2004).

thread lift. It is the fourth most used procedure globally (Kacey, 2019). The thread helps to lift the skin and has a long-lasting effect (Kalra, 2008). Threads can be barbed or smooth, and the barbed sutures can be unidirectional or bidirectional. Based on the types, there are various designs used in esthetic procedures, such as free-floating, bidirectional barbed sutures, unidirectional barbed sutures, anchored, and bidirectional double-threaded sutures (Kacey, 2019).

Table 3

Various approaches for facial reshaping using Definisse threads

Techniques	Role in esthetics
Jawline reshaping	Correction of the defects of jawline due to inferior jowl fat ptosis
Malar reshaping	Lifting the malar fat pad laterally
Lateral reshaping	Lifting the midface and lower face fat compartment laterally, combining the actions of previous techniques
Oval reshaping	Lifting the central and medial fat compartments of the cheek vertically

Thread lifting has been used since the 1990s (Sulamanidze et al., 2002); however, due to adverse events (AEs) associated with the use of nonabsorbable threads (including polypropylene-barbed threads), such as extrusion and migration, thread expulsion, dimpling, granuloma formation, and prolonged pain, the U.S. Food and Drug Administration withdrew its approval of the use of contour thread esthetic procedures in 2009 (Bernard et al., 2017). This withdrawal led to the emergence of absorbable threads made from polydioxanone and poly-L-lactic acid (Ali, 2018).

Barbed suspension threads can be an alternative option to surgery because the thread procedure is safe, minimally invasive, and an office-based technique. Barbed suspension threading is associated with lower risks and involves less downtime (Kacey, 2019). The evolution of barbed threads has been described in previous publications (Matarasso and Paul, 2013; Matarasso and Ruff, 2013; Wu, 2014). This progress has been followed by the development of various types of barbed sutures for esthetic use (Matarasso and Paul, 2013; Matarasso and Ruff, 2013; Wu, 2014). Although threads are considered a safe choice for superficial fat repositioning, this procedure often needs to be accompanied by other procedures for volume restoration (Wong, 2021). Moreover, in cases possessing a high fat volume or when superficial muscular aponeurotic system (SMAS) quality is impaired due to aging, repositioning with suspension threads may have limited effects (Wong, 2021).

Barbed threads: A focus on bidirectional threads

Numerous designs and modifications have been deployed to obtain the thread of choice. The major difference between bidirectional and unidirectional barbed threads is that the bidirectional threads have no anchoring points whereas unidirectional threads are anchored at a higher level fixation point (Kalra, 2008).

Bidirectional barbed threads are mainly used to lift the cheek area (Kalra, 2008). They can facilitate improved mechanical action in the two opposite directions between the barbs due to antagonistic traction. Moreover, their interaction with tissues or the biostimulation of tissues can also play a positive role in attaining satisfactory esthetic results (Kacey, 2019). An example of a bidirectional barbed thread is the Definisse threads, which were previously known as Happy Lift revitalizing threads. Definisse is effective in improving the esthetics of aging skin, which has been confirmed by various clinical studies (Rezaee et al., 2019; Savoia et al., 2014). This thread can be used in various approaches of facial reshaping as presented in Table 3 (Kacey, 2019).

Malar reshaping (Fig. 4) involves elevation of the midface and helps in facial rejuvenation to obtain a youthful and beautiful facial appearance without affecting the individual's personal features (De Cordier et al., 2002).

Asian faces frequently require anterior projection of the mid- and lower face, as well as reshaping of the jawline, which can be achieved by tightening and elevating fat compartments. In a typical East Asian face, bilateral traction caudally and posteriorly can often make a relative prominence on centofacial areas, such as the nose, chin, and forehead areas. Presently, there is a scarcity of

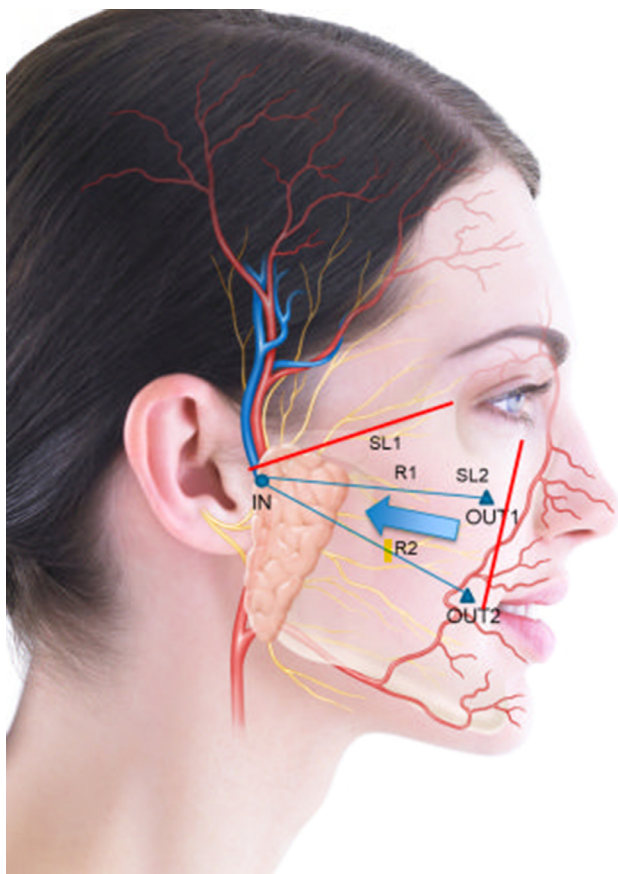


Fig. 4. Malar reshaping technique. Reshaping lines R1: From insertion point to exit point 1, Reshaping lines R2: From insertion point to exit point 2. SL, safety lines

treatment strategies in the esthetic field to help attain effective tissue mobilization and elevate the midface components. Therefore, the aim of the present study was to assess the malar reshaping strategy in Asian subjects using bidirectional, absorbable, monofilament, suspension-barbed threads of synthetic origin (poly-L-lactic acid and caprolactone, p) barbed threads.

Methods

Bidirectional convergent barbed threads

In the present study, Definisse double-needle threads were used. Definisse double-needle threads are available with two lengths of the barbed section: 12 cm and 23 cm. The 12 cm double-needle threads have two straight triangular needles 100 mm long with a diameter of 0.8 to 0.83 mm. The 23 cm double-needle threads have two 150 mm long needles with a diameter of 1.26 to 1.28 mm. The barbs distribution is bidirectional and convergent (Fig. 5). The threads interact with the tissues with a dual effect—mechanical and histological. The mechanical action of the thread is responsible for the immediate lift of the tissue and is done by symmetrically aligning both the halves of the thread that should be of the same entity. This exercise helps to avoid exit of the thread from one of the access holes upon thread insertion. The mechanical property of bidirectional convergent threads is an advantage over unidirectional barbed threads. It does not require anchorage points on the major parts of the facial region. Once placed in the subcutaneous tissue, these threads can continue to sustain their action on the tissues. Additionally, these threads exhibit a histological effect by ensuring the tissue traction and compactness (Savoia et al., 2014).



Fig. 5. Bidirectional barbed suture.

Study design

The prospective interventional study was conducted on Asian patients presenting with mild-to-moderate facial aging who were treated with Definisse double-needle thread between January and April 2018 at a single center in Hong Kong Special Administrative Region under one attending physician.

Inclusion and exclusion criteria

Patients signed a written informed consent form, explaining the treatment procedure and requesting permission to release their before and after treatment images. Patients who had received treatments with other esthetic modalities, including injectables and laser focused ultrasounds, during the previous 6 months or who presented a contraindication to minimal invasive procedures, such as infection and dysmorphophobia, were excluded, as were scar-prone and immune-compromised patients.

Study procedure

All patients underwent the malar reshaping technique. The anchoring point was the lateral preauricular fascia. One bidirectional thread per side was placed with a V path in the superficial fat compartments, specifically in the medial and middle cheek fat compartments and in the superior jowl fat compartment. This technique was performed with double-needle 12-cm threads. Local anesthesia was provided with 2% lignocaine with adrenaline, if required, injected in the insertion point (IN) and exit points (OUTs) and, optionally, along the insertion paths to reduce pain and bleeding during the insertion. Prior to the procedure, a minimal, yet adequate, surgical field was set, and the conditions were maintained during the entire procedure. All techniques include an IN, two OUTs, sometimes an intermediate point, and the reshaping lines (RLs) that indicate the direction of thread insertion. To increase patient safety, two safety lines are drawn from the tragus to the external eye canthus and from the internal eye canthus to the modiolus. Insertion of the needle beyond these lines requires greater attention to avoid damaging nerves and vessels that are more exposed to this risk in these areas (Fundaro and Hau, 2021).

As depicted in Figure 4, the thread was inserted from the preauricular area (i.e., IN), immediately below the inferior margin of the zygomatic arch, and the OUTs laterally to the nasolabial

Table 4
Global Aesthetic Improvement Scale

Score	Degree	Description
1	Exceptional improvement	Excellent corrective result
2	Marked improvement	Improvement not completely optimal
3	Improvement	Improvement compared with initial condition; touchup or further treatment required
4	Unaltered	Appearance after treatment almost similar to initial condition
5	Worsened	Appearance after treatment worse compared with initial condition

folds. The distance between these OUTs was determined by the patient's clinical characteristics and the aims of treatment. If both were located at the level of the nasolabial fat, the action was more focused on malar fat pad repositioning and nasolabial fold improvement. The IN was created using an 18-G needle inserted perpendicularly to the skin. The thread needle was introduced through the dermal hole and slowly run along the insertion path over the SMAS plane.

Once the OUT was reached, the skin was pierced to allow the thread needle to exit, making sure the exit occurs in a perpendicular way. The needle was slowly pulled out along the RL until half of the thread was inserted over the SMAS plane. The same insertion modality was used for the other half of the thread along the opposite RL. Once the Definissee double needle-thread was positioned over the SMAS plane, the lifting action was provided by pulling the skin upward along the path of the thread, distributing the tissue toward the IN. Once both parts of the threads were inserted, the superficial fat compartments were lifted, pulling both extremities of the thread.

Data collection

Standard photographs were taken from three angles including frontal, side, and 45° before treatment, immediately after treatment, and 1 month, 6 months, and 12 months after the procedure.

Study endpoints

There were two primary study endpoints: Global score on esthetic improvement and scoring for anterior projection. Global score on esthetic improvement was recorded by both patients and the physician using the Global Aesthetic Improvement Scale (GAIS) during every follow-up visit. The assessment score rating and description of the scale are presented in Table 4 (Rezaee Khiabanloo et al., 2019). To score for anterior projection, patients were asked to score the benefit of the anterior projection and other benefits in terms of esthetic improvement using a seven-point questionnaire (Fig. 6).

The secondary study endpoint was safety, assessed based on the complications or AEs experienced by patients.

Statistical analysis

The data were analyzed descriptively and presented as number (percentage).

Results

Study population

Twenty Asian patients (n=20; age range, 23–67 years; male:female ratio, 1:4) were included in the study. Of the 20 patients, four (20%) were men and 16 (80%) were women. In addition,

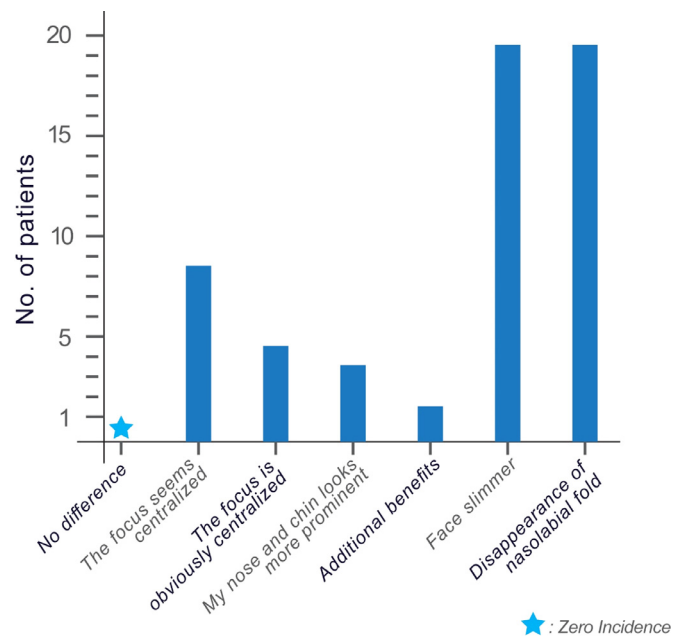


Fig. 6. Scoring for anterior projection by patients. Patients were asked to score the benefit of anterior projection.

tion, 12 patients (60%) were age <45 years and 8 patients (40%) were age ≥45 years.

Primary endpoints

Global score on esthetic improvement

The physician scored the improvement as 2 (marked improvement) on the GAIS scale during every follow-up visit (immediately after treatment, and 1 month, 6 months, and 12 months after the procedure). Patients also experienced marked improvement in the appearance from the initial condition (without treatment) and scored 2 during each follow-up, except for the follow-up after 1 month. One month after the procedure, patients scored 1 because they found optimal cosmetic improvement in their looks (Table 5).

Age-related improvement scores were 1 (optimal improvement) in patients age >45 years and 2 in those age ≤45 years per both patient and physician assessments.

Scoring for anterior projection

According to the patient assessments, the nasolabial fold disappeared in all patients (100%; n=20), and all patients reported that their face looked slimmer. Nine patients (45%) reported that the focus seemed centralized. This refers to the patient's response on the esthetic results of anterior projection resulting from the bilateral thread repositioning as per the score in Figure 6. Four patients (20%) found that their nose and chin looked more prominent. Representative pre- and postprocedure images of 60- and 36-year-old Asian women are presented in Figure 7.

Secondary endpoint

Redness, swelling, and bruising were the most common AEs, experienced by 75% of patients (n=15), followed by pain (30%; n=6). None of the patients experienced headache, infection or injury at the local site, or postinflammatory hyperpigmentation (Fig. 8). All AEs resolved within 4 weeks after incidence.

Table 5
Esthetic improvement in patients by Global Aesthetic Improvement Scale score

Time after treatment	Global Aesthetic Improvement Scale score	
	Patients	Physician
Immediate after	2	2
1 month after	1	2
6 months after	2	2
12 months after	2	2

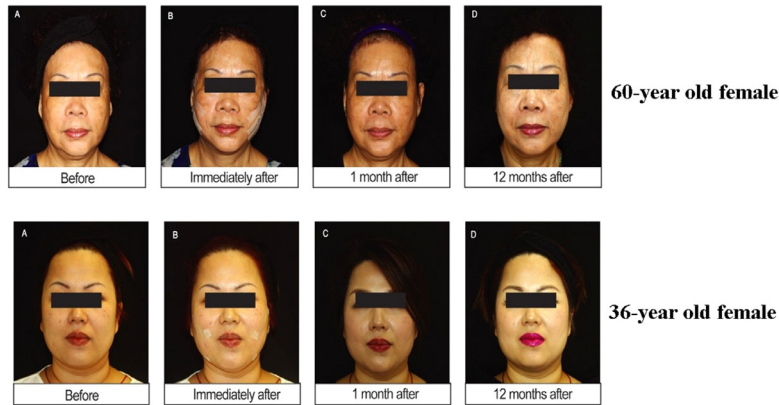

Fig. 7. Pre- and postprocedure images of 60- and 36-year-old Asian women.

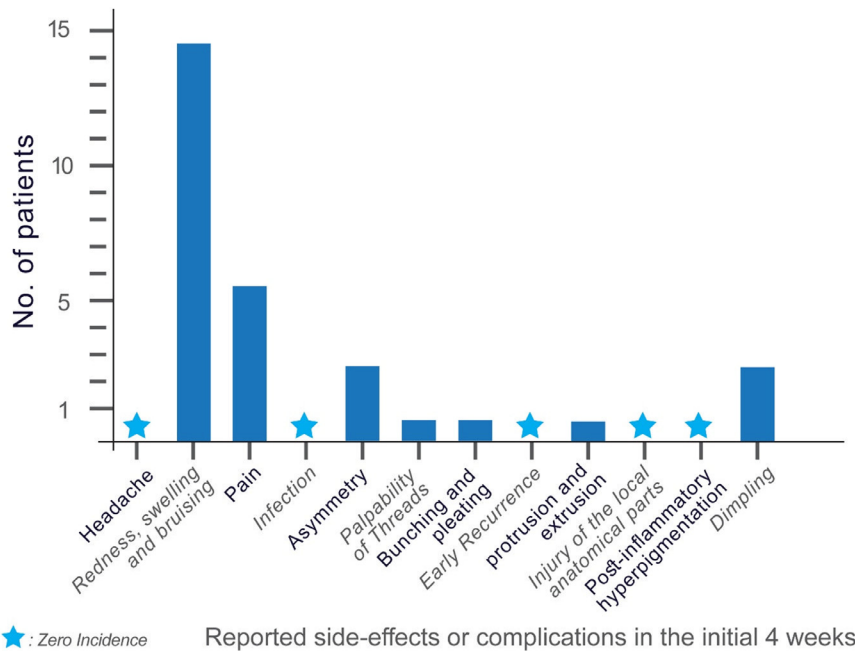


Fig. 8. Adverse events experienced by patients.

Discussion

This study aimed to assess the effectiveness and safety of the malar reshaping strategy in Asian patients using bidirectional barbed threads and to assess the esthetic improvement of anterior projection using the GAIS scoring system and a seven-point questionnaire. The results indicate marked esthetic improvements in all patients per the GAIS scores according to patients and the physician. The findings of esthetic improvement for the anterior projection questionnaire reveal that all patients observed esthetic improvement due to the disappearance of the nasolabial fold, slimmer face, prominent chin and nose, and centralized focus. In terms of safety, redness, swelling, and bruising were the most common

AEs, followed by pain. However, all AEs resolved in 4 weeks after incidence.

Ethnicity plays an important role in the esthetics because physical characteristics vary. However, loss of volume while aging is experienced by all, independent of ethnicity. In Asian populations, embellishment (detailing of a feature) is more commonly focused in patients seeking treatments related to beautification interventions prematurely (Chao et al., 2017). Generally, the Asian facial structure includes a shorter and flattened anteromedial face, smoother and wider front, wider intercanthal distance, lower structural projection of the central third of the face, broader nose, smaller lower third than upper third of the face, and in some cases retrognathia and microgenia (Liew, 2015).

Asian patients may require the malar reshaping technique because they target nose and chin augmentation and nasolabial fold correction due to their facial bone structure. Fillers help enhance anterior projection (Arsiwala, 2018) but are not reliable in such cases because they may lead to more weight and volume added on the face. Use of barbed threads suspension is more reliable and effective in reshaping these areas and create prominent zones. Barbed threads can produce an anterior projection effect (especially for nasal tips and dorsal lengthening; Lee and Yang, 2018). Implementing barb thread repositioning also solves the sagging of mid- and lower-face fat compartments (Wong et al., 2017). With barbed sutures, skin texture can also be improved (Palermo et al., 2019). Previously conducted studies report the efficacy of bidirectional barbed sutures in 37 patients with average aging signs requiring a lift of modest degree. The study reported that 33 patients (89%) were satisfied with the esthetic improvement (65% and 24% with excellent and good level of satisfaction, respectively; Savoia et al., 2014). A study by Khiabanloo et al. (2018) also reported that thread lifting is a more acceptable, safer, and effective cosmetic technique associated with a high level of satisfaction among patients and surgeons (Rezaee Khiabanloo et al., 2019). The results were in concordance with the present study as all patients experienced marked improvement in their signs of aging.

Face volume repositioning and tissue support using these threads was found to be safe with minor complications (Bernard et al., 2006), including small ecchymosis (62%), mild erythema (40%), small hemorrhage (25%), mild transitory esthesia (6%), and mild postoperation tumefaction (40%) by Savoia et al. (2014). However, no such AEs were observed in our study cohort. Because 80% of patients were female, this minimally invasive lifting procedure could be helpful for treating the signs of central facial aging in the female Asian population. Of note, investigators did not find any difference in the efficacy and safety of this procedure between the sexes.

Taking into consideration the literature findings and the results of the present study, use of bidirectional barbed threads can be considered an effective strategy for 3-dimensional repositioning/elevation of facial tissues. However, a comprehensive understanding of facial anatomy and exhaustive knowledge of fat compartments, fascia, and retaining ligaments are essential to obtain favorable results. In addition, the right patients must be selected and expectations must be discussed before choosing the right intervention.

The physical and chemical composition of threads also contribute to the overall esthetic look with immediate elevating effects due to the suspension action caused by the barbs, resulting in the reshaping and repositioning of the tissues, and delayed revitalizing action caused by fibrosis and mild inflammation in the treated area. However, more studies on the biomechanical properties of the threads are required.

With a chronic dearth of Asian data on esthetic procedures, we believe that the results of this study are an important addition. This real-world study has a few limitations: Small sample size, and the fact that the technique was not compared with any other technique. This highlights the need to conduct comparative studies using large sample sizes.

Conclusion

Overall, 3-dimensional facial rejuvenation with Definissee double-needle thread seems to be an effective, safe, and minimally invasive office-based procedure for facial contouring and reshaping showing an immediate effect. These absorbable barbed sutures can be a good alternative to more invasive procedures. The plugs on the surface of the wires allow for the combination with other

nonsurgical rejuvenation procedures, such as botulinum toxin, or substances with a transient and volumizing filler effect, chemical peelers, photorejuvenation with a pulsed light, and lip filling. Operations with these threads do not require general anesthesia and take approximately 20 to 40 minutes to complete. The technique does not cause bleeding or pain, either during or after the operation, and does not produce scars that are visible on the skin. In addition, the operations does not require a postoperative recovery period (Savoia et al., 2014). Moreover, the malar reshaping technique can result in satisfactory esthetic enhancement of 3-dimensional aging signs, including sagging, heavy, or chubby large face of Asian patients.

Conflicts of interest

K.C. Hau is a consultant for Menarini Asia Pacific Ltd. Suyog Jain was an employee of Menarini Asia Pacific.

Funding

None.

Study approval

N/A

Acknowledgments

The authors acknowledge Turacoz Healthcare Solutions (www.turacoz.com) for manuscript writing assistance.

References

- Ali YH. Two years' outcome of thread lifting with absorbable barbed PDO threads: Innovative score for objective and subjective assessment. *J Cosmet Laser Ther* 2018;20(1):41–9.
- Arsiwala SZ. Simplifying injectables for volumetric rejuvenation of face. *J Cutan Aesthet Surg* 2018;11(2):51.
- Bernard S, Neville KA, Nguyen AT, Flockhart DA. Interethnic differences in genetic polymorphisms of CYP2D6 in the U.S. population: Clinical implications. *Oncologist* 2006;11(2):126–35.
- Chao YY, Chhabra C, Corduff N, Fabi SG, Kerscher M, Lam SC, et al. PAN-ASIAN Consensus—Key recommendations for adapting the world congress of dermatology consensus on combination treatment with injectable fillers, toxins, and ultrasound devices in Asian patients. *J Clin Aesthet Dermatol* 2017;10(8):16.
- Coleman S. Structural fat grafting. St. Louis, MO: Quality Medical Publishing, Inc.; 2004.
- Coleman SR, Grover R. The anatomy of the aging face: volume loss and changes in 3-dimensional topography. *Aesthet Surg J* 2006;26(1S):S4–9.
- De Cordier BC, de la Torre JI, MS Al-Hakeem, Rosenberg LZ, Costa-Ferreira A, Gardner PM, et al. Rejuvenation of the midface by elevating the malar fat pad: Review of technique, cases, and complications. *Plast Reconstr Surg* 2002;110(6):1526–36; discussion 1537–40.
- El-Domyati M, El-Ammawi TS, Moawad O, El-Fakahany H, Medhat W, Mahoney MG, Uitto J. Efficacy of mesotherapy in facial rejuvenation: A histological and immunohistochemical evaluation. *Int J Dermatol* 2012;51(8):913–19.
- Flament F, Bazin R, Laquieze S, Rubert V, Simonpietri E, Piot B. Effect of the sun on visible clinical signs of aging in Caucasian skin. *Clin Cosmet Investig Dermatol* 2013;6:221–32.
- Fundaro SP, Hau KC. Innovative minimal invasive techniques in facial reshaping using barb suspension thread surgery [Internet]. 2021 [cited xxx]. Available from: <https://www.imcas.com/en/academy/blog/415/innovative-minimal-invasive-techniques-in-facial-reshaping-using-barb-suspension-thread-surgery-15-03-2021>.
- Ganceviciene R, Liakou AI, Theodoridis A, Makrantonaki E, Zouboulis CC. Skin anti-aging strategies. *Dermatoendocrinol* 2012;4(3):308–19.
- Jayanthi P, Joshua E, Ranganathan K. Ageing and its implications. *J Oral Maxillofac Pathol* 2010;14(2):48–51.
- Kacey H. Early surgical adverse events and incidence rates in bidirectional barb suspension thread surgery. *Dermatol Res* 2019;1(1):1–3.
- Kalra R. Use of barbed threads in facial rejuvenation. *Indian J Plast Surg* 2008;41(Suppl):S93–100.
- Kohl E, Steinbauer J, Landthaler M, Szeimies RM. Skin ageing. *J Eur Acad Dermatol Venereol* 2011;25(8):873–84.
- Lee HY, Yang HJ. Rhinoplasty with barbed threads. *Plast Reconstr Surg Glob Open* 2018;6(11).

- Liew S. Ethnic and gender considerations in the use of facial injectables: Asian patients. *Plast Reconstr Surg* 2015;136(5S):225–7.
- Makrantonaki E, Zouboulis CC, William J, Cunliffe Scientific Awards. Characteristics and pathomechanisms of endogenously aged skin. *Dermatology* 2007;214(4):352–60.
- Matarasso A, Paul MD. Barbed sutures in aesthetic plastic surgery: Evolution of thought and process. *Aesthet Surg J* 2013;33(3_Suppl) 17S–31.
- Matarasso A, Ruff GL. The history of barbed sutures. *Aesthet Surg J* 2013;33 3_Suppl12S–6.
- Mora Huertas AC, Schmelzer CE, Hoehenwarter W, Heyroth F, Heinz A. Molecular-level insights into aging processes of skin elastin. *Biochimie* 2016;128–9:163–73.
- Moragas A, Castells C, Sans M. Mathematical morphologic analysis of aging-related epidermal changes. *Anal Quant Cytol Histol* 1993;15(2):75–82.
- Palermo E, Anzai A, Jacomo A. Three-dimensional approach of cosmetic patient: Aging gracefully. Botulinum toxins, fillers-related substances. Clinical approaches procedures in cosmetic dermatology. New York, NY: Springer; 2019. p. 1–22.
- Quan T, Shao Y, He T, Voorhees JJ, Fisher GJ. Reduced expression of connective tissue growth factor (CTGF/CCN2) mediates collagen loss in chronologically aged human skin. *J Invest Dermatol* 2010;130(2):415–24.
- Rezaee Khiabanloo S, Jebreili R, Aalipour E, Saljoughi N, Shahidi A. Outcomes in thread lift for face and neck: A study performed with Silhouette Soft and Promo Happy Lift double needle, innovative and classic techniques. *J Cosmet Dermatol* 2019;18(1):84–93.
- Savoia A, Accardo C, Vannini F, Di Pasquale B, Baldi A. Outcomes in thread lift for facial rejuvenation: A study performed with happy lift revitalizing. *Dermatol Ther (Heidelb)* 2014;4(1):103–14.
- Sulamanidze MA, Fournier PF, Paikidze TG, Sulamanidze GM. Removal of facial soft tissue ptosis with special threads. *Dermatol Surg* 2002;28(5):367–71.
- Weinkle S, Saco M. Approach to the mature cosmetic patient: Aging gracefully. *J Drugs Dermatol* 2017;16(6):s84–6.
- Wong V. The science of absorbable poly (L-lactide-co-ε-caprolactone) threads for soft tissue repositioning of the face: An evidence-based evaluation of their physical properties and clinical application. *Clin Cosmet Invest Dermatol* 2021;14:45.
- Wong V, Rafiq N, Kalyan R, Hsenriksen A, Funner R. Hanging by a thread: Choosing the right thread for the right patient. *J Dermat Cosmetol* 2017;1(04):86–8.
- Wu WTL. Commentary on facial rejuvenation with fine barbed threads: The simple MIZ-lift. *Aesthet Plast Surg* 2014;38(1):75–7.
- Zhang S, Duan E. Fighting against skin aging: The way from bench to bedside. *Cell Transplant* 2018;27(5):729–38.