

FLUORESCENCE LIFETIME IMAGING OPHTHALMOSCOPY AS PREDICTOR OF LONG-TERM FUNCTIONAL OUTCOME IN MACULA-OFF RHEGMATOGENOUS RETINAL DETACHMENT

DAMIAN JAGGI, MD,*† YASMIN SOLBERG, MD,*† CHANTAL DYSLI, MD, PhD,*†
 JOEL LINCKE, MD,*† OUSSAMA HABRA, MMED,*† SEBASTIAN WOLF, MD, PhD,*†
 MARTIN ZINKERNAGEL, MD, PhD*†

Purpose: To assess whether macular fluorescence lifetimes may serve as a predictor for long-term outcomes in macula-off rhegmatogenous retinal detachment.

Methods: A single-center observational study was conducted. Patients with pseudophakic macula-off rhegmatogenous retinal detachment were included and evaluated 1 and 6 months after successful reattachment surgery. Fluorescence lifetime imaging ophthalmoscopy lifetimes in the central Early Treatment Diabetic Retinopathy Study grid subfield, in two distinct channels (short spectral channel and long spectral channel) were analyzed. Best-corrected visual acuity optical coherence tomography of the macula and fluorescence lifetimes were measured at month 1 and month 6.

Results: Nineteen patients were analyzed. Lifetimes of the previously detached retinas were prolonged compared with the healthy fellow eyes. Short lifetimes at month 1 were associated with better best-corrected visual acuity improvement (short spectral channel: $r^2 = 0.27$, $P < 0.05$, long spectral channel: $r^2 = 0.23$, $P < 0.05$) and with good final best-corrected visual acuity (short spectral channel: $r^2 = 0.43$, $P < 0.01$, long spectral channel: $r^2 = 0.25$, $P < 0.05$). Lifetimes were prolonged in some cases of outer retinal damage in optical coherence tomography scans.

Conclusion: Fluorescence lifetime imaging ophthalmoscopy might serve as a prediction tool for functional recovery in pseudophakic macula-off rhegmatogenous retinal detachment. Retinal fluorescence lifetimes could give insight in molecular processes after rhegmatogenous retinal detachment.

RETINA 42:2388–2394, 2022

Rhegmatogenous retinal detachment (RRD) is a vision-threatening ophthalmological condition with separation of the neurosensory retina from the

underlying retinal pigment epithelium. For the treatment of RRD, pars plana vitrectomy is one of the most effective procedures to restore the anatomical integrity

From the *Department of Ophthalmology, Inselspital, Bern University Hospital, University of Bern, Bern, Switzerland; and †Department of BioMedical Research, University of Bern, Bern, Switzerland.

The authors received nonfinancial support from Heidelberg Engineering GmbH, Germany.

None of the authors has any conflicting interests to disclose.

D. Jaggi: Heidelberg Engineering (nonfinancial support); Y. Solberg: Heidelberg Engineering (nonfinancial support); C. Dysli: Heidelberg Engineering (nonfinancial support); J. Lincke: Heidelberg Engineering (nonfinancial support); O. Habra: Heidelberg Engineering (nonfinancial support); S. Wolf: Allergan, Bayer, Novartis, Heidelberg Engineering, Hoya, Optos, Euretina; M. S. Zinkernagel: Allergan, Bayer, Novartis, Heidelberg Engineering, Boehringer Ingelheim.

This is an open access article distributed under the terms of the Creative Commons Attribution-Non Commercial-No Derivatives License 4.0 (CCBY-NC-ND), where it is permissible to download and share the work provided it is properly cited. The work cannot be changed in any way or used commercially without permission from the journal.

Reprint requests: Martin S. Zinkernagel, MD, PhD, Department of Ophthalmology, University Hospital Bern, Freiburgstrasse 4, 3010 Bern, Switzerland; e-mail: martin.zinkernagel@insel.ch

with a mean postoperative reattachment success rate of more than 90%.¹⁻³

Despite successful reattachment and restoration of the anatomical integrity of the retina, patients may experience unsatisfying and insufficient visual and functional recovery, especially in macula-off RRD. Several prognostic factors have been identified that influence visual recovery in patients with RRD.^{4,5}

In particular, preoperative visual acuity, age, duration and extent of retinal detachment, proliferative vitreoretinopathy, and the integrity of the outer retinal layers detected on optical coherence tomography (OCT) were found to be related to the postoperative visual outcome.⁵⁻⁹ In addition, OCT angiography revealed alterations in macular microcirculation after RRD, suggesting tissue ischemia or oxidative stress as another contributing factor in the pathophysiology of RRD.¹⁰

Recently, our group introduced fluorescence lifetime imaging ophthalmoscopy (FLIO) as a tool to investigate patients after successful RRD reattachment surgery.¹¹ Briefly, fluorescence lifetimes represent the mean amount of time retinal autofluorophores remain in the excited state following excitation using a blue light laser.¹² Because different fluorophores have characteristic lifetime values, this method provides additional information than that obtained from imaging modalities, such as OCT or fundus photography.¹³ In our previous study, we established that the mean fluorescence lifetimes were prolonged in eyes after a RRD, compared with the patient's healthy fellow eyes. Interestingly, longer lifetimes were associated with worse visual acuity. These findings suggested a connection between the altered FLIO lifetimes underlying molecular retinal environment and the pathophysiologic processes taking place in RRD.

In this study, we evaluated the prognostic value of FLIO to predict visual recovery after RRD surgery by comparing baseline FLIO measurements and follow-up clinical, OCT, and FLIO data of these patients.

Methods

Patients and Examination

This is a prospective, observational, cohort study conducted at the University Hospital Bern, Bern, Switzerland. Patients were recruited at the ophthalmology outpatient department, and written informed consent was obtained before any study-related procedures were performed. In our previous work, we already reported baseline data on 14 of the included patients.¹¹ We conducted the study in accordance with the International Conference on Harmonization Good Clinical Practice guidelines, based on the Declaration of Helsinki. We

obtained local ethics committee approval, and the study is registered on ClinicalTrials.gov (NCT 0981148).

Patients who experienced a pseudophakic macula-off RRD and underwent successful retinal reattachment surgery with pars plana vitrectomy and sulfur hexafluoride gas endotamponade, including cryo and/or laser therapy of the retinal tear, were included. Phakic patients were not included to ensure comparability of data.¹⁴ Data were collected on the eye after successful retinal detachment surgery (study eye) and on the healthy fellow eye, which was also pseudophakic and free of any retinal disease. Presumptive duration of retinal detachment was documented before study entry. Exclusion criteria were other abnormalities that would interfere with visual acuity or FLIO measurements, such as acquired or inherited abnormalities of the macula, uncontrolled or late-stage glaucoma, severe abnormalities of the vitreoretinal interface, previous vitreoretinal surgery, and retinal reattachment during the follow-up period.

Patients were examined 1 and 6 months after successful reattachment surgery. A full clinical workup, including best-corrected visual acuity (BCVA, logMAR) according to the Early Treatment Diabetic Retinopathy Study, slit-lamp examination, and funduscopy, was performed. We applied tropicamide 0.5% and phenylephrine HCL 2.5% to achieve maximal pupil dilation. Fluorescence lifetime imaging ophthalmoscopy, infrared reflectance images, and Spectral-domain OCT (Heidelberg Spectralis HRA + OCT; Heidelberg Engineering, Heidelberg, Germany) were acquired.

Fluorescence Lifetime Imaging Ophthalmoscopy Imaging and Data Processing

The HRA Spectralis system-based fluorescence lifetime imaging ophthalmoscope projects a 473-nm blue light pulsed laser onto the retina and uses a repetition rate of 80 MHz. Retinal molecules absorb the light and are hereby lifted to a higher state of energy, where they remain for several picoseconds. Two, highly sensitive, hybrid, photon-counting detectors (HPM-100-40; Becker & Hickl, Berlin, Germany) detect the afterward emitted photons as the molecules drop to their initial state of energy. Time-correlated registration of the detected photons (TCSPC-150; Becker & Hickl) is performed simultaneously for two distinct spectral wavelength channels (short-spectral channel [SSC, 498–560 nm] and long-spectral channel [LSC, 560–720 nm]). A confocal and high-contrast infrared image ensures accurate tracking of the detected photons within a frame of 256 × 256 pixels. We obtained at least 1,000 photons per pixel for each channel. The detailed principles of FLIO have been explained before (ISBN 978-3-030-22878-1).¹⁵

We converted the measured lifetime data into exponential decay curves and used the Chi-square test to quantify the “goodness of fit” (SPCImage software version 7.3, Becker & Hickl). We used the amplitude-weighted mean fluorescence lifetimes (T_m), which result from combining short and long lifetime components and their respective amplitudes. We analyzed the lifetimes with the customized “FLIO reader” software (Artorg Center for Biomedical Engineering Research, University of Bern, Bern, Switzerland) for the central region of a standardized Early Treatment Diabetic Retinopathy Study grid (1-mm diameter).

Statistical Analysis

We analyzed the FLIO lifetime data for both spectral channels separately. Therefore, mean \pm SEM were obtained and analyzed. We used a nonparametric Wilcoxon signed-rank test to compare FLIO lifetimes between the study eye and the healthy fellow eye. Spearman correlation was used to compare lifetimes and BCVA data.

Results

Nineteen patients were included in the study. Of these, 2 (11%) were female and 17 (89%) were male. The age was 68.7 ± 2.8 years (mean \pm SEM). Best-corrected visual acuity was 0.36 ± 0.05 logMAR (Snellen equivalent: 20/50, mean \pm SEM) after 1 month and improved to 0.24 ± 0.07 logMAR (Snellen equivalent: 20/32, mean \pm SEM, $P < 0.01$) after 6 months. Presumptive median duration of retinal detachment was 4 days (onset of symptoms until surgery, range: 1 to 10 days).

Fluorescence Lifetime Measurements

Fluorescence lifetime imaging ophthalmoscopy lifetime values were measured in both channels at 1 month (SSC, 229.8 ± 13.15 ps; LSC, 294.8 ± 13 ps, mean \pm SEM) and 6 months (SSC, 230.1 ± 19 ps; LSC, 294.1 ± 17 ps, mean \pm SEM) after the surgery and presented comparable values between these two time points. Healthy fellow eyes at baseline presented significantly shorter lifetimes (SSC, 209.6 ± 14 ps; LSC, 261.5 ± 15 ps, mean \pm SEM), as shown in Figure 1. Lifetimes did not correlate with the presumptive duration of detachment.

Visual Outcome

Baseline T_m of the study eyes significantly correlated with the BCVA change between month 1 and month 6 (Figure 2), where longer baseline lifetimes were associated with worse visual recovery between

month 1 and month 6 in both spectral channels (SSC: $r^2 = 0.27$, $P < 0.05$, LSC: $r^2 = 0.23$, $P < 0.05$). The correlation of lifetime values at month 1 to absolute BCVA (logMAR) values at month 6 was also statistically significant, where short lifetimes were again associated with better visual outcome (SSC: $r^2 = 0.43$, $P < 0.01$, LSC: $r^2 = 0.25$, $P < 0.05$), presented in Figure 3.

In some cases of good visual recovery, central retinal lifetimes showed even shorter lifetime values at the follow-up examination, whereas other cases without visual improvement did not present any difference in lifetime values between month 1 and month 6 (Figure 4). However, we did not observe any statistical significance between these lifetime recovery and visual recovery correlations between month 1 and month 6. Furthermore, OCT characteristics were investigated in relation to FLIO lifetimes (Figure 5). There was a tendency toward shorter lifetimes in eyes with intact outer retinal layers, in particular, the external limiting membrane and ellipsoid zone. If the external limiting membrane and/or ellipsoid zone were disturbed or disrupted, longer lifetimes were observed. However, there was no statistical significance between the three investigated subgroups, as shown in Figure 5.

Discussion

Fluorescence lifetime imaging ophthalmoscopy is a noninvasive imaging modality, which has provided new information about various retinal diseases in the past years.^{13,16–21}

Retinal detachment induces long-lasting morphological and biochemical alterations.²² Fluorescence lifetime imaging ophthalmoscopy imaging has the potential of detecting these alterations at an early stage. The technique of *in vivo* fundus autofluorescence lifetime imaging of the retina was initially introduced by Schweitzer et al.²³ Previous FLIO studies have focused on describing different disease-specific fluorescence lifetime patterns.^{13,14,16,18,19}

In healthy eyes, FLIO has been shown to display a reproducible specific pattern, in which short fluorescence lifetimes are found within the macula and proposedly emitted by components of the macular pigment such as xanthophyll whereas long fluorescence lifetimes are identified at the optic nerve head as a result of connective tissue. Intermediate lifetimes are displayed by the retina, presumably influenced by lipofuscin.^{13,16,24}

In this study, we evaluated the changes of endogenous retinal autofluorescence lifetimes and the

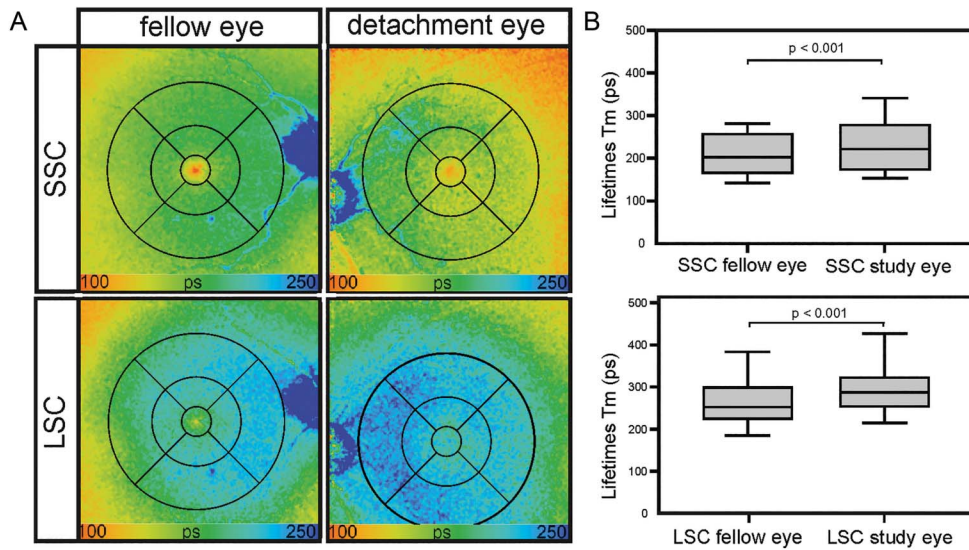


Fig. 1. Fluorescence lifetime imaging ophthalmoscopy after retinal detachment repair (A) FLIO images of the SSC (top column) and LSC (bottom column) of the healthy fellow eye (left column) and the study eye (right column) of the same patient, 4 weeks after reattachment surgery. **B.** Box plots of the corresponding *t*-test comparing the mean fluorescence lifetime values of the foveal region (center of the Early Treatment Diabetic Retinopathy Study-grid) of the healthy fellow eye versus the study eye. Both SSC and LSC showed significant prolonged lifetimes in the study eye.

correlation to long-term functional outcome, using FLIO after successful repair of a macula-off retinal detachment. We showed that in previously detached retina, the normal fluorescence lifetime pattern is significantly altered and prolonged. These alterations are predominantly found within the fovea and were demonstrated in our previous study.¹¹ The presented data from Figure 1B is therefore redundant with our previous work. The prolongation of mean fluorescence

lifetimes was significant in both the SSC and LSC. Prolonged FLIO lifetimes have been identified in pathologic conditions with molecular and morphological disturbances predominantly in the outer retinal layers, assuming the outer retinal layers to be the main source of the FLIO signal.^{15,16}

The reversed correlation of fluorescence lifetimes within the fovea suggests a variable loss of macular pigment following macula-off RRD. The spatial

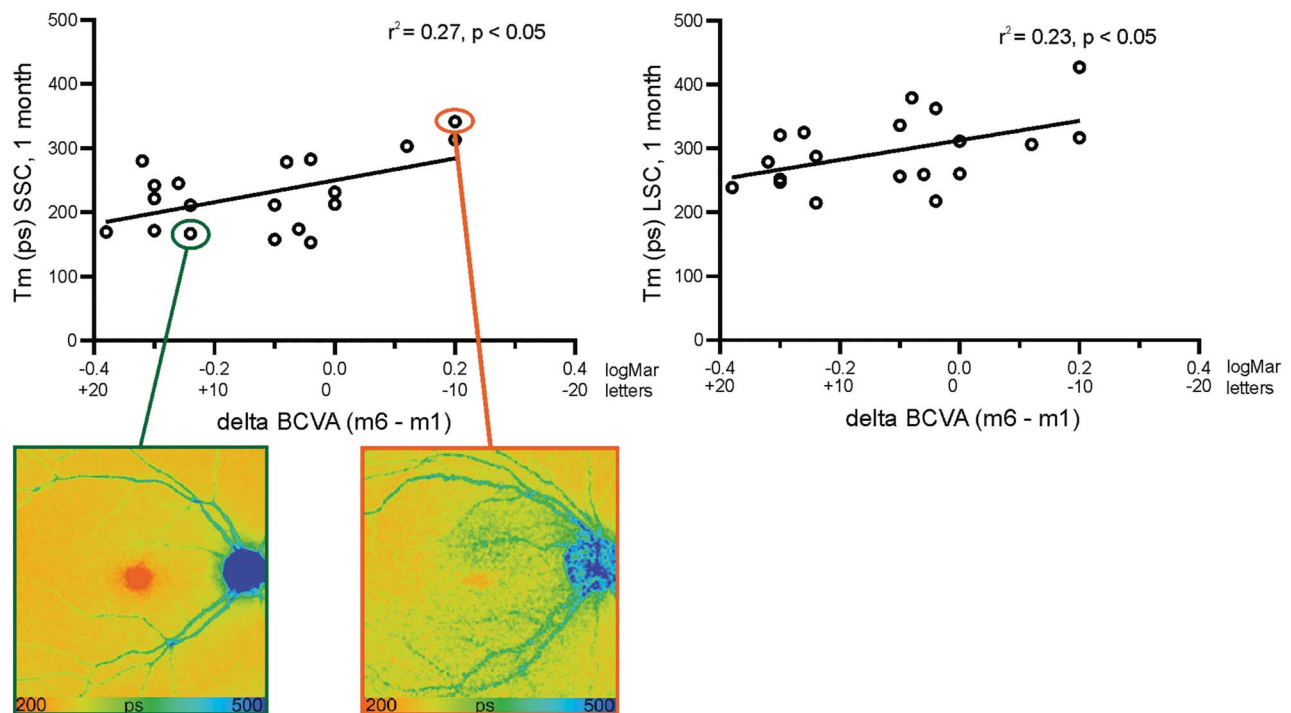


Fig. 2. Correlation of baseline mean foveal lifetimes (Tm) with visual recovery (delta LogMAR and delta Early Treatment Diabetic Retinopathy Study letters; BCVA at 6 months – BCVA at 1 month after the surgery). Both channels (SSC, left graph; LSC, right graph) showed statistically significant correlations.

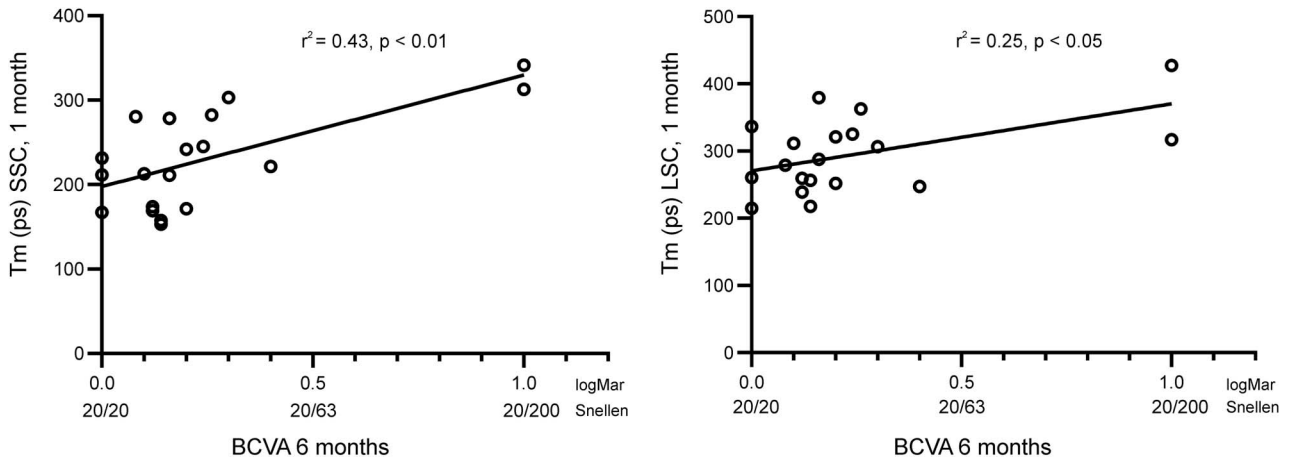


Fig. 3. Correlation of baseline mean foveal lifetimes (Tm) at 1 month with the final visual acuity (logMAR and Snellen feet) at 6 months, in the SSC (left graph) and the LSC (right graph). Correlations were statistically significant in both channels (SSC: $r^2 = 0.43$, $P < 0.01$; LSC: $r^2 = 0.25$, $P < 0.05$).

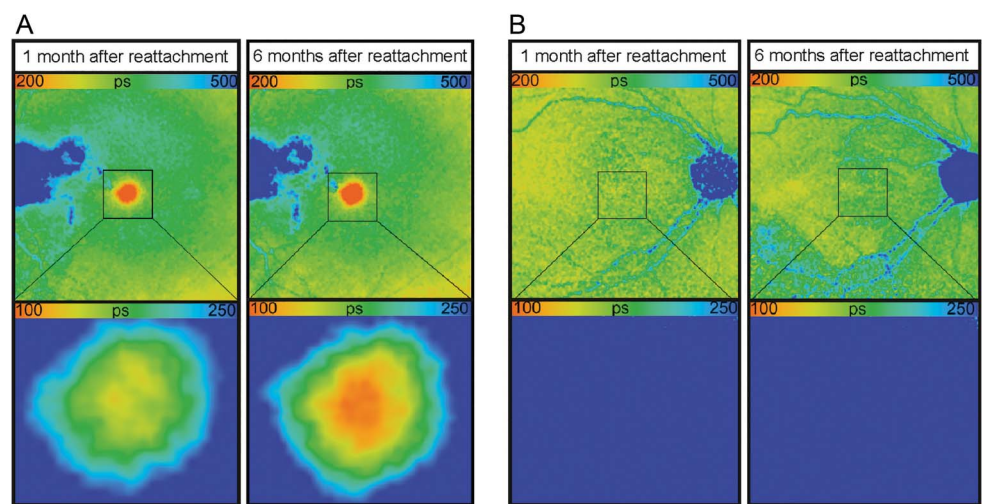
distribution of macular pigment is believed to be the result of the distribution of the cone photoreceptors, which promptly decreases outward from the foveal center. Furthermore, the foveal architecture with its characteristic foveal depression, and its width, plays a role.^{25–27} Previous studies have found that in normal subjects, there is a ring-like distribution of macular pigment with a central peak. Sauer et al²⁴ have described a similar pattern with a central peak of short fluorescence lifetimes.

Nevertheless, in addition, we found prolonged lifetimes in the inner and outer ring of the Early Treatment Diabetic Retinopathy Study grid in previously detached retina,¹¹ suggesting that the alterations in lifetimes may not merely be rationalized by disturbances in the distribution of macular pigment. As previously reported in the literature, the final postoperative functional improvement is determined by the

morphological and functional integrity of the photoreceptors. In OCT, this can be verified by the presence of an intact ellipsoid zone.

Previous studies have reported that the retinal perfusion plays a significant role in the recovery of the retinal function after surgical reattachment. Using OCT angiography, a lower parafoveal superficial and deep capillary plexus density was identified in RRD eyes, and this again was correlated with worse postoperative BCVA. Barca et al²⁸ hypothesized that a rapid vascular resistance increase, involving the superficial capillary plexus, may be induced by the retinal detachment. This could be another explanation for the prolonged lifetimes in the inner and outer rings of the Early Treatment Diabetic Retinopathy Study grid.¹¹ The release of the vasoconstrictive endothelin-1 by endothelial glial cells could be a further significant factor. Roldan-Pallares et al²⁹ identified this peptide

Fig. 4. Fluorescence lifetime imaging ophthalmoscopy images of the macula after reattachment of macula-off RRD. **A.** An example with good visual outcome. The left column was imaged 4 weeks after the surgery, where short lifetimes were observed in the fovea. The right column presents even shorter lifetimes 6 months after the surgery. The magnified fovea is illustrated in the lower column, where the color threshold was adjusted to 100–250 ps. **B.** An example of a right eye with reduced visual outcome. Foveal lifetimes were long and remained above the threshold of 250 ps. We point out the adjusted cutoffs of the Tm color scale compared with our previous work.



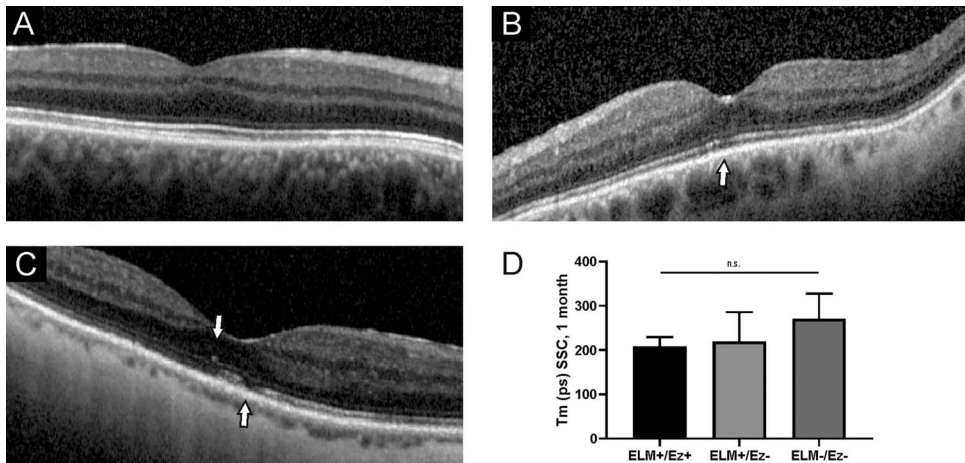


Fig. 5. Optical coherence tomography findings compared with mean foveal lifetimes (Tm, SSC). **A.** Representative OCT of a patient with intact external limiting membrane and ellipsoid zone. **B.** Optical coherence tomography scan with irregular ellipsoid zone (arrow) but intact external limiting membrane. **C.** Optical coherence tomography scan with discontinuous external limiting membrane and disturbed ellipsoid zone (arrows). **D.** No statistical significance was observed between the three groups.

in subretinal fluid accumulations. This release fits to the observation that perfusion of the retinal microvasculature is reduced. In addition, endothelin-1 acts on retinal Müller cells, thereby triggering a fibrotic remodeling, yet not detectable with common imaging techniques like OCT, but perhaps causing prolonged fluorescence lifetimes.

In this study, we show that shorter foveal fluorescence lifetimes at 1 month were significantly associated with a good visual prognosis in the following up to 6 months after RRD repair. Therefore, an increased area of short fluorescence lifetimes in the macular region after the surgery may have prognostic value. In addition, over the 6-month follow-up, we observed that the macular fluorescence lifetimes gradually recover following successful RRD repair in some cases. We assume that prolonged foveal fluorescence lifetimes in previously detached retinas may be explained by morphological and retinal microstructural alterations. Accumulation of visual cycle's by-products in the retina might further contribute to a more severe retinal dysfunction, indicated by prolonged fluorescence lifetimes. However, to date, the exact source of the FLIO signal remains ambiguous. Thus, other factors, such as structural alterations, the retinal pigment epithelium, or influence from other layers, may play a role.

From our results, it can be inferred that macular pigment is depleted in a RRD with macula-off situation and that the replenishment with macular pigment needs a reattached macula. If this holds true, strategies to avoid reduction of macular pigment or even boost replenishment with antioxidants or lutein preparations might be useful in patients with macula-off RRD.³⁰

By contrast, eyes who displayed prolonged fluorescence lifetimes following retinal detachment repair indicate insufficient recovery of the retina. This may be explained by a late ellipsoid zone recovery and cone disturbance at the fovea and thus poor visual

prognosis. Correlation with multimodal imaging confirmed the metabolic disturbance with higher lifetime values in some of these cases.

The main limitation of this study is its small sample size. Furthermore, we did not assess the height, extension, and duration of the retinal detachment. These parameters might affect the retinal vasculature and influence on the recovery of the perifoveal vascular plexus, thus influencing the postoperative BCVA results. Figure 3 and its statistical significance seems to be relating strongly on two subjects with poor visual outcome. However, we see this a pilot survey. Larger randomized studies, possibly with the investigation of macular pigment supplementation could give further insight in the pathophysiological circumstances of macula-off RRD.

Conclusion

This study confirmed that macula-off retinal detachment displays prolonged mean fluorescence lifetimes. Macular fluorescence lifetimes 1 month after the surgery correlate significantly with long-term functional outcomes, and these lifetimes seem to recover over time in some cases. FLIO may be a useful tool in the prediction of long-term functional outcomes early after macula-off RRD surgery.

Key words: fluorescence lifetimes, rhegmatogenous retinal detachment, macula, visual acuity, optical coherence tomography.

Acknowledgments

The authors thank Jörg Fischer, PhD, and Yoshihiko Katayama, PhD, from Heidelberg Engineering GmbH, Heidelberg, Germany, for providing technical assistance for the FLIO device.

References

- Adelman RA, Parnes AJ, Ducournau D; European Vitreo-Retinal Society EVRS Retinal Detachment Study Group. Strategy for the management of uncomplicated retinal detachments: the European vitreo-retinal society retinal detachment study report 1. *Ophthalmology* 2013;120:1804–1808.
- Sun Q, Sun T, Xu Y, et al. Primary vitrectomy versus scleral buckling for the treatment of rhegmatogenous retinal detachment: a meta-analysis of randomized controlled clinical trials. *Curr Eye Res* 2012;37:492–499.
- Weichel ED, Martidis A, Fineman MS, et al. Pars plana vitrectomy versus combined pars plana vitrectomy-scleral buckle for primary repair of pseudophakic retinal detachment. *Ophthalmology* 2006;113:2033–2040.
- Burton TC, Lambert RW Jr. A predictive model for visual recovery following retinal detachment surgery. *Ophthalmology* 1978;85:619–625.
- Park DH, Choi KS, Sun HJ, Lee SJ. Factors associated with visual outcome after macula-off rhegmatogenous retinal detachment surgery. *Retina* 2018;38:137–147.
- Ross WH, Kozy DW. Visual recovery in macula-off rhegmatogenous retinal detachments. *Ophthalmology* 1998;105:2149–2153.
- Grizzard WS, Hilton GF, Hammer ME, Taren D. A multivariate analysis of anatomic success of retinal detachments treated with scleral buckling. *Graefes Arch Clin Exp Ophthalmol* 1994;32:1–7.
- Shimoda Y, Sano M, Hashimoto H, et al. Restoration of photoreceptor outer segment after vitrectomy for retinal detachment. *Am J Ophthalmol* 2010;149:284–290.
- Gharbiya M, Grandinetti F, Scavella V, et al. Correlation between spectral-domain optical coherence tomography findings and visual outcome after primary rhegmatogenous retinal detachment repair. *Retina* 2012;32:43–53.
- Woo JM, Yoon YS, Woo JE, Min JK. Foveal avascular zone area changes analyzed using OCT angiography after successful rhegmatogenous retinal detachment repair. *Curr Eye Res* 2018;43:674–678.
- Jaggi D, Solberg Y, Dysli C, et al. Fluorescence lifetime imaging ophthalmoscopy: findings after surgical reattachment of macula-off rhegmatogenous retinal detachment. *Retina* 2020;40:1929–1937.
- Schweitzer D, Kolb A, Hammer M, Anders R. [Time-correlated measurement of autofluorescence. A method to detect metabolic changes in the fundus]. *Ophthalmologie* 2002;99:774–779. GermanPMID: 12376853.
- Schweitzer D, Schenke S, Hammer M, et al. Towards metabolic mapping of the human retina. *Microsc Res Tech* 2007;70:410–419.
- Lincke JB, Dysli C, Jaggi D, et al. The influence of cataract on fluorescence lifetime imaging ophthalmoscopy (FLIO). *Translational Vis Sci Technol* 2021;10:33.
- Dysli C, Wolf S, Berezin MY, et al. Fluorescence lifetime imaging ophthalmoscopy. *Prog Retin Eye Res* 2017;60:120–143.
- Dysli C, Quéllec G, Abegg M, et al. Quantitative analysis of fluorescence lifetime measurements of the macula using the fluorescence lifetime imaging ophthalmoscope in healthy subjects. *Invest Ophthalmol Vis Sci* 2014;55:2106–2113.
- Dysli C, Fink R, Wolf S, Zinkernagel MS. Fluorescence lifetimes of drusen in age-related macular degeneration. *Invest Ophthalmol Vis Sci* 2017;58:4856–4862.
- Solberg Y, Dysli C, Escher P, et al. Retinal flecks in stargardt disease reveal characteristic fluorescence lifetime transition over time. *Retina* 2019;39:879–888.
- Sauer L, Gensure RH, Hammer M, Bernstein PS. Fluorescence lifetime imaging ophthalmoscopy: a novel way to assess macular telangiectasia type 2. *Ophthalmol Retina* 2018;2:587–598.
- Sauer L, Vitale AS, Andersen KM, et al. Fluorescence lifetime imaging ophthalmoscopy (FLIO) patterns in clinically unaffected children of macular telangiectasia type 2 (MACTEL) patients. *Retina* 2020;40:695–704.
- Dysli C, Schuerch K, Escher P, et al. Fundus autofluorescence lifetime patterns in retinitis pigmentosa. *Invest Ophthalmol Vis Sci* 2018;59:1769–1778.
- Ghazi NG, Green WR. Pathology and pathogenesis of retinal detachment. *Eye (London, England)* 2002;16:411–421.
- Schweitzer D, Kolb A, Hammer M, Anders R. [Time-correlated measurement of autofluorescence. A method to detect metabolic changes in the fundus]. *Ophthalmologie* 2002;99:774–779.
- Sauer L, Andersen KM, Li B, et al. Fluorescence lifetime imaging ophthalmoscopy (FLIO) of macular pigment. *Invest Ophthalmol Vis Sci* 2018;59:3094–3103.
- Elsner AE, Burns SA, Beausencourt E, Weiter JJ. Foveal cone photopigment distribution: small alterations associated with macular pigment distribution. *Invest Ophthalmol Vis Sci* 1998;39:2394–2404.
- Kirby ML, Galea M, Loane E, et al. Foveal anatomic associations with the secondary peak and the slope of the macular pigment spatial profile. *Invest Ophthalmol Vis Sci* 2009;50:1383–1391.
- Delori FC, Goger DG, Keilhauer C, et al. Bimodal spatial distribution of macular pigment: evidence of a gender relationship. *J Opt Soc Am A Opt Image Sci Vis* 2006;23:521–538.
- Barca F, Bacherini D, Dragotto F, et al. OCT angiography findings in macula-ON and macula-OFF rhegmatogenous retinal detachment: a prospective study. *J Clin Med* 2020;9:E3982.
- Roldán-Pallarés M, Musa AS, Hernández-Montero J, et al. Retinal detachment and proliferative vitreoretinopathy: central retinal artery blood velocities, intraocular pressure, and endothelin 1. *Retina* 2013;33:1528–1539.
- Yu S, Framme C, Menke MN, et al. Neuroprotection with rasagiline in patients with macula-off retinal detachment: a randomized controlled pilot study. *Scientific Rep* 2020;10:4948.