



Case report

Gorham's disease: clinical case[☆]



Pedro Sá^{a,*}, Pedro Marques^a, Carolina Oliveira^a, André Sá Rodrigues^b,
Nelson Amorim^b, Rui Pinto^b

^a Unidade Local de Saúde Alto Minho, Viana do Castelo, Portugal

^b Centro Hospitalar São João, Porto, Portugal

ARTICLE INFO

Article history:

Received 25 April 2014

Accepted 28 April 2014

Available online 28 March 2015

Keywords:

Essential osteolysis/pathology

Essential osteolysis/diagnosis

Rare diseases/etiology

Palavras-chave:

Osteólise essencial/pathologia

Osteólise essencial/diagnóstico

Doenças raras/etiologia

ABSTRACT

Gorham's disease, also known as idiopathic massive osteolysis, is a rare pathological condition characterized by vascular proliferation that results in destruction and reabsorption of the bone matrix, of unknown etiology. It was first described by Jackson in 1838, but it was Gorham and Stout, in 1955, who defined this disease as a specific entity. It has variable clinical presentation and generally has progressive behavior. Controversy continues regarding the treatment and there is no standard treatment. This pathological condition generally presents a favorable prognosis. Here, a case of Gorham's disease with involvement of the left hip is presented, in a male patient without relevant antecedents.

© 2015 Sociedade Brasileira de Ortopedia e Traumatologia. Published by Elsevier Editora Ltda. All rights reserved.

Doença de Gorham: caso clínico

RESUMO

A doença de Gorham, também conhecida por osteólise maciça idiopática, é uma patologia rara, caracterizada por uma proliferação vascular que resulta na destruição e reabsorção da matriz óssea, de etiologia desconhecida. Foi descrita pela primeira vez em 1838 por Jackson, mas foram Gorham e Stout, em 1955, que definiram a doença como uma entidade específica. Com uma apresentação clínica variável, geralmente tem um comportamento progressivo. O tratamento permanece controverso, não há um tratamento padrão. Essa patologia apresenta geralmente um prognóstico favorável. É apresentado um caso de doença de Gorham com envolvimento do quadril esquerdo, num doente do sexo masculino, sem antecedentes de relevo.

© 2015 Sociedade Brasileira de Ortopedia e Traumatologia. Publicado por Elsevier Editora Ltda. Todos os direitos reservados.

[☆] Work developed at the São João Hospital Center, Porto, Portugal.

* Corresponding author.

E-mail: pmgs4@iol.pt (P. Sá).

<http://dx.doi.org/10.1016/j.rboe.2015.03.004>

2255-4971/© 2015 Sociedade Brasileira de Ortopedia e Traumatologia. Published by Elsevier Editora Ltda. All rights reserved.

Introduction

Gorham's disease consists of progressive idiopathic osteolysis of a bone or bones adjacent and surrounding a focus, without respecting joint borders.

It can affect any part of the skeleton. The sites most affected are the cranium, shoulder and pelvis.¹

The clinical presentation depends on the site involved and many months or years may pass by before it is diagnosed. In some cases, the disease is manifested acutely, with incapacitating pain. The first manifestations are commonly spontaneous fractures. In other patients, Gorham's disease presents an insidious course, with progressive muscle weakness.

This disease is of progressive nature in most of the patients and may, in certain cases, be self-limiting. The natural course of this pathological condition is generally benign. However, it has complications comprising pericardial and pleural effusions and these are potentially fatal if the mediastinum is reached.

Radiological examinations, especially X-rays, computed tomography (CT) and magnetic resonance imaging (MRI), in association with bone biopsies, are essential for making the differential diagnosis of this rare pathological condition.

The medical treatment of Gorham's disease includes use of radiotherapy, antiosteoclastic drugs (bisphosphonates) and interferon α -2b. The surgical options include resection of the lesion and filling with autologous or heterologous graft material or reconstruction of the joint through arthroplastic resources.

Case report

The patient was a 48-year-old white man with a history of use of intravenous drugs. He was seen at an external orthopedic consultation with a complaint of pain in his left thigh that had started 5 years earlier, with progressive loss of range of motion and the capacity to walk, and increasing need for external support in order to walk. He did not have any previous history of trauma.

At the objective examination, he presented pain upon palpation of the left trochanteric region and also during passive internal and external rotation. It was observed that during active movements, his flexion of the left hip was limited to 30°, internal rotation to 10–15° and external rotation to 15–20°. He presented a Harris Hip Score of 36.65.

He underwent X-ray examination with the pelvis bearing weight (Fig. 1), from which apparent bone necrosis of the left-side femoral head and neck was observed. A CT scan on the left hip (Fig. 2A and B) showed that complete bone reabsorption of the left-side femoral head and neck had occurred. MRI on the left hip (Fig. 3) also showed complete bone reabsorption of the proximal femur, along with the presence of a vascular "mass" in the joint space and invasion of the fossa and the upper wall of the left acetabulum and wing of the ipsilateral ilium. Bone scintigraphy was also performed and this revealed destruction of the left coxofemoral joint, with late fixation of the radiopharmaceutical.

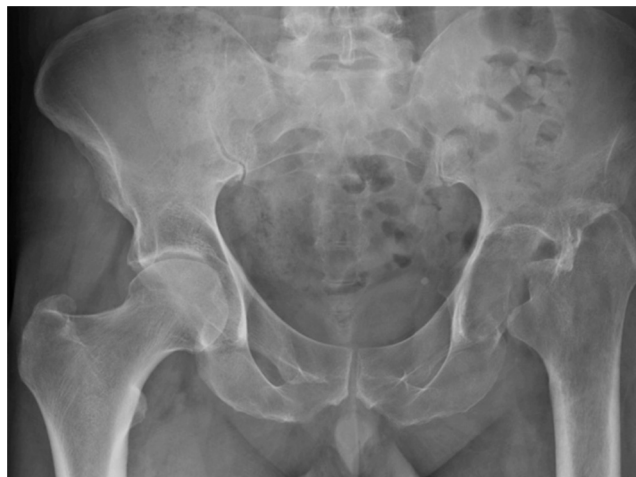

Fig. 1 – X-ray of the pelvis, with weight bearing (AP view).

A biopsy was performed, directed by means of CT on the left hip. The anatomopathological result was compatible with Gorham's disease and revealed the presence of dispersed small-caliber vessels.

The patient is currently being monitored as an orthopedics outpatient and total arthroplasty of the left hip has been proposed.

Discussion

Gorham's disease, also known as Gorham–Stout syndrome, is a rare idiopathic disease that is characterized by extensive loss of bone matrix, which is replaced by fibrotic tissue and proliferative vascular and lymphatic canals. Approximately 200 cases have been reported in the literature.² It was first described by Jackson in 1838,^{3,4} in a case of an adult male in whom complete humeral bone reabsorption was observed over an 11-year period. In 1955, Gorham and Stout⁵ defined this pathological condition as a specific entity through publishing a review of 24 cases of the disease. They reported that "Gorham's disease is generally associated with angiomas of blood and lymph vessels.

Most of the cases occur in children or in adults under the age of 40 years. Approximately 60% of the cases occur among male patients and there is no apparent genetic predisposition.⁶ The shoulder^{7,8} and the pelvis⁹ are the locations most affected by this syndrome, although it may affect any bone.¹⁰ When it affects the ribs, scapula or thoracic spine, it may lead to the appearance of chylothorax, due to direct invasion of lymphangiectasia into pleural cavity or via the thoracic duct.¹¹ In these cases, surgical drainage needs to be performed. If this is not done, there are high morbidity and mortality rates.¹¹ Nonetheless, this syndrome generally presents benign evolution.

Gorham's disease is of progressive nature, but in some cases it presents as a self-limiting pathological condition. Its etiology and pathophysiology remain unknown. The pathological process is characterized by replacement of normal bone by non-neoplastic vascular tissue of aggressive behavior,^{10,12} similar to a hemangioma or lymphangioma. In the early

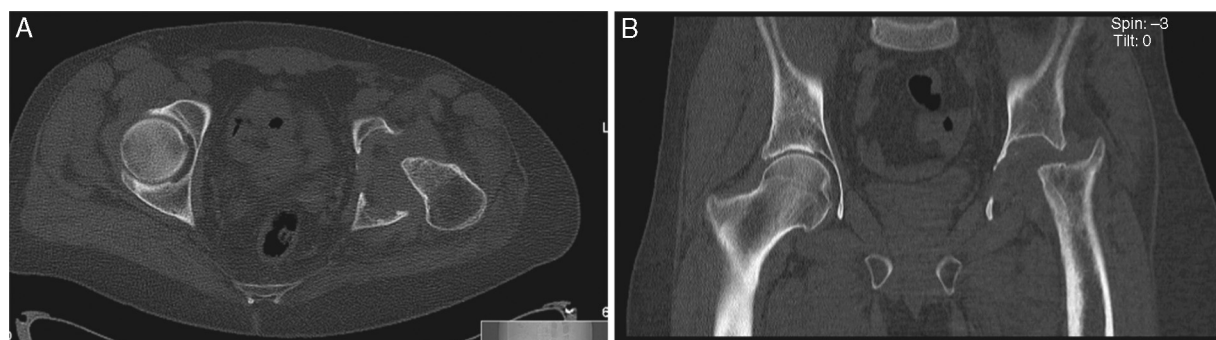

Fig. 2 – (A) CT scan of the pelvis (axial slice) and (B) CT scan of the pelvis (coronal slice).

stage of the lesion, the bone is reabsorbed and replaced by hypervascular and/or angiomatous fibrous connective tissue. Histologically, thin-walled vessels are seen to be present, and these may be capillary, sinusoidal or cavernous. At later stages, progressive bone destruction takes place, with the appearance of fibrotic tissue and massive osteolysis.¹³

The exact nature of the pathological process is unknown. Gorham and Stout⁵ stated that hyperemia, local alterations of pH and mechanical forces were responsible for the bone absorption and rules out any role for osteoclasts. Devlin et al.¹³ suggested that the osteolysis that is present in Gorham's disease was due to increased activity by osteoclasts, mediated by increased levels of interleukin-6 (IL-6). Moller et al.¹⁴ published six cases of Gorham's disease, in which the histopathological results showed that there was an increased number of osteoclasts. Hirayama et al.¹⁵ suggested that the increase in the number of osteoclasts was due to greater sensitivity of the precursors for humoral factors, which promotes formation of osteoclasts and bone reabsorption.

The clinical manifestations are variable and depend on the site affected. Some patients present a sudden start to pain and edema in the extremity affected, while others present an insidious start to the pain, with limitation of movements and progressive loss of muscle strength. Despite the severe bone deformities, serious complications are rare. Paraplegia may occur when vertebrae are involved.¹⁶ When the chest and mediastinum are involved, pleural effusion may develop,

with consequent respiratory failure, which may have a fatal outcome.¹⁷

The routine laboratory analyses are not useful for diagnosing Gorham's disease. It is possible that only the serum alkaline phosphatase levels will be elevated. However, routine radiological examinations such as X-rays, CT and MRI are useful for the diagnosis. The most dramatic appearance of massive osteolysis is seen on X-ray images. Resnick¹⁸ described the radiological findings from Gorham's disease. In the initial stage of the lesion, radiolucent foci appear in the subcortical and intramedullary region, similar to osteoporosis. Progressive dissolution, fragmentation and disappearance of the bone portion affected are seen. The remainder of the bone tissue forms shards and is accompanied by soft-tissue atrophy. The disease may extend to contiguous bones and does not respect the joint surface as a barrier. Scintigraphy shows increased levels of vascularization in the early stages and an area of low uptake corresponding to the location of absence of bone tissue at later stages.¹⁹

The diagnosis of Gorham's disease can only be established after other, more common causes of osteolysis have been ruled out, such as infection, cancer (primary or metastatic) and endocrine and inflammatory diseases. Biopsies (open, echo-guided or CT-guided) contribute toward this and establish the definitive diagnosis.

Because of the rarity of this pathological condition, there is no standard treatment for it. The medical treatment includes radiotherapy,²⁰ bisphosphonates²¹ and interferon α -2b.²² Radiotherapy at moderate doses (40–45 Gy in two fractions) presents good clinical results, with a low complication rate.²¹ Surgical treatment, which is perhaps the main method, includes resection of the lesion and bone reconstruction using a bone graft, or arthroplasty. Chylothorax is the most serious complication, and this occurs when Gorham's disease affects the chest. This complication is potentially life threatening. The surgical procedures reserved for these situations include pleurectomy, pleurodesis and deviation to the thoracic duct.^{23,24} In these cases, radiotherapy is reserved for patients who cannot tolerate invasive procedures.

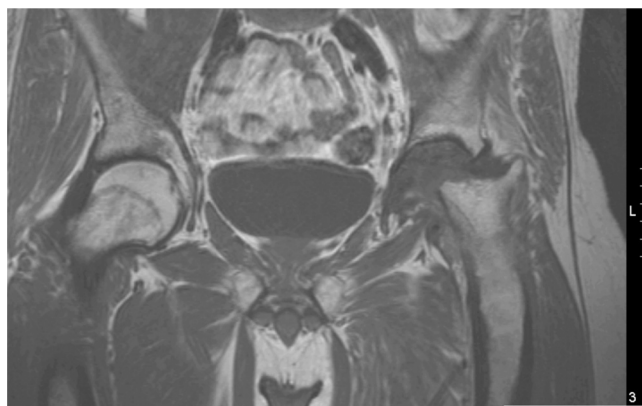


Fig. 3 – MRI of the pelvis (coronal slice).

Conclusion

Gorham's disease is a rare and peculiar musculoskeletal pathological condition in which the bone affected virtually

disintegrates and is replaced by vascular fibrous connective tissue. Its etiology is speculative. The clinical presentation is very variable and the natural history of the disease has an unpredictable prognosis. No effective therapy has been established. Most of the patients are treated with radiotherapy and surgical procedures.

Conflicts of interest

The authors declare no conflicts of interest.

REFERENCES

- Flörchinger A, Böttger E, Claass-Böttger F, Georgi M, Harms J. Gorham–Stout syndrome of the spine. Case report and review of the literature. *Rofo*. 1998;168(1):68–76.
- Papadakis SA, Khaldi L, Babourda EC, Papadakis S, Mitsitsikas T, Sapkas G. Vanishing bone disease: review and case reports. *Orthopedics*. 2008;31(3):278.
- Jackson JB. A boneless arm. *Boston Med Surg J*. 1838;18:368–9.
- Jackson JB. Absorption of the humerus after fracture. *Boston Med Surg J*. 1872;10:245–7.
- Gorham LW, Stout AP. Massive osteolysis (acute spontaneous absorption of bone, phantom bone, disappearing bone); its relation to hemangiomas. *J Bone Joint Surg Am*. 1955;37(5):985–1004.
- Hardegger F, Simpson LA, Segmueller G. The syndrome of idiopathic osteolysis. Classification, review, and case report. *J Bone Joint Surg Br*. 1985;67(1):88–93.
- Remia LF, Richolt J, Buckley KM, Donovan MJ, Gebhardt MC. Pain and weakness of the shoulder in a 16-year-old boy. *Clin Orthop Relat Res*. 1998;(347):268–71.
- Bode-Lesniewska B, von Hochstetter A, Exner GU, Hodler J. Gorham–Stout disease of the shoulder girdle and cervico-thoracic spine: fatal course in a 65-year-old woman. *Skelet Radiol*. 2002;31(12):724–9.
- Kulenkampff HA, Richter GM, Hasse WE, Adler CP. Massive pelvic osteolysis in the Gorham–Stout syndrome. *Int Orthop*. 1990;14(4):361–6.
- Dickson GR, Hamilton A, Hayes D, Carr KE, Davis R, Mollan RA. An investigation of vanishing bone disease. *Bone*. 1990;11(3):205–10.
- Tie ML, Poland GA, Rosenow EC 3rd. Chylothorax in Gorham's syndrome. A common complication of a rare disease. *Chest*. 1994;105(1):208–13.
- Pazzaglia UE, Andriani L, Bonato M, Leutner M. Pathology of disappearing bone disease: a case report with immunohistochemical study. *Int Orthop*. 1997;21(5):303–7.
- Devlin RD, Bone HG 3rd, Roodman GD. Interleukin-6: a potential mediator of the massive osteolysis in patients with Gorham–Stout disease. *J Clin Endocrinol Metab*. 1996;81(5):1893–7.
- Möller G, Priemel M, Amling M, Werner M, Kuhlmeier AS, Delling G. The Gorham–Stout syndrome (Gorham's massive osteolysis). A report of six cases with histopathological findings. *J Bone Joint Surg Br*. 1999;81(3):501–6.
- Hirayama T, Sabokbar A, Itonaga I, Watt-Smith S, Athanasou NA. Cellular and humoral mechanisms of osteoclast formation and bone resorption in Gorham–Stout disease. *J Pathol*. 2001;195(5):624–30.
- Halliday DR, Dahlin DC, Pugh DG, Young HH. Massive osteolysis and angiomatosis. *Radiology*. 1964;82:637–44.
- Kery L, Wouters HW. Massive osteolysis. Report of two cases. *J Bone Joint Surg Br*. 1970;52(3):452–9.
- Resnick D. Osteolysis and chondrolysis. In: Resnick D, editor. *Diagnosis of bone and joint disorders*. 4th ed. Philadelphia: Saunders; 2002. p. 4920–44.
- Spieth ME, Greenspan A, Forrester DM, Ansari AN, Kimura RL, Gleason-Jordan I. Gorham's disease of the radius: radiographic, scintigraphic, and MRI findings with pathologic correlation. A case report and review of the literature. *Skelet Radiol*. 1997;26(11):659–63.
- Dunbar SF, Rosenberg A, Mankin H, Rosenthal D, Suit HD. Gorham's massive osteolysis: the role of radiation therapy and a review of the literature. *Int J Radiat Oncol Biol Phys*. 1993;26(3):491–7.
- Hammer F, Kenn W, Wesselmann U, Hofbauer LC, Delling G, Alolio B, et al. Gorham–Stout disease – stabilization during bisphosphonate treatment. *J Bone Miner Res*. 2005;20(2):350–3.
- Hagberg H, Lamberg K, Aström G. Alpha-2b interferon and oral clodronate for Gorham's disease. *Lancet*. 1997;350(9094):1822–3.
- Pedicelli G, Mattia P, Zorzoli AA, Sorrone A, De Martino F, Sciotto V. Gorham syndrome. *JAMA*. 1984;252(11):1449–51.
- Feigl D, Seidel L, Marmor A. Gorham's disease of the clavicle with bilateral pleural effusions. *Chest*. 1981;79(2):242–4.