

# Safety of Intraparenchymal Injection of Allogenic Placenta Mesenchymal Stem Cells Derived Exosome in Patients Undergoing Decompressive Craniectomy Following Malignant Middle Cerebral Artery Infarct, A Pilot Randomized Clinical Trial

## Abstract

**Background:** Malignant middle cerebral artery infarct (mMCAI) largely contributes to high mortality and physical disability among adults. Surviving individuals may not have proper outcomes and suffer from severe lasting disabilities. Utilization of stem cells and paracrine factor for regenerative purposes is considered as a potential strategy for patients with neurological deficits. While preclinical stroke studies have shown that mesenchymal stem cells (MSCs) reduce post-treatment neurological deficits and prevent disability and also promote recovery, few randomized clinical trials (RCT) have assessed exosome therapy in humans. **Methods:** In this RCT, we assessed the safety of intraparenchymal injection placenta MSC-derived Exosome in mMCAI patients with average age of 62 years between January, 2019, till September, 2020. The study was done in a single-center as an open-label RCT, with a 3-months follow-up. Primary outcomes assessed the safety and also disability indexes were followed. **Results:** Five mMCAI patients were included with mean NIHSS:  $17.6 \pm 5.02$ . The mean MRS was  $3.25 \pm 0.95$  in three patients. No serious adverse events were observed. Hematoma or local reaction as excessive edema were not seen at the site of injection. **Conclusions:** Intraparenchymal implantation of MSC-EXO showed no post-interventional adverse effects in five ischemic stroke patients. It is proposed Local injection Exosome treatment following mMCAI can be safe and in future, it would be applied as a supportive, restorative and preventive treatment in patients who suffer from acute ischemic stroke and post ischemic disability.

**Keywords:** *Allogenic mesenchymal stem cell, decompressive craniectomy, exosome, mMCAI*

## Introduction

Middle cerebral artery territory ischemia (MCAI) is devastating clinical condition. Under some circumstances severe brain edema is superimposed which leads to space-occupying effect and subsequently cerebral herniation. This condition is termed as malignant middle cerebral artery infarct (mMCAI).<sup>[1]</sup> The consequent herniation and compression of brainstem tissue will raise the significant morbidities and mortality if no surgical intervention is going to be considered.<sup>[2,3]</sup> Surviving individuals usually do not have acceptable outcomes and suffer from severe lasting disabilities, stemming from MCA territory ischemia itself and even extension of the ischemic borders across the neighboring regions.<sup>[3,4]</sup> The specific treatment for ischemic strokes, including MCA-territory infarct, are anti-platelet and anticoagulant

therapy with or without combination therapy with anti-fibrinolytics, thrombectomy, barbiturate sedation, and decompressive craniectomy to restore the blood flow to and reoxygenation of the ischemic tissues.<sup>[5,6]</sup> A recent meta-analysis has indicated that decompressive craniectomy may significantly reduce the mMCAI-associated mortality rate. However, this procedure may not bring about proper outcomes in terms of improving the morbidity in patients.<sup>[6]</sup> As a result of the ischemic insult to the brain, severe degrees of disability last in patients, despite their survival from the condition. Therefore, decompressive craniectomy alone, may not suffice, regarding the treatment of these patients.

Regenerative medicine therapy based on cell-based therapy is innovatively contributing to the rehabilitation and treatment of stroke.<sup>[7]</sup>

**How to cite this article:** Dehghani L, Khojasteh A, Soleimani M, Oraee-Yazdani S, Keshel SH, Saadatnia M, *et al.* Safety of intraparenchymal injection of allogenic placenta mesenchymal stem cells derived exosome in patients undergoing decompressive craniectomy following malignant middle cerebral artery infarct, A pilot randomized clinical trial. *Int J Prev Med* 2022;13:7.

Leila Dehghani<sup>1</sup>,  
Arash Khojasteh<sup>1</sup>,  
Masoud  
Soleimani<sup>1,2,3</sup>,  
Saeed  
Oraee-Yazdani<sup>4</sup>,  
Saeed Heidari  
Keshel<sup>1</sup>,  
Mohammad  
Saadatnia<sup>5</sup>,  
Masih Saboori<sup>6</sup>,  
Alireza Zali<sup>5</sup>,  
Seyed Mahmoud  
Hashemi<sup>1,7</sup>,  
Reyhane Soleimani<sup>8</sup>

<sup>1</sup>Department of Tissue Engineering and Applied Cell Sciences, School of Advanced Technologies in Medicine, Shahid Beheshti University of Medical Sciences, Tehran, Iran, <sup>2</sup>Department of Hematology, Faculty of Medical Sciences Tarbiat Modares University, Tehran, Iran, <sup>3</sup>Medical Nanotechnology and Tissue engineering Research Center, Shahid Beheshti University of Medical Sciences, Tehran, Iran, <sup>4</sup>Functional Neurosurgery Research Center, Shohada Tajrish Comprehensive Neurosurgical Center of Excellence, Shahid Beheshti University of Medical Sciences, Tehran, Iran, <sup>5</sup>Department of Neurology, School of Medicine Isfahan University of Medical Sciences, Isfahan, Iran,

## Access this article online

**Website:**  
[www.ijpvmjournal.net/www.ijpvm.ir](http://www.ijpvmjournal.net/www.ijpvm.ir)

**DOI:**  
10.4103/ijpvm.ijpvm\_441\_21

## Quick Response Code:



This is an open access journal, and articles are distributed under the terms of the Creative Commons Attribution-NonCommercial-ShareAlike 4.0 License, which allows others to remix, tweak, and build upon the work non-commercially, as long as appropriate credit is given and the new creations are licensed under the identical terms.

For reprints contact: WKHLRPMedknow\_reprints@wolterskluwer.com

<sup>6</sup>Department of Neurosurgery, School of Medicine Isfahan University of Medical Sciences, Isfahan, Iran, <sup>7</sup>Department of Immunology, School of Medicine, Shahid Beheshti University of Medical Sciences, Tehran, Iran, <sup>8</sup>Department of Neurology, Shahid Beheshti University of Medical Sciences, Tehran, Iran

**Address for correspondence:** Prof. Arash Khojasteh,

Department of Tissue Engineering and Applied Cell Sciences, School of Advanced Technologies in Medicine, Shahid Beheshti University of Medical Sciences, Tehran, Iran.

E-mail: arashkhojasteh@gmail.com

Dr. Saeed Oraee-Yazdani,

Functional Neurosurgery Research Center, Shohada Tajrish Comprehensive Neurosurgical Center of Excellence, Shahid Beheshti University of Medical Sciences, Tehran, Iran.

E-mail: Saeed\_o\_yazdani@sbmu.ac.ir

Stem cells (SCs) take part in regenerations occurring after cerebrovascular accidents, through inducing neurogenesis, synaptogenesis, oligodendrogenesis, axonal connectivity, and myelin formation.<sup>[7,8]</sup>

The mechanisms of actions of SCs can be explained by exosomes, the content available in body fluids such as blood and cerebrospinal fluid.<sup>[9]</sup> Exosomes are 30 to 100 nm endosome-derived small membrane vesicles.<sup>[10]</sup> They contain lipids and genetic materials and take part in intercellular communications, via relocating and transferring their contents, from their cells of origin to their target cells.<sup>[9,11]</sup> Furthermore, intercellular communication between components of the neurovascular unit after a cerebrovascular accident is suggested to be modulated by exosomes.<sup>[12]</sup>

Secretion of exosome (Exo), trophic factors, and other substances capable of inducing neurogenesis, angiogenesis, and synaptogenesis, upon administration into the injured brain tissue, are significant properties of mesenchymal stem cells (MSCs). These properties can contribute to the reduction of inflammation and scar thickness,<sup>[13,14]</sup> improvement of autophagy,<sup>[9]</sup> and possible replacement of damaged cells,<sup>[11]</sup> thus, propounding the use of these cells and their exosome in stroke treatment.

Mesenchymal stem cell-Exosome (MSC-Exo) therapy has shown better safety status compared to MSC.<sup>[15]</sup> In the ischemic brain condition, exosomes are released by MSCs, dynamically, and are subsequently increased in the infarction area.

Based on searching PubMed and Web of Science, until April 2020, for articles published in any language, with the search terms “Mesenchymal Stem Cells derived exosome”, “Acute ischemic stroke”, and “clinical trial or study, we found no study that had investigated intracranial delivery of MSC-derived exosome alone in these patients. So more structured examinations are needed to draw firm conclusions. Present pilot clinical trial study focuses on the safety and feasibility of intracranial MSC-exo administration in patients with mCVAI.

## Methods

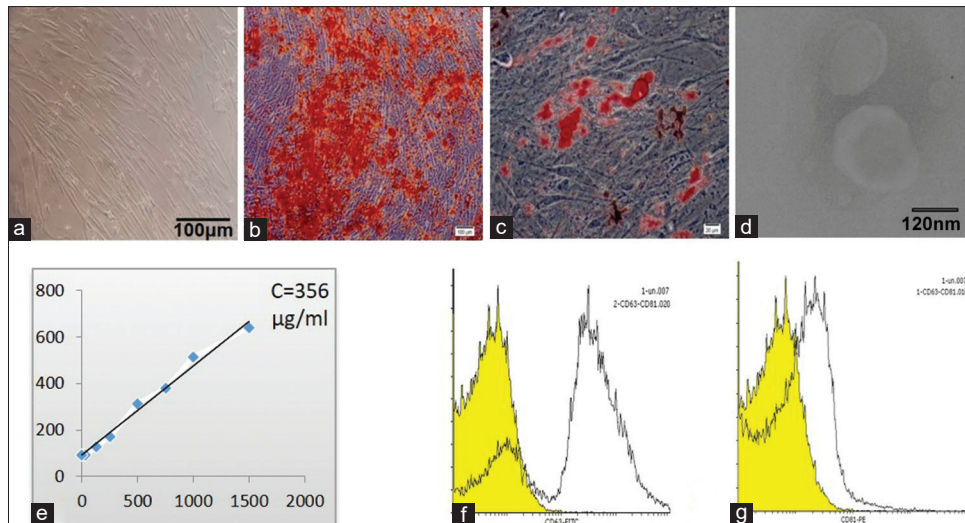
### Cell culture and exosome isolation and characterization

Fresh Placenta (34 g) was obtained from informed healthy mothers after normal deliveries in a local maternity

Hospital, rinsed with PBS and minced into minute pieces. The minced tissue washed three times with 9% sodium chloride solution to remove the remaining blood, before being incubated with 1 mg/mL GMP-grade collagenase NB6 (SERVA Electrophoresis GmbH) at 37°C for 3 h, with shaking every 30 min. Then, 9% sodium chloride solution was added and the mixture was shaken and centrifuged. The supernatant would be discarded and the cell pellet cultivated in MSC complete medium containing Dulbecco's Modified Eagle's Medium supplemented with 10% pharmaceutical grade Australian-origin fetal bovine serum.

Primary cultures were maintained for 1 week in a 37°C humidified 5% CO<sub>2</sub> incubator in small digested residues; non-adherent cells were removed by changing the culture medium and new medium was added twice weekly. Upon approximately 80% confluence, adherent MSCs were passaged via animal origin free TrypLE Express enzyme to reach a sufficient number of MSCs for further clinical applications. [Figure 1a] The MSCs were evaluated for the expression of CD14, CD19, CD34, CD45, CD73, CD90, CD105, and HLA-DR using a FACS sorter (Data not shown). *In Vitro* conditions, differentiation potency to osteoblasts and adipocytes was examined to confirm MSC. The cells were fixed in 4% paraformaldehyde for 20 minutes at 4°C after 20 days. Phosphate-buffered saline (PBS) was used to wash the cells for three times. Oil and Alizarin red were respectively used for staining adipocytes and osteocytes [Figure 1b and c]. To make the culture media ready for cells, 50 µg/mL ascorbate-2-phosphate, Osteo media including 10 mM β-glycerophosphate, 1% antibiotic and adipocyte media containing 0.5 mM isobutyl-methylxanthine, 10 – 7 M dexamethasone, 200 µM indomethacin, and 1% antibiotic were exploited [Figure 1a-c].

After confirmation, pMSCs at passage 3–5 after reaching 70% confluence, cultured in FBS-free medium for 4 h hours. Then supernatant was collected and sequentially centrifuged at 200, 2000, and 10,000 ×g for the removal of cells and cell debris, remove larger Vesicle, the conditioned media were passed through 0.22 mm filter, then centrifuged at 110,000 ×g for 2 hours. The pellet was washed twice and resuspended in PBS again centrifuged at 110,000 ×g for 2 hours. Trimming electron microscopy was used to observe the morphology of exosomes. [Figure 1d]. Bicinchoninic acid (BCA) protein assay kit (Thermo Scientific, Waltham,



**Figure 1: Microscopic images from MSC to Exosome, characterization and concentration. (a) Placenta mesenchymal stem cell, (b) Osteogenic differentiation (stained with Alizarin Red S), (c) Adipogenic differentiation (stained with Oil Red O) (d) Electron micrograph of Exosome, (e) protein quantification (f) Immunophenotyping of MSCs-Exo using flow cytometric analysis of CD63 and CD81 staining (g) Immunophenotyping of MSCs-Exo using flow cytometric analysis of CD63 and CD81 staining**

MA, USA) was used for determining protein concentration of exosomes [Figure 1e].

Expression of the exosome markers was confirmed using flow cytometry for CD63 and CD81 [Figure 1f].

The exosomes were stored at  $-20^{\circ}\text{C}$  for less than 1 month before usage. All procedures will be performed in a Good Manufacturing Practice (GMP) facility according to current GMP guidelines.

After the first passage, and on the final harvested MSCs, cell viability, MSC identity (phenotype), MSC functionality (colony-forming fibroblast unit), tumorigenicity (soft-agar test and telomerase activity), and cytogenetic stability (karyotype) were measured. Before and after procedure, HLA typing was evaluated for each patient.

Quality Control was performed for Exosome and packed at clean room type A. Culture for A/Una bacteria, fungi, direct smear, PCR for Mycoplasma, MTT test for toxin and also placental source analysis for viral infection were done. All Exosome vials were Stored at  $-4^{\circ}\text{C}$ , or room temperature (keep away from heat, Sun light, humidity) for 1 week or  $-70^{\circ}\text{C}$  for 3 months.

### Trial design

In this prospective, unicenter trial, we assigned mMCAI patients, to early hemicraniectomy and duraplasty with intraparenchymal injection of allogenic placenta MSC derived exosome at the site of infarction (N = 5).

The safety of a single dose- intraparenchymal injection of allogenic placenta MSC-Exo (356 µg/ml), were assessed via outcome evaluation. This trial has been approved and sponsored by ethic committee of Shahid Beheshti University of Medical Sciences, Tehran, Iran (IR.SBMU.REC.1398.062) and also received registration number NCT03384433. All participating

was conducted between 2019 and 2020. The participants of the study, or their legal representatives, signed an informed consent letter, after being notified regarding the aim of the study.

### Inclusion and exclusion

The inclusion criteria of the present study were as follow: 1) candidate of decompressive craniectomy due to mMCA infarction (ischemic infarction more than two-thirds of the MCA territory with progressive neurologic decline with midlineshift  $>5$  mm or other signs denoting to mass effect of ischemia) within 48 h of symptom initiation, 2) NIHSS  $\geq 14$ , in patients with an infarction in the non-dominant hemisphere, or  $\geq 19$ , in patients with an infarction in the dominant hemisphere, (total scores on the NIHSS range from 0 to 42, with higher scores indicating more severe stroke) and 3) the modified Rankin scale (mRS)  $\geq 2$  (on a scale of 0 to 6, with 0 indicating no symptoms and 6 indicating death).

Any of the participants meeting at least one of the following exclusion criteria were excluded from the study: 1) Glasgow Coma Scale (GCS) less than six, 2) hemorrhages or other associated brain lesions, 3) known systemic bleeding or coagulation disorder, 4) poor clinical condition for surgery, or 5) other concomitant severe diseases that would confound with treatment and participation in any other interventional trial.

### Surgical procedure

Decompressive craniectomy were performed within 48 h after symptom onset. In summary, under general anesthesia and in semi lateral supine position, after prep and drape in sterile fashion, a large reverse question-mark-shaped skin incision was made. Temporalis muscle shaved from squamous part of the temporal bone, generous pericranial patch harvested, a large fronto-temporo-parietal bone flap

with minimum dimension of 12 × 15 cm was deflected. The dura was opened in c-shape fashion. Tack ups on bony edges of craniectomy border performed. Surgical field irrigated with copious amount of warm sterile normal saline solution. Regarding pre-operative Brain MRI sequences and using frame-less stereotactic assistance, exosomes were applied locally in frontal lobe ischemia penumbra zone in 2 ml volume with 356 µg/ml concentration at speed injection of 1 mL/min. The product was injected in 2 cm depth by a navigated brain cannula which was kept in place for two minutes after injection to minimize the leakage. After injection duraplasty was performed in a water-tight fashion using autologous pericranial patch. Temporalis muscle repaired, a subgaleal drain was inserted and skin repaired in anatomic layers. Bone flap packed according to standard sterile protocols and sent to bone bank to be kept in a -70 C freezer (cryopreservation method). After surgery, the patients were transferred to the intensive care unit (ICU).

Efficacy of decompressive craniectomy was evaluated by post-operative CT scan in day 1 post-operation. Reduction of midline shift to <4 mm, relaxed basal cisterns, elimination of sulcal effacement and absence of new-onset hematoma were defined criteria for successful surgery.

In surviving patients, cranioplasty was performed after six-weeks to six-months of early decompression, using the autologous bone flap and titanium mini-plates and screws.

### Safety and clinical assessments

Providing evidence for the safe delivery of intracerebral injection of MSC-exo is the main aim the present study. Safety assessments and neurological status (NIHSS, and mRS) were examined before surgery, at discharge time, and 30 and 90 days after surgery. The patients were assessed for any acute or chronic side effects related to injection including Fever, chills, seizure, signs of anaphylaxis and CNS Infection. In addition, laboratory tests consist of blood analysis, and renal and liver functions were performed. Moreover, brain edema, and hemorrhagic transformation were assessed by CT scan after surgery.

## Results

### Characterization of MSCs

Osteogenic, and adipogenic differentiation was performed for potential differentiation of Placenta MSCs. [Figure 1b and c]. Transmission Electron microscopy examinations revealed cup-shaped vesicles in the preparations of human placenta-derived MSCs that measured 40–100 nm in diameter. [Figure 1d]. Flow cytometry analysis confirmed the exosome of MSC markers (CD63, CD81) more than 70% [Figure 1f] and the absence of CD45, CD31, CD34, HLA-DR and CD11b markers.

Five men with a mean age of 62 years were recruited between January, 2019, till September, 2020. All patients

had mMCAI with hemiplegia, hemi facial paresis and aphasia in patients with left hemisphere involvement (three with right hemisphere infarct and two of them had left hemisphere infarct). The data with details have been shown in Table 1.

Patients underwent decompressive craniectomy, and all received a dose of exosome in infarct penumbra region by frame-less stereotactic navigated cannula in one minute [Figure 2]. NIHSS and MRS for all patients were recorded in admission, discharge time, one and three months after surgery. Median follow-up after implantation was 90 days [Table 2].

All patients who received treatment were HLA negative before and after intervention. No serious adverse events were observed. At the site of injection was not observed any hematoma or local reaction as excessive edema. No infusion reaction or adverse events were observed in any patients within the first 72 h. None of the patients experienced meningitis, brain abscess or wound healing problems after infusion during the first month. Blood cell count and liver and renal function showed no significant differences at the 3-month follow-up point compared with baseline. At admission and during the follow up, no seizure was observed in any patients [Table 3].

One of patients was expired seven days after surgery, due to extension of ischemia and brain stem ischemia and also developed ventilator assisted pneumonia during hospitalization in the ICU.

Regards to mRS, disability at 3 months was unchanged in one patient- while two patients improved two grades from 5 to 3 and 4 to 2 [Table 2]. NIHSS in these patients also reduced from 11 to 2 and 18 to 8, respectively [Table 2].

## Discussion

As a small study in exosome implantation, the feasibility, tolerability, and allogeneic MSC-exosome-related safety of intraparenchymal injection in patients with mMCAI were examined. We observed no short-term or long-term (during three months) severe adverse events related to the procedure in any of the patients.

Concerning the previously published data in the literature, decompressive craniectomy may reduce mortality about 50% after mMCAI.<sup>[6]</sup> Most individuals are rescued from death by craniectomy suffer severe degrees of long-lasting postoperative disabilities.<sup>[5]</sup> Therefore, it is essential to recognize how to improve disability, quality of life, and clinical outcomes in these patients. Cell and exosome therapy have produced some hopes to modulate this concern. According to previous preclinical studies, SC-derived exosomes contribute to stroke treatment by increasing brain repair and immunomodulatory activities and have a substantial protective effect against hippocampal neuronal death by preventing of endothelial damage and BBB integrity preservation, and neutrophil infiltration decrement.<sup>[15]</sup>

**Table 1: Clinical and Biochemical Characteristics of Patients**

Patients (P)	P1	P2	P3	P4	P5
Age (y)	56	62	74	61	56
Sex	male	male	male	male	male
Weight (Kg)	70	90	88	70	85
Infarct territory	Right MCA	Right carotid/ Fetal PCA	Right MCA	Left MCA	Left MCA
Diabetes	Yes	No	No	Yes	No
Hypertension	Yes	No	No	Yes	No
Hyperlipidemia	Yes	No	yes	No	No
Recurrent stroke	No	Yes	-	No	No
Atrial Fibrillation	No	No	Yes	No	No
Smoker	No	No	Yes	No	No
Ischemic heart disease	No	No	Yes	No	No
MI	No	No	No	Yes	No
Endocarditis	Yes	No	No	No	No
Drinker	No	No	No	No	No
OSAS	No	No	No	No	No
Stroke subtype	Acute Ischemic	Acute Ischemic	Acute Ischemic	Acute Ischemic	Ischemic large vessel
Aspirin/clopidogel	No	Yes	Yes	Yes	No
ACE inhibitor or ARB	No	No	Yes	Yes	No
Ca <sup>2+</sup> -channel blocker	No	No	No	No	No
Hypoglycemic agent	No	No	Yes	Yes	No
Time from onset to Exosome therapy, hours	4	30	36	15	27
rTPA	Yes	No	Yes	No	No
Pro-Coagulant drugs	No	No	Yes	No	No
Statin	yes	No	yes	yes	No
CRP	27.6	19.8	103.8	136.8	19.1
Bun/Cr	10/0.73	22/1.19	33/1.76	19/1.3	15/0.99
k	3.8	4.2	4.1	3.5	3.8
Na	135	141.7	128	143	140
INR	1	1.1	2.9	1.7	1.1/1
PTT	30	35	67	95	33/30
PT	13	14	25.7	18	13.7/13
Plt	281	325	174	139	186/226
Hb	11.7	13.6	7.6	9.7	10.9
WBC	10.6	19.4	17.1	8.9	5900/10000
ESR	40	25	25	80	23/110

OSAS, obstructive sleep apnea syndrome; ACE, angiotensin-converting enzyme; ARB, enzyme receptor blocker

**Table 2: Stroke characteristic and follow up before and one and three after implantation**

Patients	GCS (before/1, 3 months after injection)	NIHSS (before and 1, 3 month after Exosome injection)	MRS (before and 1, 3 month after Exosome injection)	CRP (Before Exo injection/1 month After Exo Injection)
P1	14/15/15	11/2/2	4/2/2	27.6/3
P2	6/3	25/25	5/6	19/8
P3	13/3/8	18/10/9	5/4/3	5/1
P4	11/6/10	16/14/13	5/5/3	1/1
P5	10/13/13	18/18/8	5/4/4	19.1/8

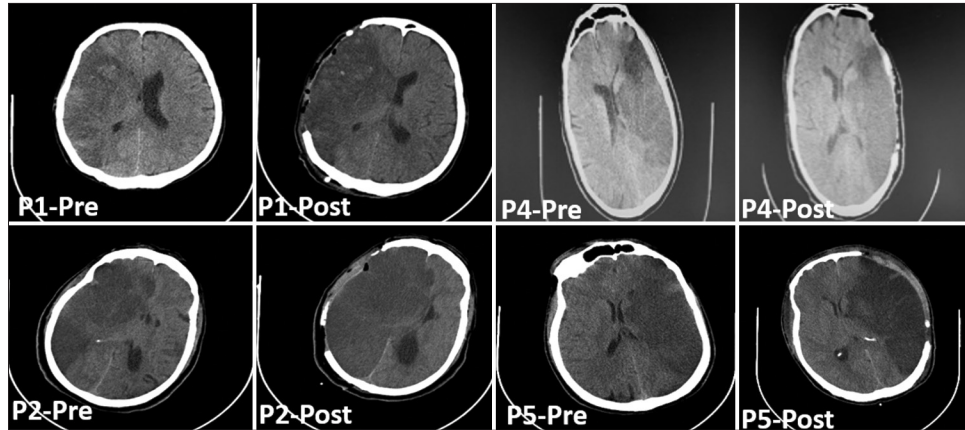
In four patients, some improvements were achieved in several functional indices on the modified Rankin Scale, three months after the stroke. Given that the study is conducted with few patients by open-label single-arm study design, reliable conclusions about effectiveness could not be drawn. Indeed, this study's primary purpose is to assess

the safety and feasibility of intraparenchymal injection of exosome to the brain when treating acute stroke and no side effect was seen.

Based on previous literature, better motor and recovery results were reported in stroke patients for intravenous injection of exosomes.<sup>[16]</sup> Low mobility and poor

**Table 3: Safety assessments**

Patients	Post-injection site hematoma	Need to pack cell during surgery	GI Bleeding/liver and renal function/recurrent stroke	Allergic reaction	Fever (Before/After)
1	NO	NO	NO	No	Yes/No
2	No	No	No	No	Yes/Yes
3	No	No	No	No	No/No
4	No	No	No	No	No/No
5	No	No	No	No	No/No

**Figure 2: Computed Tomography (CT) Scans of patient Pre and Post Operation from, P1 to P5**

diffusion of stem cells, beyond the site of injection, are the major shortcomings of the intravenous route of administration.<sup>[11,17,18]</sup> In addition, there is a possibility of embolism and cell engraftment through the intravenous injection.<sup>[19]</sup> Therefore, the intracerebral route of administration may predispose the subjects to fewer complications, as its functions can be regulated by diffuse paracrine or peripherally mediated therapeutic effects.

Regarding the protection against secondary damage and expansion of the infarct region, exosomes lower the expression of apoptosis indicators in the lesion zone- cleaved caspase 3 and cleaved poly ADP-ribose polymerase (PARP). Moreover, in animal studies, the expression of markers associated with DNA and mitochondrial damage was reduced. A bright future is expected for brain protection through exosome therapy.<sup>[16,20]</sup>

Exosome administration can result in increased neurogenesis (shown by elevated densities of doublecortin and NeuN+ neurons) in the damaged zone.<sup>[21]</sup> Besides, it increases of CD31+ BrdU+ cells which confirms the presence of new endothelial cells.<sup>[22]</sup> An increase in the expression of the Von Willebrand factor and the small number of vessels shows more endothelial integrity and angiogenesis.<sup>[16]</sup> Administration of exosomes can also help limit the immunosuppression caused by stroke. Activation of CD4 and CD6 T lymphocytes and the decrease of the decline in dendritic cells can be intensified by MSC exosomes.<sup>[23]</sup> In animal studies, the increase in oligodendrogenesis-associated markers (2',

3'-cyclic-nucleotide 3'-phosphodiesterase [CNPase], A2B5, and myelin oligodendrocyte glycoprotein) are associated with the white matter repair.<sup>[24,25]</sup>

Considering the beneficial effects of exosome in reducing inflammation and up-regulating the motor repair, it may serve as a suitable candidate to modulate and prevent the destructive effects of ischemic stroke.

### Limitations of the study

The first limitation of the present work that we would like to mention is the few number of patients in our study, as only five patients received the selected dose regards to aim of the study as safety and feasibility assessment. Secondly, safety was only assessed in a three-month follow-up period, and safety issues that would occur in more extended periods are not investigated. Third limitation of the study was that mean age of the cases was approximately 62 which is a negative predictor is CVA outcome. on the other hand, all the patients were male which limits the generalizability of the study to all genders. Finally, as exosome treatment is still developing, many questions are yet to be answered before considering this method as a routinely performed procedure in clinics. The most effective administration route, dosage considerations, the time of administrations, long-term safety, and probable adverse effects are topics demanding further investigations in future research programs.

### Conclusions

Exosome-based therapy for stroke has just started to flourish, and we need more studies before thoroughly

embarking on clinical practice. Preclinical studies can contribute to the practical use of exosomes' therapeutic potential for treating mMCAI/stroke through feasibility and safety tests in humans. Intracerebral implantation of MSC-EXO showed no post-interventional adverse effects in five ischemic stroke patients. To the best of our knowledge, no human studies are conducted as yet, and it is remarkably the first study that applies MSC-EXO in stroke patients, with no post-interventional adverse effects. More longitudinal clinical studies are needed to confirm the safety and to assess the efficacy of intracerebral implantation of MSC-EXO to prevent post ischemic neurological deficits.

### Declaration of patient consent

The authors certify that they have obtained all appropriate patient consent forms. In the form the patient(s) has/have given his/her/their consent for his/her/their images and other clinical information to be reported in the journal. The patients understand that their names and initials will not be published and due efforts will be made to conceal their identity, but anonymity cannot be guaranteed.

### Acknowledgments

This study is extracted from PhD thesis of Leila Dehghani, School of Advanced Technologies in Medicine, Shahid Beheshti University of Medical Sciences, Tehran, Iran. We also appreciate all authors and patients who take part in study.

### Financial support and sponsorship

This study was granted at School of Advanced Technologies in Medicine, Shahid Beheshti University of Medical Sciences, Tehran, Iran (Project NO. 17877 IR.SBMU.REC.1398.062).

### Conflicts of interest

There are no conflicts of interest.

**Received:** 11 Oct 21 **Accepted:** 12 Oct 21

**Published:** 19 Jan 22

### References

1. Treadwell SD, Thanvi B. Malignant Middle cerebral artery (MCA) infarction: Pathophysiology, diagnosis and management. *Postgrad Med J* 2010;86:235-42.
2. Lammy S, Al-Romhain B, Osborne L, George EJS. 10-year institutional retrospective case series of decompressive craniectomy for malignant middle cerebral artery infarction (mMCAI). *World Neurosurg* 2016;96:383-9.
3. Hatefi D, Hirshman B, Leys D, Lejeune J-P, Marshall L, Carter BS, *et al.* Hemicraniectomy in the management of malignant middle cerebral artery infarction: Lessons from randomized, controlled trials. *Surg Neurol Int* 2014;5:72.
4. Vahedi K, Hofmeijer J, Juettler E, Vicaud E, George B, Algra A, *et al.* Early decompressive surgery in malignant infarction of the middle cerebral artery: A pooled analysis of three randomised controlled trials. *Lancet Neurol* 2007;6:215-22.
5. Gupta R, Connolly ES, Mayer S, Elkind MS. Hemicraniectomy for massive middle cerebral artery territory infarction: A systematic review. *Stroke* 2004;35:539-43.
6. Das S, Mitchell P, Ross N, Whitfield PC. Decompressive hemicraniectomy in the treatment of malignant middle cerebral artery infarction: A meta-analysis. *World Neurosurg* 2019;123:8-16.
7. Peplow PV, Martinez B, Mascareñas D, Dambinova SA. Neuroplasticity biomarkers in experimental stroke recovery. *Stroke Biomarkers*. Springer; 2020. p. 35-59.
8. Otero-Ortega L, Laso-García F, del Carmen Gómez-de Frutos M, Rodríguez-Frutos B, Pascual-Guerra J, Fuentes B, *et al.* White matter repair after extracellular vesicles administration in an experimental animal model of subcortical stroke. *Sci Rep* 2017;7:44433.
9. Zivin JA. Acute stroke therapy with tissue plasminogen activator (tPA) since it was approved by the U.S. Food and drug administration (FDA). *Ann Neurol* 2009;66:6-10.
10. Théry C, Witwer KW, Aikawa E, Alcaraz MJ, Anderson JD, Andriantsitohaina R, *et al.* Minimal information for studies of extracellular vesicles 2018 (MISEV2018): A position statement of the International society for extracellular vesicles and update of the MISEV2014 guidelines. *J Extracell Vesicles* 2018;7:1535750.
11. Campbell BC, Mitchell PJ, Kleinig TJ, Dewey HM, Churilov L, Yassi N, *et al.* Endovascular therapy for ischemic stroke with perfusion-imaging selection. *N Engl J Med* 2015;372:1009-18.
12. Lo EH, Dalkara T, Moskowitz MA. Mechanisms, challenges and opportunities in stroke. *Nat Rev Neurosci* 2003;4:399-414.
13. Zhang ZG, Buller B, Chopp M. Exosomes — Beyond stem cells for restorative therapy in stroke and neurological injury. *Nat Rev Neurol* 2019;15:193-203.
14. Adeoye O, Hornung R, Khatri P, Kleindorfer D. Recombinant tissue-type plasminogen activator use for ischemic stroke in the United States: A doubling of treatment rates over the course of 5 years. *Stroke* 2011;42:1952-5.
15. Dehghani L, Hashemi SM, Saadatnia M, Zali A, Oraee-Yazdani S, Keshel SH, *et al.* Stem cell-derived exosomes as treatment for stroke: A systematic review. *Stem Cell Rev Rep* 2021;17:428-38.
16. Chen K-H, Chen C-H, Wallace CG, Yuen C-M, Kao G-S, Chen Y-L, *et al.* Intravenous administration of xenogenic Adipose-derived mesenchymal stem cells (ADMSC) and ADMSC-derived exosomes markedly reduced brain infarct volume and preserved neurological function in rat after acute ischemic stroke. *Oncotarget* 2016;7:74537-56.
17. Ikegame Y, Yamashita K, Hayashi S-I, Mizuno H, Tawada M, You F, *et al.* Comparison of mesenchymal stem cells from adipose tissue and bone marrow for ischemic stroke therapy. *Cytotherapy* 2011;13:675-85.
18. Moher D, Shamseer L, Clarke M, Ghersi D, Liberati A, Petticrew M, *et al.* Preferred reporting items for systematic review and meta-analysis protocols (PRISMA-P) 2015 statement. *Syst Rev* 2015;4:1.
19. Kean TJ, Lin P, Caplan AI, Dennis JE. MSCs: Delivery routes and engraftment, cell-targeting strategies, and immune modulation. *Stem Cells Int* 2013;2013:Article ID 732742, 13 pages. doi: 10.1155/2013/732742.
20. Dehghani L, Khojasteh A, Oraee YS, Oustad M, Soleimani M. Role of mesenchymal stem cells derived exosomes therapy in neuronal remodeling after ischemic stroke. *Minerva Med* 2019. doi: 10.23736/S0026-4806.19.06277-3.
21. Chen SY, Lin Mc, Tsai JS, He PL, Luo WT, Chiu IM, *et al.* Exosomal 2',3'-CNP from mesenchymal stem cells promotes hippocampus CA1 neurogenesis/neuritogenesis and contributes

- to rescue of cognition/learning deficiencies of damaged brain. *Stem Cells Transl Med* 2020;9:499-517.
22. Doeppner TR, Herz J, Görgens A, Schlechter J, Ludwig A-K, Radtke S, *et al.* Extracellular vesicles improve post-stroke neuroregeneration and prevent postischemic immunosuppression. *Stem Cells Transl Med* 2015;4:1131-43.
  23. Ueno Y, Hira K, Miyamoto N, Kijima C, Inaba T, Hattori N. Pleiotropic effects of exosomes as a therapy for stroke recovery. *Int J Mol Sci* 2020;21:6894.
  24. Otero-Ortega L, Gutiérrez-Fernández M, Ramos-Cejudo J, Rodríguez-Frutos B, Fuentes B, Sobrino T, *et al.* White matter injury restoration after stem cell administration in subcortical ischemic stroke. *Stem Cell Res Ther* 2015;6:121.
  25. Xin H, Li Y, Cui Y, Yang JJ, Zhang ZG, Chopp M. Systemic administration of exosomes released from mesenchymal stromal cells promote functional recovery and neurovascular plasticity after stroke in rats. *J Cereb Blood Flow Metab* 2013;33:1711-5.