



Contents lists available at ScienceDirect

International Journal of Surgery Case Reports

journal homepage: www.casereports.com

Gallbladder volvulus, a rare cause of acute abdomen, a case report

M. Bouzas Cardaci*, C.V. Bivoleanu

Department of Visceral Surgery CSF, Belgium

ARTICLE INFO

Article history:

Received 15 June 2020

Received in revised form 1 September 2020

Accepted 1 September 2020

Available online 6 September 2020

Keywords:

Volvulus of the gallbladder

Gallbladder torsion

Cholecystitis

Cholecystectomy

ABSTRACT

INTRODUCTION: The gallbladder volvulus is a rare surgical emergency and its defined as the rotation of the gallbladder on its mesentery along the axis of the cystic duct and cystic artery. Definitive diagnosis is usually made during surgery and a delay in treatment may result in a high mortality due to rupture of gall bladder and bile peritonitis.

CASE PRESENTATION: We report the case of an 88-year-old woman who presented with an acute torsion of gall bladder, which was treated promptly after admission by laparoscopic cholecystectomy.

DISCUSSION: Acute torsion of gall bladder is a rare disease. Its pathogenesis is not well known but postulated to be multifactorial. Two anatomic variants that predispose to gall bladder torsion have been described. Clinical presentation is not specific, with symptoms and biologic signs that mimic acute cholecystitis.

This condition should be suspected in elderly women with uncertain diagnosis of acute cholecystitis or acute abdominal pain of unknown origin.

CONCLUSION: Gallbladder volvulus is a rare life-threatening surgical emergency that requires emergency surgical treatment. Out- come is often favorable when early diagnosis and surgery are made.

© 2020 Published by Elsevier Ltd on behalf of IJS Publishing Group Ltd. This is an open access article under the CC BY-NC-ND license (<http://creativecommons.org/licenses/by-nc-nd/4.0/>).

1. Introduction

First reported by Wendel in 1898 [1], volvulus of the gallbladder is a relatively uncommon phenomenon, that presents as acute abdomen and often leads to significant morbidity due to the delay in diagnosis and surgical treatment.

Since its initial description, over 500 cases of gallbladder torsion have been reported and although recent advances in radiographic finding have helped in the diagnosis of many diseases, abdominal computed tomography (CT) and ultrasonography (US) remain nonspecific in diagnosing volvulus of the gallbladder [2,3].

Gallbladder torsion is predominantly a condition of the elderly affecting those between the ages of 60 and 80, however, children can also be affected. There is an incidence of one in 365,520 hospital admissions with a female preponderance ratio of 3:1.4. It carries an associated mortality of 6% [2].

The exact etiology of gallbladder torsion remains unknown, although certain anatomical variants are thought to predispose to torsion. Volvulus can be classified as incomplete, in which rotation is 180 degrees, or complete, in which rotation is >180 degrees. The torsion directly affects the blood supply to the gallbladder causing infarction. With prompt surgical intervention, the potential for gall-

bladder gangrene and perforation can be averted and an excellent prognosis is achieved [2,4,5].

The authors report the case of an 88-year-old woman who presented with an acute torsion of gall bladder, treated with laparoscopic cholecystectomy.

2. Case presentation

A Caucasian 88-year-old female presented to the emergency department with a 12-h onset of colicky right hypochondrial pain. There has not been previous episodes of similar pain and the patient had no other related symptoms.

Her background included hypertension and dyslipidaemia.

On physical examination she had a temperature of 36.4 °C. Blood pressure was 142/75 mmHg and pulse rate was 88 b.p.m.

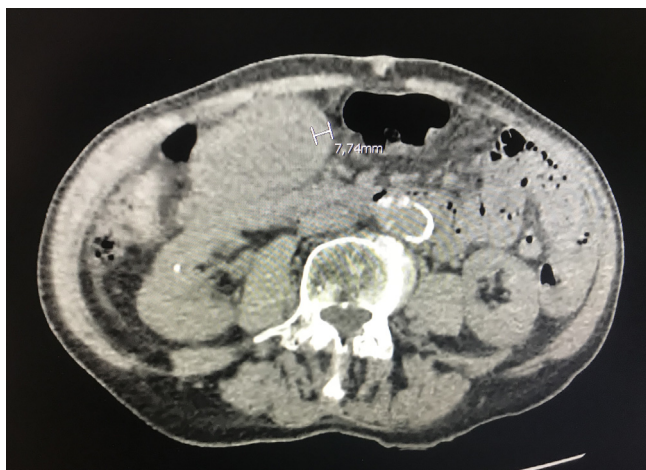
The abdomen was soft and not distended, with diffuse tenderness in the right upper quadrant.

All blood tests were within normal limits including a white blood cell counts (WBC), C-reactive protein (CRP) and liver function test.

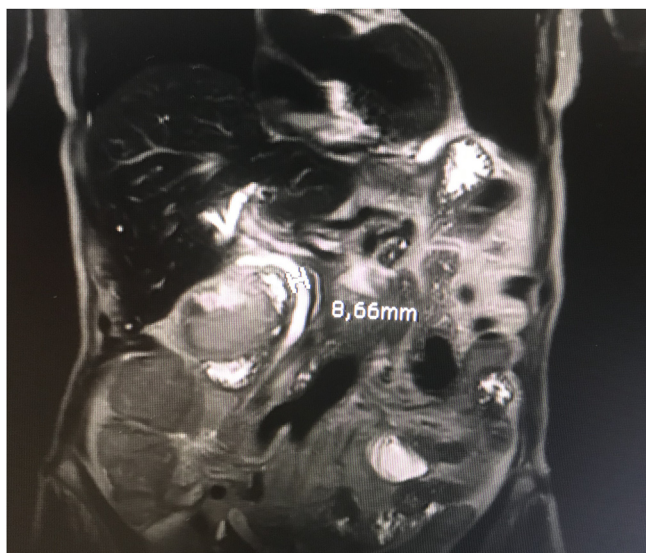
In the emergency room, the first radiological study carried out was CT that showed a largely distended gallbladder with asymmetrical thickening of the wall but nevertheless without infiltration of the peri vesicular fat, pericholecystic fluids or any other sign of cholecystitis. There was no shift in the position of the gallbladder (Picture 1).

* Corresponding author at: CSF Chimay, Boulevard Louise 18, 6460, Chimay, Belgium.

E-mail address: bouzas_m@hotmail.com (M. Bouzas Cardaci).



Picture 1. CT that showed a largely distended gallbladder with asymmetrical thickening of the wall without signs of cholecystitis.



Picture 2. MRCP confirming acalculous cholecystitis and lack of malignancy.

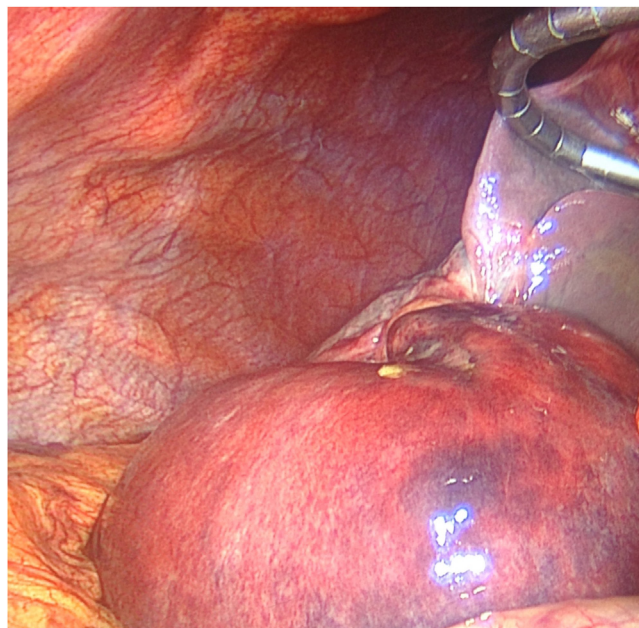
US was then performed and also showed a distended gallbladder and an asymmetrical gallbladder wall thickening to 14 mm but no evidence of gallstones, sludge, or signs of acute cholecystitis. Tapering interruption of the cystic duct was not described by the radiologist.

Given the absence of signs of cholecystitis as well as the age of the patient, the diagnosis of probable carcinoma of the gallbladder was therefore suspect and the patient was admitted to the digestive surgery department.

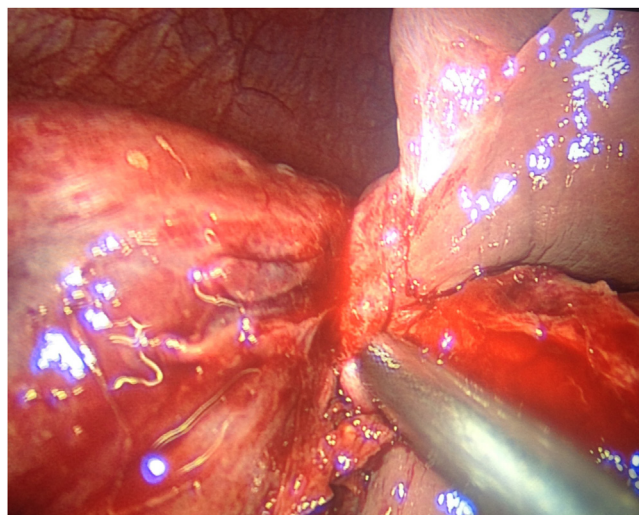
48 h after admission, Magnetic Resonance Cholangiopancreatography (MRCP) was performed and demonstrated a distended gallbladder with wall thickening edema, and pericholecystic fluid confirming acalculous cholecystitis as well as lack of malignancy seen on axial imaging (Picture 2).

There were no abnormal values in the blood coagulation studies, and the tumor marker levels, including carcinoembryonic antigen and CA19-9, were also normal.

After 48 h of observation with only analgesics and simultaneous fluids resuscitation, the patient's clinical status did not improve and she complained of persistent abdominal pain as well as an increase in the values of the CRP up to 71. The rest of the blood test remained within the norms.



Picture 3. Distended and gangrenous gallbladder.



Picture 4. Torsion in 180 degrees in anti-clockwise direction.

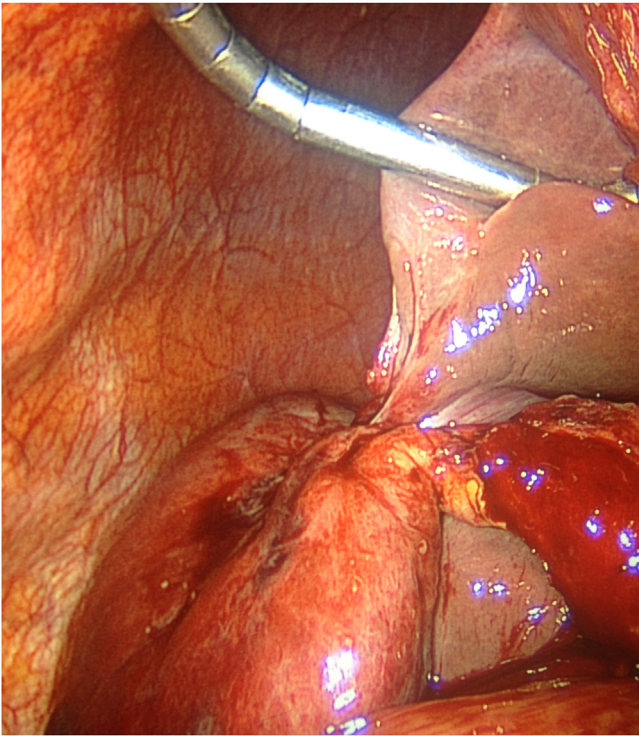
The decision was made to undergo exploratory laparoscopic.

The operative findings showed that the gallbladder was dark red, necrotic, distended, and enlarged (Picture 3). The only attachment appeared to be the gallbladder and cystic duct to the inferior surface of the liver by mesentery on which the gallbladder had twisted 180 degrees in an anti-clockwise direction (Picture 4).

A diagnosis of gallbladder torsion complicating Gross-I [6] was made and cholecystectomy was performed.

It was necessary to unravel the torted pedicle before proceeding with the dissection (Picture 5) and then the cholecystectomy was carried out without major incidents.

Patient recovery was uneventful. The patient was discharged on postoperative day 3. The pathology showed hemorrhagic necrosis in the wall and severe inflammatory cell infiltration throughout its thickness.



Picture 5. Detorsion of the gallbladder.

3. Discussion

An acute torsion of gall bladder is a rare surgical emergency and preoperative diagnosis is always difficult. A delay in treatment may result in a high mortality due to rupture of gall bladder and bile peritonitis.

Its pathogenesis is not well known but postulated to be multifactorial. Liver atrophy, loss of visceral fat and elasticity with ageing, kyphoscoliosis, and weight loss are predisposing factors that place the gall bladder in a more dependent position. Arteriosclerosis with a long, tortuous and rigid cystic artery, violent movement of the adjacent organ, cholelithiasis with acute dilatation of gall bladder are other precipitating factors contributing to the development of a rigid fulcrum for torsion of the gall bladder. Gallstones are considered incidental rather than causative when found in patients with gallbladder volvulus [7–9].

In young patients, the torsion can reduce spontaneously because elasticity of the supporting structures is still present. A congenital mesentery is present in 5% of the general population, suggesting that the mechanism probably develops with age [10].

Two anatomic variants that predispose to gall bladder torsion have been described by Gross [6]. Type I is defined as attachment of the gallbladder and cystic duct to the inferior surface of the liver by mesentery, and type II as attachment of only the cystic duct to the liver. Carter et al. [11] classify gallbladder torsion on the basis of the degree of rotation into a 'complete' type, in which the degree of rotation exceeds 180 degrees and natural detorsion is impossible, and an 'incomplete' type, in which the rotation is less than 180 degrees and natural detorsion is possible. Both clockwise and anticlockwise rotation have been described; it has been proposed that clockwise rotation occurs as a result of gastric and duodenal peristalsis, whereas anticlockwise rotation is secondary to colonic peristalsis [4].

Clinical findings are not specific and could include abdominal pain, nausea and vomiting, palpable mass, fever and rarely, jaundice. Lau et al. first described the 'triad of triads', involving

appearance (elderly, thin, spinal deformities), symptoms (sudden onset, right upper quadrant pain, early emesis) and examination (non-toxic presentation, palpable abdominal mass and pulse–temperature discrepancy) [8].

The patient in this case report satisfied 6 of the 9 features described by Lau, that is: elderly, thin, spinal deformities (scoliosis), sudden onset, right upper quadrant pain and non-toxic presentation.

Laboratory investigations typically show a normal to elevated WBC. Liver function tests are normal as the common bile duct remains unobstructed [4].

In this case, the patient did not present any alteration in the blood tests on admission, however, during hospitalization, elevation of the CRP without leukocytosis was noted after 48 h of admission.

Although recent advances in radiographic studies have helped in the diagnosis of many diseases, radiographic studies remain non-specific in diagnosing volvulus of the gallbladder. Fewer than a dozen cases have been reported in the literature where a preoperative diagnosis was made. Ultrasound studies often reveal a large floating gallbladder without gallstones, and a thickened gallbladder wall. Specific US signs seen with gallbladder torsion include the presence of the gallbladder outside its normal anatomic fossa, inferior to the liver or in a transverse orientation with an echogenic conical structure. Additionally, CT findings are also non specific. A few cases of CT diagnosis of gallbladder torsion commented on radiographic findings of marked enlargement of the gallbladder with an unusual shape and configuration. MRCP has been used to establish a diagnosis preoperatively. MRCP findings include high signal intensity within the gallbladder wall on T1 weighted images, suggesting necrosis and hemorrhage consistent with gallbladder torsion [3].

In this case, none of the radiological signs that could have guided the diagnosis of gallbladder volvulus were reported by radiologists.

When US shows a large horizontalized gallbladder with no obstructing stone, gallbladder volvulus must be suspected, and the twisted cystic pedicle has to be searched for. In case of doubt, other imaging techniques such as CT can be used to increase the preoperative diagnostic accuracy, demonstrating a low-lying distended horizontalized gallbladder, twisted on its cystic mesentery: small "whirlpool sign" (as in midgut volvulus), with a beaked-shape neck: "beak sign," sometimes a poor enhancement of the gallbladder wall. This combination of CT scan signs was recently described and allows preoperative diagnosis [12].

In addition, preoperative diagnosis is also delayed since clinical features overlap with other acute gallbladder conditions. The distinction between torsion and acute calculous cholecystitis is difficult but important; while cholecystitis can initially be treated conservatively, delay in intervention could prove fatal in the setting of gallbladder torsion. Torsion of the gallbladder has a mortality rate of 6%. Thus, early diagnosis and prompt intervention can reduce the mortality associated with this condition [4].

Nakao et al. [13] summarized in a table the features of gallbladder torsion to make a differential diagnostic between acute cholecystitis and gallbladder volvulus.

This case is therefore an excellent example of why gallbladder volvulus should be considered as a differential diagnosis in all patients with uncertain diagnosis of acute cholecystitis fulfilling the majority of the triad of triads despite equivocal radiological findings.

4. Conclusions

Gallbladder volvulus, or gallbladder torsion, is a rare condition predominantly occurring in elderly women and should be consid-

ered when clinical and imaging findings of cholecystitis are not specifics or unclear.

The performance of urgent laparoscopic surgery would be first option to avoid perforation and peritonitis. With prompt surgical intervention, the condition has an excellent prognosis.

Declaration of Competing Interest

All authors declare that they have no conflict of interest

Funding

No sources of funding.

Ethical approval

The study is exempt from ethnical approval.

Consent

Written informed consent was obtained from the patient for publication of this case report and accompanying images. A copy of the written consent is available for review by the Editor-in-Chief of this journal on request.

Author contribution

Miguel Bouzas Cardaci: writing the paper.
Ion Surdeanu: writing the paper.
Cristian Bivoleanu: writing the paper.

Registration of research studies

N/A.

Guarantor

Miguel Bouzas Cardaci .

Provenance and peer review

Not commissioned, externally peer-reviewed.

References

- [1] A.V. Wendel VI, A case of floating gallbladder and kidney complicated by Cholelithiasis, with perforation of the gall-bladder, *Ann. Surg.* 27 (February (2)) (1898) 199–202.
- [2] D.J. Reilly, G. Kalogeropoulos, D. Thiruchelvam, Torsion of the gallbladder: a systematic review, *HPB (Oxford)* 14 (October (10)) (2012) 669–672, <http://dx.doi.org/10.1111/j.1477-2574.2012.00513.x>, Epub 2012 Jul.
- [3] N. Matsuhashi, S. Satake, K. Yawata, et al., Volvulus of the gallbladder diagnosed by ultrasonography, computed tomography, coronalmagnetic resonance imaging and magnetic resonance cholangio-pancreatography, *World J. Gastroenterol.* 12 (July (28)) (2006) 4599–4601.
- [4] George Younan, Max Schumm, Fadwa Ali, et al., Gallbladder volvulus in a patient with type I choledochal cyst: a case report and review of the literature, *Case Rep. Surg.* 2016 (2016), 5626531.
- [5] Yang Hwang, Krish Kulendran, Jack Ashworth, Expect the unexpected: torsion of the gallbladder, a rare cause for acute cholecystitis, *Cureus* 10 (December (12)) (2018) e3726.
- [6] R.E. Gross, Congenital anomalies of the gallbladder, review of one. Hundred and forty-eight cases, with report of a double gallbladder, *Arch Surg.* 32 (1) (1936) 131–162.
- [7] A. Levene, Acute torsion of the gallbladder; post-mortem findings in two cases, *Br. J. Surg.* 45 (January (192)) (1958) 338–340.
- [8] W.Y. Lau, S.T. Fan, S.H. Wong, Acute torsion of the gall bladder in the aged: a re-emphasis on clinical diagnosis, *Aust. N. Z. J. Surg.* 52 (October (5)) (1982) 492–494.
- [9] E.D. Arslan, O. Hakbilir, B. Uyanik, et al., Gallbladder volvulus, *J. Pak. Med. Assoc.* 62 (September (9)) (2012) 965–966.
- [10] P.C. Garcivilla, J.F. Alvarez, G.V. Uzqueda, Diagnosis and laparoscopic approach to gallbladder torsion and cholelithiasis, *JSLs* 14 (January-March (1)) (2010) 147–151.
- [11] R. Carter, R.J. Thompson Jr., L.P. Brennan, et al., Volvulus of the gallbladder, *Surg. Gynecol. Obstet.* 116 (January) (1963) 105–108.
- [12] C. Escalard, A. Calinghen, N. Habchi, Gallbladder volvulus: a rare cause of acute gallbladder distension, *J. Gastroenterol. Hepatol.* 34 (July (7)) (2019) 1133.
- [13] A. Nakao, T. Matsuda, S. Funabiki, et al., Gallbladder torsion: case report and review of 245 cases reported in the Japanese literature, *J. Hepatobiliary. Surg.* 6 (4) (1999) 418–421.

Open Access

This article is published Open Access at [sciencedirect.com](https://www.sciencedirect.com). It is distributed under the [IJSCR Supplemental terms and conditions](#), which permits unrestricted non commercial use, distribution, and reproduction in any medium, provided the original authors and source are credited.