



Case Report

Clival simple bone cyst: Rare pathological entity (case report)

Jumana Abdulmohsen Fatani¹, Alaa Arab², Hisham Alkhalidi³, Abdulrazag Ajlan⁴

¹Intern, College of Medicine, King Saud University, ²Department of Neurosurgery, King Abdulaziz Medical City, ³Department of Pathology, King Saud University, ⁴Department of Neurosurgery, King Saud University Medical City, Riyadh, Saudi Arabia.

E-mail: *Jumana Abdulmohsen Fatani - jumana95f@gmail.com; Alaa Arab - ala_arab@yahoo.com; Hisham Alkhalidi - hishamkh@gmail.com; Abdulrazag Ajlan - Dr_ajlan79@hotmail.com

*Corresponding author:

Jumana Abdulmohsen Fatani,
College of Medicine, King
Saud University, Riyadh 11564,
Saudi Arabia.

jumana95f@gmail.com

Received : 30 July 2020

Accepted : 25 November 2020

Published : 11 December 2020

DOI

10.25259/SNI_478_2020

Quick Response Code:



ABSTRACT

Background: Clival cystic lesions are not frequently seen in neurosurgery. Cystic lesion in the clivus can be part of a neoplastic process such as chordoma, chondrosarcoma, plasmacytoma, or metastasis. Rare types of pure cystic clival lesions include simple bone cysts and arachnoid cysts, which are asymptomatic most of the time and do not cause symptoms until they reach a large size.

Case Description: This is a case report of a healthy 53-year-old male patient with a clival cystic lesion. The patient underwent surgical drainage and wall resection of the clival lesion with no postoperative complications. Intraoperative finding raised the possibility of the diagnosis of an arachnoid cyst. However, the pathology findings indicated a simple bone cyst.

Conclusion: Simple bone cyst and arachnoid cyst in the clivus are rare, they should be considered in the diagnosis of clival cystic lesions.

Keywords: Arachnoid, Clivus, Simple cyst

INTRODUCTION

Clival lesions are not uncommonly encountered in neurosurgery. Cystic lesion in the clivus can be part of a neoplastic process such as chordoma, chondrosarcoma, plasmacytoma, or metastasis.^[1,2] Rare types of pure cystic clival lesions include simple bone cysts and arachnoid cysts.^[9] Usually, simple bone cysts are asymptomatic and predominantly detected incidentally on radiographs.^[14,15] We present a case of an incidental finding of a large clival cystic lesion that was operated by transnasal endoscopic approach for exploration and resection.

CASE DESCRIPTION

History and examination

This is a healthy 53-year-old male with an unremarkable medical or surgical history, who has a 6-month history of progressive neck pain that radiates to his right and left shoulders. The patients' pain, which was alleviated by analgesia and physiotherapy, increased when he lay flat

This is an open-access article distributed under the terms of the Creative Commons Attribution-Non Commercial-Share Alike 4.0 License, which allows others to remix, tweak, and build upon the work non-commercially, as long as the author is credited and the new creations are licensed under the identical terms.

©2020 Published by Scientific Scholar on behalf of Surgical Neurology International

or on his left side. His neurological examination, including a cranial nerves exam, indicated normal findings. There was no history of trauma or sinus disease.

Imaging

Imaging of the cervical spine and brain was performed. The brain magnetic resonance imaging (MRI) [Figure 1 a-n] showed a well-defined mildly expansile bone lesion in the clivus with low T1 and high T2 signal intensity with nearly complete suppression of signal intensity on fluid attenuated inversion recovery. No contrast enhancement or solid tissue was identified. There is a mild posterior expansion of the clivus, which caused effacement of the prepontine cistern, mild collapse of the clivus, and relatively acute angulation of the clivus canal angle. Surgery was discussed to perform a biopsy and reach a diagnosis.

Operative procedure

The patient underwent transnasal endoscopic resection of the clival lesion in collaboration with the ear, nose, and throat team using neuronavigation. The superior margin of the clival lesion was identified by neuronavigation, and then trepanation of the anterior portion of the clivus was performed using a high-speed drill [Figure 1 o-p]. A gush of clear colorless fluid leaked under high-pressure. Direct communication was detected between the subarachnoid space and the cyst through a dural defect. The cyst wall was a direct continuation of the arachnoid membrane. Specimens were taken from the bone, cyst wall, and cavity and were sent for analysis. The intraoperative fresh frozen section was inconclusive. A fat graft was obtained from the thigh, placed in the cystic bony cavity and supported by a synthetic plate and septal flap. There were no intraoperative complications, and the patient was transferred to the recovery room in stable condition for observation.

Pathology

The specimens taken from the bone, cyst wall, and cavity consisted of a fragmented white tan hemorrhagic bony and soft tissue. Microscopy [Figure 2] confirmed fragments of bone with focal degeneration and fragments of fibrous tissue with foci hemosiderin deposition (indicates old hemorrhage). There was no intact defining cyst lining identified and no evidence of neoplastic process. The findings were consistent with a clival simple bone cyst.

DISCUSSION

Clival simple bone cyst and arachnoid cyst at the clivus are rarely encountered in neurosurgery.^[4,9]

Simple bone cysts are benign lesions that can affect nearly any bone;^[9] they account for 3% of all primary bone lesions.^[14,16]

However, the cause of simple bone cysts is still unknown.^[14] Bone cysts are commonly seen in childhood and adolescence and less commonly in adults, where they usually occur in unusual sites.^[13,16] In general, bone cysts arise in long bones.^[14] Limited cases of simple cysts were detected in the cervical spine.^[3,6,17] None of these cases were associated with a clival lesion. A simple bone cyst can be empty or filled with fluid;^[12] usually, simple bone cysts are asymptomatic^[14,15] and may go undetected until they reach a large size.^[13] As bone cysts expand, they can present as pain, swelling, or pathological fracture at the site of the cyst,^[14] but most of the time they are detected incidentally on radiographs.^[15] On T1-weighted MRI, simple bone cysts appear to have low signal intensity, while on T2-weighted MRI, they have high signal intensity.^[14] A biopsy might be required in cases in which the simple bone cyst appears to be in a location other than long tubular bones.^[5] The best treatment for simple bone cysts is still uncertain. The recurrence rate in simple bone cysts is high especially in young patients; surgical intervention might be considered if the cysts were in unusual sites.^[3] If simple bone cyst was identified in a flat bone, surgical management may not be required.^[5]

On the other hand, arachnoid cyst is a developmental collection of cerebrospinal fluid (CSF) within the arachnoid membranes. Most of the time, these cysts are detected incidentally, but they may expand progressively and cause symptoms by increasing the intracranial pressure or compressing nearby neural structures.^[8,11] Surgical management is required in case of increased intracranial pressure and symptomatic patients.^[11] Although intracranial arachnoid cysts are commonly encountered on MRI, usually incidental, it is rarely reported inside the clivus.^[4] A reported case of a 22-year-old man presented with unilateral progressive facial pain for 2 years. He also complained of transient episodes of decreased vision.^[8] The MRI showed an arachnoid cyst located in the prepontine and right cerebellopontine angle, compressing the brainstem. The clivus posterior surface showed signs of chronic compression but was not invaded by the cyst. The patient was treated medically with no need for surgical intervention.^[8] Another reported case of clival arachnoid cyst in a 40-year-old male who presented with an acute ischemic stroke showed a prepontine homogenous arachnoid cyst with no cystic component inside the clivus. They presumed that the origin was the posterior clival surface. The cyst was fenestrated and drained stereotactically through the vertex under local anesthesia. After 3 years of postoperative follow-ups, the patient remained asymptomatic.^[10] Despite our intraoperative impression that the cystic wall was communicating with the subarachnoid space, the pathology of the removed wall and the reported literature do not support the diagnosis of an arachnoid cyst in our case.

The final diagnosis of our lesion was simple clival bone cyst. Only one case of a clival simple cyst has been reported.^[16] Shkarubo *et al.* reported the case of an 8-year-old girl who

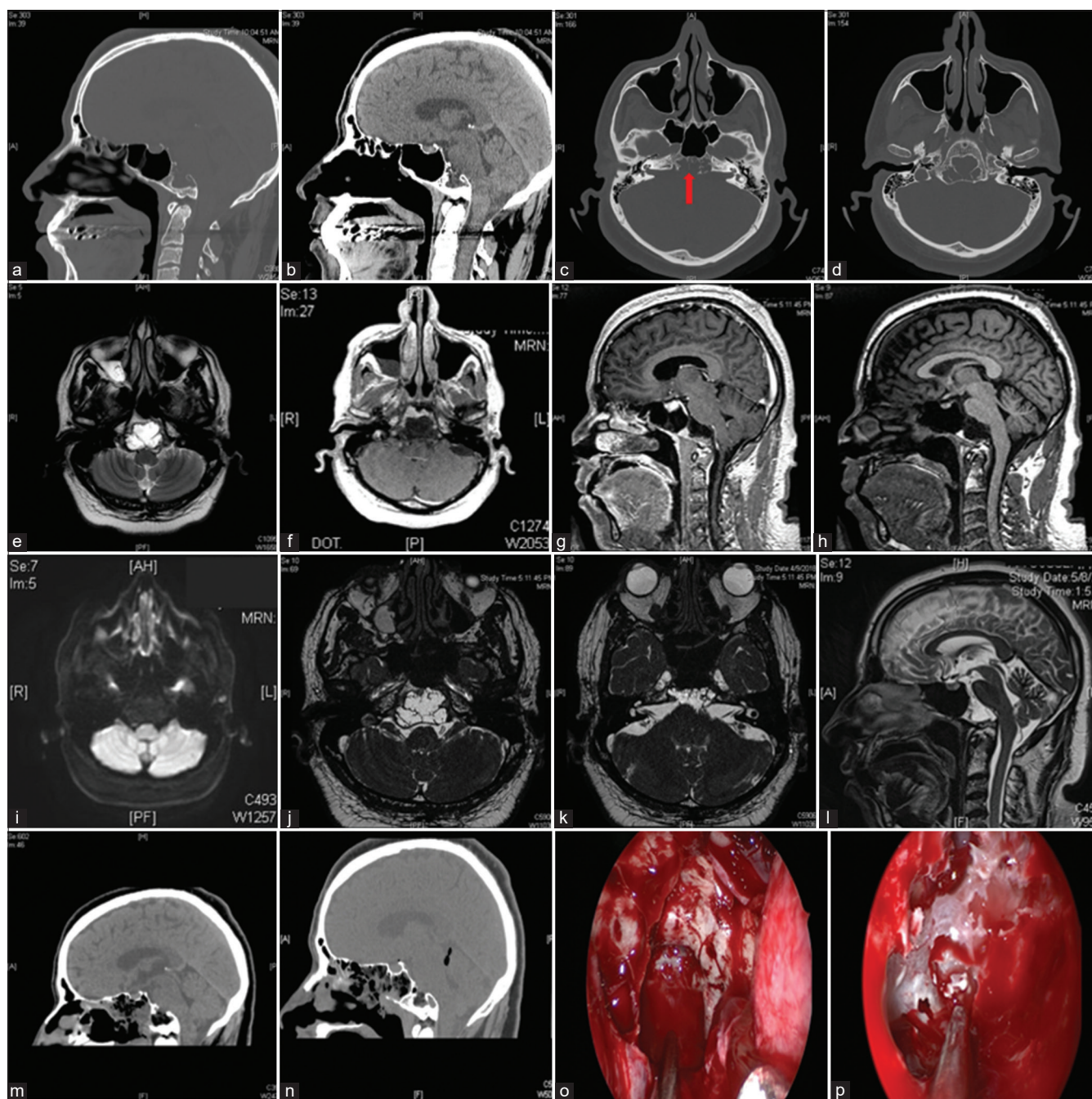


Figure 1: (a) Computed tomography (CT) scan, sagittal view, bone window showing the clival cyst (b) CT scan, sagittal view showing the clival cyst communicating with subarachnoid space (c) CT scan, bone window showing the clival cyst (arrow) (d) CT scan, bone window showing the clival cyst communicating with arachnoid space (e) magnetic resonance imaging (MRI), T2 sequence, axial cut (f) MRI, T1 sequence, axial view with contrast. (G) MRI, T1 sequence, sagittal view with contrast (h) MRI, T1 sequence, sagittal view (i) MRI, diffusion-weighted imaging sequence, axial view showing no restriction (j) MRI, T2 sequence, axial cut showing the clival cyst (k) MRI, T2 sequence, axial cut showing the cyst communicating with subarachnoid space (l) MRI, T2 sequence, sagittal cut showing the clival cyst communicating with subarachnoid space (m and n) Postoperative imaging post cyst drainage and cystic wall resection, the cystic cavity filled with fat graft (o) Intraoperative view of the endoscopic transnasal approach showing the cystic cavity in the clival cyst after anterior wall opening (p) Intraoperative view showing the cystic wall.

presented with a meningeal-like headache that was later associated with vomiting. The MRI detected a clival lesion that was hyperintense on T2-weighted MRI and hypointense

on T1-weighted MRI. Transoral trepanation of the clivus was performed, and the bone cyst was evacuated. The cyst was constantly recollecting CSF after evacuation. The pathology

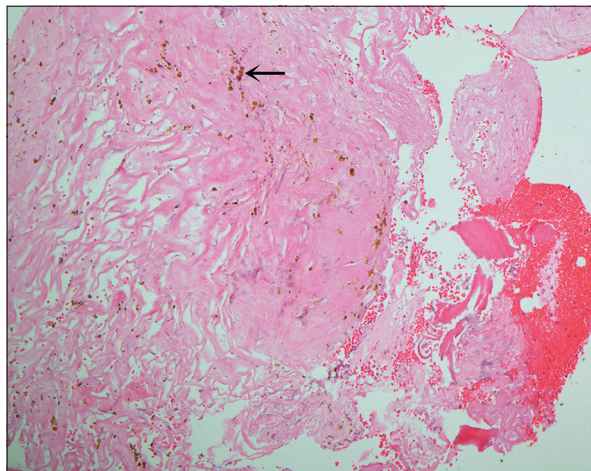


Figure 2: The cyst wall consisted of thick fibrous tissue with scattered foci of hemosiderin deposition (arrow, H and E, magnification power $\times 100$).

report revealed fragments of compact bone and a lack of spongy bone trabecula.^[16]

Although the optimal treatment for neoplastic clival lesions is surgical resection,^[7] close follow-up of symptoms could be recommended rather than surgical management for pure clival cysts.^[8]

In pure clival cysts, surgical intervention is not recommended and should be only performed in progressive symptomatic cysts or when the diagnosis is really in doubt.

CONCLUSION

We report a case of a clival cyst that underwent successful surgical resection and evacuation of the clival lesion.

Because simple bone cyst and arachnoid cyst in the clivus are rare, they should be considered in the diagnosis of clival cystic lesions.

Declaration of patient consent

Patient's consent not required as patients identity is not disclosed or compromised.

Financial support and sponsorship

Nil.

Conflicts of interest

There are no conflicts of interest.

REFERENCES

1. Bellut D, Holzmann D, de Alba Buenrostro G, Rushing EJ, Bernays RL. CSF containing cystic lesion of the clivus-case

report and review of the literature. *Clin Neurol Neurosurg* 2013;115:95-8.

2. Borges A. Skull base tumours Part II. Central skull base tumours and intrinsic tumours of the bony skull base. *Eur J Radiol* 2008;66:348-62.
3. Boude AB, Vásquez LG, Alvarado-Gomez F, Bedoya MC, Rodríguez-Múnera A, Morales-Saenz LC. A simple bone cyst in cervical vertebrae of an adolescent patient. *Case Rep Orthop* 2017;2017:8908216.
4. Bourekas EC, Raji MR, Dastur KJ, Francken GJ, Engle DJ, Nayak NT. Retroclival arachnoid cyst. *AJNR Am J Neuroradiol* 1992;13:353-4.
5. Chang JH, Chang JW, Park YG, Kim TS, Kim JA, Chung SS. Simple bone cyst occurring in calvarium. *Acta Neurochir (Wien)* 2003;145:927-8.
6. Coskun B, Akpek S, Dogulu F, Uluoglu O, Eken G. Simple bone cyst in spinous process of the c4 vertebra. *AJNR Am J Neuroradiol* 2004;25:1291-3.
7. Folbe AJ, Svider PF, Liu JK, Eloy JA. Endoscopic resection of clival malignancies. *Otolaryngol Clin North Am* 2017;50:315-29.
8. Genc E, Dogan EA, Kocaogullar Y, Emlik D. A case with prepontine (clival) arachnoid cyst manifested as trigeminal neuralgia. *Headache* 2008;48:1525-7.
9. Gunawat P, Shaikh ST, Karmarkar V, Deopujari C, Shah N. Endoscopic excision of symptomatic simple bone cyst at skull base. *J Clin Diagn Res* 2016;10:PD03-4.
10. Iacono RP, Labadie EL, Johnstone SJ, Bendt TK. Symptomatic arachnoid cyst at the clivus drained stereotactically through the vertex. *Neurosurgery* 1990;27:130-3.
11. Kim MH, Jho HD. Endoscopic management of cranial arachnoid cysts using extra-channel method. *J Korean Neurosurg Soc* 2010;47:433-6.
12. Matsumura S, Murakami S, Kakimoto N, Furukawa S, Kishino M, Ishida T, et al. Histopathologic and radiographic findings of the simple bone cyst. *Oral Surg Oral Med Oral Pathol Oral Radiol Endod* 1998;85:619-25.
13. Nager GT. Solitary (unicameral) cysts involving the temporal bone. *Laryngoscope* 1986;96:666-74.
14. Pretell-Mazzini J, Murphy RF, Kushare I, Dormans JP. Unicameral bone cysts: General characteristics and management controversies. *J Am Acad Orthop Surg* 2014;22:295-303.
15. Rubin MM, Murphy FJ. Simple bone cyst of the mandibular condyle. *J Oral Maxillofac Surg* 1989;47:1096-8.
16. Shkarubo AN, Kuleshov AA, Semenova LA, Shishkina LV, Shvets VV, Vetrile MS, et al. Surgical treatment of clival and axis bone cysts. *Zh Vopr Neirokhir Im N N Burdenko* 2016;80:88-97.
17. Snell BE, Adesina A, Wolfla CE. Unicameral bone cyst of a cervical vertebral body and lateral mass with associated pathological fracture in a child. Case report and review of the literature. *J Neurosurg* 2001;95:243-5.

How to cite this article: Fatani JA, Arab A, Alkhalidi H, Ajlan A. Clival simple bone cyst: Rare pathological entity (case report). *Surg Neurol Int* 2020;11:427.