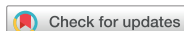

Review Article



Diagnostic Methods for Prosthetic Joint Infection in Korea

Kyung-Hwa Park ¹ and Robin Patel^{2,3}

¹Department of Infectious Diseases, Chonnam National University Medical School, Gwangju, Korea

²Division of Clinical Microbiology, Department of Laboratory Medicine and Pathology, Mayo Clinic, Rochester, MN, USA

³Division of Infectious Diseases, Department of Internal Medicine, Mayo Clinic, Rochester, MN, USA



Received: Jul 11, 2018

Corresponding Author:

Kyung-Hwa Park, PhD

Department of Infectious Diseases, Chonnam National University Medical School, 42 Jebong-ro, Dong-gu, Gwangju 61469, Korea.
Tel: +82-62-220-6296
Fax: +82-62-225-8578
E-mail: iammedkid@naver.com

Copyright © 2018 by The Korean Society of Infectious Diseases and Korean Society for Chemotherapy

This is an Open Access article distributed under the terms of the Creative Commons Attribution Non-Commercial License (<https://creativecommons.org/licenses/by-nc/4.0/>) which permits unrestricted non-commercial use, distribution, and reproduction in any medium, provided the original work is properly cited.

ORCID iDs

Kyung-Hwa Park 
<https://orcid.org/0000-0003-2836-6963>

Conflict of Interest

No conflicts of interest.

ABSTRACT

Prosthetic joint infection (PJI) poses a burden on patients and health care resources. PJI diagnosis can be challenging, owing to imperfect definition, alongside inadequate diagnostic techniques. In this review, we describe consensus definitions of PJI, approaches to diagnosis using methods available in Korea, and novel diagnostic methods.

Keywords: Prosthetic; Joint; Infection; Diagnosis; Korea

INTRODUCTION

Total joint arthroplasty is a highly successful treatment modality that improves joint function, relieves pain, and increases the overall quality of life [1]. Prosthetic joint infection (PJI) is one of the most dreaded complications of arthroplasties, reported in 2–3% of patients undergoing primary total knee and hip arthroplasties in Korea [2]. With a projected increase in the number of primary or revision arthroplasties [3, 4], more patients with PJI are anticipated in the future. PJIs are caused by organisms that grow on the surface of foreign bodies in biofilms and, in some cases, persist intracellularly in cells surrounding the implants. The majority of PJIs are initiated through inadvertent introduction of normal microbial flora at the time of surgery. Early PJI (*i.e.*, within three months after arthroplasty) mainly results from infection with virulent organisms [5], whereas delayed (*i.e.*, 3–12 months after arthroplasty) or late (>12 months after arthroplasty) PJIs tend to be associated with low-virulence bacteria, such as *Staphylococcus epidermidis* [6]. Biofilm-related infections are difficult to diagnose, as traditional microbiological tests are optimized to detect free-floating but not sessile bacteria. Diagnosis relies on a combination of clinical suspicion, clinical assessment, synovial fluid biomarker analysis, appropriately performed cell cultures, histology, and, in some cases, additional testing. Various definitions of PJI have been used between studies evaluating diagnostic tests for PJI, potentially affecting comparability of results. In an effort to standardize the definition of PJI, multiple medical societies and working groups have proposed definitions. In 2011, the Musculoskeletal Infectious Society (MSIS) proposed a set of criteria for the diagnosis of PJI that was later revised at the International Consensus Meeting (ICM) on PJI [7, 8] (Table 1). In 2013, the Infectious Disease Society of America (IDSA) published a set of criteria for the definition of PJI [9]. However, these definitions are slightly different between each other. [6]. In recent years, extensive research efforts into

Table 1. Proposed definitions of prosthetic joint infection

Infectious Disease Society of America (IDSA) 2013	Musculoskeletal Infection Society (MSIS) 2011	International Consensus Meeting (ICM) 2013
<p>PJI is present when one of the following criteria is present:</p> <ul style="list-style-type: none"> -Sinus tract communicating with prosthesis -Presence of purulence -Acute inflammation on histopathological evaluation of periprosthetic tissue -Two or more positive cultures with the same organism (intraoperatively and/or preoperatively) -Single positive culture with virulent organism 	<p>PJI is present when one major criterion is present or four out of six minor criteria exist.</p>	<p>PJI is present when one major criterion is present or four out of five minor criteria exist.</p>
	<p>Major Criteria:</p> <ul style="list-style-type: none"> -Two positive periprosthetic cultures with phenotypically identical organisms -A sinus tract communicating with the joint <p>Minor Criteria:</p> <ul style="list-style-type: none"> -elevated CRP and ESR -elevated synovial fluid leukocyte count or ++ change on leukocyte esterase test strip -elevated synovial fluid PMN % -presence of purulence in the affected joint -positive histological analysis of periprosthetic tissue -A single positive culture 	<p>Major Criteria:</p> <ul style="list-style-type: none"> -Two positive periprosthetic cultures with phenotypically identical organisms -A sinus tract communicating with the joint <p>Minor Criteria:</p> <ul style="list-style-type: none"> -elevated CRP and ESR -elevated synovial fluid leukocyte count or ++ change on leukocyte esterase test strip -elevated synovial fluid PMN % -positive histological analysis of periprosthetic tissue -A single positive culture

PJI, prosthetic joint infection; CRP, C-reactive protein; ESR, erythrocyte sedimentation rate; WBC, white blood cell; PMN %, polymorphonuclear leukocyte percentage.

biomarker identification have been performed [10, 11], and new definitions of periprosthetic hip and knee joint infection have been suggested or are in formulation [12].

Diagnosis of PJI remains a challenge to the orthopedic community, at least in some cases. According to a publication from the Korea knee research group, diagnosis of PJI is based on clinical suspicion in one-third of cases, without joint fluid and histological analysis [13]. Recently, diagnosis of PJI has been greatly improved, due to application of molecular techniques. In this article, we review PJI diagnostic strategies with methods available in Korea using the ICM PJI definition.

DIAGNOSIS

1. Clinical suspicion

Clinical presentations of PJI are diverse depending on the time of onset following prosthesis placement, mechanism of infection, virulence of the pathogen, and host immune response. Chronic PJI has an indolent course characterized by persistent joint pain, with or without early implant failure [9]. Joint pain is also the most common symptom in aseptic failure. Therefore, clinical suspicion based on a patient's constellation of clinical symptoms and risk factors for infection is important to decide upon the most appropriate diagnostic testing strategy. When patients have postoperative wound healing complications, such as prolonged wound drainage, wound dehiscence, wound hematoma, or lack of resolution of joint pain after primary surgery, the possibility of PJI increases [14]. Joint erythema, tenderness, and systemic findings, such as chills and fever, are highly specific for infection but are rarely observed except in hematogenous PJI or early infections [15]. A sinus tract that communicates with prosthesis is considered by most investigators to be specific, definitive evidence of PJI, and has been considered diagnostic in all three definitions (Table 1). Thorough history and physical examination improve the accuracy of diagnostic tests, but are dependent on the expertise of the evaluating clinician.

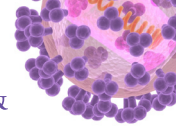
2. Biomarkers in the serum: erythrocyte sedimentation rate (ESR), C-reactive protein (CRP), procalcitonin, interleukin (IL)-6

Several preoperative tests are available to assist in the assessment of PJI. ESR and CRP are the most frequently used inflammatory markers and are determined through inexpensive, widely available, noninvasive tests with rapid turnaround time in most laboratories that have now been incorporated in the routine evaluation of PJI (Table 1). Values greater than 30 mm/h for ESR and greater than 10 mg/L for CRP have been proposed for PJI diagnosis [8]. Infections with low-virulence organisms, prior antimicrobial use, and immunosuppression may be associated with normal inflammatory markers [16]. CRP and ESR can be elevated during the post-operative period and in renal disease, malignancy, advanced age, and chronic inflammatory conditions such as rheumatoid arthritis and metallosis [17]. Serum procalcitonin levels have been useful for other infections but have been investigated in only a small number of patients for PJI diagnosis. One study involving 78 patients found that serum procalcitonin was specific (98%), but not sensitive enough (33%) [18]. Therefore, procalcitonin is not currently recommended for PJI diagnosis. IL-6 is a cytokine produced by monocytes and macrophages that has been shown to be useful in the diagnosis of PJI. In a meta-analysis, IL-6 was shown to have a higher diagnostic odds ratio (314.7) when compared with ESR and CRP [19].

3. Synovial fluid studies - cell count and differential, IL-6, α -defensin

If clinical signs and symptoms, and blood tests suggest the possibility of PJI, the next step is fluid aspiration from the joint. Synovial fluid can be obtained through preoperative or intraoperative aspiration. Synovial fluid aspiration of a knee arthroplasty is easily performed in the office, but aspiration of a hip arthroplasty may require fluoroscopic guidance. The amount of synovial fluid obtained during aspiration does not correlate with the presence or absence of infection. Synovial fluid should be submitted for determination of nucleated cell counts and percentages of neutrophils and for bacterial aerobic and anaerobic cultures. Specific cutoffs for synovial fluid leukocyte counts have been recommended for diagnosis of PJI, which are lower than those reported for native septic arthritis. The cutoff value for a positive test varies across joint-types and time of onset of PJI, and is also affected by the presence of underlying inflammatory arthritis. Leukocyte counts $>1,100/\text{mm}^3$ provided a sensitivity and specificity of 90.7% and 88.1%, respectively, in one study of 429 patients with knee arthroplasties (including 161 PJIs) [20]. A smaller study by Trampuz et al. of 133 patients (34 with PJI) with knee arthroplasties found that a leukocyte count $>1,700$ cells/ mm^3 showed sensitivity and specificity of 94 and 88%, respectively [21]. The optimal cutoff values for synovial fluid leukocyte counts and neutrophil percentages appear to be higher in hip than in knee arthroplasties. A study of 201 hip arthroplasties (including 55 PJIs) found that a leukocyte count $>4,200$ cells/ mm^3 provided a sensitivity and specificity of 84% and 93%, respectively [22]. A more recent study of 810 patients with knee or hip arthroplasties (including 146 PJIs) found that a count of $>3,450$ leukocytes/ mm^3 was 91% sensitive and 93% specific, and that a neutrophil percentage $>78\%$ was 95% sensitive and 87% specific [23]. According to the MSIS PJI definition, a synovial fluid leukocyte counts of $>3,000/\text{mm}^3$ and a neutrophil percentage of $>80\%$ indicate hip or knee arthroplasty infection. Notably, IDSA diagnostic criteria do not include specific values for synovial fluid leukocyte counts or leukocyte differential. Because synovial cell counts may be elevated in periprosthetic fractures, inflammatory arthritis, and allergies to metals, interpretation must be careful. By combining results of synovial fluid cell count and differential, with those of culture, ESR, and CRP, the sensitivity of PJI detection can be improved up to 99.7% [16].

Some biomarkers can be elevated in various inflammatory conditions. In theory, synovial fluid biomarkers, which are obtained directly from the affected joint, may be more accurate



for PJI diagnosis than serum biomarkers. A relatively recent development includes synovial fluid analysis for identification of novel biomarkers, such as α -defensin and IL-6 [11]. One study that evaluated the sensitivity, specificity, and accuracy of 24 synovial fluid biomarkers in patients with PJI versus aseptic failure reported that synovial fluid IL-6 had excellent diagnostic performance, with an accuracy over 0.9 for the diagnosis of hip and knee PJI [7]. This finding corresponds well with the results of a recent study reporting that synovial fluid IL-6 had an accuracy of 0.89, with very high sensitivity, thus leading to strong diagnostic strength [24]. Synovial fluid IL-6 as a predictor of shoulder PJI had 87% sensitivity and 90% specificity with an area under the curve of 0.891 and an ideal cutoff value of 359.3 pg/mL [25]. Defensins are endogenous peptides of the host-defense innate immune system that are released mainly from polymorphonuclear cells in response to pathogens. Several studies have considered the role of α -defensin in the evaluation of painful hip and knee replacements with a sensitivity and specificity approaching 100% [26, 27]. These results have not been replicated for shoulder replacements, with sensitivity dropping to 63% [28]. A recent study showed that α -defensin can be falsely positive in conjunction with an underlying non-infectious inflammatory disease, mainly in cases with crystal deposition [29]. The detection of synovial fluid α -defensin with enzyme-linked immunosorbent assay (ELISA) is commercially available under the name Synovasure™ (Zimmer, Warsaw, IN, USA) PJI test, but not yet available in Korea. At least 1.0 mL of synovial fluid is required for analysis and the stability of α -defensin in synovial fluid is 48 h at room temperature [26]. The test has been validated for the detection of PJI with a cutoff value of 5.2 μ g/mL, providing a signal-to-cutoff ratio of 1.0.

4. Intraoperative periprosthetic purulence and histology

IDSA and MSIS guidelines consider intraoperative purulence as a diagnostic criterion for PJI. However, with concerns regarding the subjective interpretation of purulence and the possibility that noninfectious causes of arthroplasty failure, such as reactions to metal debris and crystal-induced arthritis, can induce a purulent-like fluid response, the ICM omitted purulence from their diagnostic criteria.

Histopathology is highly specific in predicting culture-positive PJI and therefore confirming the presence of infection [30]. Histopathological evaluation of PJI involves tissue sampling from the areas adjacent to the prosthesis that appear to be infected upon intraoperative inspection. Different thresholds for acute inflammation have been proposed, but the presence of at least 5 neutrophils per high power field ($\times 400$ magnification) in at least 5 microscopic fields is one of the most common definitions used. Intraoperative frozen section evaluations can provide useful information to surgeons at the time of revision surgery, with the caveat that, as with assessment of purulence, non-infectious conditions, such as inflammatory arthritis or periprosthetic fracture, may provide false-positive results [31]. In addition, histology may be false-negative when infection is due to a low-virulence microorganism, such as a coagulase negative *Staphylococcus* species or *Cutibacterium acnes* [32].

5. Culture of synovial fluid, periprosthetic tissue and sonicate fluid

Aspirated synovial fluid can be inoculated into blood culture bottles at the time of collection or first transported to the microbiology laboratory and inoculated into blood culture bottles; alternatively, synovial fluid may be inoculated into solid and/or into liquid media. Recent studies recommended that synovial fluid should be inoculated into paired aerobic and anaerobic blood culture bottles for ideal diagnosis of PJI [33, 34].

Multiple periprosthetic tissue samples should be collected and submitted for aerobic and anaerobic culture at the time of operation. Single-tissue specimens for culture should be avoided because of low sensitivity and difficulty in interpreting potential contamination with low-virulence microorganisms [35]. The number of cultures required for optimal detection of pathogens has recently been re-defined. The IDSA guidelines recommended that at least three and optimally five or six periprosthetic intraoperatively-collected tissue samples should be submitted for aerobic and anaerobic cultures [9]. A single positive culture may be important, especially when a virulent organism such as *S. aureus*, a beta-hemolytic *Streptococcus* species, or an aerobic gram negative bacillus is isolated, or when the same organism is found in the synovial fluid and the sonicate fluid. The specific media and incubation time for periprosthetic tissue culture have been examined to a limited extent [36]. Previous microbiological techniques for periprosthetic tissue culture have used aerobic and anaerobic blood agar plates, alongside broths, such as thioglycolate broth. One recent large study involving 178 patients compared the sensitivities and specificities of four different culture media to a gold standard for the detection of acute inflammation in periprosthetic tissue. Cultures using cooked meat broth (83%) or blood culture bottles (87%) were more sensitive than cultures using fastidious anaerobic broth (57%) or solid-agar plates (39%) [37]. Newly published studies have shown that culture of periprosthetic tissue specimens in blood culture bottles improved diagnosis; additionally, it required fewer specimens (three specimens) than cultures using conventional plates and broths, for accurate PJI diagnosis; culture in blood culture bottles is also labor- and cost-saving [38-41]. In the majority of studies, the incubation period was in the order of 5 days for aerobic cultures and 14 days for anaerobic cultures. Schafer and Butler-Wu recommended an incubation period of 14 days based on late recovery of *Cutibacterium/Propionibacterium* species [42, 43].

Sonication fluid culture has emerged as a practical and effective method to dislodge biofilms and the associated bacteria from the surface of implants [44]. Sonicate culture should be accompanied by the use of solid rather than liquid media, to enable semi-quantitative analysis, which is not possible when a broth medium is used. A recommended protocol for sonication of explanted joint prostheses is shown in **Figure 1**. Plating onto aerobic and anaerobic sheep blood agar plates, the microorganisms are enumerated and identified by routine microbiological techniques. According to Mayo Clinic guidelines, sonication fluid cultures are positive when at least 20 colony-forming units are grown per plate (0.1 mL inoculum equals 10 mL of original sonicated sample) [45, 46]. Sonication has been studied on hip, knee, shoulder, and elbow prostheses, with a range of observed diagnostic accuracies reported (**Table 2**) [45, 47-50]. A recent meta-analysis of clinical trials showed that sonication fluid culture is of greater value for PJI diagnosis than traditional tissue culture [51, 52]. A recent study demonstrated that periprosthetic tissue culture sensitivity in blood culture bottles was similar to that of sonication fluid culture; however, the two tests combined had the highest sensitivity without compromising specificity [39].

Absence of bacterial growth has been reported in up to 14% of patients with clinical evidence of PJI [6]. In general, PJI caused by mycobacteria and fungi is rare, and routine use of mycobacterial and fungal cultures is not cost-effective in Western countries [53]. In a literature review, Million and colleagues reported that, out of 301 cases of culture-negative PJI, 46% were due to fungi, 43% due to mycobacteria, and 11% due to bacteria [54]. In Korea, the prevalence of *Mycobacterium tuberculosis* infection is not low [55] and routine mycobacterial culture may be useful. If fungal or mycobacterial infection is suspected, proper specimen transport and isolation media should be used. Adequate numbers of samples,




Figure 1. Prosthesis sonication protocol used in the Mayo Clinic Clinical Microbiology Laboratory (Courtesy of David Lynch, reproduced with permission).

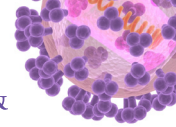
The implant is collected in a sterile container and 400 mL Ringer's solution is added followed by rigorous mixing (vortex). Vortex of the sample for 30 s before sonication increases the yield of positive cultures. Following vortex, the container was sonicated (40 kHz) in an ultrasound bath for 5 min. After sonication, sonicate fluid is vortexed for 30 s again, followed by centrifugation; for example, 50 mL aliquots are centrifuged at 3,150 g for 5 min, and the whole supernatant, but the bottom 0.5 mL, is discarded. As shown in **Figure 1**, after the concentration step, the supernatant is aspirated and 0.1 mL of the precipitate is plated onto aerobic and anaerobic sheep blood agar plates, which are incubated at 37°C in 5% CO₂ aerobically and anaerobically for 5 and 14 days, respectively.

strict withholding of antimicrobials prior to surgery and improvements in microbiological techniques may decrease the number of culture-negative infections. Antimicrobial agents should be held until cultures are collected, if the patient is not systemically ill.

Table 2. Comparative studies of sonication culture with tissue culture and yield of positive cultures in patients with orthopedic implant-associated infection

Reference (publication year)	Country	No. of patients	Vortexing	Centrifugation	Sonication (prosthesis) culture		Tissue culture		Comments (number)	Diagnostic criteria applied
					Sensitivity	Specificity	Sensitivity	Specificity		
Puig-Verdie et al. [49] (2013)	Spain	317	NA	NA	89.9% (98/109)	99% (206/208)	67% (73/109)	99.5% (207/208)	Various implants: knee (98) or hip prosthesis (54), tibial inserts (13), acetabular components (22), fixation device (101), spinal device (20)	IOF, H, M
Vergidis et al. [47] (2011)	USA	36	Yes	Yes	89% (8/9)	100% (27/27)	55% (5/9)	93% (25/27)	Elbow prosthesis (36)	IOF, H, M
Piper et al. [45] (2009)	USA	134	Yes	Yes	67% (22/33)	98% (99/101)	55% (18/33)	95% (96/101)	Shoulder prosthesis (134)	IOF, H
Esteban et al. [50] (2008)	Spain	31	No	Yes	94% (16/17)	50% (7/14)	88% (15/17)	100% (8/8)	hip prosthesis (15), knee prosthesis (3), intramedullary nails (4), other devices (9)	IOF, H, M
Trampuz et al. [48] (2007)	USA	331	Yes	Yes	78% (62/79)	99% (249/252)	61% (48/79)	99% (250/252)	knee prosthesis (207), hip prosthesis (124)	IOF, H

NA, not-available; IOF, Intraoperative finding; H, histological examination; M, microbiological or laboratory examination.



6. Future diagnostics: Molecular methods

Culture-negative PJIs are challenging in terms of management, so new laboratory methods that improve the microbiological diagnosis of PJI are required. The use of polymerase chain reaction (PCR) technology has the theoretical advantage of a rapid turnaround time and ability to detect culture-negative cases. In the context of PJI diagnosis, two main categories of PCR assays exist, specific PCR and broad-range PCR assays [56, 57]. Specific PCR assays target single bacterial species (*e.g.*, *S. aureus*) or a group of closely related species (*e.g.*, *Staphylococcus* species) or multiple specific genes combined with detection of common resistance genes such as *mecA* for MRSA, or *vanA*, *vanB*, or *bla_{KPC}*. Specific PCR assays have been used with commercial or laboratory-designed PCR primers [46, 58-60]; recently, these are typically real-time PCR assays. A rapid panel PCR showed better performance in an evaluation using sonication fluid [46] but not using periprosthetic tissue or synovial fluid [58, 61]. However, panel PCR may show limited sensitivity with relation to multiplex PCR design, which can only detect pathogens included in the primer setup [62]. Broad-range bacterial 16S rRNA PCR targets regions of the bacterial rRNA gene conserved across species [63]. The specific identity of the source bacteria in broad-range assays is determined by analyzing the sequence of the amplified DNA. Mixed sequence data, resulting from mixed infection, may be resolved by several strategies, including cloning of the PCR amplicon and sequencing of a limited number of clones or with next generation sequencing. The main limitations of broad-range bacterial PCR relate to inherent sensitivity issues. The use of next-generation sequencing techniques allows for the generation of thousands of individual sequences from a single broad-range PCR reaction and this approach may provide detailed information on the bacterial population present in prosthetic joint samples [64, 65].

CONCLUSIONS

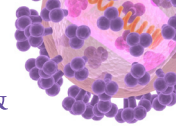
Joint arthroplasties are life-enhancing and the number of arthroplasties is increasing. Accordingly, more infectious complications are expected, but, clinical data or research regarding PJI is lacking in Korea. Major contributions in the advancements of PJI diagnosis have been made in the recent years. All current diagnostic tests have inherent limitations that require the combination of different testing modalities for ideal clinical care. Laboratorians, orthopedic surgeons, and infectious disease specialists should cooperate to accomplish accurate diagnosis of PJI. Improved diagnostics for PJI is anticipated over the following years. While waiting for the advent of new technologies, clinicians should make an effort to follow strategies that can be used to enhance the yield of culture techniques.

REFERENCES

1. Jones CA, Voaklander DC, Johnston DW, Suarez-Almazor ME. Health related quality of life outcomes after total hip and knee arthroplasties in a community based population. *J Rheumatol* 2000;27:1745-52.
[PUBMED](#)
2. Choi HJ, Adiyani L, Sung J, Choi JY, Kim HB, Kim YK, Kwak YG, Yoo H, Lee SO, Han SH, Kim SR, Kim TH, Lee HM, Chun HK, Kim JS, Yoo JD, Koo HS, Cho EH, Lee KW; Korean Nosocomial Infections Surveillance System (KONIS). Five-year decreased incidence of surgical site infections following gastrectomy and prosthetic joint replacement surgery through active surveillance by the Korean Nosocomial Infection Surveillance System. *J Hosp Infect* 2016;93:339-46.
[PUBMED](#) | [CROSSREF](#)
3. Yoon PW, Lee YK, Ahn J, Jang EJ, Kim Y, Kwak HS, Yoon KS, Kim HJ, Yoo JJ. Epidemiology of hip replacements in Korea from 2007 to 2011. *J Korean Med Sci* 2014;29:852-8.
[PUBMED](#) | [CROSSREF](#)

4. Koh IJ, Kim TK, Chang CB, Cho HJ, In Y. Trends in use of total knee arthroplasty in Korea from 2001 to 2010. *Clin Orthop Relat Res* 2013;471:1441-50.
[PUBMED](#) | [CROSSREF](#)
5. Parvizi J, Fassihi SC, Enayatollahi MA. Diagnosis of periprosthetic joint infection following hip and knee arthroplasty. *Orthop Clin North Am* 2016;47:505-15.
[PUBMED](#) | [CROSSREF](#)
6. Tande AJ, Patel R. Prosthetic joint infection. *Clin Microbiol Rev* 2014;27:302-45.
[PUBMED](#) | [CROSSREF](#)
7. Parvizi J, Gehrke T; International Consensus Group on Periprosthetic Joint Infection. Definition of periprosthetic joint infection. *J Arthroplasty* 2014;29:1331.
[PUBMED](#) | [CROSSREF](#)
8. Parvizi J, Zmistowski B, Berbari EF, Bauer TW, Springer BD, Della Valle CJ, Garvin KL, Mont MA, Wongworawat MD, Zalavras CG. New definition for periprosthetic joint infection: from the Workgroup of the Musculoskeletal Infection Society. *Clin Orthop Relat Res* 2011;469:2992-4.
[PUBMED](#) | [CROSSREF](#)
9. Osmon DR, Berbari EF, Berendt AR, Lew D, Zimmerli W, Steckelberg JM, Rao N, Hanssen A, Wilson WR; Infectious Diseases Society of America. Diagnosis and management of prosthetic joint infection: clinical practice guidelines by the Infectious Diseases Society of America. *Clin Infect Dis* 2013;56:e1-e25.
[PUBMED](#) | [CROSSREF](#)
10. Frangiamore SJ, Gajewski ND, Saleh A, Farias-Kovac M, Barsoum WK, Higuera CA. α -defensin accuracy to diagnose periprosthetic joint infection-best available test? *J Arthroplasty* 2016;31:456-60.
[PUBMED](#) | [CROSSREF](#)
11. Deirmengian C, Kardos K, Kilmartin P, Cameron A, Schiller K, Parvizi J. Diagnosing periprosthetic joint infection: has the era of the biomarker arrived? *Clin Orthop Relat Res* 2014;472:3254-62.
[PUBMED](#) | [CROSSREF](#)
12. Parvizi J, Tan TL, Goswami K, Higuera C, Della Valle C, Chen AF, Shohat N. The 2018 definition of periprosthetic hip and knee infection: an evidence-based and validated criteria. *J Arthroplasty* 2018;33:1309-1314.e2.
[PUBMED](#) | [CROSSREF](#)
13. Koh IJ, Cho WS, Choi NY, Parvizi J, Kim TK; Korea Knee Research Group. How accurate are orthopedic surgeons in diagnosing periprosthetic joint infection after total knee arthroplasty?: a multicenter study. *Knee* 2015;22:180-5.
[PUBMED](#) | [CROSSREF](#)
14. Barrack RL, Harris WH. The value of aspiration of the hip joint before revision total hip arthroplasty. *J Bone Joint Surg Am* 1993;75:66-76.
[PUBMED](#) | [CROSSREF](#)
15. Gomez-Urena EO, Tande AJ, Osmon DR, Berbari EF. Diagnosis of prosthetic joint infection: cultures, biomarker and criteria. *Infect Dis Clin North Am* 2017;31:219-35.
[PUBMED](#) | [CROSSREF](#)
16. McArthur BA, Abdel MP, Taunton MJ, Osmon DR, Hanssen AD. Seronegative infections in hip and knee arthroplasty: periprosthetic infections with normal erythrocyte sedimentation rate and C-reactive protein level. *Bone Joint J* 2015;97-B:939-44.
[PUBMED](#) | [CROSSREF](#)
17. Levine SE, Esterhai JL Jr, Heppenstall RB, Calhoun J, Mader JT. Diagnoses and staging. Osteomyelitis and prosthetic joint infections. *Clin Orthop Relat Res* 1993;(295):77-86.
[PUBMED](#)
18. Bottner F, Wegner A, Winkelmann W, Becker K, Erren M, Götze C. Interleukin-6, procalcitonin and TNF-alpha: markers of peri-prosthetic infection following total joint replacement. *J Bone Joint Surg Br* 2007;89:94-9.
[PUBMED](#) | [CROSSREF](#)
19. Berbari E, Mabry T, Tsaras G, Spangehl M, Erwin PJ, Murad MH, Steckelberg J, Osmon D. Inflammatory blood laboratory levels as markers of prosthetic joint infection: a systematic review and meta-analysis. *J Bone Joint Surg Am* 2010;92:2102-9.
[PUBMED](#) | [CROSSREF](#)
20. Ghanem E, Parvizi J, Burnett RS, Sharkey PF, Keshavarzi N, Aggarwal A, Barrack RL. Cell count and differential of aspirated fluid in the diagnosis of infection at the site of total knee arthroplasty. *J Bone Joint Surg Am* 2008;90:1637-43.
[PUBMED](#) | [CROSSREF](#)

21. Trampuz A, Hanssen AD, Osmon DR, Mandrekar J, Steckelberg JM, Patel R. Synovial fluid leukocyte count and differential for the diagnosis of prosthetic knee infection. *Am J Med* 2004;117:556-62.
[PUBMED](#) | [CROSSREF](#)
22. Schinsky MF, Della Valle CJ, Sporer SM, Paprosky WG. Perioperative testing for joint infection in patients undergoing revision total hip arthroplasty. *J Bone Joint Surg Am* 2008;90:1869-75.
[PUBMED](#) | [CROSSREF](#)
23. Cipriano CA, Brown NM, Michael AM, Moric M, Sporer SM, Della Valle CJ. Serum and synovial fluid analysis for diagnosing chronic periprosthetic infection in patients with inflammatory arthritis. *J Bone Joint Surg Am* 2012;94:594-600.
[PUBMED](#) | [CROSSREF](#)
24. Lee YS, Koo KH, Kim HJ, Tian S, Kim TY, Maltenfort MG, Chen AF. Synovial fluid biomarkers for the diagnosis of periprosthetic joint infection: a systematic review and meta-analysis. *J Bone Joint Surg Am* 2017;99:2077-84.
[PUBMED](#) | [CROSSREF](#)
25. Frangiamore SJ, Saleh A, Kovac MF, Grosso MJ, Zhang X, Bauer TW, Daly TM, Ricchetti ET, Iannotti JP. Synovial fluid interleukin-6 as a predictor of periprosthetic shoulder infection. *J Bone Joint Surg Am* 2015;97:63-70.
[PUBMED](#) | [CROSSREF](#)
26. Deirmengian C, Kardos K, Kilmartin P, Cameron A, Schiller K, Parvizi J. Combined measurement of synovial fluid α -Defensin and C-reactive protein levels: highly accurate for diagnosing periprosthetic joint infection. *J Bone Joint Surg Am* 2014;96:1439-45.
[PUBMED](#) | [CROSSREF](#)
27. Bingham J, Clarke H, Spangehl M, Schwartz A, Beauchamp C, Goldberg B. The alpha defensin-1 biomarker assay can be used to evaluate the potentially infected total joint arthroplasty. *Clin Orthop Relat Res* 2014;472:4006-9.
[PUBMED](#) | [CROSSREF](#)
28. Frangiamore SJ, Saleh A, Grosso MJ, Kovac MF, Higuera CA, Iannotti JP, Ricchetti ET. α -Defensin as a predictor of periprosthetic shoulder infection. *J Shoulder Elbow Surg* 2015;24:1021-7.
[PUBMED](#) | [CROSSREF](#)
29. Plate A, Stadler L, Sutter R, Anagnostopoulos A, Frustaci D, Zbinden R, Fucentese SF, Zinkernagel AS, Zingg PO, Achermann Y. Inflammatory disorders mimicking periprosthetic joint infections may result in false positive α -defensin. *Clin Microbiol Infect* 2018.pii:S1198-743X(18)30194-0.
[PUBMED](#)
30. Tsaras G, Maduka-Ezeh A, Inwards CY, Mabry T, Erwin PJ, Murad MH, Montori VM, West CP, Osmon DR, Berbari EF. Utility of intraoperative frozen section histopathology in the diagnosis of periprosthetic joint infection: a systematic review and meta-analysis. *J Bone Joint Surg Am* 2012;94:1700-11.
[PUBMED](#) | [CROSSREF](#)
31. Shah RP, Plummer DR, Moric M, Sporer SM, Levine BR, Della Valle CJ. Diagnosing infection in the setting of periprosthetic fractures. *J Arthroplasty* 2016;31 9 Suppl:140-3.
[PUBMED](#) | [CROSSREF](#)
32. Bori G, Soriano A, García S, Gallart X, Mallofre C, Mensa J. Neutrophils in frozen section and type of microorganism isolated at the time of resection arthroplasty for the treatment of infection. *Arch Orthop Trauma Surg* 2009;129:591-5.
[PUBMED](#) | [CROSSREF](#)
33. Hughes JG, Vetter EA, Patel R, Schleck CD, Harmsen S, Turgeant LT, Cockerill FR 3rd. Culture with BACTEC Peds Plus/F bottle compared with conventional methods for detection of bacteria in synovial fluid. *J Clin Microbiol* 2001;39:4468-71.
[PUBMED](#) | [CROSSREF](#)
34. Font-Vizcarra L, García S, Martínez-Pastor JC, Sierra JM, Soriano A. Blood culture flasks for culturing synovial fluid in prosthetic joint infections. *Clin Orthop Relat Res* 2010;468:2238-43.
[PUBMED](#) | [CROSSREF](#)
35. Gandhi R, Silverman E, Courtney PM, Lee GC. How many cultures are necessary to identify pathogens in the management of total hip and knee arthroplasty infections? *J Arthroplasty* 2017;32:2825-8.
[PUBMED](#) | [CROSSREF](#)
36. Larsen LH, Lange J, Xu Y, Schönheyder HC. Optimizing culture methods for diagnosis of prosthetic joint infections: a summary of modifications and improvements reported since 1995. *J Med Microbiol* 2012;61:309-16.
[PUBMED](#) | [CROSSREF](#)
37. Hughes HC, Newnham R, Athanasou N, Atkins BL, Bejon P, Bowler IC. Microbiological diagnosis of prosthetic joint infections: a prospective evaluation of four bacterial culture media in the routine laboratory. *Clin Microbiol Infect* 2011;17:1528-30.
[PUBMED](#) | [CROSSREF](#)



38. Peel TN, Dylla BL, Hughes JG, Lynch DT, Greenwood-Quaintance KE, Cheng AC, Mandrekar JN, Patel R. Improved diagnosis of prosthetic joint infection by culturing periprosthetic tissue specimens in blood culture bottles. *MBio* 2016;7:e01776-15.
[PUBMED](#) | [CROSSREF](#)
39. Yan Q, Karau MJ, Greenwood-Quaintance KE, Mandrekar JN, Osmon DR, Abdel MP, Patel R. Comparison of diagnostic accuracy of periprosthetic tissue culture in blood culture bottles to that of prosthesis sonication fluid culture for diagnosis of prosthetic joint infection (PJI) by use of bayesian latent class modeling and IDSA PJI criteria for classification. *J Clin Microbiol* 2018;56:pii:e00319-18.
[PUBMED](#) | [CROSSREF](#)
40. Peel TN, Sedarski JA, Dylla BL, Shannon SK, Amirahmadi F, Hughes JG, Cheng AC, Patel R. Laboratory workflow analysis of culture of periprosthetic tissues in blood culture bottles. *J Clin Microbiol* 2017;55:2817-26.
[PUBMED](#) | [CROSSREF](#)
41. Peel TN, Spelman T, Dylla BL, Hughes JG, Greenwood-Quaintance KE, Cheng AC, Mandrekar JN, Patel R. Optimal periprosthetic tissue specimen number for diagnosis of prosthetic joint infection. *J Clin Microbiol* 2016;55:234-43.
[PUBMED](#) | [CROSSREF](#)
42. Schäfer P, Fink B, Sandow D, Margull A, Berger I, Frommelt L. Prolonged bacterial culture to identify late periprosthetic joint infection: a promising strategy. *Clin Infect Dis* 2008;47:1403-9.
[PUBMED](#) | [CROSSREF](#)
43. Butler-Wu SM, Burns EM, Pottinger PS, Magaret AS, Rakeman JL, Matsen FA 3rd, Cookson BT. Optimization of periprosthetic culture for diagnosis of *Propionibacterium acnes* prosthetic joint infection. *J Clin Microbiol* 2011;49:2490-5.
[PUBMED](#) | [CROSSREF](#)
44. Trampuz A, Piper KE, Hanssen AD, Osmon DR, Cockerill FR, Steckelberg JM, Patel R. Sonication of explanted prosthetic components in bags for diagnosis of prosthetic joint infection is associated with risk of contamination. *J Clin Microbiol* 2006;44:628-31.
[PUBMED](#) | [CROSSREF](#)
45. Piper KE, Jacobson MJ, Cofield RH, Sperling JW, Sanchez-Sotelo J, Osmon DR, McDowell A, Patrick S, Steckelberg JM, Mandrekar JN, Fernandez Sampedro M, Patel R. Microbiologic diagnosis of prosthetic shoulder infection by use of implant sonication. *J Clin Microbiol* 2009;47:1878-84.
[PUBMED](#) | [CROSSREF](#)
46. Cazanave C, Greenwood-Quaintance KE, Hanssen AD, Karau MJ, Schmidt SM, Gomez Urena EO, Mandrekar JN, Osmon DR, Lough LE, Pritt BS, Steckelberg JM, Patel R. Rapid molecular microbiologic diagnosis of prosthetic joint infection. *J Clin Microbiol* 2013;51:2280-7.
[PUBMED](#) | [CROSSREF](#)
47. Vergidis P, Greenwood-Quaintance KE, Sanchez-Sotelo J, Morrey BF, Steinmann SP, Karau MJ, Osmon DR, Mandrekar JN, Steckelberg JM, Patel R. Implant sonication for the diagnosis of prosthetic elbow infection. *J Shoulder Elbow Surg* 2011;20:1275-81.
[PUBMED](#) | [CROSSREF](#)
48. Trampuz A, Piper KE, Jacobson MJ, Hanssen AD, Unni KK, Osmon DR, Mandrekar JN, Cockerill FR, Steckelberg JM, Greenleaf JF, Patel R. Sonication of removed hip and knee prostheses for diagnosis of infection. *N Engl J Med* 2007;357:654-63.
[PUBMED](#) | [CROSSREF](#)
49. Puig-Verdié L, Alentorn-Geli E, González-Cuevas A, Sorlí L, Salvadó M, Alier A, Pelfort X, Portillo ME, Horcajada JP. Implant sonication increases the diagnostic accuracy of infection in patients with delayed, but not early, orthopaedic implant failure. *Bone Joint J* 2013;95-B:244-9.
[PUBMED](#) | [CROSSREF](#)
50. Esteban J, Gomez-Barrena E, Cordero J, Martín-de-Hijas NZ, Kinnari TJ, Fernandez-Roblas R. Evaluation of quantitative analysis of cultures from sonicated retrieved orthopedic implants in diagnosis of orthopedic infection. *J Clin Microbiol* 2008;46:488-92.
[PUBMED](#) | [CROSSREF](#)
51. Liu H, Zhang Y, Li L, Zou HC. The application of sonication in diagnosis of periprosthetic joint infection. *Eur J Clin Microbiol Infect Dis* 2017;36:1-9.
[PUBMED](#) | [CROSSREF](#)
52. Zhai Z, Li H, Qin A, Liu G, Liu X, Wu C, Li H, Zhu Z, Qu X, Dai K. Meta-analysis of sonication fluid samples from prosthetic components for diagnosis of infection after total joint arthroplasty. *J Clin Microbiol* 2014;52:1730-6.
[PUBMED](#) | [CROSSREF](#)

53. Wadey VM, Huddleston JI, Goodman SB, Schurman DJ, Maloney WJ, Baron EJ. Use and cost-effectiveness of intraoperative acid-fast bacilli and fungal cultures in assessing infection of joint arthroplasties. *J Arthroplasty* 2010;25:1231-4.
[PUBMED](#) | [CROSSREF](#)
54. Million M, Bellevegue L, Labussiere AS, Dekel M, Ferry T, Deroche P, Socolovschi C, Cammilleri S, Raoult D. Culture-negative prosthetic joint arthritis related to *Coxiella burnetii*. *Am J Med* 2014;127:786.e7-e10.
[PUBMED](#) | [CROSSREF](#)
55. Kim HJ. Current status of tuberculosis in Korea. *Korean J Med* 2011;82:257-62.
[CROSSREF](#)
56. Hartley JC, Harris KA. Molecular techniques for diagnosing prosthetic joint infections. *J Antimicrob Chemother* 2014;69 Suppl 1:i21-4.
[PUBMED](#) | [CROSSREF](#)
57. Jun Y, Jianghua L. Diagnosis of periprosthetic joint infection using polymerase chain reaction: an updated systematic review and meta-analysis. *Surg Infect (Larchmt)* 2018;19:555-65.
[PUBMED](#) | [CROSSREF](#)
58. Melendez DP, Greenwood-Quaintance KE, Berbari EF, Osmon DR, Mandrekar JN, Hanssen AD, Patel R. Evaluation of a genus- and group-specific rapid PCR assay panel on synovial fluid for diagnosis of prosthetic knee infection. *J Clin Microbiol* 2016;54:120-6.
[PUBMED](#) | [CROSSREF](#)
59. Suda AJ, Tinelli M, Beisemann ND, Weil Y, Khoury A, Bischel OE. Diagnosis of periprosthetic joint infection using alpha-defensin test or multiplex-PCR: ideal diagnostic test still not found. *Int Orthop* 2017;41:1307-13.
[PUBMED](#) | [CROSSREF](#)
60. Lourter-Hascoëtt J, Bicart-See A, Félicé MP, Giordano G, Bonnet E. Is Xpert MRSA/SA SSTI real-time PCR a reliable tool for fast detection of methicillin-resistant coagulase-negative staphylococci in periprosthetic joint infections? *Diagn Microbiol Infect Dis* 2015;83:59-62.
[PUBMED](#) | [CROSSREF](#)
61. Ryu SY, Greenwood-Quaintance KE, Hanssen AD, Mandrekar JN, Patel R. Low sensitivity of periprosthetic tissue PCR for prosthetic knee infection diagnosis. *Diagn Microbiol Infect Dis* 2014;79:448-53.
[PUBMED](#) | [CROSSREF](#)
62. Renz N, Feihl S, Cabric S, Trampuz A. Performance of automated multiplex PCR using sonication fluid for diagnosis of periprosthetic joint infection: a prospective cohort. *Infection* 2017;45:877-84.
[PUBMED](#) | [CROSSREF](#)
63. Gomez E, Cazanave C, Cunningham SA, Greenwood-Quaintance KE, Steckelberg JM, Uhl JR, Hanssen AD, Karau MJ, Schmidt SM, Osmon DR, Berbari EF, Mandrekar J, Patel R. Prosthetic joint infection diagnosis using broad-range PCR of biofilms dislodged from knee and hip arthroplasty surfaces using sonication. *J Clin Microbiol* 2012;50:3501-8.
[PUBMED](#) | [CROSSREF](#)
64. Thoendel M, Jeraldo P, Greenwood-Quaintance KE, Yao J, Chia N, Hanssen AD, Abdel MP, Patel R. Identification of prosthetic joint infection pathogens using a shotgun metagenomics approach. *Clin Infect Dis* 2018 [Epub ahead of print].
[PUBMED](#) | [CROSSREF](#)
65. Tarabichi M, Shohat N, Goswami K, Alvand A, Silibovsky R, Belden K, Parvizi J. Diagnosis of periprosthetic joint infection: the potential of next-generation sequencing. *J Bone Joint Surg Am* 2018;100:147-54.
[PUBMED](#) | [CROSSREF](#)