

Contents lists available at [ScienceDirect](#)

Tzu Chi Medical Journal

journal homepage: [www.tzuchimedjnl.com](http://www.tzuchimedjnl.com)

## Case Report

## Dialysis catheter-related pulmonary embolism in a patient with paraquat intoxication

Li-Keng Chao <sup>a</sup>, Te-Chao Fang <sup>b, c, \*</sup><sup>a</sup> Department of Internal Medicine, Buddhist Tzu Chi General Hospital, Hualien, Taiwan<sup>b</sup> Department of Internal Medicine, Wan Fang Hospital, Taipei Medical University, Taipei, Taiwan<sup>c</sup> Department of Internal Medicine, School of Medicine, College of Medicine, Taipei Medical University, Taipei, Taiwan

## ARTICLE INFO

## Article history:

Received 6 February 2015

Received in revised form

6 April 2015

Accepted 29 April 2015

Available online 2 July 2015

## Keywords:

Double-lumen catheter

Paraquat intoxication

Pulmonary embolism

## ABSTRACT

A 30-year-old woman was sent to the emergency room after alcohol and paraquat ingestion. After three sessions of hemoperfusion via the indwelling double-lumen catheter, the patient could tolerate ambient air and her urine output was good. However, on the 10<sup>th</sup> day of hospitalization, she had a sudden onset of dyspnea and hypoxia. Pulmonary embolism was diagnosed by a computed tomography pulmonary angiogram. The patient recovered after anticoagulation therapy. We could find no reports of dyspnea caused by pulmonary embolism in patients with paraquat intoxication. Here, we present this rare case; the indwelling double-lumen catheter might have been a cause of the pulmonary embolism.

Copyright © 2015, Buddhist Compassion Relief Tzu Chi Foundation. Published by Elsevier Taiwan LLC. This is an open access article under the CC BY-NC-ND license (<http://creativecommons.org/licenses/by-nc-nd/4.0/>).

## 1. Introduction

Paraquat (1,1'-dimethyl-4,4'-bipyridinium dichloride) is a rapidly acting, nonselective herbicide, which is widely used because it is relatively inexpensive [1]. Dermal or spray exposure generally causes only limited, localized injury. However, accidental or deliberate ingestion results in an extremely high case-fatality rate. In addition to intense local irritation of the mouth, oropharynx, and esophagus and multiple organ failure (cardiac, respiratory, hepatic, and renal) may occur. Pulmonary features predominate and are the usual causes of death. The present report describes a case of paraquat poisoning in which the patient's clinical condition improved after three rounds of hemoperfusion. However, the patient developed dyspnea during hospitalization and was diagnosed with a superimposed pulmonary embolism, but made a complete recovery after anticoagulation therapy. We found no reports of dyspnea caused by pulmonary embolism in patients with paraquat intoxication in the literature. In this case, paraquat intoxication may have been the main cause of dyspnea, but other possible causes must be kept in mind, such as pulmonary embolism

when hemoperfusion is performed by inserting a double-lumen catheter in a central vein.

## 2. Case report

A 30-year-old woman was sent to the emergency room because of an attempted suicide with an uncertain quantity of paraquat (probably 3–4 mouthfuls, liquid form) consumed with rice wine. She had an argument with her husband the night prior to admission. There was no history of vomiting, loose stools, abdominal pain, seizures, or fever. She had a history of hypertension under regular medication control for 2 years.

She was sent to a local hospital, where activated charcoal was administered. She was referred to our hospital 12 hours later and was admitted to the intensive care unit. At the time of examination, she was conscious, alert, and oriented. Her oral cavity showed mild mucosal erosion of her lips. On physical examination, the pulse rate was 98 beats/min and regular, blood pressure was 130/80 mmHg, and respiratory rate was 22 breaths/min with an SpO<sub>2</sub> of 98% under ambient air. Her heart sound was normal. There was no difficulty in breathing, but there were mild crackles over the bilateral lower lung fields. Her pupils were equal bilaterally and reactive to light. Both activated charcoal and methylprednisolone were administered at admission. Her initial chest radiograph showed no infiltrates. A biochemistry survey revealed metabolic acidosis (pH 7.46, pCO<sub>2</sub> 28.8 mmHg, and HCO<sub>3</sub> 19.9 mmol/L) with mild

Conflict of interest: none.

\* Corresponding author. Department of Internal Medicine, Wan Fang Hospital, Taipei Medical University, 111, Section 3, Hsing-Long Road, Taipei, Taiwan. Tel.: +886 2 2930 7930x8108; fax: +886 2 2930 2448.

E-mail address: [fangtechao@yahoo.com.tw](mailto:fangtechao@yahoo.com.tw) (T.-C. Fang).

<http://dx.doi.org/10.1016/j.tcmj.2015.05.005>

1016-3190/Copyright © 2015, Buddhist Compassion Relief Tzu Chi Foundation. Published by Elsevier Taiwan LLC. This is an open access article under the CC BY-NC-ND license (<http://creativecommons.org/licenses/by-nc-nd/4.0/>).

hypoxemia (pO<sub>2</sub> 66.1 mmHg, SpO<sub>2</sub> 93.8%) under ambient air with normal serum urea and creatinine levels on the day of admission (Table 1). She was found to have a high serum ethanol level. Liver enzymes (serum glutamic oxaloacetic transaminase and serum glutamate-pyruvate transaminase) were only slightly elevated with normal bilirubin and albumin levels, and prothrombin time. Urine was quantitatively positive for paraquat, and urine paraquat was qualitatively positive at 3047 ng/mL after the first hemoperfusion, which became negative after the third hemoperfusion. Blood paraquat tests were negative. A urine human chorionic gonadotropin test was negative for pregnancy. Other toxicological screenings for acetaminophen, methanol, and benzodiazepines were also negative, and the results of an infection panel (complete blood count and C-reactive protein) were all within the normal ranges. Blood and urine cultures were sterile. Other blood investigations including urine examination were normal (Table 1).

During hospitalization, acute kidney injury was noted, with serum creatinine levels up to 1.6 mg/dL (estimated glomerular filtration rate 40 mL/min) on the 3<sup>rd</sup> day, which normalized gradually during hospitalization (Table 2). A double-lumen femoral catheter was inserted and hemoperfusion was performed consecutively during the initial 3 days. Her condition improved, and she was transferred to a ward on the 4<sup>th</sup> day of hospitalization. She could tolerate room air, and her urine output was good. Due to a high alveolar–arterial oxygen gradient (AaDO<sub>2</sub>; 48; arterial blood gases: pH 7.41, pCO<sub>2</sub> 41.2 mmHg, pO<sub>2</sub> 77.9 mmHg, HCO<sub>3</sub> 25.2 mmol/L, SpO<sub>2</sub> 95.4%), lung radiotherapy was introduced on the 5<sup>th</sup> day of hospitalization to prevent further lung injury. Her dyspnea gradually improved. The double lumen was removed on the 7<sup>th</sup> day of hospitalization.

However, on the 10<sup>th</sup> day of hospitalization, a sudden aggravation of dyspnea and hypoxia occurred (respiratory rate 32 breaths/

min, arterial blood gases: pH 7.45, pO<sub>2</sub> 57.6 mmHg, pCO<sub>2</sub> 35.2 mmHg, HCO<sub>3</sub> 23.7 mmol/L, SpO<sub>2</sub> 90.8% under room air, AaDO<sub>2</sub> 48) accompanied by severe tachycardia (about 125 beats/min). A chest examination and a chest film showed no abnormalities (Fig. 1A). Electrocardiography showed sinus tachycardia with S1Q3T3 (Fig. 1B), and her D-dimer level was elevated (4265 ng/mL). An urgent computed tomography pulmonary angiogram revealed massive filling defects in the bilateral pulmonary arteries, compatible with pulmonary embolism (Fig. 1C). Heparin was used immediately targeting an activated partial thromboplastin time 1.5 times the normal upper limit. Sonography revealed no venous thrombosis in the legs. Her dyspnea and blood oxygen saturation improved gradually. Her hemodynamics stabilized and warfarin was overlapped after heparin infusion for 4 days. A survey of risk factors for pulmonary embolism revealed no history of deep venous thrombosis or pulmonary embolism prior to this admission, no oral contraceptive use, and no known malignancy, and she was not on total bed rest in the general ward. A coagulation profile (prothrombin time and activated partial thromboplastin time) and thrombophilia screen (antithrombin III, protein S, protein C, lupus anticoagulant, cardiolipin, immunoglobulins M and G, and anti-nuclear antibodies) showed results within the normal ranges. Meanwhile, lung radiotherapy was completed with a total dose of 1200 cGy (10 fractions) within 2 weeks.

After adequate anticoagulation therapy for 2 weeks, her follow-up pO<sub>2</sub> was 97.2 mmHg under ambient air (Table 2). Pulmonary function tests also revealed data within the normal ranges. The patient was discharged after 25 days of hospitalization with warfarin. Four months later, a computed tomography pulmonary angiogram disclosed regression of the previous hypodense thrombi in the bilateral pulmonary arteries (Fig. 1D). The time sequence of this patient with paraquat intoxication is shown in Fig. 2.

### 3. Discussion

We present a patient who was admitted to our hospital with paraquat intoxication and developed pulmonary embolism during hospitalization. To our knowledge, there are no reports of these problems occurring concurrently in the literature.

Paraquat generates reactive oxygen species that cause cellular damage via lipid peroxidation, activation of nuclear factor-κB, mitochondrial damage, and apoptosis in many organs [2]. Studies in experimental animals have demonstrated that paraquat produces an acute damaging phase in the lung, followed by a reparative phase dominated by extensive fibrosis. The latter is a major contributor to the lung lesion that causes hypoxemia [3]. Paraquat also causes renal and liver injury [2].

In the management of paraquat ingestion, elimination methods such as hemodialysis and hemoperfusion are unlikely to change the clinical course, and the efficacy of immunosuppression with steroids (dexamethasone and methylprednisolone) or cyclophosphamide is very weak, although widely practiced [2]. The prognosis depends on plasma paraquat concentrations, urine and plasma dithionite tests, and clinical features [4,5]. Our patient had a history of paraquat intoxication, as evidenced by physical examination and urine paraquat tests.

When the patient was recovering from paraquat poisoning, an episode of pulmonary embolism occurred. The mechanism of thrombus formation may be explained by Virchow's triad (hypercoagulability, venous stasis or turbulence, and endothelial injury). Risk factors were reviewed in this patient. Although she was on bed rest during the first 3 days of hospitalization, she did not develop deep venous thrombosis (as shown by sonography of the legs), and there was no malignancy. According to some studies, factor V Leiden mutation is common in Caucasians, but is rare in the Chinese

**Table 1**  
Laboratory data.

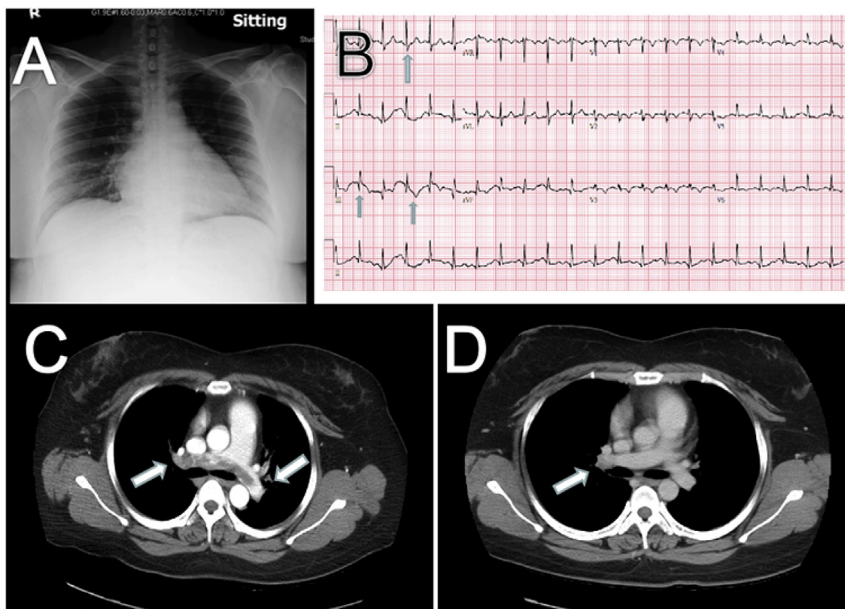
Variable	On admission	Reference range
Artery blood gas	pH 7.45	7.35–7.45
	pCO <sub>2</sub> 28.8	35–45 mmHg
	HCO <sub>3</sub> 19.9	22–26 mmol/L
	pO <sub>2</sub> 66	80–95 mmHg
	SpO <sub>2</sub>	95–98%
Biochemistry	Blood urea nitrogen	7–18 mg/dL
	Serum creatinine	0.7
	AST (GOT)	47
	ALT (GPT)	54
	LDH	166
	Blood albumin	4.2 g/dL
Toxicology panel	Urine benzodiazepine	Negative (<30)
	Blood acetaminophen	<2.0 μg/mL
	Blood methanol	Undetectable
	Blood ethanol	227.4
	Urine paraquat (qualitative)	Positive
	Blood paraquat (qualitative)	Undetectable
	Urine paraquat (quantitative)	Paraquat 3047 ng/mL
Hemogram	White blood cells	5.59
	Segments form (%)	52.8
	Hemoglobin	15.0
	Platelet count	300
	C-reactive protein	<0.05
	Others	
Urine HCG	Negative	Negative
Blood culture	No growth	No growth
Urine culture	No growth	No growth

ALT = alanine transaminase; AST = aspartate aminotransferase; GOT = glutamic oxaloacetic transaminase; GPT = glutamate-pyruvate transaminase; HCG = human chorionic gonadotropin; LDH = lactate dehydrogenase.

**Table 2**  
Artery blood gas and serum creatinine levels.

		Day 1	Day 3	Day 5	Day 7	Day 10	Day 14	Day 23	Day 42
ABG	pH	7.46	7.40	7.41	7.42	7.45	7.40	7.41	7.41
	pCO <sub>2</sub> (mmHg)	28.8	39.3	41.2	43.5	35.2	36.9	37.5	38.1
	pO <sub>2</sub> (mmHg)	66.1	80.5	77.9	86.1	57.6	99.2	97.2	98.2
	HCO <sub>3</sub> (mmol/L)	19.9	24.0	25.2	27.5	23.7	22.3	23.0	23.7
	SpCO <sub>2</sub> (%)	93.8	95.8	95.4	96.8	90.8	99.0	97.5	97.6
	FiO <sub>2</sub> (%)	21	21	21	21	21	21	21	21
AaDO <sub>2</sub>		48	20	20	9	48	4	6	4
Creatinine (mg/dL)		0.7	1.6	1.5	1.2	1.3	1.1	1.0	0.7

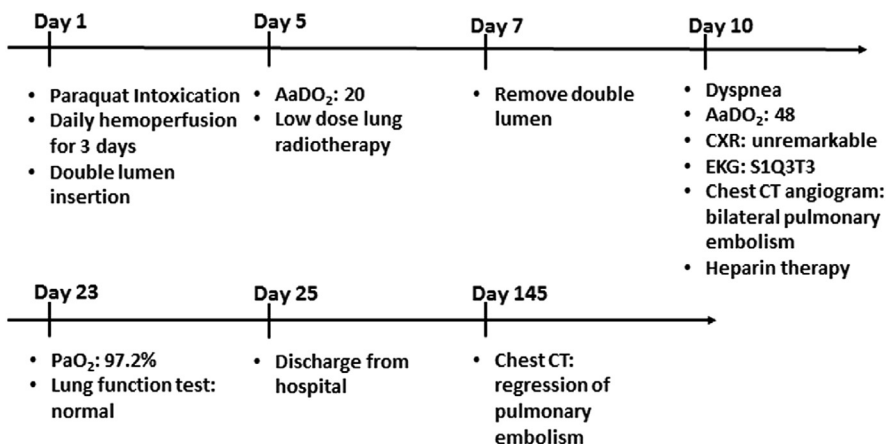
AaDO<sub>2</sub> = alveolar–arterial oxygen gradient; ABG = artery blood gas.



**Fig. 1.** (A) Chest radiograph performed on the 9<sup>th</sup> day of hospitalization when dyspnea occurred. (B) Electrocardiography showing S1Q3T3. (C) Filling defects over the bilateral pulmonary arteries. (D) Regression of filling defects 4 months after treatment with anticoagulants.

population [5–8]. The results of a thrombophilia screen were all within the normal ranges. Hence, hypercoagulability and venous stasis were excluded as risk factors. Therefore, vascular endothelium injury, a major component of Virchow's triad, might have played a key role in this patient. The vascular endothelium can be damaged by a variety of factors such as mechanical injury of the

venous endothelium during insertion of a catheter and a number of vein punctures. Our patient had an indwelling double-lumen femoral catheter for hemoperfusion. Hsieh et al [9] showed that pulmonary thromboembolism could be a complication of an indwelling femoral catheter. Additionally, there is no association between pulmonary embolism and low-dose lung radiotherapy,



**Fig. 2.** Time sequence of this patient with paraquat intoxication. AaDO<sub>2</sub> = alveolar–arterial oxygen gradient; CT = computed tomography; CXR = chest radiograph; EKG = electrocardiogram.

and to the best of our knowledge, there are no reports on the correlation between paraquat intoxication and thrombi formation in the literature. Therefore, we suspect that this complication occurred due to the indwelling catheter.

Femoral vein catheterization is a common procedure. However, it can cause vascular endothelial injury and thus clot formation, leading to pulmonary thromboembolism. In this case, paraquat intoxication might have been the main cause of dyspnea, but other possible causes, especially pulmonary thromboembolism, must be kept in mind when hemoperfusion is performed by inserting a double-lumen catheter through a central vein.

## References

- [1] Gunnell D, Eddleston M, Phillips MR, Konradsen F. The global distribution of fatal pesticide self-poisoning: systematic review. *BMC Public Health* 2007;7:357.
- [2] Gawarammana IB, Buckley NA. Medical management of paraquat ingestion. *Br J Clin Pharmacol* 2011;72:745–57.
- [3] Smith LL. Mechanism of paraquat toxicity in lung and its relevance to treatment. *Hum Toxicol* 1987;6:31–6.
- [4] Senarathna L, Eddleston M, Wilks MF, Woollen BH, Tomenson JA, Roberts DM, et al. Prediction of outcome after paraquat poisoning by measurement of the plasma paraquat concentration. *QJM* 2009;102:251–9.
- [5] Min YG, Ahn JH, Chan YC, Ng SH, Tse ML, Lau FL, et al. Prediction of prognosis in acute paraquat poisoning using severity scoring system in emergency department. *Clin Toxicol (Phila)* 2011;49:840–5.
- [6] Ho CH, Chau WK, Hsu HC, Gau JP, Chih CM. Prevalence of factor V Leiden in the Chinese population. *Zhonghua Yi Xue Za Zhi (Taipei)* 1999;62:875–8.
- [7] Jun ZJ, Ping T, Lei Y, Li L, Ming SY, Jing W. Prevalence of factor V Leiden and prothrombin G20210A mutations in Chinese patients with deep venous thrombosis and pulmonary embolism. *Clin Lab Haematol* 2006;28:111–6.
- [8] Zakai NA, McClure LA. Racial differences in venous thromboembolism. *J Thromb Haemost* 2011;9:1877–82.
- [9] Hsieh HS, Liao HT, Wei CJ, Tarng DC. Indwelled femoral vein non-cuffed, double-lumen hemodialysis catheter complicated by pulmonary thromboembolism. *Clin Nephrol* 2004;62:162–4.