



Contents lists available at ScienceDirect

## International Journal of Surgery Case Reports

journal homepage: [www.casereports.com](http://www.casereports.com)

# Does situs inversus totalis preclude liver donation in living donor liver transplantation? A series of 3 cases from single institution

Selvakumar N. \*, Neerav Goyal, Mohammed Nayeem, Sandeep Vohra, Subash Gupta

Indraprasta Apollo Hospital, Sarita Vihar, New Delhi 110085, India

## ARTICLE INFO

### Article history:

Received 30 September 2015  
Received in revised form 26 January 2016  
Accepted 26 January 2016  
Available online 11 February 2016

### Keywords:

Situs inversus totalis  
Living donor liver transplantation  
Modified right lobe graft

## ABSTRACT

**INTRODUCTION:** Liver transplantation (LT) is the gold standard for decompensated Chronic Liver Disease (CLD) in individuals satisfying the selection criteria. Organ scarcity is the rate limiting step in liver transplantation across the globe. Expanding the donor pool is practiced by transplant surgeons across the globe in view of perennial donor organ scarcity and ever increasing organ demand.

**PRESENTATION OF CASE:** We have presented series of 3 cases of liver transplantation (LT) with modified left lobe (conventional right) graft from a situs inversus donor and implanting it as a conventional right lobe with a modified technique. The grafts had Type 1, Type 2 and Type 3 biliary anatomies. One graft had inferior hepatic veins also. All three patients had uneventful recoveries. The follow up period range is 4 years to 8 months.

**DISCUSSION:** There are multiple case reports in the literature involving situs inversus donors in liver transplantation. Various techniques have also been described. We describe simple and effective technique which has proved successful to our patients.

**CONCLUSION:** SIT donors can be safely accepted for living donor liver transplantation. It is a technically challenging procedure both for donor liver harvesting and implantation in recipient. This is the first case series of LT using modified left lobe graft (conventional right) from a SIT donor with 2 different techniques. Biliary anastomosis is the tricky part of the operation.

© 2016 The Authors. Published by Elsevier Ltd. on behalf of IJS Publishing Group Ltd. This is an open access article under the CC BY-NC-ND license (<http://creativecommons.org/licenses/by-nc-nd/4.0/>).

## 1. Introduction

Liver transplantation (LT) is the gold standard for decompensated Chronic Liver Disease (CLD) in individuals satisfying the selection criteria [1]. Organ scarcity is the rate limiting step in liver transplantation across the globe. Expanding the donor pool is practiced by transplant surgeons across the globe in view of perennial donor organ scarcity and ever increasing organ demand [2]. We have presented series of 3 cases of liver transplantation (LT) with modified left lobe (conventional right) graft from a situs inversus donor and implanting it as a conventional right lobe with a modified technique [3]. Living donor liver transplantation (LDLT) is technically the most complex surgery. Donor hepatectomy is both technically and emotionally challenging because of major hepatectomy involving healthy individual. We describe yet more challenging case series of LDLT with modified left (conventional right) lobe graft from situs inversus totalis (SIT) donors. There are few case reports of SIT and LDLT. This is the first case series of LDLT using modified left lobe graft (conventional right) from a SI donor with 2 different techniques.

## 2. Presentation of cases

### 2.1. Case 1

44 years old lady from India was symptomatic with decompensated HCV related CLD her 22 years old daughter came forward as a donor. The donor on further evaluation was found to have SIT. CT Liver Angiography (CTLA) was suggestive of SIT. The liver had Type 1 hepatic artery, Type A portal vein and Type IIIA Bile duct anatomy with good volume of right lobe and adequate remnant. The estimated left lobe volume (technically right lobe) was 536 g with one RHV two inferior HVs (IRHV) one portal vein. One hepatic artery and type 3A biliary anatomy. She underwent liver transplantation as described in technique section. Implantation was done with technique A. since the bile ducts were >5 mm apart the drainage was done with two biliary anastomoses. RASD was drained by RYHJ and RPSD was anastomosed to the CHD. Intraoperative Doppler (IOD) showed optimum vascularity of the graft. Intraoperative cholangiogram (IOC) showed optimal opacification of biliary tree of the graft liver with no anastomotic narrowing or leakage. Post operatively patient had steady recovery. Patient was extubated on POD-1. Peak bilirubin was 1.8 on POD 1 and peak INR was 2.2 on POD 3. The drains were removed on POD 10 and patient was discharged home on 18th POD. The last follow up was done on 25th January 2015 on

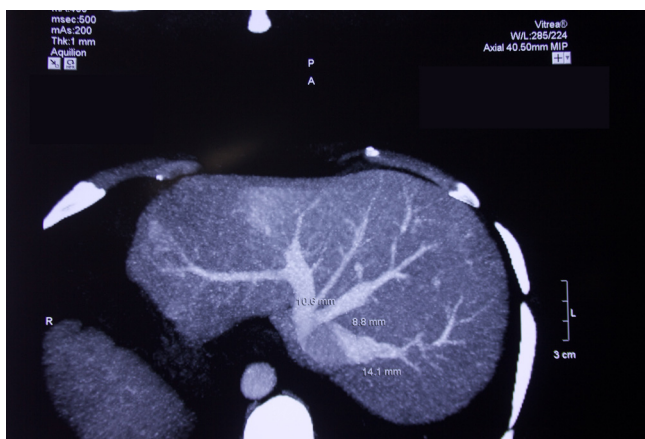\* Corresponding author.

E-mail address: [enselva1@gmail.com](mailto:enselva1@gmail.com) (S. N.).

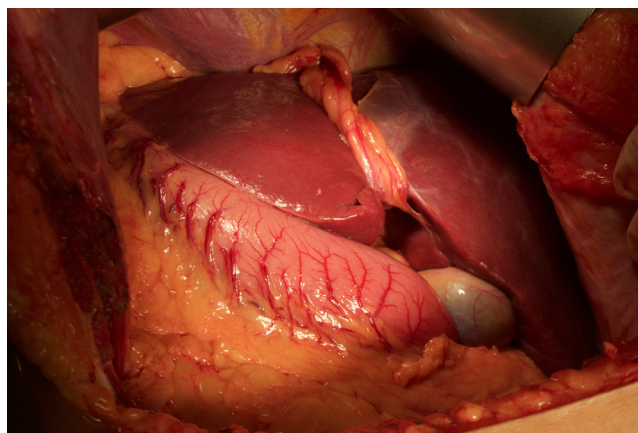
**Table 1**  
List of cases.

| No | Diagnosis       | Patient (age/sex) | Donor(age/sex) | Date of transplantation | Graft | IHV | Implantation          | Type of biliary anastomosis | Complications |
|----|-----------------|-------------------|----------------|-------------------------|-------|-----|-----------------------|-----------------------------|---------------|
| 1  | HCV CLD         | 44/M              | 20/F           | 31-Aug-10               | MRL   | 2   | Cross clamping of IVC | DD + RYHJ                   | NIL           |
| 2  | HBV CLD         | 25/M              | 35/F           | 14-Mar-11               | MRL   | 0   | Cross clamping of IVC | Ductoplasty + DD            | NIL           |
| 3  | Cryptogenic CLD | 46/M              | 45/F           | 14-Mar-15               | MRL   | 0   | Side clamping of IVC  | DD                          | NIL           |

CLD—Chronic Liver Disease; HBV—hepatitis B virus; HCV—hepatitis C virus; MRL—modified right lobe (actual left lobe); IHV—inferior hepatic vein; IVC—inferior vena cava; DD—duct to duct; RYHJ—Roux en Y hepaticojejunostomy.



**Fig. 1.** CTLA venous phase of donor.



**Fig. 2.** Situs inversus liver in donor intraoperatively.

phone. Patient is on single immunosuppression with tacrolimus with stable liver and kidney functions with good quality of life (Table 1).

**2.2. Case 2**

25 years old doctor from Pakistan was a case of decompensated HBV related CLD. His donor was his sister 35 years old female. The donor had situs inversus totalis. CTLA was suggestive of situs inversus totalis. But the liver had Type 1 hepatic artery, Type A portal vein and Type II Bile duct anatomy with good graft volume and adequate remnant. The estimated left lobe (conventional right) volume was 668 g with GRWR of 0.9. The graft had one HV, one segment 5 and one segment 8 veins each, one PV, one HA and 2 bile ducts <3 mm apart. Since RASD and RPSD were close by they were plasted together and were anastomosed to the CHD of the recipient. IOD and IOC were satisfactory. Post operatively patient was extubated on POD-1. Serial dopplers were satisfactory. Peak bilirubin was 3.8 on POD-3 and Peak INR was 1.8 on POD-2. The drains were removed on 9th POD. Patient was discharged on 16th POD. Last follow up was done on 25th January 2015 on phone. Patient is on single immunosuppression with tacrolimus with normal liver and renal functions with good quality of life.

**2.3. Case 3**

45 years old Indian lady with no comorbidities and no previous surgeries was evaluated as a potential liver donor for living donor liver transplantation for her 46 years old husband who had decompensated CLD secondary to cryptogenic cirrhosis. Biochemical and virological examinations were within normal limits. CTLA (Fig. 1) was suggestive of situs inversus totalis. But the liver had Type 1 hepatic artery, Type A portal vein and Type 1 Bile duct with good volume of right lobe and adequate remnant. (Fig. 2). The graft had single RHV no IRHVs, single portal vein single hepatic artery and single bile duct. There were one each of segment 5 and segment 8 veins on the cut surface. Back tabling was done to reconstruct the neo MHV using the recipient PV graft. Implantation was done with

technique B as described in discussion section. Since there was a single bile duct it was anastomosed to the recipient CHD in duct to duct fashion. Patient was extubated on POD 1. Peak bilirubin was 2.4 on POD1 and peak INR was 1.8 on POD3. Drains were removed on POD 10. Patient was discharged on POD16. Last follow up was on 25th January 2015. Patient is on two drugs immunosuppression with stable liver and renal functions.

**3. Discussion**

**3.1. Techniques**

**a) Graft retrieval**

The graft was harvested from the donor as a left lobe graft with out middle hepatic vein (conventional right), the operating surgeon stood on the conventional right side and operated. Modified left (conventional right) lobe graft was taken with segment 5 and 8 veins. IRHVs were preserved if any. All the grafts were retrieved after leaving adequate remnant in the donor (Fig. 1).

**b) Back table**

Back benching was done to create a neo MHV by using recipient portal vein graft to drain the segment 5 and 8 veins. IRHVs also extended with PV grafts to facilitate tension free implantation.

**c) Implantation**

The graft was rotated 180° counterclockwise and placed in the hepatic fossa in the right sub diaphragmatic space.

On end-on view the graft liver was lying with the segments 5 and 8 lying posteriorly (conventionally lie anteriorly) and the segments 6 and 7 lying anteriorly (conventionally lie posteriorly) (Fig. 3 and Fig. 4).

Hepatic venous anastomosis was done by two techniques.

In technique A (cross clamping of IVC) IVC was clamped above at the diaphragm and below at the suprarenal region.

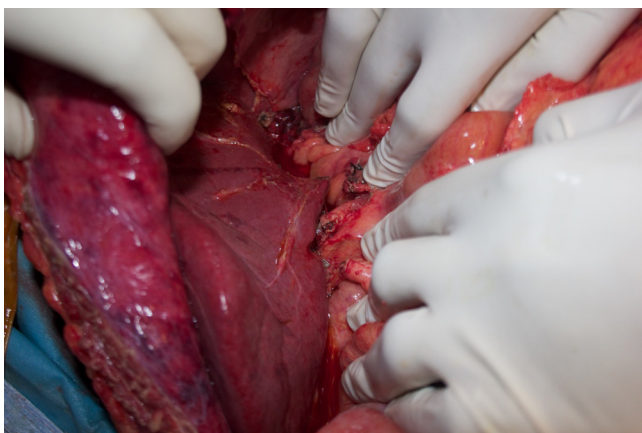


Fig. 3. Completed implantation of situs inversus graft liver.

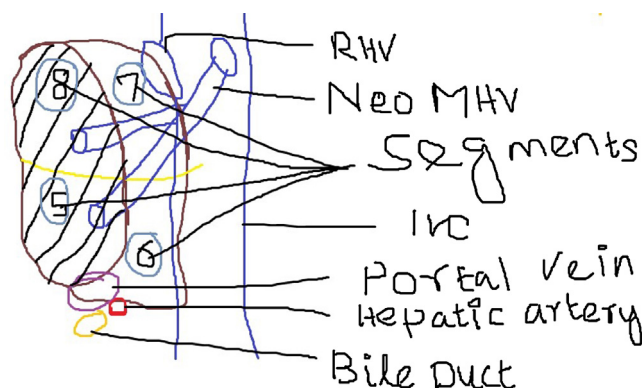


Fig. 4. Illustration of completed implantation.

In technique B (side clamping of IVC) IVC was clamped in side fashion and the veins were implanted one by one to the IVC after securing the completed anastomosis with a bulldog clamp. The Neo MHV was implanted to the MHV-LHV complex of the recipient instead of the IVC as in technique A. All implantations after July 2013 were being done in this technique in our institution. There is clinically significant reduction in the incidences of reperfusion injuries, renal dysfunction and hemodynamic instabilities.

The RHV was anastomosed to the IVC followed by the IHVs and then the neo MHV was anastomosed to the cava (technique A) or to the MHV LHV junction (technique B).

Graft was reperfused after completion of portal vein anastomosis (portal vein anastomosis done in the conventional way) (Fig. 3).

The hepatic artery was lying posterolateral (conventionally anteromedial to the portal vein) and the anastomosis was completed with slight modification in orientation.

The bile duct was lying posteromedial to the portal vein and the operating surgeon had to sit on a chair and position the patient in the right up position and complete the bile duct anastomosis behind the portal vein (Fig. 4).

After completion of anastomosis protocol doppler showed good graft vasculature with optimal portal venous flow and triphasic hepatic venous flow.

At the porta the portal venous anastomosis lies anteriorly (routine grafts it is the posterior most) followed by the hepatic arterial anastomosis and then the bile duct anastomosis.

The biliary anastomosis was done by the surgeon sitting on a chair and do the anastomosis posterolateral to the portal venous anastomosis (anteromedial routinely).

The sequence of anastomosis was RHV, IHVs, neo MHV, PV, HA and bile duct.

There was no increase in WIT in our technique as we followed standard sequence of vascular and biliary anastomosis contrary to the case report from Asan Medical Center where bile duct anastomosis was done prior to HA anastomosis for convenience [4].

#### 4. Conclusion

SIT donors can be safely accepted for living donor liver transplantation. It is a technically challenging procedure both for donor liver harvesting and implantation in recipient. This is the first case series of LT using modified left lobe graft (conventional right) from a SIT donor with 2 different techniques. Biliary anastomosis was the tricky part of the operation.

#### Conflicts of interest

No potential conflicts of interest.

#### Funding

No external sources of fundings.

#### Ethical approval

Ethics committee approval not needed.

#### Consent

Patient consent taken.

#### Author contribution

N. Selvakumar, Mohammed Nayeem, Neerav Goyal Subash gupta—All contributed in the surgery. Sandeep Vohra—Contributed in making images.

#### Guarantor

Subash Gupta.

#### References

- [1] Alice Tung Wan Song, Vivian Iida Avelino-Silva, Rafael Antonio Arruda Pecora, Vincenzo Pugliese, Luiz Augusto Carneiro D'Albuquerque, Edson Abdala, Liver transplantation: fifty years of experience, *World J. Gastroenterol.* 20 (May (18)) (2014) 5363–5374.
- [2] Daniele Pezzati, Davide Ghinolfi, Paolo De Simone, Emanuele Balzano, Franco Filippini, Strategies to optimize the use of marginal donors in liver transplantation, *World J. Hepatol.* 7 (November (26)) (2015) 2636–2647.
- [3] Songfeng Yu, Hua Guo, Wu Zhang, Jun Yu, Sheng Yan, Jian Wu, Min Zhang, Shusen Zheng, Orthotopic liver transplantation in situs inversus adult from an ABO-incompatible donor with situs inversus, *BMC Gastroenterol.* 14 (2014) 46.
- [4] LETTER TO THE EDITORS, Novel technique of implantation for reversed modified right lobe graft from donor with situs inversus totalis: new challenge in adult living donor liver transplantation, *Transplant International* ISSN, 0934–0874.

#### Open Access

This article is published Open Access at [scimedirect.com](http://scimedirect.com). It is distributed under the [IJSCR Supplemental terms and conditions](#), which permits unrestricted non commercial use, distribution, and reproduction in any medium, provided the original authors and source are credited.