

Implantable cardioverter-defibrillator shocks due to tachycardia with more atrial depolarizations than ventricular depolarizations with a far-field ventricular morphology shift: What is the mechanism?



Xin Zhang, MD, Dali Fan, MD, Uma N. Srivatsa, MBBS, MAS, FHRS, Adam Oesterle, MD

From the Division of Cardiovascular Medicine, Department of Internal Medicine, University of California Davis, Sacramento, California.

Introduction

Inappropriate and appropriate implantable cardioverter-defibrillator (ICD) shocks are common. The mechanism can often be elucidated from close interpretation of the device intracardiac electrograms (EGMs). We describe a case where close examination of the EGMs suggests the correct diagnosis, which was confirmed with an electrophysiology (EP) study.

Case report

We report a 60-year-old man with a past medical history significant for drug abuse now on methadone therapy, cardiac arrest due to torsades de pointes status post dual-chamber ICD (St. Jude Medical, Saint Paul, MN) placed at an outside institution, nonischemic cardiomyopathy with improved ejection fraction from 25% to 50%, and supraventricular tachycardia (SVT) terminated by adenosine. He was treated with bisoprolol and amiodarone and referred to EP as an outpatient for evaluation of multiple ICD shocks.

ICD intracardiac EGMs of tachycardia detection (Figure 1A), the response to antitachycardia pacing (ATP) (Figure 1B), and ICD shock (Figure 1C) are shown. Figure 1D shows another episode of tachycardia that the ICD characterized as SVT.

What is the differential diagnosis of the tachycardia? Does ATP help narrow the differential? What are the explanations for the difference in discrimination morphology between Figure 1A and Figure 1D in the context of the tachycardia in Figure 1A?

KEYWORDS Ablation; Electrophysiology study; Implantable cardioverter-defibrillator; Implantable cardioverter-defibrillator shock; Supraventricular tachycardia
(Heart Rhythm Case Reports 2021;7:59–62)

Funding Sources: The authors have no funding sources to disclose. **Disclosures:** No conflicts of interest. **Address reprint requests and correspondence:** Dr Adam Oesterle, Division of Cardiovascular Medicine, Department of Internal Medicine, University of California Davis, 4860 Y St, ACC Building, Suite 2820, Sacramento, CA 95817. E-mail address: aosterle@ucdavis.edu.

KEY TEACHING POINTS

- Close assessment of the implantable cardioverter-defibrillator (ICD) intracardiac electrograms can reveal the arrhythmia diagnosis.
- Supraventricular tachycardia should be considered in the differential diagnosis of an episode classified by the device as ventricular tachycardia, resulting in an ICD shock, even in the presence of a far-field morphology shift.
- The differential diagnosis of a 2:1 atrioventricular (AV) tachycardia includes atrial tachycardia, AV node reentrant tachycardia, and junctional tachycardia.

Device EGM discussion

Figure 1A shows tachycardia detection. There is a mode switch event prior to ventricular tachycardia (VT) detection, indicated by “DDI.” Analysis of the EGMs shows that there are more As than Vs, with an atrial rate of 300 ms. The first 2 depolarizations on the tracing show near-simultaneous A and V activation, followed by a 2:1 AV relationship, another depolarization of simultaneous A and V activation, 2 consecutive 2:1 depolarizations, and then 1:1 tachycardia at 300 ms with simultaneous A and V activation, which falls into the VT detection zone.

Figure 1B shows ATP, which is unsuccessful in terminating the tachycardia. The atrial signal amplitude decreases during ATP. However, ATP does not appear to accelerate the atrial depolarizations to the paced cycle length, dissociating the atrium from the ventricle.

Figure 1C shows successful tachycardia termination with a 36 J shock. Figure 1D shows a simultaneous A and V tachycardia with a 315 ms cycle length, categorized as SVT, with a narrow and different discrimination morphology compared to Figure 1A.

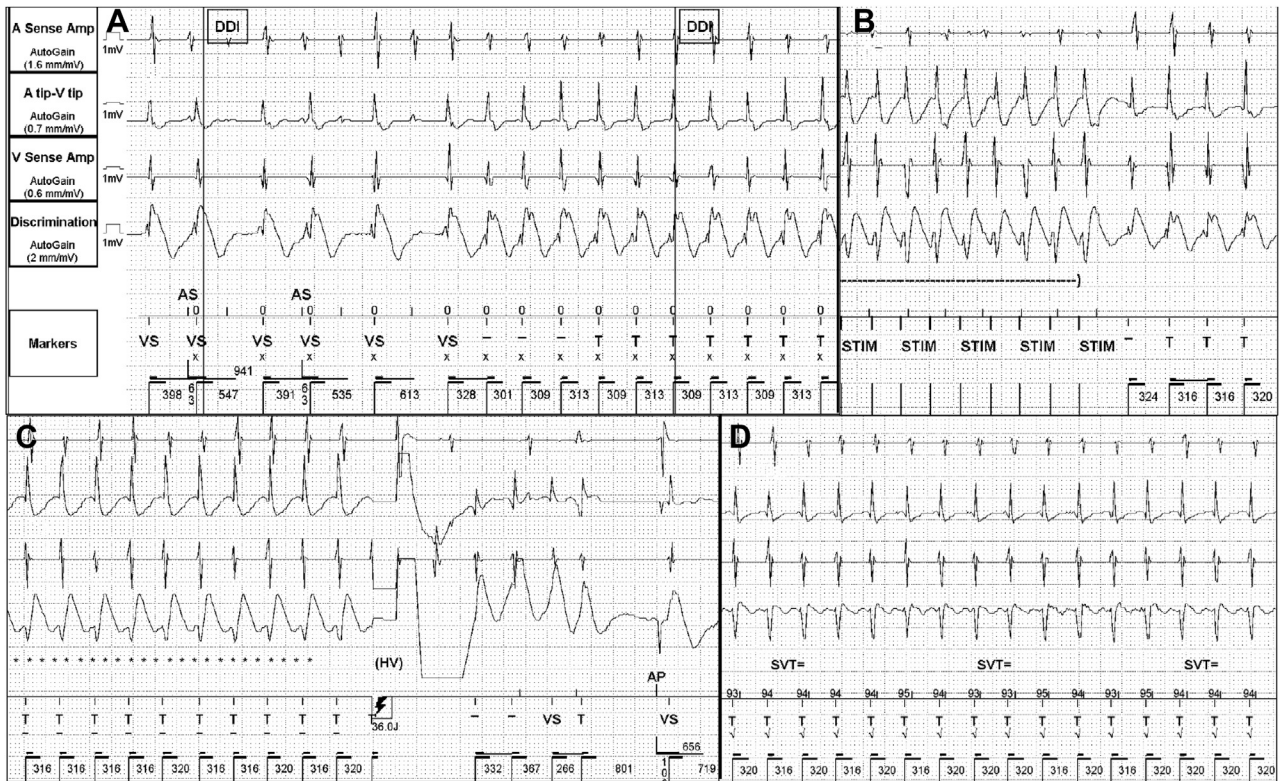


Figure 1 A: Intracardiac electrogram (EGM) demonstrating initial tachycardia detection. B: Antitachycardia pacing fails to terminate the tachycardia. C: Tachycardia is terminated with an intracardiac implantable cardioverter-defibrillator (ICD) shock. D: An ICD EGM that was classified as supraventricular tachycardia by the device. A = atrial; AP = atrial paced; AS = atrial sense; DDI = dual-chamber pacing, dual-chamber sensing, inhibition; HV = high voltage; stim = stimulation; SVT = supraventricular tachycardia; T = tachycardia; V = ventricular; VS = ventricular sense.

The differential for 1:1 tachycardia with near-simultaneous A and V activation includes typical AV node reentry tachycardia (AVNRT), junctional tachycardia, atrial tachycardia (AT), VT with 1:1 retrograde fast pathway conduction, and “double tachycardia”—simultaneous SVT and VT at near-identical rates.

Initiation of 1:1 tachycardia with more As than Vs, with an initial atrial rate identical to the ventricular rate during 1:1 tachycardia, makes double tachycardia and VT unlikely. Although there is a clear morphology shift in the discrimination channel, it is more likely due to a rate-related (phase 3 block) bundle branch block than VT. Phase 3 block is not present in Figure 1D, despite occurring at a similar length—possibly due to changes in autonomic tone and catecholaminergic state, which can affect bundle branch refractoriness. Atrioventricular reentrant tachycardia is ruled out with AV dissociation. The remaining possibilities are AT, junctional tachycardia, and AVNRT with lower common pathway block.

The response to ATP in this case demonstrates dissociation of the A from the V, which favors AT but does not rule out AVNRT with lower common pathway block. It is, however, unusual for a rapid 8-beat drive train to fail to penetrate the AV node during AVNRT. Junctional tachycardia is also less likely, as the atrial rate can either accelerate to the paced cycle length or decrease in the absence of VA conduction.

Case continued

After discussion with the patient, an EP study was performed. During catheter manipulation a 2:1 A:V tachycardia was initiated with catheter premature atrial complexes and AH prolongation. The earliest atrial activation during the 2:1 tachycardia was on the septum (Figure 2A). The surface ECG shows superiorly directed P waves with positive p wave in V₁, and right bundle branch aberrancy. The tachycardia was therefore similar to that seen in the device EGM shown in Figure 1A.

Premature ventricular complexes delivered during tachycardia with 2:1 AV relationship resulted in conversion of the SVT to a 1:1 AV relationship, with a septal VA time of 18 ms (Figure 2B). Ventricular overdrive pacing during 1:1 tachycardia demonstrated an SA-VA time of 154 ms. The postpacing interval – tachycardia cycle length was 251 ms, with a “V-A-H-V” response. Atrial overdrive pacing during tachycardia demonstrated VA linking and an “A-H-A” response. All of the above findings supported typical AVNRT with lower common pathway block as the etiology of the tachycardia seen both in the EP laboratory and on the corresponding device EGM.^{1,2}

Tachycardia was terminated and the ablation catheter was positioned on the anatomic right inferior extension of the slow pathway, and a series of radiofrequency ablation lesions were delivered with automatic junctional ectopy. During a 30-minute waiting period, no arrhythmias were

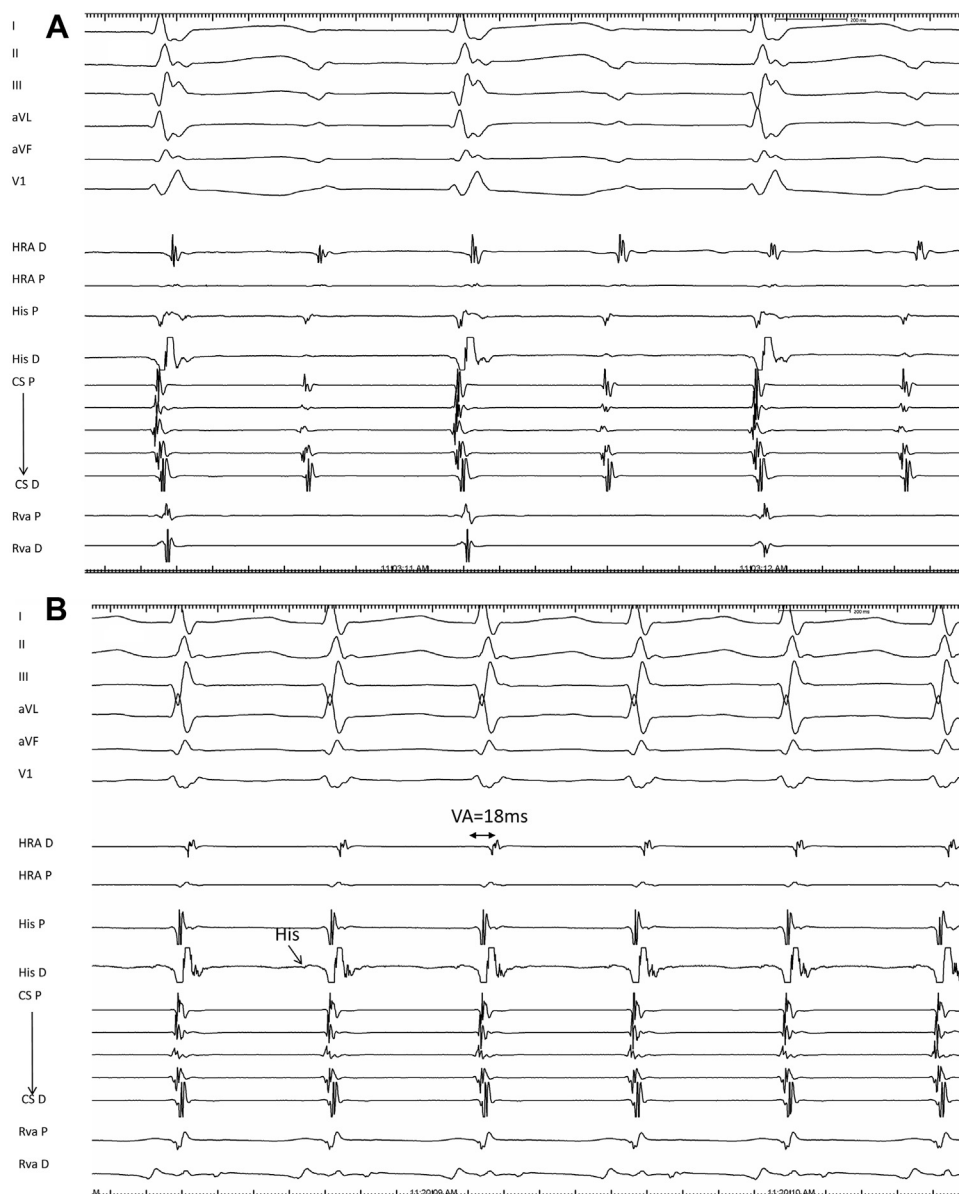


Figure 2 **A:** Intracardiac electrocardiogram (EGM) of supraventricular tachycardia (SVT) with 2:1 AV conduction. A right bundle branch block is seen in V_1 . The earliest atrial activation is at the right atrial (RA) septum. **B:** Intracardiac EGM of SVT with 1:1 AV conduction with a VA time of 18 ms. The 2:1 tachycardia converted to 1:1 tachycardia after premature ventricular contractions were delivered. The atrial activation is identical for both tachycardias. CS = coronary sinus; D = distal; HRA = high right atrium; P = proximal; RVa = right ventricle apex.

inducible with and without isoproterenol administration, or with atrial programmed extrastimulation and burst pacing. The patient has had no additional ICD shocks in follow-up.

Discussion

ICD EGMs should be carefully examined in the event of an ICD shock. This patient was initially treated with amiodarone prior to EP referral. Treating ICD shocks as VT can result in unnecessary ischemia work-ups and toxic medications. Close examination of the EGMs can also expedite curative ablation when the shock is inappropriate and due to SVT, which can significantly reduce patient morbidity.

AVNRT has been shown to have an incidence of 3.5% in the ICD population, which is higher than the general population.³ AVNRT with lower common pathway block has been previously described, with an incidence of as high as 10% during EP study.⁴ It is important to recognize this possibility during a 2:1 AV tachycardia and not misdiagnose AT to avoid mapping and ablating the earliest atrial activation, which may increase the risk of heart block. Spontaneous AVNRT with lower common pathway block has been less commonly described on a device EGM. Recognizing it as part of the differential when analyzing device tracings can help the clinician counsel the patient on the risks and benefits of an ablation procedure and can assist in planning the procedure.

References

1. Michaud GF, Tada H, Chough S, et al. Differentiation of atypical atrioventricular node re-entrant tachycardia from orthodromic reciprocating tachycardia using a septal accessory pathway by the response to ventricular pacing. *J Am Coll Cardiol* 2001;38:1163–1167.
2. Fan R, Tardos JG, Almasry I, Barbera S, Rashba EJ, Iwai S. Novel use of atrial overdrive pacing to rapidly differentiate junctional tachycardia from atrioventricular nodal reentrant tachycardia. *Heart Rhythm* 2011; 8:840–844.
3. Goldberger JJ, Passman R, Arora R, Kadish AH. A higher than expected prevalence of AV nodal reentrant tachycardia in patients receiving implantable cardioverter-defibrillators. *Pacing Clin Electrophysiol* 2011;34:584–586.
4. Man KC, Brinkman K, Bogun F, et al. 2:1 atrioventricular block during atrioventricular node reentrant tachycardia. *J Am Coll Cardiol* 1996; 28:1770–1774.