

Available online at [www.sciencedirect.com](http://www.sciencedirect.com)

ScienceDirect

journal homepage: <http://Elsevier.com/locate/radcr>

## Case Report

# Use of a portal vein localization sheath in the single-needle pass technique for creation of a portosystemic shunt

Yen-Chi Wang MD<sup>a</sup>, Matt Chiung-Yu Chen MD<sup>b,\*</sup>, Mei-Jui Weng MD<sup>c</sup><sup>a</sup> Department of Radiology, E-Da Hospital, Kaohsiung, Taiwan<sup>b</sup> Department of Interventional Radiology, Yuan's General Hospital, No. 162, Cheng-gong 1st Rd., Lingya District, Kaohsiung, Taiwan<sup>c</sup> Department of Radiology, Kaohsiung Veterans General Hospital, Kaohsiung, Taiwan

## ARTICLE INFO

## Article history:

Received 10 October 2016

Received in revised form

31 October 2016

Accepted 22 November 2016

Available online 28 December 2016

## Keywords:

Portosystemic shunt

Transjugular intrahepatic

Ultrasonography

Intervention

## ABSTRACT

This study aimed to report a modification to the single-needle pass technique by use of a portal vein localization sheath for creation of a portosystemic shunt. The modification makes the single-needle pass technique a more straightforward procedure.

© 2016 the Authors. Published by Elsevier Inc. under copyright license from the University of Washington. This is an open access article under the CC BY-NC-ND license (<http://creativecommons.org/licenses/by-nc-nd/4.0/>).

## Introduction

The transjugular intrahepatic portosystemic shunt (TIPS) is a well-proven treatment for complications of portal hypertension. However, this procedure has a long learning curve to become skillful. The most difficult step in TIPS is to establish transjugular systemic to portal vein wire access. TIPS usually requires a longer procedure time compared with other interventional procedures, and has a higher radiation exposure.

Therefore, an alternative method of using the single-needle pass technique for creation of a portosystemic shunt has been reported [1,2] in which the portal vein and systemic vein are connected with a long needle puncture. In the

single-needle pass technique, balloon dilatation of the portosystemic needle tract is a requisite for the transjugular wire to exit to the portal vein. However, in our patients, a 0.035" balloon catheter cannot traverse the portosystemic needle tract. We describe here a modification to the single-needle pass technique by using a portal vein localization (PVL) sheath.

## Materials and methods

We retrospectively reviewed 7 patients in whom the portosystemic shunts were created by the modified

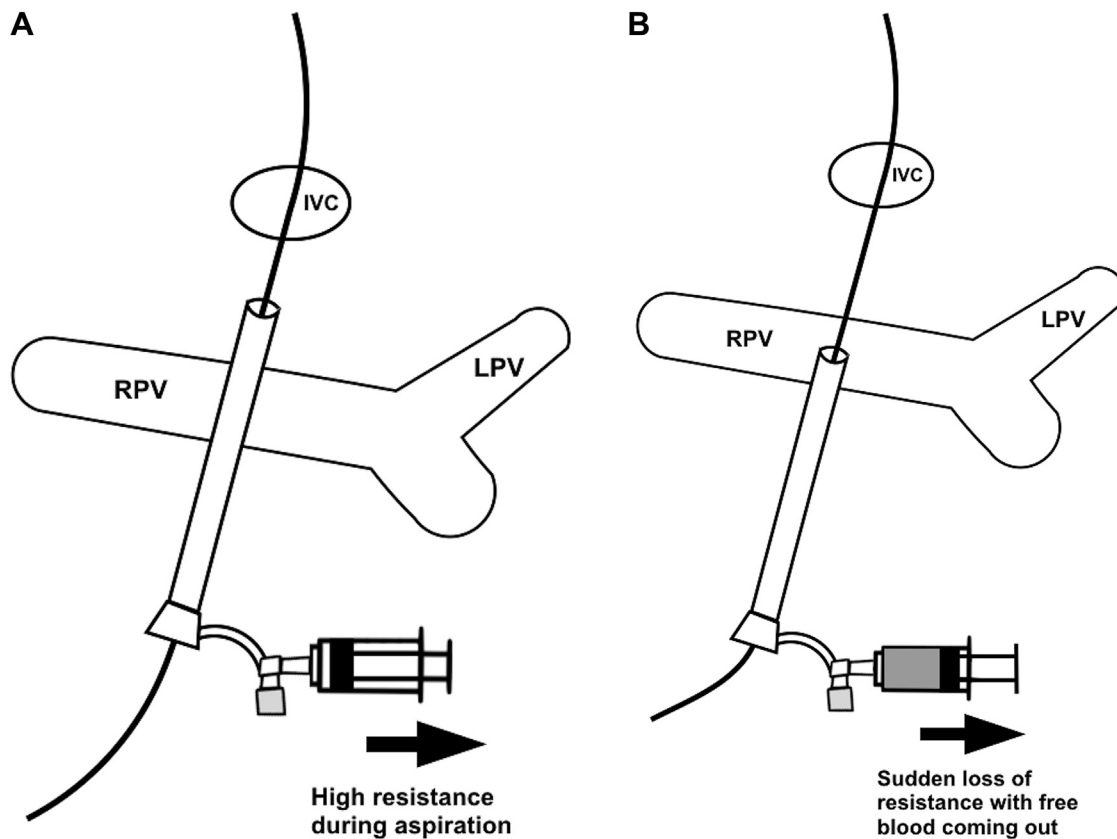
Competing Interests: The authors have declared that no competing interests exist.

\* Corresponding author.

E-mail address: [jjychen@gmail.com](mailto:jjychen@gmail.com) (M.C.-Y. Chen).

<http://dx.doi.org/10.1016/j.radcr.2016.11.014>

1930-0433/© 2016 the Authors. Published by Elsevier Inc. under copyright license from the University of Washington. This is an open access article under the CC BY-NC-ND license (<http://creativecommons.org/licenses/by-nc-nd/4.0/>).



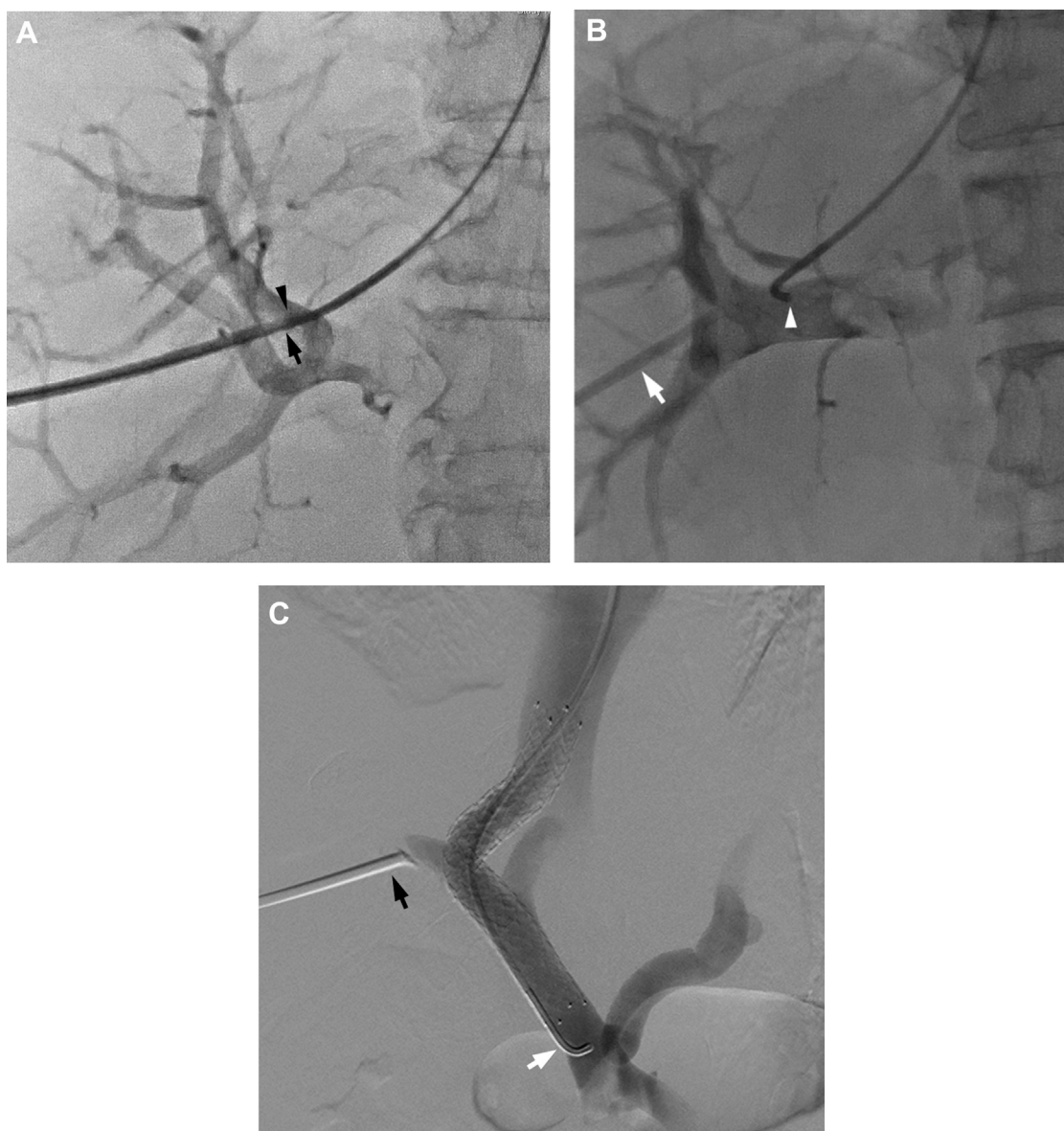
**Fig. 1** – Schema showing how the portal vein localization (PVL) sheath works. (A) When the sheath tip is in the portacaval needle tract, a high resistance is encountered during aspiration and nothing comes out in the syringe. (B) When the sheath tip is already in the portal vein, a sudden loss of resistance can be felt during aspiration and blood comes out freely in the syringe. IVC, inferior vena cava; LPV, left portal vein; RPV, right portal vein.

single-needle pass technique using a PVL sheath from August 2010 to December 2015. Informed consent was obtained from all individual participants included in the study. Institutional review board's approval was obtained for review of the patient's records. The technical success and hemodynamic success were defined according to the guidelines by the Society of Interventional Radiology [3].

#### The modified technique

An animation video of this technique is available as a [Supplementary Video](#). We modified the single-needle pass technique by Raza et al [1] and Boyvat et al [2]. A trans-hepatic puncture was made through the portal vein and into the inferior vena cava (IVC) with an 18G Chiba Needle (20 cm; Top Corp., Shimotsuma-shi, Ibaraki, Japan). A 260-cm stiff hydrophilic wire (Radifocus Guidewire M; Terumo Corporation, Tokyo, Japan) was then threaded into the IVC and was snared out of an 8F sheath in the right internal jugular vein. After a through-and-through wire access was established, we attempted dilatation of the needle tract between the portal vein and the IVC (portacaval tract), by sending a 0.035" low profile balloon catheter (POWERFLEX PRO; Cordis, Miami, FL) via the jugular sheath. However, in

all the 4 patients, the balloon catheter could not be pushed into the portacaval needle tract because high resistance was encountered at the liver surface. Therefore, we used a 6F 25-cm sheath (Radifocus Introducer II; Terumo Corp) to dilate the liver all the way over the through-and-through wire access from the abdominal puncture site to the IVC. Instead of dilating the portacaval needle tract to find the portal vein, we then slowly pulled back the 6F sheath (the PVL sheath) to localize the portal vein. A 10-mL Luer-lock syringe was connected to the PVL sheath and was slowly pulled back until high resistance was encountered, which indicated that the sheath had been pulled into the liver parenchyma (Fig. 1A). During pullback of the PVL sheath, if the operator was in doubt, a hand injection of some contrast medium via the PVL sheath would be helpful to estimate how far the sheath tip had been away from the vena cava. We kept pulling back the PVL sheath against the high resistance until there was a sudden loss of resistance with free aspiration of blood in the syringe, which indicated that the sheath had already been in the portal vein (Fig. 1B). A hand injection venogram was performed to confirm the location of the portal vein. A 5F BER catheter (Cordis) was advanced over the wire via the jugular sheath until the catheter tip was abutting the PVL sheath tip or in the portal vein shadow on the roadmap image (Fig. 2A). When the wire was

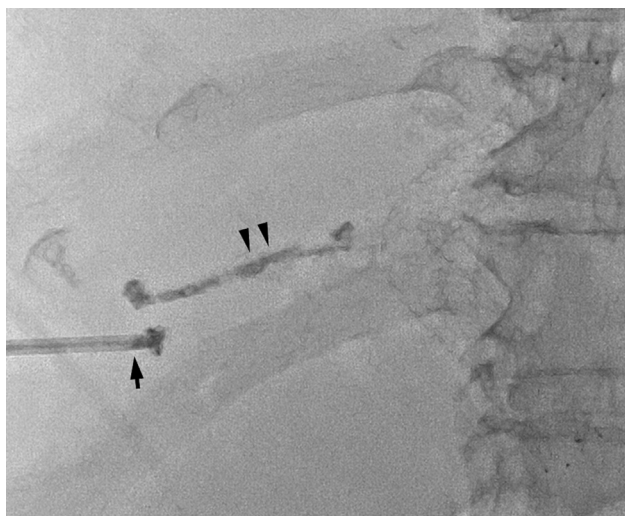

**Fig. 2 – (A)** A 5F BER catheter was advanced over the wire via the jugular sheath until the catheter tip (black arrowhead) was abutting the tip of the PVL sheath tip (black arrow) on the portogram. **(B)** The tip of the BER catheter (arrowhead) spontaneously went into the portal vein when the through-and-through wire access was withdrawn away from the PVL sheath (arrow). **(C)** A completion venogram was performed via the BER catheter (white arrow) after a bare metal stent was deployed in the portacaval shunt. The PVL sheath remained in place (black arrow).

withdrawn from the jugular sheath, the tip of the BER catheter resumed its right-angle shape and then spontaneously went into the portal vein (Fig. 2B). The wire was reinserted via the BER catheter and then manipulated into the splenic vein or superior mesenteric vein. A 5 mm × 4 cm standard balloon was advanced via the jugular vein sheath to the portacaval needle tract, which had been dilated with the PVL sheath, for predilatation. A 10 mm × 8 cm bare metal stent (Complete SE Vascular Stent; Medtronic, Minneapolis, MN) was then deployed (Fig. 2C). When the desired pressure gradient was achieved after dilatation of the stent, the PVL sheath was removed with the sheath tract sealed off by N-butyl cyanoacrylate (Fig. 3).

## Results

A total of 7 portosystemic shunts were created in 7 male patients. Of them, 4 shunts were created by the modified single-needle pass technique in 4 patients aged 50–53 years (mean age, 51.5 years), and the traditional transjugular technique was performed in the others. The mean fluoroscopic time was 45.7 minutes and the mean procedure time 175.3 minutes (the procedure time of patient 2 was not available). No patient died within 30 days after creation of a shunt. Two patients died during follow-up because of gastric cancer (patient 6) and hepatocellular carcinoma (patient 4). Patient 2 underwent a



**Fig. 3 – The intrahepatic sheath tract was sealed off by N-butyl cyanoacrylate (arrowheads) via the PVL sheath (black arrow), which had been pulled out of the liver.**

successful reintervention 286 days after creation of a shunt for recurrent ascites. The clinical and demographic characteristics of patients are shown in Table 1. The technical and hemodynamic success rates were both 100%.

## Discussion

The traditional TIPS procedure requires a reasonable length of time to be skillful and many of the procedural complications are a consequence of the learning curve for this complex procedure [4]. For creation of a portosystemic shunt, the single-needle pass technique has been reported as a useful alternative when the standard TIPS technique fails.

There are 2 critical steps in the single-needle pass technique as follows: (1) a puncture through the portal vein into the IVC, which is not difficult for an operator who is skillful in ultrasound-guided procedures and (2) shifting from the through-and-through wire access to the transjugular systemic to portal access. Boyvat et al [2] sent a 0.035" ultrathin balloon via the jugular sheath to the intrahepatic tract. After the tract was dilated under sonographic control, an 8F sheath was advanced into the tract to identify the portal vein.

According to the reported technique [1,2], we attempted, but failed, to traverse the portacaval needle tract, which had been dilated by an 18G Chiba needle, by a commonly available 0.035" low profile balloon catheter. The reasons for failure might be because (1) the balloon that was used by previous authors was different from ours, but they did not specify the balloon in their reports and (2) the degree of liver fibrosis was different and the texture of the liver was harder in our patients than those in patients in the previous reports.

Considering the single-needle pass technique, our modification would be a better option among the reported ones [1,2] when the liver texture is hard, which makes transjugular traversal of the balloon catheter in the portocaval needle tract difficult or impossible. Therefore, preprocedural assessment

**Table 1 – Clinical and demographic characteristics.**

Case number	Age, y	Child-Pugh score	MELD score	Indication	Fluoroscopic time	Procedure time	Shunt type	Pressure gradient (mm Hg)	Death in 30 d
1	52	8	18	Refractory ascites	41.8 min	3 h	Portocaval shunt	9	No
2	50	8	16	Refractory ascites	48.3 min		Portocaval shunt	11	No
3	51	7	14	EV bleeding	21.4 min	2 h 26 min	Portocaval shunt	10	No
4	53	9	19	Refractory ascites	71.4 min	3 h 20 min	Portocaval shunt	8	No
MELD, Model For End-Stage Liver Disease; EV, esophageal varices.									
								2016/1/6 (recurrent ascites)	Dead for hepatoma

of the liver stiffness would be of value in selecting which single-needle pass technique to use. Multiple studies have shown a strong correlation between the measurement results of the magnetic resonance and transient elastographic techniques and the stage of hepatic fibrosis at histologic examination [5]. Nevertheless, the role of elastography in such a clinical setting is currently unclear.

In the previously reported alternative way of using the single-needle pass technique [1,2], after the balloon was pushed into the portacaval needle tract, the authors had to stop the fluoroscope and performed an in-procedure sonogram to guide positioning of the balloon between the portal vein and the IVC. They then stopped the sonogram and used the fluoroscope again during balloon inflation. In our modification, there was no need to shift between the sonogram and fluoroscope to visualize the portacaval needle tract. In addition, because a clear hand injection venogram or road-map image of the portal vein could be obtained via the PVL sheath, we did not need to search for the portal vein shadow by injecting contrast medium into the balloon-macerated needle tract in the liver parenchyma. The PVL sheath thus made wiring into the portal vein more straightforward to perform.

---

## Conclusion

Use of the PVL sheath as a modification to the single-needle pass technique for creation of a portosystemic shunt maybe safe and effective. In addition, this modified technique also

makes the single-needle pass technique a more straightforward procedure to perform.

---

## Supplementary data

Supplementary data associated with this article can be found in the online version, at <http://dx.doi.org/10.1016/j.radcr.2016.11.014>.

---

## REFERENCES

- [1] Raza SA, Walser E, Hernandez A, Chen K, Marroquin S. Transhepatic puncture of portal and hepatic veins for TIPS using a single-needle pass under sonographic guidance. *Am J Roentgenol* 2006;187:W87–91.
- [2] Boyvat F, Harman A, Ozyer U, Aytekin C, Arat Z. Percutaneous sonographic guidance for TIPS in Budd-Chiari syndrome: direct simultaneous puncture of the portal vein and inferior vena cava. *Am J Roentgenol* 2008;191:560–4.
- [3] Dariushnia SR, Haskal ZJ, Midia M, Martin LG, Walker TG, Kalva SP, et al. Quality improvement guidelines for transjugular intrahepatic portosystemic shunts. *J Vasc Interv Radiol*. Elsevier 2016;27:1–7.
- [4] Saxon RR, Keller FS. Technical aspects of accessing the portal vein during the TIPS procedure. *J Vasc Interv Radiol* 1997;8:733–44.
- [5] Barr RG, Ferraioli G, Palmeri ML, Goodman ZD. Elastography assessment of liver fibrosis: society of radiologists in ultrasound consensus conference statement. *Radiology* 2015;276:845–61.