



Case report

An unusual localization of echinococcosis: Gallbladder hydatid cyst

Ghassen Hamdi Kbir, Sohaib Messaoudi, Marwen Selmi*, Mohamed Maatouk, Mohamed Tahar Bouzidi, Farouk Ennaceur, Mounir Ben Moussa



A21 Surgery Department, Charles Nicolle Hospital, Research laboratory LR12ES01, Faculty of medicine of Tunis, Tunis El Manar University, Tunis, Tunisia

ARTICLE INFO

Article history:

Received 30 January 2022

Received in revised form 16 February 2022

Accepted 17 February 2022

Keywords:

Hydatidosis

Gallbladder

Liver

Hydatid Cyst

ABSTRACT

Echinococcosis is endemic in Mediterranean countries. Liver then lungs are the most affected organs. Gallbladder hydatid cyst is an exceptional localization.

A 64-year-old patient was referred to our surgical outpatient department by his physician for suspicion of liver hydatid cyst based on right upper quadrant abdominal pain, associated with nausea. Physical examination showed mild tenderness of the right upper quadrant of the abdomen. A computed tomography abdominal scan showed a multivesicular cystic lesion of the segment IV measuring $9.5 \times 7.5 \times 13$ cm with exophytic component abutting the gallbladder.

The patient underwent right subcostal laparotomy. The exploration has found that the hydatid cyst is developed from the fundus of the gallbladder, without any connections or fistulas to nearby organs. A cholecystectomy was performed. Histopathological examination confirmed the diagnosis of gallbladder echinococcosis.

Primary gallbladder hydatid cysts (PGHC) is an extremely rare condition, occurring in less than 0.4% of echinococcosis localizations. After literature research of case reports, only twenty-three such cases, including our case, have been reported in English literature. Due to its uncommon nature, radiologists rarely consider a PHGB as the first diagnosis. Preoperative diagnosis of hydatid cyst was possible only in 50% of cases. Therefore, a careful attention is necessary to assist in making the diagnosis preoperatively, leading to the appropriate treatment.

© 2022 Published by Elsevier Ltd.
CC_BY_NC_ND_4.0

Introduction

Echinococcosis remains endemic in Mediterranean countries, especially in Tunisia, where the main species pathogenic for humans is *Echinococcus granulosus* [1]. Liver hydatid cysts are the most frequent localization [2]. The primary hydatid cyst of the gallbladder represents 0.4% of echinococcosis localizations [3].

The diagnosis is based on patient history, physical examination, hydatid serology and radiological imaging. However, accurate diagnosis was mainly made intra-operatively.

Patients with primary hydatid cyst of the gallbladder are those with no history of hydatid disease nor other cysts found at imagery explorations or at the time of surgery [4].

The aim of this case report is to highlight the diagnostic tools, and treatment options of this rare clinical entity.

Case presentation

A 64-year-old patient was referred to the surgery A department of Charles Nicolle hospital in Tunis by his physician for suspicion of liver hydatid cyst, based on right upper quadrant abdominal pain, associated with nausea during 20 days, with no history of jaundice. The ultrasound, showed a heterogeneous cystic mass of the liver involving the gallbladder and the transvers colon.

Physical exam found a mild pain in the right upper quadrant. CBC, renal, liver were normal. Hydatid serology tests (ELISA) < 10 kU/L. Chest x-ray did not show signs of cardio-respiratory disease or lung echinococcosis.

Thoracic and abdominal computed tomography were performed for further identification of the abdominal mass and search for other localizations of eventual cysts.

It concluded to: "Multivesicular cystic mass with brood cysts and exophytic clean wall on the anterior surface of segment 4 of the liver measuring $9.5 \times 7.5 \times 13$ cm (Fig. 1). Gallbladder, architecture and size of biliary ducts were normal. The cystic lesion has close

* Correspondence to: A21 Surgery Department, Charles Nicolle Hospital, Research laboratory LR12ES01, Faculty of medicine of Tunis, Tunis El Manar University, Rue 9 avril , 1007 Bab Saadoun, Tunis, Tunisia.

E-mail address: marwen.fmt709@gmail.com (M. Selmi).

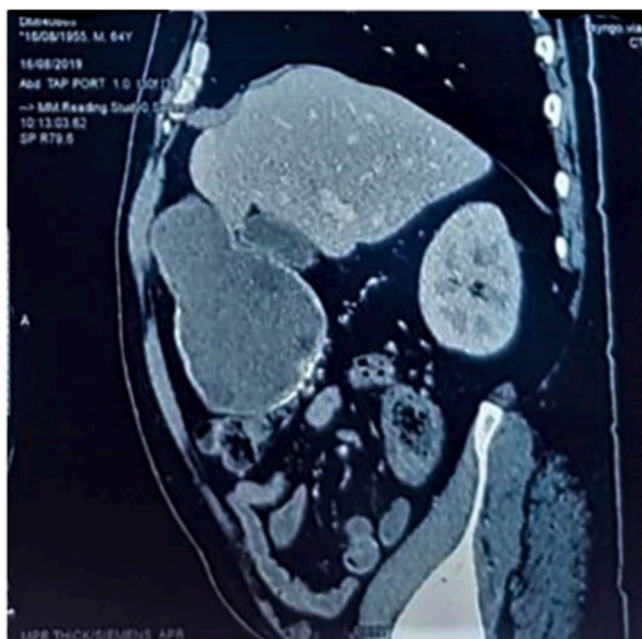


Fig. 1. CT scan showing hydatid cyst of the gallbladder.

connections with the gallbladder and the transvers colon. No fistula was detected."

The patient underwent right subcostal laparotomy. The exploration has found that the hydatid cyst is developed from the fundus of the gallbladder, without any connections or fistulas to nearby organs (Fig. 2). We performed open cholecystectomy, carrying the cyst (Fig. 3). Per operative cholangiography was normal. The examination of the transvers colon found no fistula or erosion of the colon wall. The exploration of the peritoneal cavity found no other cysts.

The patient's postoperative course was uneventful; he was discharged in good condition on the fifth postoperative day. Seen regularly at consultation, with no complications or recidivism.

Discussion

Echinococcosis is a frequent pathology in Tunisia. Liver echinococcosis is a very common pathology of surgical wards [5].

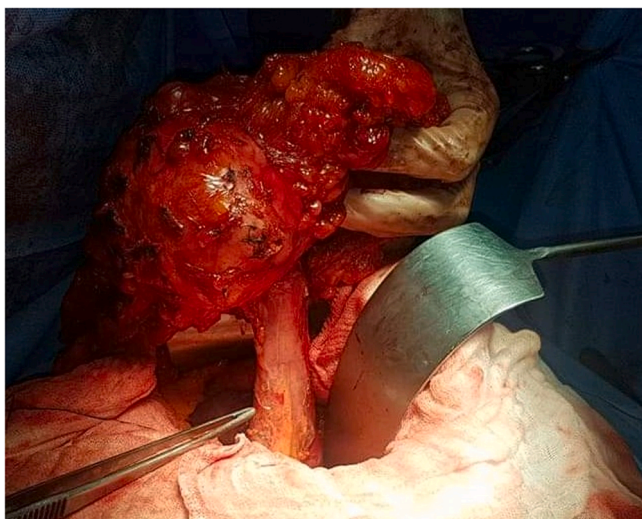


Fig. 2. Per operative view of gallbladder hydatid cyst.

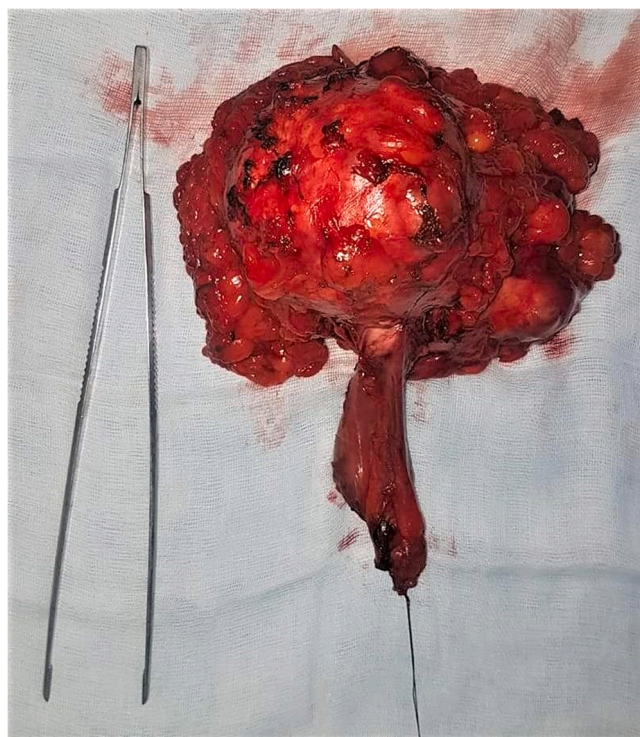

Fig. 3. Specimen of gallbladder with hydatid cyst.

Pathogenesis begins with the ingestion of *Echinococcus granulosus* eggs, which, in the human intestine transform into embryos, due to gastric acidity, then, penetrate actively the small bowel mucosa, enter venules and travel via portal circulation to the liver, the first biological filter [6,7]. Nevertheless, hydatid cysts can develop anywhere in the human body, tracking lymphatic system or venous cava stream [8].

Based on the location of the cyst, theories about the pathogenesis are depending whether the cyst develops in the lumen of the gallbladder or on its external surface. Indeed, in the first case; cysts are the result of dissemination of brood capsules through the biliary duct, whereas, in the second case, cysts develop on the gallbladder's wall after spreading via the lymphatic circulation [4].

Cystic echinococcosis usually remains asymptomatic for a long period of cystic growth; however, the hydatid cysts developing primarily from the gallbladder become symptomatic earlier [4].

Imaging diagnostic tools such as ultrasound and computed tomography are specific in the diagnosis of cystic echinococcosis [6]. Usually, the exact localization of primary gallbladder hydatid cysts is not diagnosed preoperatively, since it depends mainly on the radiologist's experience to determine the origin of the cyst [5]. As in this case, the initial ultrasound and computed tomography scans described the cystic lesion as a hydatid cyst of the liver with involvement of the gallbladder and the transvers colon, only to have the diagnosis corrected intra-operative.

Surgery is the curative treatment of hydatid disease. The aim is the eradication of the parasite without spillage of the cyst content. In liver cystic echinococcosis, partial pericystectomy is the most frequent surgical approach. Cholecystectomy was performed in most of reported cases as well as in this case. Postoperative recovery was uneventful.

Consent

Written informed consent was obtained from the patient.

Ethical approval

Written informed consent was obtained from the patient for the publication of this case report and its accompanying images.

Funding

We declare that no financial support was provided for this publication.

CRediT authorship contribution statement

Ghassen Hamdi Kbir, Sohaib Messaoudi, Marwen Selmi, Mohamed Tahar Bouzidi, Farouk Ennaceur: Clinical management of the patient, writing and editing the manuscript. Mohamed Maatouk and Mounir Ben Moussa: Writing, editing the manuscript.

Conflict of interest

The authors report no conflict of interest.

References

- [1] Bellil S, Limaïem F, Bellil K, Chelly I, Mekni A, Haouet S, et al. Descriptive epidemiology of extrapulmonary hydatid cysts: a report of 265 Tunisian cases. *Tunis Med* févr 2009;87(2):123–6.
- [2] Mushtaque M, Mir MF, Malik AA, Arif SH, Khanday SA, Dar RA. Atypical localizations of hydatid disease: experience from a single institute. *Niger J Surg* 2012;18(1):2–7.
- [3] Yagnik VD, Dawka S, Patel N. Gallbladder hydatid cyst: a review on clinical features, investigations and current management. *Clin Exp Gastroenterol* 2020;13:87–97.
- [4] Uzunoglu MY, Altintoprak F, Dikicier E, Zengin I, Celik A. Hydatid disease in the gallbladder: a rare location. *J Med Cases* 2016;7(12):522–3.
- [5] CDC - DPDx - Echinococcosis [Internet]. 2019 [cité 16 nov 2019]. Disponible sur: <https://www.cdc.gov/dpdx/echinococcosis/index.html>.
- [6] Safioleas M, Stamoulis I, Theocharis S, Moulakakis K, Makris S, Kostakis A. Primary hydatid disease of the gallbladder: a rare clinical entity. *J Hepatobiliary Pancreat Surg* 2004;11(5):352–6.
- [7] WHO Working Group WI. International classification of ultrasound images in cystic echinococcosis for application in clinical and field epidemiological settings. *Acta Trop* févr 2003;85(2):253–61.