

Effectiveness of transcutaneous electrical stimulation combined with artificial tears for the treatment of dry eye: A randomized controlled trial

MING-MING CAI¹ and JIE ZHANG²

Departments of ¹Ophthalmology and ²Urology, The Ninth People's Hospital of Chongqing, Chongqing 400700, P.R. China

Received February 23, 2020; Accepted September 2, 2020

DOI: 10.3892/etm.2020.9305

Abstract. There is currently no available cure or universally effective treatment for dry eye (DE). The aim of the present study was to investigate the clinical efficacy of transcutaneous electrical stimulation (TES) combined with artificial tears in treating DE. Patients diagnosed with DE were referred for therapy with TES combined with sodium hyaluronate (SH)-containing artificial tears. A total of 52 patients (104 eyes) with DE were enrolled in this randomized controlled trial. The patients were randomized 1:1 to the TES + SH or SH group. The patients in the TES + SH group were treated with 20 sessions (5 sessions per week for 4 weeks), and each session lasted for 20 min. The treatment was continued for 4 weeks in all cases. The Ocular Surface Disease Index (OSDI), tear film breakup time (BUT), Schirmer's I test and corneal fluorescein scores were used to assess treatment efficacy. A total of 90 eyes of 45 patients completed all aspects of the study: 22 patients (44 eyes) in the TES + SH group and 23 patients (46 eyes) in the SH group. There was no statistically significant difference in sex, age or course between the two groups. The mean OSDI scores, BUT, Schirmer's I test and corneal fluorescein scores exhibited a significant improvement in the TES + SH group compared with the SH group after treatment. No serious adverse events were recorded during TES treatment. In conclusion, TES combined with artificial tears appeared to be an effective treatment for DE. Therefore, TES may represent a new therapeutic option with promising potential applications.

Introduction

Dry eye (DE) is a multifactorial disease of the ocular surface that is characterized by loss of homeostasis of the tear film and is accompanied by ocular symptoms, in which tear film

instability and hyperosmolarity, ocular surface inflammation and damage, as well as neurosensory abnormalities, play etiological roles (1). DE is one of the most prevalent ocular disorders and is characterized by discomfort symptoms, such as burning, tearing, foreign body sensation and ocular fatigue (2). Patients with DE experience difficulties in daily routine activities that compromise their quality of life (3). The incidence of DE continues to increase, which may be partly associated with changes in lifestyle and working environments.

There is currently no cure or universally effective treatment for DE. The main standard treatment for DE is the topical administration of artificial tears, such as those containing sodium hyaluronate (SH), to provide additional lubrication, but the expected results are usually not optimal and the efficacy is limited. Other therapeutic alternatives consist of topical cyclosporine, topical corticosteroids and punctal occlusion, but their use is limited due to the drawbacks and related side effects (2,4). The currently available treatments are mainly palliative, intended to supplement patients' natural tears or improve the residence time of the limited volume of tears present, as restoring the physiological lacrimal secretion is difficult (5). In addition, a number of patients report less improvement in chronic ocular pain and photophobia with topical therapies (6). Evaluating the potential of low-risk adjuvant treatments in these patients has been attracting increasing interest (7).

Transcutaneous electrical stimulation (TES) is a well-established therapeutic strategy for activating peripheral nerve pathways directly, in order to correct organ dysfunction and manage disease symptoms (8-11). TES involves the transmission of electrical current to the peripheral nervous system through electrodes placed on the skin surface. It is a non-invasive form of neuromodulation that has demonstrated effectiveness in numerous pain conditions and has been widely used over recent decades (12-15). TES also has been used for treating ocular diseases with promising results (7,16,17).

Recently, TES was reported to have potential efficacy as a novel option for treating DE (18). However, clinical researches have been insufficient and no controlled comparative studies demonstrating the superiority of TES for DE have been conducted to date. Hence, the aim of the present study was to prospectively investigate the efficacy of TES combined with artificial tears in the treatment of DE.

Correspondence to: Dr Jie Zhang, Department of Urology, The Ninth People's Hospital of Chongqing, 69 Jia Ling Road, Chongqing 400700, P.R. China
E-mail: zhangjie320320@163.com

Key words: dry eye, ocular surface disease, transcutaneous electrical stimulation

Materials and methods

Participants. This randomized controlled trial was performed to compare TES + SH with SH. The study was performed between February 2019 and December 2019 and was approved by the Ethics Committee of the Ninth People's Hospital of Chongqing. Overall, 138 eyes of 69 patients who met the clinical diagnosis of bilateral DE according to the definitions set out by the International Dry Eye WorkShop were recruited for this study (1). Based on the inclusion/exclusion criteria, 104 eyes of 52 patients who matched the DE criteria were enrolled in the present study by a trained ophthalmologist (Fig. 1).

The inclusion criteria were as follows: i) Patients aged 18-65 years; ii) patients who volunteered to join the study and signed the informed consent form; and iii) patients who conformed to the following DE diagnostic criteria: Schirmer's I test outcomes of ≤ 10 mm, tear film breakup time (BUT) < 10 sec, and presence of DE symptoms evaluated using the Ocular Surface Disease Index (OSDI) questionnaire (OSDI ≥ 13).

The exclusion criteria were as follows: i) Psychiatric and severe systemic diseases; ii) DE complicated by active ocular infection, corneal abnormalities or any other ocular pathologies; iii) history of punctal occlusion; iv) history of biomedical electronic device implantation, including cardiac pacemaker or automatic internal defibrillator, cerebrovascular condition, epilepsy, pregnancy, acute pain of unknown etiology, and skin lesion or injury at the site of electrode placement; v) other previous treatments except artificial tears in the last 2 months; and vi) wearing contact lenses.

Sample size. Based on previous data (18), a power analysis was performed to determine the sample size required to obtain significant effects after the treatment. A dropout rate of 15% was predicted. Therefore, a total sample size of 104 eyes was deemed sufficient.

Randomization. Washout was carried out in all patients with preservative-free saline eye drops instilled four times per day for 2 weeks. After washout, all patients were randomized 1:1 into two groups, each with 52 eyes of 26 patients, using a computer-generated list of random numbers by a special statistician. Patients in the SH group used only SH eye drops (URSAPHARM Arzneimittel GmbH) four times per day, while patients in the TES + SH group used TES combined with SH therapy. The treatment was continued for 4 weeks in all cases. The patients were made aware of the treatment group assignment, but the examiner was blinded to the grouping of the patients.

Application of electrical stimulation. Electrical stimulation was applied with a device (Huatuo brand SDZ-II Electrical Stimulator, Suzhou Medical Supply & Equipment). Its function was based on the resonance effect, with the possibility of maximizing the delivery of energy to biological tissues by oscillating electric fields without increasing the temperature and eliciting biological responses, both pathophysiological and potentially therapeutic (19).

The participants were asked to lie down comfortably and relax in a quiet environment. The skin overlying the sites of

electrode placement was first cleaned with alcohol pads and allowed to dry. Treatment was administered as previously described (7,18). Two rectangular electrodes sized 50x30 mm² were placed in the periorbital area of each eye: One over the temporal area and one near the lower lid, so that they were in proximity to the ophthalmic (V1) and maxillary (V2) branches of the trigeminal nerve (Fig. 2).

Each patient underwent 20 sessions (5 sessions per week for 4 weeks), and each session lasted for 20 min, with a frequency of 20 Hz and a power of no more than 2 mA. The amplitude of each eye was increased manually until the point of discomfort and then set to one level below this point.

Safety evaluation. The adverse effects included dizziness, edema and severe pain during or after electrical stimulation. Any other adverse events were also recorded.

Ocular examinations. Improvement in OSDI, BUT, Schirmer's I test and corneal fluorescein staining were assessed and compared before and after treatment. A single examiner performed all ocular examinations.

OSDI scores were obtained according to a subjective questionnaire, and the patients gave their impressions on the status of their eyes before and after treatment. Symptoms such as itching, dryness and foreign body sensation were evaluated (20). BUT was observed under a slit lamp biomicroscope. Three measurements were performed and the mean value was calculated. The Schirmer's I test was performed using standard strips (Alcon) kept in the lower conjunctival sac for 5 min. Corneal fluorescein staining was scored according to the grading system recommended by the National Eye Institute/Industry Workshop on Clinical Trials in Dry Eyes (21). The cornea was divided into five zones: Central, superior, temporal, nasal and inferior. For each zone, the amount of corneal fluorescein staining was graded on a scale of 0-3 as follows: 0, normal or negative slit lamp findings; 1, mild or superficial stippling; 2, moderate or punctate staining, including superficial abrasion of the cornea; and 3, severe abrasion or corneal erosion, deep corneal abrasion, or recurrent erosion. The maximum score was 15 (22).

The primary outcome measure was the differences in the OSDI. The secondary outcome measures were the differences in BUT, Schirmer's I test and corneal fluorescein staining.

Statistical analysis. The data are presented as mean \pm SD and were analyzed using SPSS 17.0 software for Windows (SPSS, Inc.). The Student's t-test was used to assess the differences between the TES + SH and SH groups before and after treatment. $P < 0.05$ was considered to indicate a statistically significant difference.

Results

Patient characteristics. A total of 52 patients (104 eyes) were included in the present study. No significant differences were found between the two groups in terms of basic characteristics, including age, sex and duration of the disease (Table I; $P > 0.05$). A total of 90 eyes completed all aspects of the study, 22 patients (44 eyes) in the TES + SH group and 23 patients

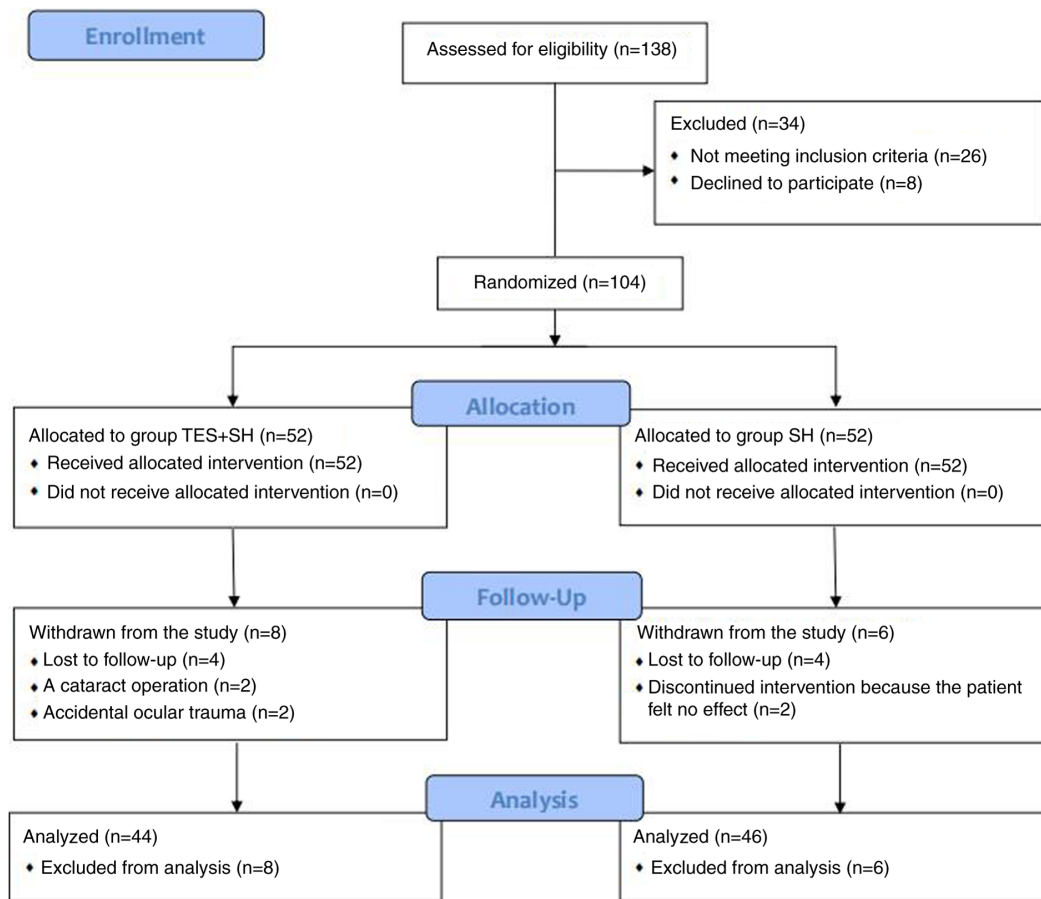


Figure 1. Flow chart of the study. TES, transcutaneous electrical stimulation; SH, sodium hyaluronate.

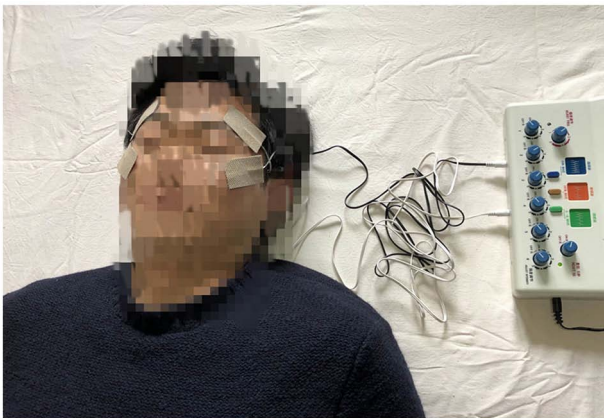

Figure 2. Patient receiving transcutaneous electrical stimulation treatment. Electrode placement was performed bilaterally. One electrode was placed over the temporal area and the second electrode was placed near the lower lid.

(46 eyes) in the SH group. The flow chart of the study is shown in Fig. 1. A total of 4 patients in the TES + SH group were withdrawn from the analysis: 2 patients (4 eyes) were lost to follow-up, 1 patient (2 eyes) underwent cataract surgery, and 1 patient (2 eyes) was withdrawn due to accidental ocular trauma. A total of 3 patients in the SH group were withdrawn from the analysis: 2 patients (4 eyes) were lost to follow-up, and 1 patient (2 eyes) discontinued treatment as she experienced no subjective improvement.

Primary outcome. With respect to the OSDI, no statistically significant difference in the OSDI was found between the TES + SH and SH groups before treatment (42.3 ± 7.6 vs. 43.2 ± 6.2 , $P=0.106$). The OSDI scores declined significantly in the two groups after treatment ($P<0.05$); a significant difference was observed between the two groups after 4 weeks (24.5 ± 4.8 vs. 31.3 ± 8.6 , $P=0.004$). The OSDI scores were markedly better in the TES + SH group compared with those in the SH group 4 weeks after treatment. The differences between the two groups are summarized in Table II.

Secondary outcome. Regarding the objective DE measures, BUT and Schirmer's I test findings did not differ between the two study groups before treatment ($P>0.05$). Significant increases in BUT and Schirmer's I test were found in the TES + SH group 4 weeks after the treatment ($P<0.05$), but not in the SH group ($P>0.05$). Significant differences in OSDI, BUT, Schirmer's I test and corneal fluorescein scores were found between the two groups 4 weeks after treatment (Table II, $P<0.05$).

No statistically significant difference in corneal fluorescein staining scores was found between the TES + SH and SH groups before treatment (3.1 ± 1.8 vs. 3.5 ± 1.9 , $P=0.385$). The scores in both groups were markedly decreased after treatment ($P<0.05$). The scores were markedly lower in the TES + SH group compared with those in the SH group 4 weeks after treatment (1.2 ± 1.0 vs. 2.5 ± 1.4 , $P=0.029$). Therefore, the TES + SH group exhibited better epithelial healing. The

Table I. Demographics and baseline characteristics of patients with dry eye.

Characteristics	TES + SH		P-value
	SH group	group	
Total no. of patients (eyes)	23 (46)	22 (44)	
Male:female ratio	10:13	9:13	0.862
Age (years)			0.497
Mean \pm SD	42.9 \pm 15.1	41.2 \pm 14.2	
Range	18-65	19-63	
Course of DE (years)			0.255
Mean \pm SD	3.9 \pm 2.7	4.2 \pm 3.4	
Range	1-10	1-12	

TES, transcutaneous electrical stimulation; SH, sodium hyaluronate; SD, standard deviation.

scores of fluorescein staining in the two groups are presented in Table II.

Adverse events. No serious adverse events were reported in either group. A total of 4 patients reported minor pain in the skin overlying the site of electrode placement. No other adverse effect was observed in all patients. No patients withdrew from the study due to adverse effects.

Discussion

The present study demonstrated that TES significantly affected subjective outcomes as well as objective measures in patients with DE. Significant improvements in OSDI, BUT, Schirmer's I test and corneal staining scores were observed in patients treated with TES + SH compared with patients treated with SH alone. No serious adverse events occurred in either group. Patients in the TES + SH group generally exhibited a reduction in symptoms and reported a high degree of overall satisfaction. The majority stated that they would recommend TES therapy to friends or family members with DE.

TES was initially described as an effective treatment for DE by Pedrotti *et al* in 2016 (18). A total of 27 patients with DE underwent TES with electrodes placed onto the periorbital region of both eyes. TES was shown to improve DE, both subjectively and objectively, without any associated adverse effects, and may prove to be of value for the treatment of DE. However, this was a pilot study with only 27 patients and no control group. During medical procedures, it was not considered practical to only treat patients with TES without artificial tears as most patients were unwilling to receive TES treatment only without eye drops. Sivanesan *et al* (7) found that the non-invasive electrical stimulation of the trigeminal nerve achieved a short-term reduction in DE-related chronic ocular pain and photophobia. The use of TENS reduced pain intensity in both eyes by a mean of 57% and decreased light sensitivity by 27-28%. However, this was also a pilot study with a small population and no control group. It only studied subjective symptoms but did not analyze objective indicators,

Table II. Changes in the outcomes of patients with dry eye before and after treatment.

Outcomes	Baseline	4 weeks	P-value
OSDI			
SH group (n=23 patients)	43.2 \pm 6.2	31.3 \pm 8.6	0.013
TES + SH group (n=22 patients)	42.3 \pm 7.6	24.5 \pm 4.8	0.000
P-value	0.106	0.004	
BUT			
SH group (n=46 eyes)	4.2 \pm 2.0	5.3 \pm 2.2	0.333
TES + SH group (n=44 eyes)	4.0 \pm 1.7	6.5 \pm 3.0	0.001
P-value	0.658	0.039	
Schirmer's I test			
SH group (n=46 eyes)	4.4 \pm 1.9	5.1 \pm 2.2	0.193
TES + SH group (n=44 eyes)	4.5 \pm 1.8	6.9 \pm 3.1	0.000
P-value	0.523	0.016	
Corneal staining			
SH group (n=46 eyes)	3.5 \pm 1.9	2.5 \pm 1.4	0.030
TES + SH group (n=44 eyes)	3.1 \pm 1.8	1.2 \pm 1.0	0.008
P-value	0.385	0.029	

TES, transcutaneous electrical stimulation; SH, sodium hyaluronate; OSDI, Ocular Surface Disease Index; BUT, tear film breakup time.

such as BUT, Schirmer's I test and corneal staining score. A prospective, open-label, non-randomized clinical trial, using neurostimulation of the nasal sensory nerves, was conducted by Friedman *et al* in 40 subjects with mild-to-severe DE (4). The results revealed a significant increase in tear production based on the difference in Schirmer's I test scores, as well as an improvement in OSDI scores, along with corneal and conjunctival staining. The authors concluded that the neurostimulation of the nasolacrimal pathway was an effective means for increasing tear production and reducing symptoms among patients with DE. More recent studies also demonstrated that intranasal tear neurostimulation exerted an effect on the aqueous, lipid and mucin components of the tears (23-26). However, several patients did not approve of intranasal tear neurostimulation due to discomfort and concerns regarding hygiene. Compared with intranasal tear neurostimulation, TES is less invasive, easy to perform and more tolerable.

Compared with previous studies, the present study had several advantages: i) TES is an easy to perform, safe, cost-effective and non-invasive procedure. Treatment is applied transcutaneously; therefore, TES is less invasive compared with surgical therapy and acupuncture, and relatively inexpensive compared with pharmaceutical therapies. ii) Previous studies were mainly pilot studies with a small population and no control group. This was a randomized controlled trial on the use of TES + SH for DE that covered the limitations of previous studies and helped determine the best approach to the management of this frequent ocular surface disease. iii) During actual clinical procedures, it is not practical to only administer TES treatment to patients without artificial tears. As a result, TES was combined with SH as the experimental group in this

study and compared with the control group using artificial tears alone to explore the effect of TES in treating DE.

The OSDI score was selected as the primary outcome of the present study, as the main goal of the treatment was to improve the symptoms of DE. The OSDI (27) is a 12-item questionnaire designed to provide a rapid assessment of the symptoms of ocular irritation consistent with DE (28). It is a standardized and validated instrument for evaluating the symptoms of the ocular surface disease and can be easily performed. A significant reduction in the OSDI scores and a more marked effect on patients treated with TES + SH were observed at the end of the treatment. The results of the present study were attributed to the application of TES.

The exact mechanisms underlying the beneficial effect of TES treatment on DE remain unclear. However, two possible hypotheses may explain the positive results obtained in the present study.

The first hypothesis is that TES can effectively stimulate the trigeminal nerve to relieve DE symptoms such as pain and photophobia (7,29); this hypothesis may account for OSDI results. Previous studies reported that the mechanism of TES for DE may be associated with the modulation of neuroanatomical pain pathways within the trigeminal system (22,30,31). TES functions by a phenomenon referred to as 'gate control theory' (32). It stimulates vibration receptors by electrical current, thereby reducing the transmission of painful stimuli to the brain (33). Moreover, it relieves pain through repeated application to an area and an increase in the secretion of endogenous endorphins (34). In addition, it is possible that TES can desensitize retinal cells directly and reduce their ability to respond to light, thereby reducing photophobia. Another possible site of action is the trigeminal-cervical complex, where the photophobia and pain pathways converge (35).

The second hypothesis may account for both the subjective and objective results. This hypothesis is that TES can produce quantum molecular resonance (QMR), stimulate the lacrimal system, and reactivate the lacrimal and meibomian gland tissue (18), thus promoting the secretion of tears and increasing the thickness of the lipid and mucin layers (36). QMR creates energy to break the molecular bonds without increasing the kinetic energy of the hit molecules, thus not increasing the temperature and limiting the damage to the surrounding tissue. It can also produce a mechanical stimulation, an electrical interaction with the cellular membrane, and a biochemical interaction that involves the internal structures of the cells. The metabolism and biochemical stimulation of cellular structures are achieved through a series of contractions and relaxations. The stimulation leads to self-renewal of tissues and improvements in structure and function. The improvements appear following applications repeated at intervals of 1 or more days. In addition, QMR may induce deformation of cell membranes and lead to a cascade of reactions at the cellular level that are capable of increasing the normal metabolism. These potential mechanisms can explain the positive effects achieved by TES in physiotherapy medicine.

The improvements in objective DE measures (BUT, Schirmer's I test and corneal fluorescein staining scores) were related to the improvements in the secretion of tears and the thickness of the lipid and mucin layers achieved by TES. The corneal fluorescein staining scores in both groups were

markedly lower after treatment, but BUT and Schirmer's I test exhibited significant improvements in the TES + SH group. This was likely due to the increase in both tear secretion and the thickness of the lipid and mucin layers in the TES + SH group. However, only SH was administered to the SH group, and the water layer was supplemented without a simultaneous improvement in the lipid and mucin layers. With the help of artificial tears, the corneal epithelium healed significantly within 4 weeks. Therefore, BUT and Schirmer's I test scores may improve significantly in the SH group over a longer study period. However, the exact underlying mechanisms require further investigation.

The basis for selecting the sites of electrode placement is the anatomical location of the trigeminal nerve and lacrimal gland. TES can effectively stimulate the trigeminal nerve to relieve DE symptoms including pain and photophobia, and produce QMR to stimulate the lacrimal system and reactivate the lacrimal and meibomian gland tissue. Whether this effect is associated with the acupuncture points of Chinese medicine is unclear.

The present study yielded promising initial results. However, there were certain limitations. First, it was only a randomized controlled trial. Conventional eye drops in clinical trials can be administered in a double-blinded manner, but this is not possible with TES. Second, this study used a single waveform and electrode location; whether these were optimal was not known. It should be possible to increase the treatment effect through further optimization of stimulation parameters and dosing interval. Third, patients in the TES + SH group used TES combined with SH therapy. We consider that the placebo effect was not significant. However, as the control group only used SH treatment, a potential placebo effect may be a limitation. Furthermore, the study was performed in only one hospital and over a short period. Therefore, a large-sample multicenter study with a long-term follow-up is required to confirm the benefits of TES for DE.

In conclusion, TES combined with artificial tears was found to be more effective in treating DE compared with artificial tears alone. Therefore, TES may represent a promising novel treatment option for DE, provided that its benefits are confirmed and mechanism of action elucidated in prospective studies using electrical stimulation for DE.

Acknowledgements

Not applicable.

Funding

No funding was received.

Availability of data and materials

All datasets generated and/or analyzed during the present study are included in this published article.

Authors' contributions

JZ was responsible for the design of the study and interpretation of the analysis results; MC undertook data analysis and

drafted the manuscript. Both authors have read and approved the final version of the manuscript.

Ethics approval and consent to participate

The present study was conducted following approval by the Ethics Committee of the Ninth People's Hospital of Chongqing. This study was registered with the Chinese Clinical Trial Registry: ChiCTR1900021036, registered on January 25, 2019.

Patient consent for publication

All the patients consented to the publication of their data and any associated images.

Competing interests

The authors declare that they have no competing interests.

References

- Craig JP, Nichols KK, Akpek EK, Caffery B, Dua HS, Joo CK, Liu Z, Nelson JD, Nichols JJ, Tsubota K and Stapleton F: TFOS DEWS II definition and classification report. *Ocul Surf* 15: 276-283, 2017.
- Merayo-Llodes J, Sanchez-Avila RM, Riestra AC, Anitua E, Begoña L, Orive G and Fernandez-Vega L: Safety and efficacy of autologous plasma rich in growth factors eye drops for the treatment of evaporative dry eye. *Ophthalmic Res* 56: 68-73, 2016.
- García-Conca V, Abad-Collado M, Hueso-Abancens JR, Mengual-Verdú E, Piñero DP, Aguirre-Balsalobre F and Molina JC: Efficacy and safety of treatment of hyposecretory dry eye with platelet-rich plasma. *Acta Ophthalmol* 97: e170-e178, 2019.
- Friedman NJ, Butron K, Robledo N, Loudin J, Baba SN and Chayet A: A nonrandomized, open-label study to evaluate the effect of nasal stimulation on tear production in subjects with dry eye disease. *Clin Ophthalmol* 10: 795-804, 2016.
- Kossler AL, Wang J, Feuer W and Tse DT: Neurostimulation of the lacrimal nerve for enhanced tear production. *Ophthalm Plast Reconstr Surg* 31: 145-151, 2015.
- Rosenthal P and Borsook D: The corneal pain system. Part I: The missing piece of the tear eye puzzle. *Ocul Surf* 10: 2-14, 2012.
- Sivanesan E, Levitt RC, Sarantopoulos CD, Patin D and Galor A: Noninvasive electrical stimulation for the treatment of chronic ocular pain and photophobia. *Neuromodulation* 21: 727-734, 2018.
- Gofeld M: New horizons in neuromodulation. *Curr Pain Headache Rep* 18: 397, 2014.
- Goroszeniuk T and Pang D: Peripheral neuromodulation: A review. *Curr Pain Headache Rep* 18: 412, 2014.
- Kacker R, Lay A and Das A: Electrical and mechanical office-based neuromodulation. *Urol Clin North Am* 40: 581-589, 2013.
- Luan S, Williams I, Nikolic K and Constandinou TG: Neuromodulation: Present and emerging methods. *Front Neuroeng* 7: 27, 2014.
- Park C, Choi JB, Lee YS, Chang HS, Shin CS, Kim S and Han DW: The effect of intra-operative transcutaneous electrical nerve stimulation on posterior neck pain following thyroidectomy. *Anaesthesia* 70: 434-439, 2015.
- Santana LS, Gallo RB, Ferreira CH, Duarte G, Quintana SM and Marcolin AC: Transcutaneous electrical nerve stimulation (TENS) reduces pain and postpones the need for pharmacological analgesia during labour: A randomised trial. *J Physiother* 62: 29-34, 2016.
- Engen DJ, Carns PE, Allen MS, Bauer BA, Loehrer LL, Cha SS, Chartrand CM, Egger EJ, Cutshall SM and Wahner-Roedler DL: Evaluating efficacy and feasibility of transcutaneous electrical nerve stimulation for postoperative pain after video-assisted thoracoscopic surgery: A randomized pilot trial. *Complement Ther Clin Pract* 23: 141-148, 2016.
- Rakel BA, Zimmerman MB, Geasland K, Embree J, Clark CR, Noiseux NO, Callaghan JJ, Herr K, Walsh D and Sluka KA: Transcutaneous electrical nerve stimulation for the control of pain during rehabilitation after total knee arthroplasty: A randomized, blinded, placebo-controlled trial. *Pain* 155: 2599-2611, 2014.
- Whitacre MM: The effect of transcutaneous electrical nerve stimulation on ocular pain. *Ophthalmic Surg* 22: 462-466, 1991.
- Ghaffariyeh A, Peyman A, Puyan S, Honarpisheh N, Bagheri B and Peyman M: Evaluation of transcutaneous electrical stimulation to improve recovery from corneal hypoesthesia after LASIK. *Graefes Arch Clin Exp Ophthalmol* 247: 1133-1138, 2009.
- Pedrotti E, Bosello F, Fasolo A, Frigo AC, Marchesoni I, Ruggeri A and Marchini G: Transcutaneous periorbital electrical stimulation in the treatment of dry eye. *Br J Ophthalmol* 101: 814-819, 2017.
- Pall ML: Electromagnetic fields act via activation of voltage-gated calcium channels to produce beneficial or adverse effects. *J Cell Mol Med* 17: 958-965, 2013.
- Amparo F, Schaumberg DA and Dana R: Comparison of two questionnaires for dry eye symptom assessment: The ocular surface disease index and the symptom assessment in dry eye. *Ophthalmology* 122: 1498-1503, 2015.
- Lemp MA: Report of the national eye institute/industry workshop on clinical trials in dry eyes. *CLAO J* 21: 221-232, 1995.
- Sook Chun Y and Park IK: Reliability of 4 clinical grading systems for corneal staining. *Am J Ophthalmol* 157: 1097-1102, 2014.
- Cohn GS, Corbett D, Tenen A, Coroneo M, McAlister J, Craig JP, Gray T, Kent D, Murray N, Petsoglou C, *et al*: Randomized, controlled, double-masked, multicenter, pilot study evaluating safety and efficacy of intranasal neurostimulation for dry eye disease. *Invest Ophthalmol Vis Sci* 60: 147-153, 2019.
- Gumus K and Pflugfelder SC: Intranasal tear neurostimulation: an emerging concept in the treatment of dry eye. *Int Ophthalmol Clin* 57: 101-108, 2017.
- Pattar GR, Jerkins G, Evans DG, Torkildsen GL, Ousle GW, Hollander DA, Holdbrook M and Senchyna M: Symptom improvement in dry eye subjects following intranasal tear neurostimulation: Results of two studies utilizing a controlled adverse environment. *Ocul Surf* 18: 249-257, 2020.
- Farhangi M, Cheng AM, Baksh B, Sarantopoulos CD, Felix ER, Levitt RC and Galor A: Effect of non-invasive intranasal neurostimulation on tear volume, dryness and ocular pain. *Br J Ophthalmol* 104: 1310-1316, 2020.
- Ozcura F, Aydin S and Helvacı MR: Ocular surface disease index for the diagnosis of dry eye syndrome. *Ocul Immunol Inflamm* 15: 389-393, 2007.
- Schiffman RM, Christianson MD, Jacobsen G, Hirsch JD and Reis BL: Reliability and validity of the ocular surface disease index. *Arch Ophthalmol* 118: 615-621, 2000.
- Chiou YF, Yeh ML and Wang YJ: Transcutaneous electrical nerve stimulation on acupuncture points improves myofascial pain, moods, and sleep quality. *Rehabil Nurs* 45: 225-233, 2020.
- Galor A, Levitt RC, Felix ER, Martin ER and Sarantopoulos CD: Neuropathic ocular pain: An important yet undervalued feature of dry eye. *Eye (Lond)* 29: 301-312, 2015.
- Ainsworth L, Budelier K, Clinesmith M, Fiedler A, Landstrom R, Leeper BJ, Moeller L, Mutch S, O'Dell K, Ross J, *et al*: Transcutaneous electrical nerve stimulation (TENS) reduces chronic hyperalgesia induced by muscle inflammation. *Pain* 120: 182-187, 2006.
- Grover CA, McKernan MP and Close RJH: Transcutaneous Electrical Nerve Stimulation (TENS) in the emergency department for painrelief: A preliminary study of feasibility and efficacy. *West J Emerg Med* 19: 872-876, 2018.
- Gozani SN: Fixed site high-frequency transcutaneous electrical nerve stimulation for treatment of chronic low back and lower extremity pain. *J Pain Res* 9: 469-479, 2016.
- Zhu Y, Feng Y and Peng L: Effect of transcutaneous electrical nerve stimulation for pain control after total knee arthroplasty: A systematic review and meta analysis. *J Rehabil Med* 49: 700-704, 2017.
- Garrison DW and Foreman RD: Decreased activity of spontaneous and noxiously evoked dorsal horn cells during transcutaneous electrical nerve stimulation (TENS). *Pain* 58: 309-315, 1994.
- Dieckmann G, Fregni F and Hamrah P: Neurostimulation in dry eye disease-past, present, and future. *Ocul Surf* 17: 20-27, 2019.



This work is licensed under a Creative Commons Attribution-NonCommercial-NoDerivatives 4.0 International (CC BY-NC-ND 4.0) License.