

Surgical management of an erupted complex odontoma occupying maxillary sinus

Access this article online

Website:

www.amsjournal.com

DOI:

10.4103/2231-0746.95333

Quick Response Code:



K. V. Arunkumar, Vijaykumar, Nitin Garg

Department of Oral and Maxillofacial Surgery, Subharti Dental College and Hospital, Meerut, Uttar Pradesh, India

Address for correspondence:

Dr. K. V. Arunkumar, Department of Oral and Maxillofacial Surgery, Subharti Dental College and Hospital, NH-58, Delhi-Meerut-Haridwar Bypass Road, Meerut, Uttar Pradesh – 250 005, India.
E-mail: arunkumarkv@yahoo.com

ABSTRACT

The occurrence of complex odontomas is not considered to be rare in the jaws. But the occurrence of large odontomas obscuring the maxillary sinus, or erupting into the oral cavity are considered to be rare. The prognosis is good with surgical excision and recurrence is nil. Most of the times the surgical site can be closed primarily, but sometimes requires local flaps to achieve tension free closure. Here, we report such a case treated by surgical excision trans orally followed soft tissue defect reconstruction with pedicled palatal island flap.

Keywords: Complex odontoma, maxillary sinus, odontomas, palatal flap

INTRODUCTION

Odontomas are best known as hamartomatous benign tumors rather than true neoplasms, arising from odontogenic tissues. Histologically, they are classified as compound and complex variety.^[1] The tissues in compound odontoma appear to be arranged orderly containing rudimentary tooth-like structures having enamel, dentin, cementum and pulp whereas, the complex odontoma is a mass of disorganized dental tissues. Clinically they are classified as intraosseous (central), peripheral (soft tissue or extra-osseous) and erupted odontomas.^[2] The central (intraosseous) odontomas are common representing 51%, occurring in anterior maxilla (compound odontoma) followed by mandibular molar region (complex odontoma).^[3] Peripheral odontoma are rare and occur in the soft tissue over the tooth-bearing zone and most reported ones are of compound variety.^[4] The erupted odontoma are the one which are present coronal to an erupting or impacted tooth or superficially in bone and may have enabled its eruption into the oral cavity.^[5]

Here, we present the surgical management of a case of complex odontoma erupted intraorally, occupying 2/3rd of maxillary sinus, symptomatic by causing pain, foul smell and occasional nasal discharge.

CASE REPORT

A 22-year-old male patient presented with history of pain and swelling in the left cheek region since 6 months, with nasal obstruction, occasional purulent discharge from left nostril associated with foul smell and reported several episodes of oral bleeding. On examination, a diffuse swelling [Figure 1a] in the left cheek measuring approximately 3X4cm, hard in consistency, immobile with neurosensory deficits. Intraorally, a yellowish white hard mass [Figure 1b] was seen in the region of clinically missing maxillary left first and second molar teeth with palatal as well as buccal expansion obliterating the buccal vestibule. The mucosa around was apparently inflamed with evidence of discharge and bleeding. Left submandibular lymph nodes were palpable, two in number, oval shape (0.5x1 cm), soft, mobile and nontender. Except for partial deafness in the left ear, patient had no significant personal or family history.

Routine conventional radiographs and CT scans were obtained [Figures 2a and 2b]. A 4x3.5-cm irregular radiopaque mass (cotton wool-like appearance) occupied the left posterior maxilla and extended into 2/3rd of maxillary sinus. The first and second molar were impacted, one lying at the orbital floor and other high in the tuberosity region. A provisional diagnosis of odontoma

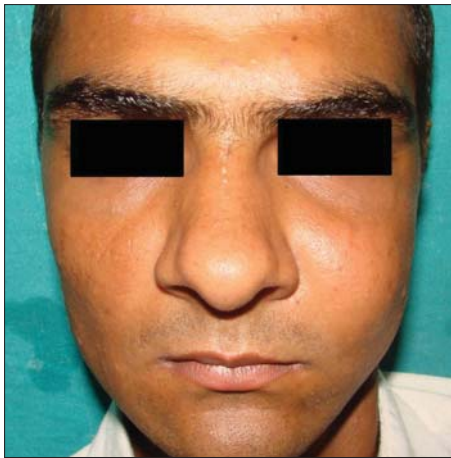


Figure 1(a): Diffuse swelling in the left cheek

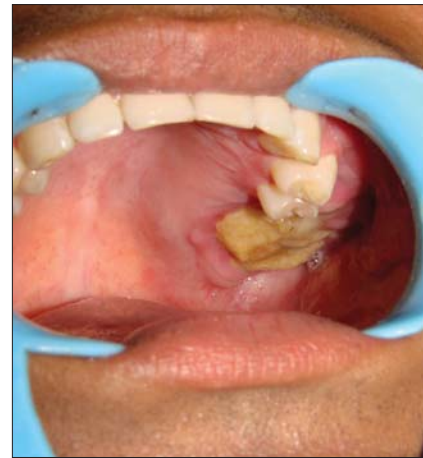

Figure 1(b): Erupted odontoma in place of the molar teeth

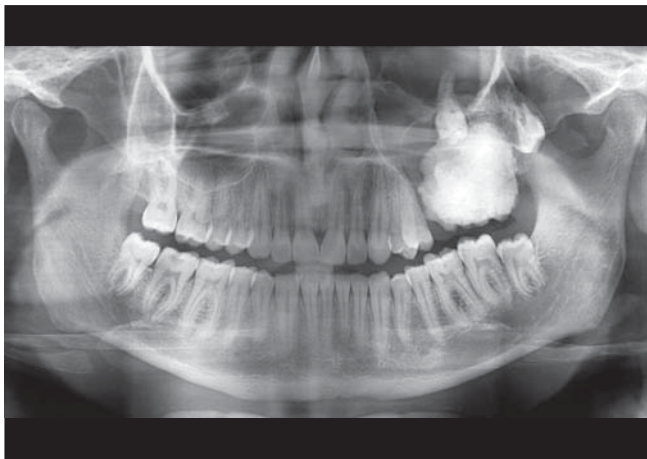


Figure 2(a): Pre-operative orthopantomogram with radiopaque mass in sinus and impacted maxillary first and second molar

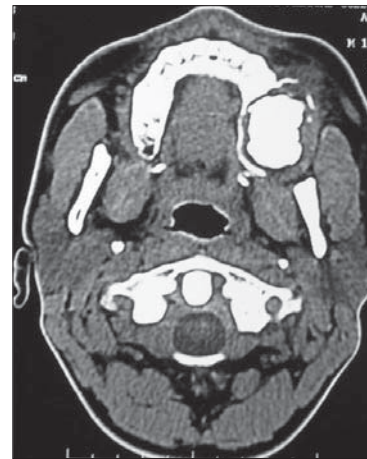

Figure 2(b): CT-Axial view showing hyperdense mass with surrounding hypodense halo around the mass

was made. The mass was excised intraorally in piecemeal due to its size [Figure 3a]. The teeth were deep inside and an attempt to retrieve them caused severe pain and discomfort to the patient under local anesthesia. Therefore, the wound was closed with the help of collagen sheet supported with an acrylic palatal plate. The collagen sheet failed to aid in healing of the defect, resulting in wound dehiscence [Figure 4a]. Two weeks later a palatal island flap was designed and rotated over the dehiscence and closed primarily without tension. Wound healed completely without any postoperative complications [Figure 4b]. Histopathologically [Figure 3b] the decalcified section showed haphazard arrangement of dentin and cementum with numerous pulp spaces confirming the diagnosis as complex odontoma. Six months after the surgery the patient was free of symptoms and no postoperative complications were evident. The patient is under follow-up to assess the fate of the impacted teeth [Figure 3c] as there is evidence of them erupting once the odontoma is removed. Patient has been rehabilitated with a removable partial denture replacing the first and second molar (4c) to facilitate masticatory function and also to prevent supraeruption of opposing lower molar teeth.

DISCUSSION

The etiology of odontoma is not known but environmental causes such as infection, trauma, family history and genetic mutation are hypothesized.^[6] The complex odontoma constitute 5-30% of all odontogenic tumors and are mostly found in the posterior mandible and anterior maxilla. They are seen with unerupted teeth in 10-44% and about 17% of them are associated with impacted maxillary lateral incisors. Females are affected marginally more than male (1.5:1). Majority of cases (84%) are seen below 30 years but are seen in any age group with peak incidence in second decade. Less than 10% are found in patients above 40 years of age.^[7-9]

H.M. Worth in 1937 classified odontomas as: a) epithelial odontomas arising from dental epithelium, e.g., dentigerous cyst, adamantinoma. b) composite odontomas arising from the dental epithelium and dental mesoblastic tissues, e.g., complex, compound, geminated and dilated.^[10] Thoma and Goldman in 1946, gave a classification as: a) Geminated composite odontomas: nearly well-developed fused teeth. b) Compound composite odontomas: made up rudimentary teeth. c) Complex composite odontomas: calcified structures not resembling normal

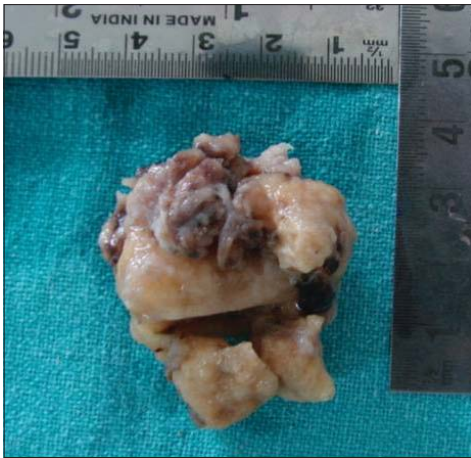

Figure 3(a): Excised specimen measuring 3x4 cm

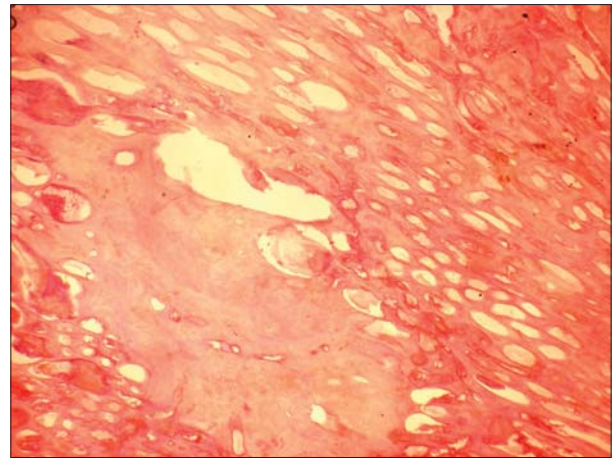


Figure 3(b): Haphazard arrangement of dentin and cementum with numerous pulp spaces

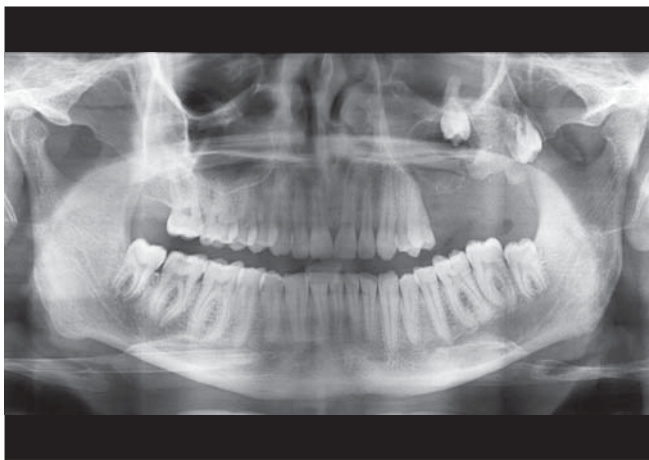


Figure 3(c): Post-op OPG with impacted teeth expected to erupt over a period of time

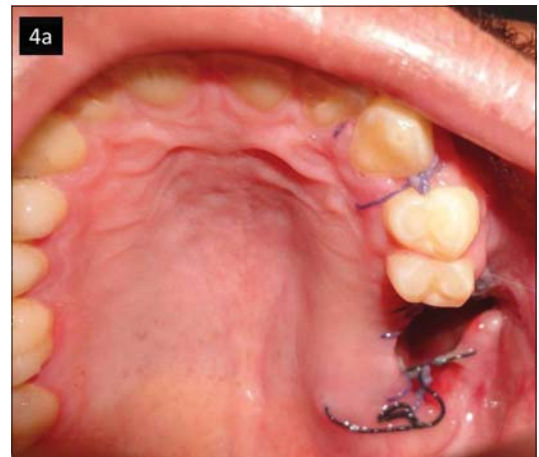


Figure 4(a): Wound dehiscence due to breakdown of collagen sheet

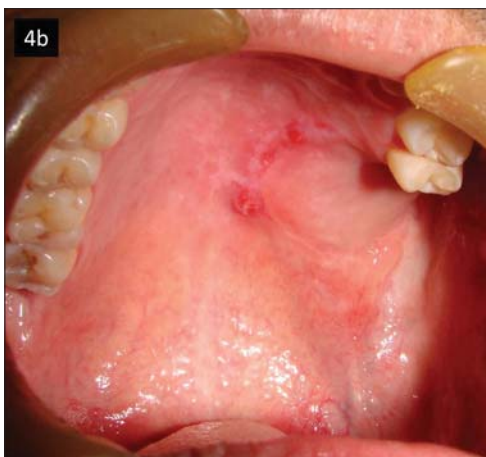

Figure 4(b): Palatal Island flap healing after 3 weeks

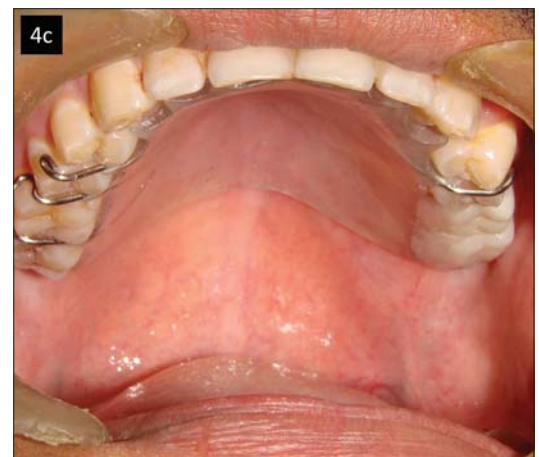


Figure 4(c): Removal prosthesis replacing first and second molar

anatomical arrangement of dental tissues. d) Dilated odontomas: enlarged crown or root portion of tooth. e) Cystic odontomas: odontoma encapsulated by fibrous connective tissue in a cyst or in the wall of a cyst.^[11]

Odontomas are also classified as intraosseous and extraosseous odontomas. The intraosseous odontomas occur inside the bone and may erupt into the oral cavity (erupted odontome). The extraosseous or peripheral odontomas are odontomas occurring

in the soft tissue covering the tooth-bearing portions of the jaws and having a tendency to exfoliate.^[12,13]

World Health Organization (WHO) classified odontomas into three groups: a) Complex odontoma; when the calcified dental tissues are simply arranged in an irregular mass bearing no morphological similarity to rudimentary teeth. b) Compound odontoma: composed of all odontogenic tissues in an orderly pattern, which result in many teeth-like structures, but without morphological resemblance to normal teeth. c) Ameloblastic fibro-odontome: consists of varying amounts of calcified dental tissue and dental papilla-like tissue, the later component resembling an ameloblastic fibroma. The ameloblastic fibro-odontome is considered as an immature precursor of complex odontoma. A new variant called as hybrid odontomas are quoted in few published literatures.^[14]

Odontomas are incidental findings on routine radiographs. Retention of deciduous teeth, unerupted permanent teeth, cortical expansion and teeth displacement are all indicators for a possible odontomas.^[7] They are symptomatic with expansion, local and/or radiating pain and neurosensory deficit when secondarily infected.^[15] The differential diagnosis of complex odontoma include cementifying or ossifying fibroma, adenomatoid odontogenic tumor, calcifying odontogenic cysts, periapical cemental dysplasia and calcifying epithelial odontogenic tumor.

Although the odontomas erupting in the oral cavity is controversial, the reason is attributed to the eruptive forces of the apparently impacted teeth and in cases of absence of teeth, the reasons could possibly be the resorption of alveolar ridge exposing the odontoma, sequestration of overlying bone, alveolar bone remodeling in young adults, reactive growth of the capsule surrounding odontoma in elderly patients. Odontomas have been associated with trauma during primary dentition as well as with inflammatory and infectious processes, hereditary anomalies (multiple odontomas in Gardner syndrome, Hermann's syndrome), odontoblastic hyperactivity and alterations in the genetic components responsible for controlling dental development.^[5,8]

Association of this lesion with the unerupted tooth is high and three quarters of impacted teeth related to odontomas can erupt after removal of the odontoma.^[16] Another reason for removing odontomas is their association with cysts in a significant number of cases (27.6%). Looking at the association of these lesions and the potential complications associated with the cyst, odontomas should be properly evaluated and removed completely in case of any suspicion of cystic transformation.^[17] In cases where smaller segments are left behind, they do not tend to grow or get infected postoperatively.^[18] Excision of larger erupted odontoma may cause problem to achieve primary closure and may require additional soft tissues for wound closure. The most common options are palatal rotation flap, buccal mucosal flaps, pedicled buccal fat pad graft or tongue flap.

CONCLUSIONS

Odontomas are common benign odontogenic pathologies

that are accidentally discovered on routine radiography when asymptomatic. But can be a cause of concern when they grow to attain unusual dimensions, displacing and preventing eruption of teeth, cystic transformation. When they occur in the maxilla with sinuses present can go unnoticed till they attain bigger size leading to functional problems. A routine periodic check-up along with conventional radiographs should be mandatory for early detection of benign asymptomatic bone tumors and treat to avoid future complications.

REFERENCES

1. Kramer IR, Pindborg JJ, Shear M. Histological typing of odontogenic tumors. WHO International histological classification of tumors. Berlin: Springer-Verlag; 1992. p. 21.
2. Philipsen HP, Reichart PA, Praetorius F. Mixed odontogenic tumors and odontomas. Considerations on interrelationship. Review of the literature and presentation of 134 new cases of odontomas. *Oral Oncol* 1997;33:86-99.
3. Daley TD, Wysoki GP, Pringle GA. Relative incidence of odontogenic tumors and oral jaw cyst in a Canadian population. *Oral Surg Oral Med Oral Pathol* 1994;77:276-80.
4. Ide F, Shimoyama T, Horie N. Gingival peripheral odontoma in an adult: Case report. *J Periodontol* 2000;71:830-2.
5. Ragalli CC, Ferreria JL, Blasco L. Large erupting complex odontoma. *Int J Oral Maxillofac Surg* 2000;29:373-4.
6. Mupparapu M, Singer SR, Rinaggio J. Complex odontoma of unusual size involving the maxillary sinus: Report of a case and review of CT and histopathologic features. *Quintessence Int (Berl)* 2004;35:641-5.
7. Reichart PA, Philipsen HP. Complex odontoma, odontogenic tumors and allied lesions. New Delhi: Quintessence Publishing Co.; 2005. p. 141-7.
8. Vengal M, Arora H, Ghosh S, Pai KM. Large erupting complex odontoma: A case report. *J Can Dent Assoc* 2007;73:169-73.
9. Chang JY, Wang YP, Liu BY, Sun A, Chiang CP. Odontoma: A clinicopathologic study of 81 cases. *J Formos Med Assoc* 2003;102:876-82.
10. Worth HM. Tumours of the jaw. *Br J Radiol* 1937;10:223-36.
11. Thoma KH, Goldman HM. Odontogenic tumors- A classification based on observation of the epithelial, mesenchymal, and mixed varieties. *Am J Pathol* 1946;22:433-71.
12. Das UM, Nagarathna, Arathi. Unerupted maxillary primary canine associated with compound composite odontoma. A case report. *J Indian Soc Pedod Prev Dent* 2002;20:98-101.
13. Singh S, Singh M, Singh I, Khandelwal D. Compound composite odontoma associated with an unerupted deciduous incisor- A rarity. *J Indian Soc Pedod Prev Dent* 2005;23:146-50.
14. Phillips MD, Closmann JJ, Baus MR, Torske KR, Williams SB. Hybrid odontogenic tumor with features of ameloblastic fibro-odontoma, calcifying odontogenic cyst, and adenomatoid odontogenic tumor: A case report and review of the literature. *J Oral Maxillofac Surg* 2010;68:470-4.
15. Tüzüm MS. Orofacial pain associated with an infected complex odontoma case report. *Aust Dent J* 1990;35:352-4.
16. Morning P. Impacted teeth in relation to odontomas. *Int J Oral Surg* 1980;9:81-91.
17. Wanjari SP, Tekade SA, Parwani RN, Managutti SA. Dentigerous cyst associated with multiple complex composite odontomas. *Contemp Clin Dent* 2011;2:215-7.
18. Marx RE, Stern D. Odontogenic tumors [14]; Oral and maxillofacial pathology. Quintessence; 2003. p. 678-9.

Cite this article as: Arunkumar KV, V, Garg N. Surgical management of an erupted complex odontoma occupying maxillary sinus. *Ann Maxillofac Surg* 2012;2:86-9.

Source of Support: Nil, **Conflict of Interest:** None declared.