



# Application of Supercharge End-to-Side (SETS) Obturator to Femoral Nerve Transfer in Electrical Injury-Induced Neuropathy to Improve Knee Extension

Katie Pei-Hsuan Wu, MD<sup>1,\*</sup> Li-Ching Lin, MD<sup>2,\*</sup> Johnny Chuieng-Yi Lu, MD, MS<sup>2</sup>

<sup>1</sup> Department of Physical Medicine and Rehabilitation, Chang Gung Medical University, Chang Gung Memorial Hospital-Linkou, Taoyuan, Taiwan

<sup>2</sup> Division of Reconstructive Microsurgery, Department of Plastic and Reconstructive Surgery, Chang Gung Medical University, Chang Gung Memorial Hospital, Linkou, Taiwan

Address for correspondence Johnny Chuieng-Yi Lu, MD, MS, Division of Reconstructive Microsurgery, Department of Plastic and Reconstructive Surgery, Chang Gung University, Chang Gung Memorial Hospital, 5 Fu-Hsing Street, Kuei-Shan, Taoyuan 333, Taiwan (e-mail: cylvu122@gmail.com).

Arch Plast Surg 2022;49:769–772.

## Abstract

Femoral nerve injuries are devastating injuries that lead to paralysis of the quadriceps muscles, weakening knee extension to prohibit ambulation. We report a devastating case of electrical injury-induced femoral neuropathy, where no apparent site of nerve disruption can be identified, thus inhibiting the traditional choices of nerve reconstruction such as nerve repair, grafting, or transfer. Concomitant spinal cord injury resulted in spastic myopathy of the antagonist muscles that further restricted knee extension. Our strategy was to perform (1) supercharge end-to-side technique (SETS) to augment the function of target muscles and (2) fractional tendon lengthening to release the spastic muscles. Dramatic postoperative improvement in passive and active range of motion highlights the effectiveness of this strategy to manage partial femoral nerve injuries.

## Keywords

- ▶ supercharge
- ▶ femoral nerve
- ▶ end to side nerve transfer
- ▶ obturator to femoral nerve
- ▶ electrical injury

## Introduction

Electrical injury could lead to multisystemic injury,<sup>1</sup> with high physical and psychological impact. The current could destruct soft tissue (skin, muscle, and bone) via direct electrical and thermal energy.<sup>2</sup> Neurological impairments leading to permanent central and peripheral neuropathy were not unusual.<sup>2</sup> We report a case of chronic bilateral femoral nerve injury presenting at 5 years after a high-

voltage electric current passed through the patient's spinal cord and exited at bilateral thighs. Impairment of the quadriceps led to significant disability requiring the use of assisting devices for ambulation.<sup>3,4</sup> This case was complicated by three main issues: (1) a poorly distinguished nerve injury site with atrophied vastus muscles, and (2) spinal cord injury-induced spastic contracture of the posterior thigh muscles.<sup>5</sup> We performed supercharge end-to-side (SETS) technique to a partially injured femoral nerve to augment knee extension. Significant improvement postoperatively warranted the future application in similar cases.

\* The first two authors contributed equally to the article.

received  
December 8, 2021  
accepted after revision  
February 17, 2022

DOI <https://doi.org/10.1055/s-0042-1756290>.  
eISSN 2234-6171.

© 2022. The Korean Society of Plastic and Reconstructive Surgeons. All rights reserved.

This is an open access article published by Thieme under the terms of the Creative Commons Attribution-NonDerivative-NonCommercial-License, permitting copying and reproduction so long as the original work is given appropriate credit. Contents may not be used for commercial purposes, or adapted, remixed, transformed or built upon. (<https://creativecommons.org/licenses/by-nc-nd/4.0/>)

Thieme Medical Publishers, Inc., 333 Seventh Avenue, 18th Floor, New York, NY 10001, USA

## Idea

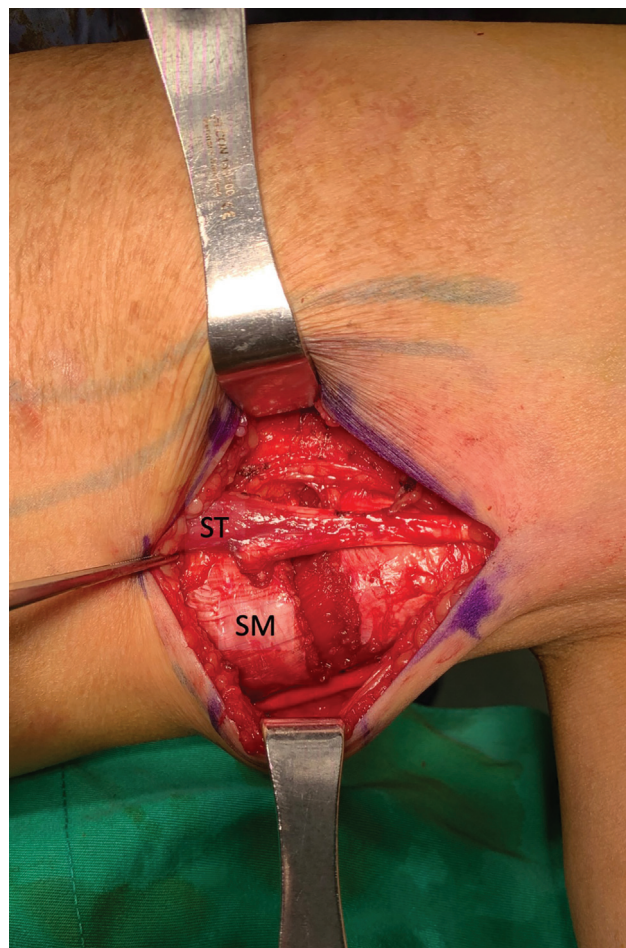
A 55-year-old male patient endured a 11,000V electrical injury due to inadvertent contact with electric pole and fallen from a height of four floors that resulted in left pelvic nondisplaced fracture and minimal intracranial hemorrhage. The electric entry point was the left forearm, and it exited from his left lateral and right medial thigh; both of the wounds were treated with skin grafts for coverage. Left median nerve palsy was subsequently treated with opponoplasty procedure which improved his functional grip. Weakness of bilateral hip flexion and knee extension compounded by spastic contractures in the posterior thigh muscle impaired his ambulation and rehabilitation efficacy. Even after intense rehabilitation for years, maximum left knee extension was M2+, with active range of motion (AROM) of 0 to 40°, and passive range of motion (PROM) of 0 to 50°. He was referred to the peripheral nerve surgeon (J. C.-Y.L.) at 5 years after the initial injury. The rectus femoris was palpable during contraction but vastus lateralis (VL) and vastus medialis (VM) muscles were both atrophied (► **Video 1**). Right knee extension was also M2+, but again with limiting AROM of 0 to 50° and PROM of 0 to 60°. Spastic contracture of bilateral semitendinosus (ST) and semimembranosus (SM) muscles near the tenomuscular junction could be palpated on posterior thigh. Electrodiagnostic studies revealed decreased amplitude and nerve conduction velocity in the left femoral nerve, and decreased recruitment in the left VM and VL muscles with 2+ positive fibrillation waves. The preoperative impression was (1) partial injury of the left femoral nerve with nerve in continuity due to direct electrical burn and (2) spastic myopathy of bilateral posterior thigh muscles resulting from incomplete spinal cord injury. Our plan was to perform SETS obturator nerve transfer to selected branches of the left femoral nerve and fractional tendon lengthening of ST and SM muscles on both posterior thighs.

### Video 1

Preoperative video showed severe restriction in extension of both knees. Online content including video sequences viewable at: <https://www.thieme-connect.com/products/ejournals/html/10.1055/s-0042-1756290>.

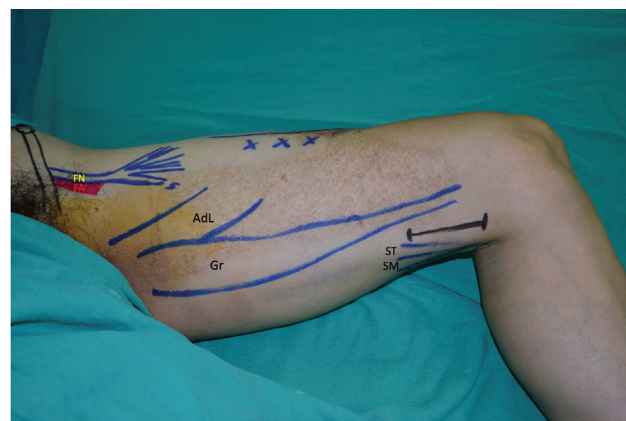For the lower limb, the patient was placed in supine position with the leg in frog leg position. A medial longitudinal incision was placed over the distal posteromedial thigh where the ST and SM tendons were located (► **Fig. 1**). Fractional tendon lengthening was performed by tenotomy at the tenomuscular junction but still preserving the underlying muscles. Once completed, the knees were able to extend fully passively.

The first step for nerve transfer was to identify the femoral canal by femoral artery pulsation. A longitudinal incision was

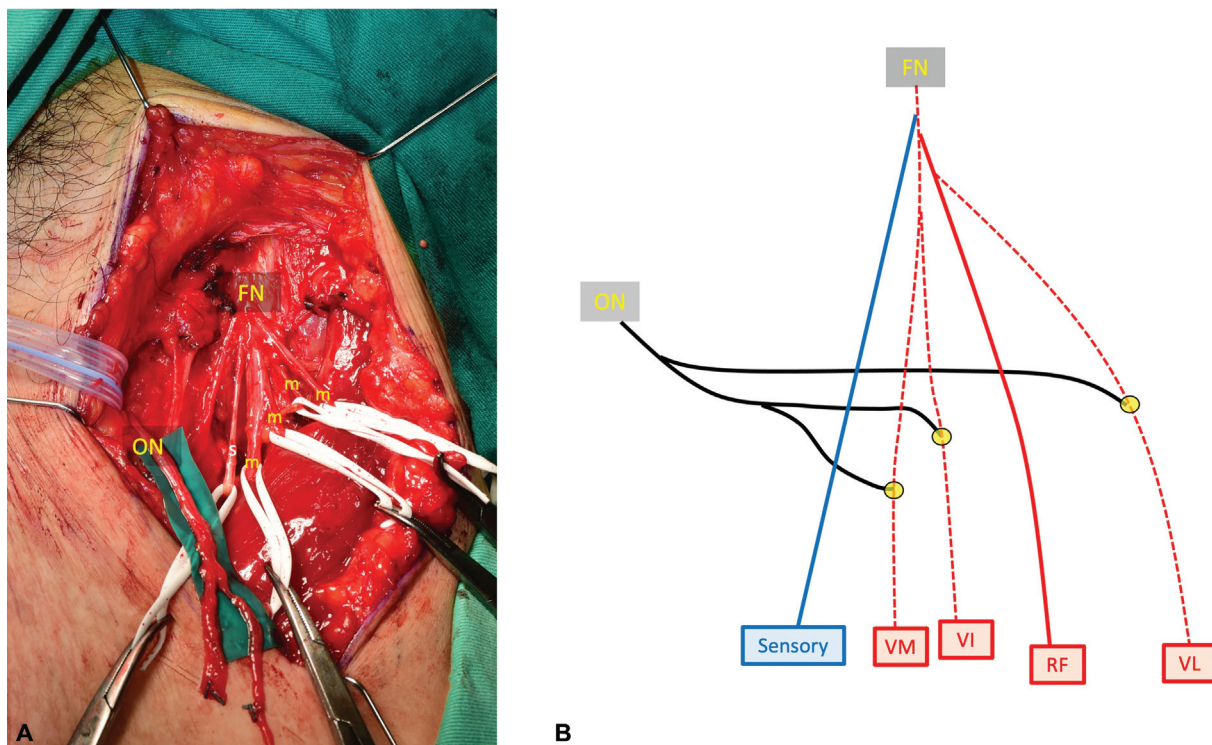


**Fig. 1** Fractional tendon lengthening was performed on the semitendinosus (ST) and semimembranosus (SM) tendons.

made over the femoral canal from below the inguinal crease to the sartorius muscle. The sartorius was retracted laterally to expose the neurovascular bundle, where the femoral nerve lied lateral to the artery (► **Fig. 2**). The nerve trifurcated into (1) medial sensory branch, (2) motor branches into VM and



**Fig. 2** Femoral nerve (FN) was identified lateral to the femoral artery (FA) in the femoral canal, beneath the inguinal ligament and with the sartorius retracted. The obturator nerve was best identified between the gracilis (Gr) and adductor longus (AdL) muscle. The incisions for the semitendinosus (ST) and semimembranosus (SM) tendons were made more distally posterior to the gracilis tendon.



**Fig. 3** (A) The donor obturator nerve (ON) was mobilized to the anterior incision where the recipient femoral nerve lies (FN). The targets were the motor branches (m), with exclusion of the most medial, sensory branch. (B) Separate branches of the obturator nerve (ON) were coapted to the branches of the vastus medialis (VM), intermedialis (VI), and lateralis (VL) in end-to-side fashion. The sensory branch and the rectus femoris (RF) branch of the femoral nerve (FN) were protected. Note: This figure is an original diagram drawn by the authors not published elsewhere.

vastus intermedius (VI), and (3) motor branches into rectus femoris and VL, as previously described by Tung et al.<sup>4</sup> Neurolysis was performed to separate the different branches to check for individual response to electrical stimulation, where only the rectus femoris branch elicited visible contraction. A second incision was made in the medial thigh to expose the plane between the gracilis and adductor longus muscle (► Fig. 2). The neurovascular bundle of the gracilis muscle was identified, and then traced distally into the muscle to increase length of the donor nerve. The purpose is to harvest multiple branches as donors to supercharge various locations on the recipient femoral nerve. The donor nerve was then mobilized underneath the adductor longus to the medial side and then tunneled subcutaneously to the anterior thigh incision (► Fig. 3A). Individual branches of the obturator nerve were then coapted to the branches of the VM, VI, and VL at 3 cm below the trifurcation in SETS fashion (► Fig. 3B). Epineurial Windows up to 2 to 3 mm were created in the recipient nerves to allow adequate sprouting from the donor fascicles into the target axons. The wounds were then closed and knee splinted in full extension for 3 weeks.

At 1 year after surgery, left knee showed M3+ extension, with AROM improving significantly to 80° (from 40°). The left VL and medialis muscle could be visibly seen contracting against gravity (► Video 2) Right knee showed M3 extension with AROM improving to 70° (from 50°). Gait efficiency and stability improved significantly with newly acquired knee extension movement. The patient subjectively reported that

there was more improvement with the left limb than the right limb. Informed consent was given by the patient for publication and sharing of the preoperative and postoperative videos.

#### Video 2

Postoperative video at 1 year after the surgery: increased bulk of the left vastus lateralis and medialis muscles with visible improvement in the active range of motion of the left knee. Online content including video sequences viewable at: <https://www.thieme-connect.com/products/ejournals/html/10.1055/s-0042-1756290>.

#### Discussion

Electricity entered via an entry point, commonly the hand, and exited via a blow out point searching for a grounding source.<sup>2</sup> Our patient showed blow out wounds in both thighs, in particular the left lateral thigh resulting in a large open wound, which indicated that his quadriceps muscle suffered both direct skin thermal burn, muscle trauma, and indirect nerve electrocuting injuries. The path of the electrical current followed the path of least resistance, with nerves and blood vessels having lower resistance compared with bone

and fat. The disproportionate neurological sequelae may have derived from the following mechanisms: (1) thermal burn on the nerve leading to demyelination and microvascular thrombosis,<sup>6</sup> (2) entrapment neuropathy of the major peripheral nerves due to swelling of the inflamed neural tissue, and (3) aberrant regeneration within the nerve leading to synkinetic movement of the antagonistic muscles. Understanding the mechanism of injuries was fundamental to providing the correct treatment for this patient.

The primary concern in this patient was the limited knee extension in both legs that affected his ambulation and stance. Visible contractions of the left rectus femoris muscle with atrophied VL and VM affecting the AROM indicated a partially injured femoral nerve. Anatomically, the femoral nerve is the largest branch of the lumbar plexus and innervates the quadriceps muscle group (including rectus femoris, VL, medialis, and intermedius), which plays a great role in ambulation via knee extension. In lower extremity palsies, tendon transfers are rarely an option for weak knee extension. Nerve grafting is not suitable since there is no proximal stump. Nerve transfer which was used when the motor units in the target muscle were still responsive to incoming signals as in spinal cord injuries,<sup>7</sup> is an appropriate treatment to improve the quadriceps power when the lower motor neuron is still intact.

Traditional nerve transfer involves coaptation of the proximal stump of a normal donor nerve to the distal end of an injured nerve. Its use for completely transected femoral nerve injuries has been published in case reports with success.<sup>3,4</sup> We modified the traditional end-to-end transfer into the SETS technique (otherwise known as the reverse end to side)<sup>8</sup> for a partially injured femoral nerve. Even though the VM, VI, and VL branches elicited minimal response to intraoperative electrical stimulation, we opted to perform SETS instead of end-to-end coaptation since the proximal femoral nerve is still in continuity. The aim was to introduce more axons into the target muscles while preserving the original pathway.<sup>9,10</sup> In dividing the donor nerve into multiple fascicles and selecting the denervated branches as the sites of SETS, we could selectively reinnervate different muscles of the same nerve. The donor nerve was an expendable nerve that easily reaches the recipient nerve through intramuscular dissection into the gracilis muscle. Donor site morbidity was negligible and the patient was instructed to perform synchronous thigh adduction to activate the knee extension.

In conclusion, the management of combined femoral nerve and spinal cord injuries following electric injury is multifactorial and challenging. Reinnervating a partially injured nerve via the SETS technique has promising advantages over conservative rehabilitation or tendon transfers while also minimizing donor side morbidities. We believe such strategy can be applied in larger series of patients with similar presentations to enhance patient's quality of life.

#### Note

All figures provided in this manuscript are original diagrams drawn by the authors and not published elsewhere.

#### Patient Consent

The patient has granted written consent for use of their photos and video for publication.

#### Authors' Contributions

Wu K.P.H. revised and completed the entire manuscript. Also involved in further edits and revisions.

Lin L.C. reviewed the patient profile and provided the first draft. Lu J.C.Y. provided the case and provided the final edits as the corresponding author.

#### Ethical Approval

This publication was approved by the Institutional Review Board at the Chang Gung Medical Foundation under the file number 202100759B0.

#### Conflict of Interest

None declared.

#### References

- 1 Koumbourlis AC. Electrical injuries. *Crit Care Med* 2002;30(suppl 11):S424–S430
- 2 Duff K, McCaffrey RJ. Electrical injury and lightning injury: a review of their mechanisms and neuropsychological, psychiatric, and neurological sequelae. *Neuropsychol Rev* 2001;11(02):101–116
- 3 Campbell AA, Eckhauser FE, Belzberg A, Campbell JN. Obturator nerve transfer as an option for femoral nerve repair: case report. *Neurosurgery* 2010;66(suppl operative 6):375, discussion 375
- 4 Tung TH, Chao A, Moore AM. Obturator nerve transfer for femoral nerve reconstruction: anatomic study and clinical application. *Plast Reconstr Surg* 2012;130(05):1066–1074
- 5 Fleuren JF, Voerman GE, Snoek GJ, Nene AV, Rietman JS, Hermens HJ. Perception of lower limb spasticity in patients with spinal cord injury. *Spinal Cord* 2009;47(05):396–400
- 6 Schaefer NR, Yaxley JP, O'Donohue P, Lisec C, Jeyarajan E. Electrical burn causing a unique pattern of neurological injury. *Plast Reconstr Surg Glob Open* 2015;3(04):e378
- 7 Fox IK, Novak CB, Krauss EM, et al. The use of nerve transfers to restore upper extremity function in cervical spinal cord injury. *PM R* 2018;10(11):1173–1184.e2
- 8 Isaacs J, Allen D, Chen LE, Nunley J II. Reverse end-to-side neurotization. *J Reconstr Microsurg* 2005;21(01):43–48, discussion 49–50
- 9 Farber SJ, Glaus SW, Moore AM, Hunter DA, Mackinnon SE, Johnson PJ. Supercharge nerve transfer to enhance motor recovery: a laboratory study. *J Hand Surg Am* 2013;38(03):466–477
- 10 McInnes CW, Ha AY, Power HA, Tung TH, Moore AM. Femoral nerve decompression and sartorius-to-quadriceps nerve transfers for partial femoral nerve injury: a cadaveric study and early case series. *J Neurosurg* 2020;•••:1–8