

## Midterm results of consecutive periprosthetic femoral fractures Vancouver type A and B

Klemens Trieb, Rainer Fiala,  
Christian Briglauer

Department of Orthopedics, Klinikum  
Wels-Grieskirchen, Wels, Austria

### Abstract

Surgical treatment of periprosthetic femoral fractures has a high complication and mortality rate of more than 10%. The aim of this study is to report the outcome of a consecutive single center patient group. Thirty-four consecutive patients (mean age 81.2±8.5 years, 14 male, 20 female) with a periprosthetic femoral fracture Vancouver type A (n=5) or type B (n=29) were followed-up after 43.2 months, none of the patients were lost to follow-up. Nineteen of the patients were treated through change of the stem and cerclage fixation, five by plates and ten by cerclage cables. One successfully treated infection was observed. No further complications have been reported peri- or postoperatively, therefore resulting in 2.9% overall complication rate. These results demonstrate that precisely selected revision surgery protocol following periprosthetic femoral fractures within elderly multimorbid patients may lead to beneficial outcomes at a low risk of complications.

### Introduction

Periprosthetic femoral fractures after primary total hip arthroplasty occur at an incidence of 1%, and show an increasing tendency of 4% following revision surgery.<sup>1,2</sup> Among these occurrences, the time interval between primary total hip arthroplasty and fracture varies among different studies, ranging from 7.4 years (Swedish Registry) to 8.1 years (Mayo Clinic Total Joint Registry). Furthermore, the Swedish Registry reported the time interval between revision surgery and fracture to average 3.9 years.<sup>3,4</sup> The respective treatment of periprosthetic femoral fractures is expensive and of complex nature, clinically showing relatively low harris-hip-scores and an elevated risk of mortality. Adding to these facts, the effected patients are mostly of advanced age with accompanying comorbidities, therefore complicating post-revision rehabilitation and reducing clinical outcome. These facts, in addition to a high prevalence of

poor bone quality, require specialized strategies for effective surgical treatment.<sup>1,2,5</sup>

Femoral periprosthetic fractures are more prevalent than acetabular fractures. Currently, the Vancouver classification is mostly utilized, including localization of the fracture, implant loosening, and bone quality to categorize fracture types.<sup>6,7</sup> Surgical treatment of these fractures is being recommended. An exception can be made for special circumstances of Vancouver type A fractures, showing beneficial results following conservative treatment. After deciding in favor of surgical treatment, different operating methods should be performed depending on fracture height, implant stability, and bone quality. These options range from open reduction with internal fixation (for instance wires, cerclage cables, struts), revision total hip arthroplasty using a long-stemmed femoral prosthesis, or utilization of fixed-angle plates in addition to minimally-invasive attachment of screws and cerclage cables to stabilize the fracture over enlarged distances. Postoperative results vary depending on surgical institution and method utilized.<sup>8-13</sup> This study documents a series of consecutive patients with periprosthetic femoral fractures, with surgical treatment and follow-up occurring at the same orthopedic department.

### Materials and Methods

Thirty-four consecutive patients (14 male, 20 female; average age 81.2±8.5 years) with acute periprosthetic femoral fracture, Vancouver type A (n=5) and type B (n=29), were enrolled to participate within this study at our orthopedic department. After evaluation of general operability according to comorbidities and following optimization of blood coagulation, surgical treatment occurred as soon as possible. The mean follow-up period was 43.2 months (range 20-64 months), with none of the patients having been lost to follow-up.

Preoperatively, the American Society of Anesthesiologists (ASA) physical status classification system was performed for proper risk evaluation. Collected data also included the patients' body-mass-index (BMI), duration until surgery, and medical conditions. Furthermore, patients underwent a physical examination, including patient history, and X-ray imaging of the injured hip for classification purposes. The radiological fracture classification was based on the Vancouver classification<sup>6,7</sup> to estimate the optimal surgical strategy (Table 1). The Vancouver classification includes type and localization of the fracture, implant stability, as well as bone quality.

Based on this classification system, the surgical decision regarding operating method was made. However, every single operation was

Correspondence: Klemens Trieb, Department of Orthopedics, Klinikum Wels-Grieskirchen, Grieskirchnerstr. 42, A-4600 Wels, Austria.  
Tel.: +43.72424153603.  
E-mail: Klemens.trieb@klinikum-wegr.at

Key words: Fracture; femur; periprosthetic.

Conflict of interest: the authors declare no potential conflict of interest.

Received for publication: 11 July 2016.  
Accepted for publication: 10 August 2016.

This work is licensed under a Creative Commons Attribution NonCommercial 4.0 License (CC BY-NC 4.0).

©Copyright K. Trieb et al., 2016  
Licensee PAGEPress, Italy  
*Clinics and Practice* 2016; 6:871  
doi:10.4081/cp.2016.871

undertaken using the entire array of surgical instruments for femoral revision (Alloclassic® SLL, Zimmer, Inc., Warsaw, IN, USA), modular long-stemmed prostheses (MRP-TITAN®, PETER BREHM GmbH, Weisendorf, Germany), surgical plates (NCB® Distal Femur plate, Zimmer, Inc.; LISS plate, Synthes, Inc., West Chester, PA, USA), as well as cerclage cables (Gundolf Titanbandcerclage, ImplanTec Schweiz GmbH, Baar, Switzerland).

The follow-up visit included X-ray images of the hip, clinical examination, harris-hip score, a quick neurological status, as well as documentation of complications or consecutive surgeries after revision surgery.

### Results

The individually adjusted surgical procedure was performed as soon as possible following diagnosis, with 23 out of 34 patients receiving surgical treatment either immediately or within 24 h. Delays were a result of patients' insufficient preoperative conditions, where optimizing of blood coagulation and other preoperative preparations had to primarily be undertaken. A BMI between 25 and 29 kg/m<sup>2</sup> was observed within 15 patients (44%), whereas 13 patients (38%) showed a BMI lower than 25 kg/m<sup>2</sup>, and 6 patients (18%) were documented with BMI greater than 30 kg/m<sup>2</sup>.

Only 1 patient (3%) was categorized as ASA grade 1, 8 patients (24%) ASA grade 2, 22 patients (64%) ASA grade 3, and 3 patients (9%) ASA grade 4. These classifications clearly reflect the diminished preoperative health status of our elderly injured patients.

There were 15 well-fixed stems (43%) (=Vancouver type A/B1), the remaining 19 (57%) were loose within bone (=Vancouver B2/B3). Concerning choice of surgical method, 19 patients (57%) had an exchange of stem with application of cerclage cables, 10 patients (29%) underwent open reduction and internal fixation also using cerclage cables, and 5 patients (14%) were treated with fixed-angle plates (Figure 1-6).

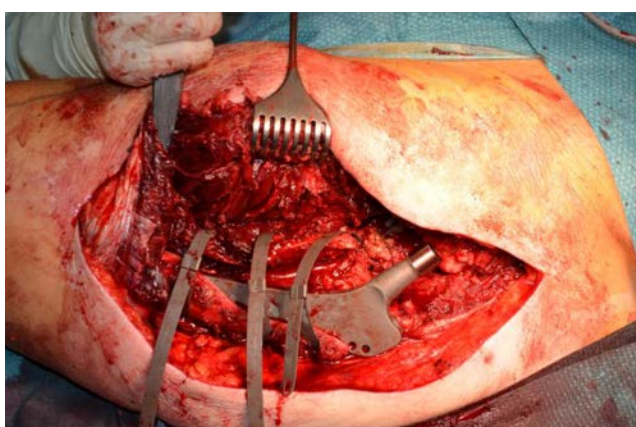
For patients with exchange of stem, 13 out of 19 received a modular long-stemmed prosthesis (MRP-TITAN®, PETER BREHM GmbH),<sup>14</sup> and 6 patients received a revision monoblock-stem (Zweimüller SLL, Zimmer, Inc.). The length of implants was 190 to 300 mm. Generally, titan-band cerclage wires were

used for proper fixation. Postoperatively, 1 patient showed a deep infection and was treated using a two-stage revision protocol. At the follow-up visit after 21 months, this patient

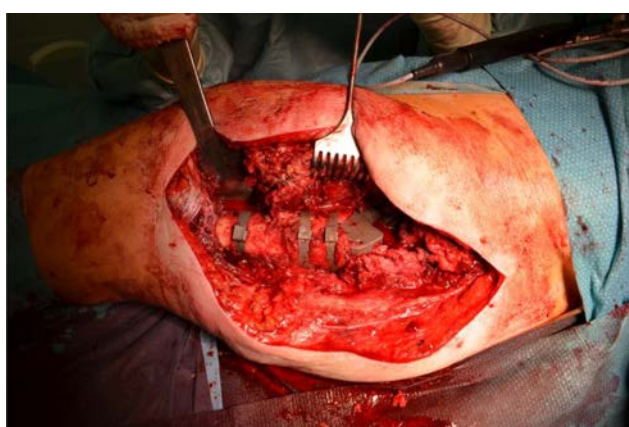
had a Harris hip score of 89 points and showed normal clinical and radiological results. Two multimorbid patients (5.8%) died of cardiac arrest shortly after surgery, both having been

**Table 1. Vancouver classification.**

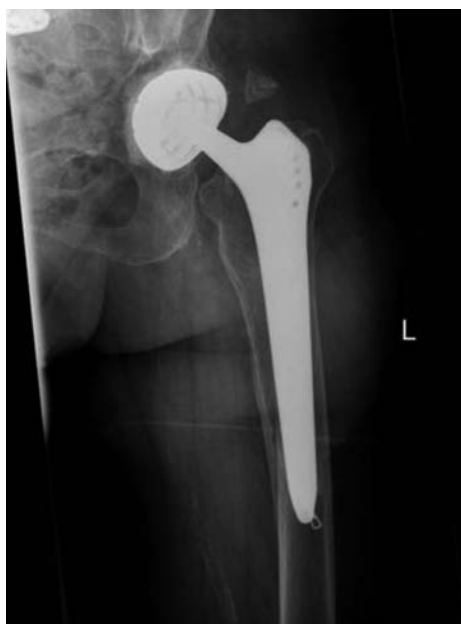Type	Description
A	Fracture in the trochanteric region
B	Fracture around the stem or just below
B1	With well fixed stem
B2	With loose stem but good proximal bone
B3	With poor quality or severely comminuted proximal bone
C	Fracture below the prosthesis



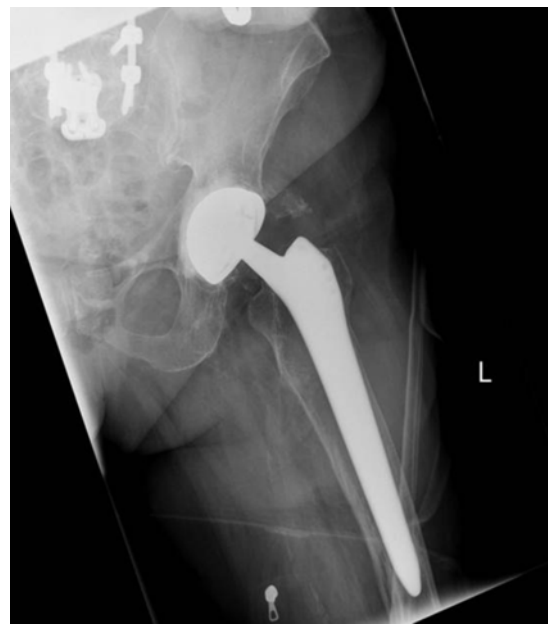**Figure 1. Intraoperative picture after fixation using titan-band cerclages.**



**Figure 2. Intraoperative picture after open reduction and fixation using titan-band cerclage.**



**Figure 3. Preoperative X-ray image of periprosthetic femoral fracture Vancouver type B (a.p.).**



**Figure 4. Axial X-ray imaging of Figure 3.**

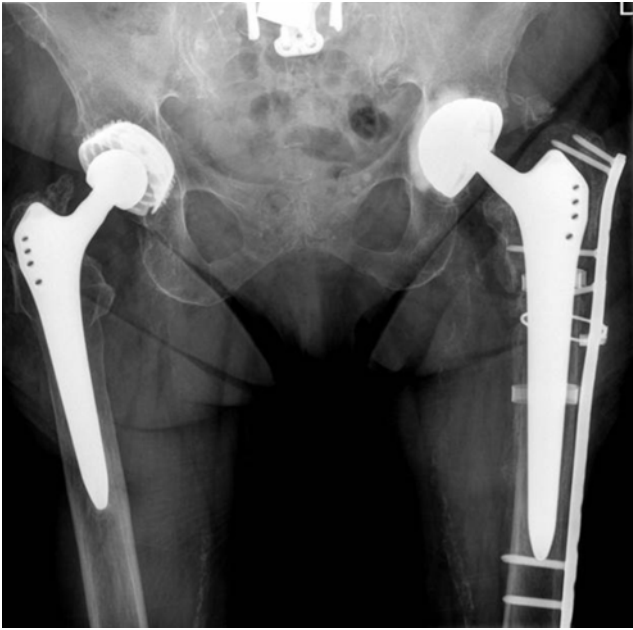

Figure 5. Postoperative X-ray image after open reduction and internal fixation using cerclage cables and plate (proximal).

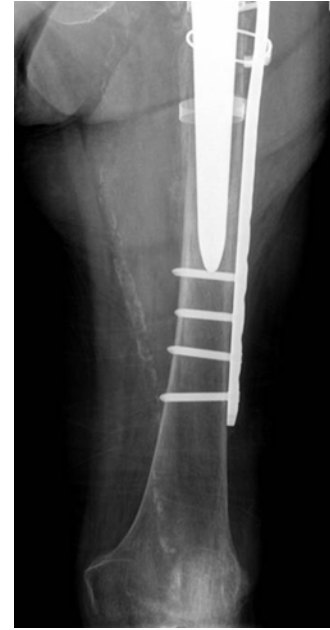

Figure 6. Postoperative X-ray image after open reduction and internal fixation using cerclage cables and plate (distal).

categorized ASA 4. One of these patients, aged 78 years, died one day postoperatively, and the other 86-year old patient deceased on the third day postoperatively.

One successfully treated infection was observed (2.9% complication rate).

No further peri- or postoperative complications occurred, and the remaining 32 patients presented themselves in good health without any signs or symptoms of implant failure or recurrent bone fracture during follow-up visits. The patients maximally utilized two walking-sticks for locomotion, and the average Harris hip score was 85 points (range 60-95 points).

## Discussion

Within the last years, major advances have been achieved for treatment of periprosthetic femoral fractures. Credit may be given to standardized classification systems, which allow for respective treatment algorithms.<sup>2,6,7</sup> Currently, internal fixation and revision total hip arthroplasty are viewed as gold standard, being utilized depending upon implant stability, bone rigidity, and type of fracture. The careful evaluation of these factors is crucial within the process of deciding upon the individually most efficient surgical procedure. Many cases simply show a non-adequate minor trauma, which might be resulting from prior implant loosening. Existing data

document up to 70% of loose implants at occurrence of periprosthetic femoral fractures, which is often a result of poor or missing follow-up visits. Elderly patients, frequently living in retirement homes, simply lack high-quality follow-up programs to screen for possible implant loosening prior to fracturing. A retrospective study by Abdel and colleagues,<sup>15</sup> evaluating 32,644 total hip arthroplasties over four decades, found a gradually rising cumulative probability of periprosthetic femoral fracture, with 0.4% after one year, 0.8% after 5 years, 1.6% after 10 years, and as many as 3.5% after 20 years. Ideally, loosened femoral implants should be replaced before the occurrence of fracture.<sup>8,9</sup> Precaution is advised for chronic progressive loosening as respective signs and symptoms are often missing, therefore regular clinical and radiological follow-ups are recommended. Within current literature, surgical treatment of periprosthetic femoral fractures demonstrate an elevated rate of complications and mortality, generally showing a prevalence of approximately 10%.<sup>16,17</sup> For instance, a matched pair study from the New Zealand Registry, comparing postoperative functional outcome of femoral periprosthetic fracture and revision hip arthroplasty, documented an increased rate of mortality (7.3 *vs.* 0.9%) and increased rates of re-revision (7.3 *vs.* 2.6%) after periprosthetic fracture, describing re-fracturing and luxation to be dominant causes for re-revision.<sup>18</sup>

Another study, comparing periprosthetic

femoral fractures to primary hip arthroplasty concerning mortality rates, also showed an elevation within the fracture group (11 *vs.* 2.9%), with a three-fold decrease in mortality after stem revision compared to open reduction and internal fixation. The Swedish Registry evaluated 63,582 primary hip arthroplasties and 736 periprosthetic femoral fractures to show an increased rate of postoperative mortality for the latter, ranging from 2.1 to 10%, and documenting great variation among functional results with up to 60% of patients complaining of chronic pain.<sup>19</sup> Other studies also highlight this tendency of unexpected events after surgical treatment of periprosthetic femoral fractures, with complications in 14 out of 45 patients (31%), including 6 deep infections, 6 cases of pseudarthrosis, and 2 cases of loosening,<sup>12</sup> or even larger rates of complications ranging from 26 to 43%.<sup>20,21</sup> Our consecutive series of patients demonstrated a mortality rate of 5.8% and one infection, but no other complications or re-revisions, showing a complication rate of 2.9%.

## Conclusions

Although large rates of complications and mortality have been described within literature, our results support the recommendation of surgical treatment after periprosthetic femoral fractures within elderly multimorbid patients.



## References

1. Kim Y, Tanaka C, Tada H, et al. Treatment of periprosthetic femoral fractures after femoral revision using a long stem. *BMC Musculoskelet Disord* 2015;16:113-9.
2. Schwarzkopf R, Oni JK, Marwin SE. Total hip arthroplasty periprosthetic femoral fractures: a review of classification and current treatment. *Bull Hosp Jt Dis* 2013;71:68-78.
3. Lewallen DG, Berry DJ. Periprosthetic fracture of the femur after total hip arthroplasty: treatment and results to date. *Instr Course Lect* 1998;47:243-9.
4. Lindahl H, Malchau H, Odén A, Garellick G. Risk factors for failure after treatment of a periprosthetic fracture of the femur. *J Bone Joint Surg Br* 2006;88:26-30.
5. Wähnert D, Schliemann B, Raschke MJ, Kösters C. Treatment of periprosthetic fractures: new concepts in operative treatment. *Orthopade* 2014;43:306-13.
6. Masri BA, Meek RM, Duncan CP. Periprosthetic fractures evaluation and treatment. *Clin Orthop Relat Res* 2004;469:80-95.
7. Duncan CP, Masri BA. Fractures of the femur after hip replacement. *Instr Course Lect* 1995;44:293-304.
8. Marsland D, Mears SC. A review of periprosthetic femoral fractures associated with total hip arthroplasty. *Geriatr Orthop Surg Rehabil* 2012;3:107-20.
9. Biggi F, Di Fabio S, D'Antimo C, Trevisani S. Periprosthetic fractures of the femur: the stability of the implant dictates the type of treatment. *J Orthop Traumatol* 2010;11:1-5.
10. Mukundan C, Rayan F, Kheir E, Macdonald D. Management of late periprosthetic femur fractures: a retrospective cohort of 72 patients. *Int Orthop* 2010;34:485-9.
11. Lunebourg A, Mouhsine E, Cherix S, et al. Treatment of type B periprosthetic femur fractures with curved non-locking plate with eccentric holes: Retrospective study of 43 patients with minimum 1-year follow-up. *Orthop Traumatol Surg Res* 2015;101:277-82.
12. Holder N, Papp S, Gofton W, Beaulé PE. Outcomes following surgical treatment of periprosthetic femur fractures: a single centre series. *Can J Surg* 2014;57:209-13.
13. Holley K, Zelken J, Padgett D, et al. Periprosthetic fractures of the femur after hip arthroplasty: an analysis of 99 patients. *HSS J* 2007;3:190-7.
14. Wimmer MD, Randau TM, Deml MC, et al. Impaction grafting in the femur in cementless modular revision total hip arthroplasty: a descriptive outcome analysis of 243 cases with the MRP-TITAN revision implant. *BMC Musculoskelet Disord* 2013;14:19.
15. Abdel MP, Watts CD, Houdek MT, et al. Epidemiology of periprosthetic fracture of the femur in 32 644 primary total hip arthroplasties. *Bone Joint J* 2016;98:461-7.
16. Streubel PN, Ricci WM, Wong A, Gardner MJ. Mortality after distal femur fractures in elderly patients. *Clin Orthop Relat Res* 2011;469:1188-96.
17. Griffiths EJ, Cash DJ, Kalra S, Hopgood PJ. Time to surgery and 30-day morbidity and mortality of periprosthetic hip fractures. *Injury* 2013;44:1949-52.
18. Young SW, Walker CG, Pitto RP. Functional outcome of femoral peri prosthetic fracture and revision hip arthroplasty: a matched-pair study from the New Zealand Registry. *Acta Orthop* 2008;79:483-8.
19. Bhattacharyya T, Chang D, Meigs JB, et al. Mortality after periprosthetic fracture of the femur. *J Bone Joint Surg Am* 2007;89:2658-62.
20. Zuurmond RG, van Wijhe W, van Raay JJAM, et al. High incidence of complications and poor clinical outcome in the operative treatment of periprosthetic femoral fractures: an analysis of 71 cases. *Injury* 2010;41:629-33.
21. Cohen K, Vanrykel F, Bellemans J, et al. An algorithm for the surgical treatment of periprosthetic fractures of the femur around a well-fixed femoral component. *J Bone Joint Surg A* 2009;91:1424-30.