

Giant Intraosseous Meningioma Associated with Calvarial Hyperostosis and Subcutaneous Invasion: Case Reports and Literature Review

Abstract

Most meningiomas grow intracranially, and primary intraosseous meningioma is rarely reported. We present two rare surgical cases of giant intraosseous meningotheial meningioma. The first patient was a 35-year-old male with parietal skull deformity without neurological symptoms. Total resection was successful. The origin was the parasagittal intraosseous layer, and the superior sagittal sinus was partially opened. The second patient was a 20-year-old female with a slightly upward protrusion of the frontal skull without pain or neurological deficits. The lesion was totally resected, and the origin was the parasagittal intraosseous layer invading into the dura matter and subcutaneous layer. The clinical management of these cases presented a surgical challenge because of detachment and repair from venous sinuses. The current report provides surgical tips for such rare diseases and is a good reference for the future treatment of similar diseases.

Keywords: Calvarium, intraosseous meningioma, meningioma

Introduction

Meningioma is the most common intracranial tumor and accounts for 15%–20% of all intracranial neoplasms.^[1,2] Skull hyper-ostosis associated with intradural meningioma is a well-known sign and is observed in 4.5% of all types,^[3] but it is more frequently observed in primary intraosseous meningioma (PIOM), with an incidence of 60%.^[4] “PIOM” is a subset of extradural meningioma that develops in bone^[5] and represents approximately two-thirds of all extradural meningiomas, accounting for 1%–2% of all meningiomas.^[6] As such, PIOM is rare.^[7] We report two surgical cases of giant intraosseous meningioma with a review of the literature.

Case Reports

Case 1

A 35-year-old male with no medical history was introduced to our department because of head deformation without neurological symptoms. The parietooccipital skull swelling deformity had a maximum diameter of 7 cm and consisted of a hard, elastic, and painless growing mass. Neurological

examination and laboratory testing revealed no abnormalities. Skull X-ray revealed the wide extent of the osteoblastic mass in the parieto-occipital skull [Figure 1a]. On gadolinium (Gd)-enhanced magnetic resonance imaging (MRI), a large homogeneous enhanced tumor in the subcutaneous and intraosseous portions, and a small enhanced tumor in the subdural parasagittal portion were observed [Figure 1b and c]. In addition, digital subtraction angiography revealed that the bilateral superficial temporal artery and occipital artery were the major sources of blood supply to the subcutaneous and intraosseous portions, and the parasagittal tumor was supplied from the right middle meningeal artery.

We first planned biopsy to exclude malignancy. Biopsy of the subcutaneous and intraosseous tumor revealed a benign meningotheial meningioma. As there was no neurological deficit, 5 months after the biopsy, elective tumor resection was performed. To maintain normal perfusion of the scalp, preoperative embolization for the main feeding artery, the superficial temporal artery, was impossible. We prepared autotransfusion for major hemorrhage

**Keisuke Sasaki,
Atsushi Saito¹,
Yasuo Nishijima²,
Takashi Inoue²,
Shinsuke Suzuki²,
Masayuki Ezura²,
Hiroshi Uenohara²,
Teiji Tominaga**

Department of Neurosurgery, Tohoku University, Graduate School of Medicine, ¹Department of Neurosurgery, Kohnan Hospital, ²Department of Neurosurgery, National Hospital Organization Sendai Medical Center, Sendai, Miyagi, Japan

Address for correspondence:

*Dr. Atsushi Saito,
Department of Neurosurgery,
Kohnan Hospital, 4-20-1
Nagamachiminami, Taihaku,
Sendai, Miyagi 9828523, Japan.
E-mail: satsushi2002@
yahoo.co.jp*

Access this article online

Website: www.asianjns.org

DOI: 10.4103/ajns.AJNS_534_20

Quick Response Code:



This is an open access journal, and articles are distributed under the terms of the Creative Commons Attribution-NonCommercial-ShareAlike 4.0 License, which allows others to remix, tweak, and build upon the work non-commercially, as long as appropriate credit is given and the new creations are licensed under the identical terms.

For reprints contact: WKHLRPMedknow_reprints@wolterskluwer.com

How to cite this article: Sasaki K, Saito A, Nishijima Y, Inoue T, Suzuki S, Ezura M, *et al.* Giant intraosseous meningioma associated with calvarial hyperostosis and subcutaneous invasion: Case reports and literature review. *Asian J Neurosurg* 2021;16:589-94.

Submitted: 08-Dec-2020

Revised: 22-Jan-2021

Accepted: 21-Mar-2021

Published: 14-Sep-2021

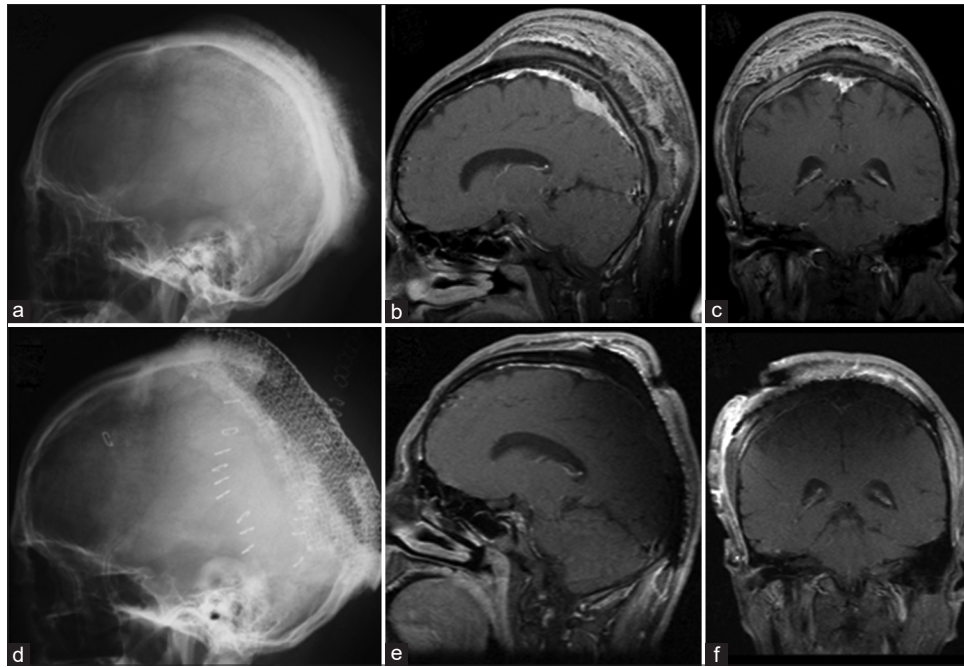


Figure 1: Preoperative images in Case 1. X-ray (a) showed the wide extent of osteoblastic lesions. Gadolinium-enhanced magnetic resonance imaging showed homogeneously enhanced regions of subcutaneous and parasagittal tumors (b and c). Postoperative images in Case 1. X-ray (d) showed cranioplasty with titanium mesh following the resection of the lesions. Gadolinium-enhanced magnetic resonance imaging demonstrated subtotal resection of the lesion (e and f)

during resection. After peeling the skin flap back with a coronary skin incision, a thick subcutaneous tumor mass was observed and dissected from the bony tumor mass. A subcutaneous, parasagittal intraosseous layer was the origin, and it extended into the subcutaneous lesion serially. Macroscopically, the inner skull plate was intact, and the dural infiltrated lesion was readily dissected. There were no continuous intracranial or subdural lesions. However, the subdural tumor was attached to the parasagittal area, thus we diagnosed him with multiple meningioma. The extended lesion was excised, and cranioplasty was performed using a titanium sheet [Figure 1d]. The intraosseous and parasagittal tumor was almost completely removed [Figure 1e and f]. Pathology of both extracranial and intracranial tumor lesions revealed meningothelial meningioma, and there was no malignancy based on the MIB-1 staining index. (This monoclonal antibody enables the detection of Ki-67 in proliferating cell populations in routine paraffin sections.) No recurrence was noted 10 years after the surgery. We've obtained his consent for this report

Case 2

A 20-year-old woman with a giant convexity meningioma was introduced to our hospital. At the age of 17 years, the meningioma was incidentally noted after examination of the left lower limb. She visited a local hospital because of slow aggravation of chronic headache, vomiting, and somnolence. Consciousness improved after the administration of steroids and glycerol, and she was transferred to our department for

surgery. The frontal calvaria were irregularly thickened on computed tomography. Gd-enhanced MRI on admission revealed a giant homogeneous enhanced tumor within the frontal calvaria associated with extracranial and intradural extensions [Figure 2a]. The superior sagittal sinus (SSS) was invaded but not completely occluded. Collateral circulation developed through bridging veins around the tumor [Figure 2b]. To reduce blood loss, we decided to preserve the tumor around the SSS. Hyper-osteosis from the intraosseous lesion was considered compressive and symptomatic because high intracranial pressure may cause neurological symptoms.

Staged surgical resection and cranioplasty were planned. The skin flap was turned forward after a coronal skin incision, and the subcutaneous tumor lesion was dissected from the serial bony lesion [Figure 3a and b]. Cutting into some pieces of the cranium was difficult because of marked thickness; therefore, burr holes were placed in normal cranium, and we divided the abnormal cranium and subdural lesion. During this procedure, approximately 2.1 L of blood was lost from the SSS, necessitating blood transfusion. The origin of the tumor was the parasagittal intraosseous layer and the tumor extended intra-durally with localized occlusion of the SSS [Figure 3c and d]. Pial tumor invasion was also observed in the cortical surface. A large amount of tumor tissue was dissected from the cortical surface and the dural-extending lesion was resected. Dissecting the hyper-osteotic skull from the dura matter was difficult because the working angle for the dissecting plane was limited and because of serial invasion from the

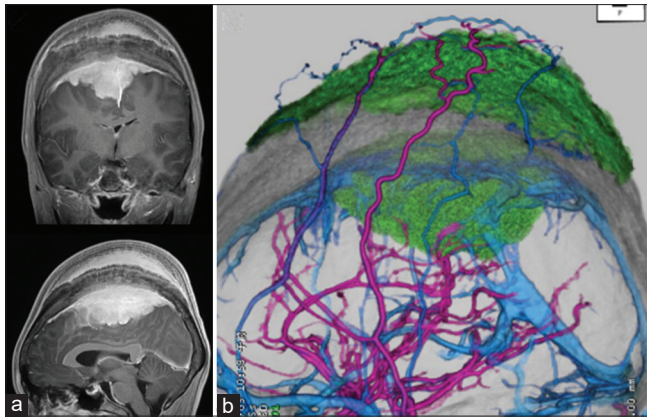


Figure 2: Preoperative images in Case 2. Gadolinium-enhanced magnetic resonance imaging showed a giant homogeneous enhanced tumor with intracranial, calvarial, and extracranial extensions and thickened calvaria with hyper-osteosis (a). Three-dimensional reconstruction images of computed tomography showed the superior sagittal sinus passing through the tumor, being partially occluded (b; green area: Tumor mass; blue vessels: Veins; red vessels: Arteries)

intraosseous to cortical surface. The frontal cortical surface was damaged. To preserve the SSS, the tumor removed was classified as Simpson grade 3 [Figure 4a]. Hydrocephalus and subcutaneous cerebrospinal fluid (CSF) collection developed as complications and were managed under external drainage. A lumbar abdominal shunt was placed and subcutaneous CSF collection improved. On pathology, intertrabecular spaces were infiltrated by the meningothelial meningioma, and the intracranial tumor lesion had the same features and contained trabecular tissue. MIB-1 staining was negative in the intracranial tumor and extracranial tumor (1% and 2%–3%, respectively). The patient was transferred for rehabilitation. Seven months after tumor resection, rehabilitation was completed and joint cranioplasty with plastic surgery was planned. Due to the extensive skull defect, we decided to use a titanium plate [Figure 3e]. The temporal posterior periosteal flap, which was continuous from the bilateral temporal periosteal flap, was lifted and sutured to lie below the skin incision such that the titanium plate was not directly exposed. The surgery was completed after the placement of a subcutaneous drain [Figure 4b and c]. No recurrence was noted 1 year after the surgery. We've obtained her consent for this report

Discussion

Extradural meningioma originating from subcutaneous skull bone and nasopharynx accounts for 1%–2% of all meningioma.^[8,9] PIOM is a rare type of meningioma originating from the calvarium and accounts for 60% of extradural meningioma.^[9] PIOM has a bimodal frequency at 20 years and 50–70 years of age and is more prevalent in women.^[10]

Marwah *et al.*^[11] termed meningioma developing in the skull as PIOM and the diagnostic criteria include the

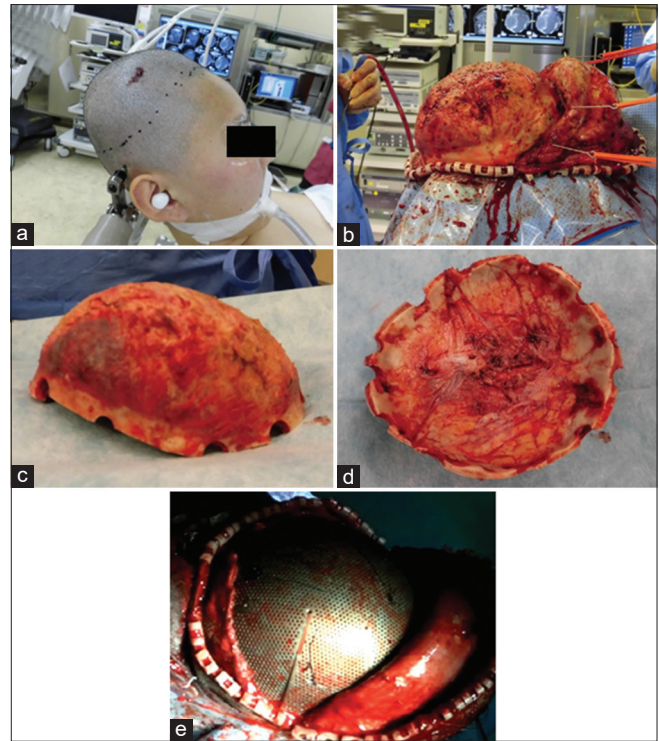


Figure 3: Intraoperative images in Case 2 during tumor resection showing the head deformation and coronary incision (a). After flap rotation, the tumor was revealed (b). Tumorized calvaria were noted after resection (c and d). Tenting of the artificial dura to a titanium plate and covering of the plate with the bilateral periosteal flap during cranioplasty (e)

following conditions: (i) the histological features of meningioma; (ii) lesions located in the epidural region or skull; and (iii) no involvement of the brain tissue, arachnoid, or dura. On the other hand, previous reports demonstrated that primary extradural meningioma (PEM) can exhibit intracranial growth involving the dura mater. Bassiouni *et al.*^[12] suggested that 14 of 16 (88%) PEM patients who underwent surgery had true dural involvement, which was confirmed pathologically. On the other hand, en plaque meningioma is associated with a higher incidence of hyperostosis between 13% and 49%.^[3] The origin in our two cases is unclear. Some authors stated that localization of the main tumor mass within the skull enables the determination of the site of origin of the tumor and designation of PIOM or PEM, even in the presence of dural invasion.^[13] JH Yun and SK Lee suggested that PIOM more often forms a broader base in the calvarium than in the dura, whereas tumors of meningeal origin, including meningioma, have a broader base in the dura than in the calvarium^[14] Both of our cases had a broader base in the calvarium than in the dura, which is why we diagnosed them as PIOM.

There are many different hypotheses regarding the origin of PEM. A frequent site of PIOM is around the calvarial suture adjacent to the ocular region and coronal suture.^[4] Mechanisms for its development have been reported as follows: Meningeal cells originate from mesenchymal cells, which directly originate from

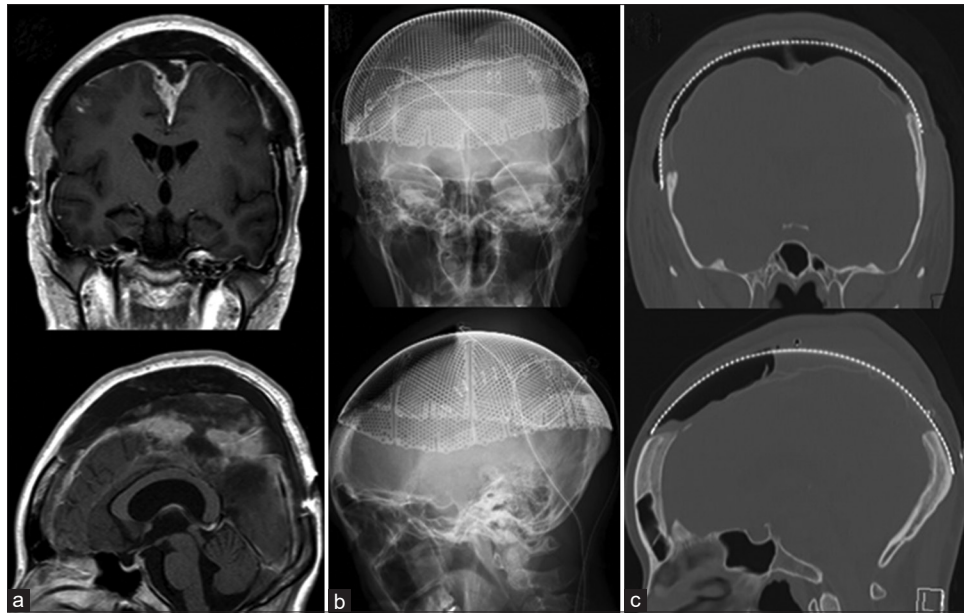


Figure 4: Postoperative images in Case 2 after tumor resection. Gadolinium-enhanced magnetic resonance imaging showed total resection of tumorized calvaria and extracranial lesion, and partial removal of intracranial lesion (a). Postoperative skull X-ray (b; upper row: Coronal image; lower row: Sagittal image) and computed tomography (c; upper row: Coronal image; lower row: Sagittal image) in Case 2 after cranioplasty confirmed the majority of the convexity part to be covered with a titanium plate

multipotent differentiating cells, such as fibroblast cells and Schwann cells, and differentiation occurs in many regions.^[15] Meningocytes or arachnoid cap cells exist in vessels and the nervous system, migrate to other regions, and proliferate.^[16] Arachnoid cap cells become trapped inside the fracture line or skull suture line and increase.^[17] Arachnoid cells migrate and increase inside the skull suture during osteoplasia at birth.^[18]

Intraosseous meningioma can be classified radiologically into an osteolytic type or an osteoblastic type.^[19] The osteoblastic type is dominant, but intradural meningioma and the osteolytic type account for 20% of cases.^[17] Crawford *et al.*^[4] reported that the osteoblastic subtype accounts for 59% of these meningiomas, whereas 32% exhibited osteolytic changes, and 6% had mixed features of both osteolysis and hyperostosis. The osteoblastic type has similar radiological findings to osteoma, osteosarcoma, Paget disease, and fibrous dysplasia.^[20] The osteolytic type has a referential diagnosis of hemangioma, chondroma, chondrosarcoma, dermoid, epidermoid tumors, multiple myeloma, plasmacytoma, giant cell tumors, aneurismal bone cysts, eosinophilic granuloma, and metastatic tumors.^[4,10,17,21] The osteolytic type is more malignant than the osteoblastic type.^[7] Only a few previous studies reported PIOM with pial invasion. Kudo *et al.*^[21] reported osteolytic PIOM with a dural defect that invaded the underlying arachnoid membrane and the wall of a large cortical vein. Lee *et al.*^[22] reported osteolytic PIOM that invaded the underlying brain parenchyma when it recurred 2 years after the first resection. Both cases had the osteolytic features not observed in our Case 2, which had osteoblastic features. We reported the first case of osteoblastic PIOM with pial invasion. PIOM is rare

and giant PIOM is markedly rare. Therefore, the long-term prognosis of untreated osteoblastic PIOM remains unclear.

The pathology of intraosseous meningioma is meningotheial type in 63%, transitional type in 25%, and malignant meningioma in only 0.2% of cases.^[23] Recurrence was noted in 22% of the previously reported cases of benign PEM.^[9] Arana *et al.*^[13] reported five cases of recurrence (36%) within 6 months to 4 years after surgery in 14 patients in their series. Both of our cases were benign on pathology. Case 1 had no recurrence, but frequent follow-up to prevent recurrence should be performed in Case 2.

Wide surgical excision of intraosseous meningioma is the treatment of choice and is potentially curative if possible.^[4] There was partial invasion of the intraosseous tumor lesion into the dura matter, and the tumor was adjacent to the SSS without direct invasion into the SSS in Case 2. The dural invasive lesion extended to the intradural parasagittal lesion and attached to the frontal cortex. Although detachment and hemostasis were predicted to be difficult during dissection between the cranium and dura matter, the dural surface on the SSS was intact, and tight adhesion was limited. However, securing an angle to dissect the attachment of the dural surface from the curved large cranium was difficult, and cutting pieces of the cranium were also difficult because of marked thickness. Both a detailed dissecting procedure and appropriate hemostasis should be considered for safer craniotomy. There are several technical reports of removing intraosseous meningioma. Bone cutting guides or a drilling template were used for tumor resection.^[24,25] Duraplasty using artificial dura was applied for broad dural defects.

Moreover, decompressive craniectomy is a well-established concept for traumatic injury to reduce intracranial pressure that improves survival in the clinical settings.^[26,27] Wang *et al.*^[28] reported that this process significantly reduces intracranial hypertension and improves pressure dynamics after the resection of giant meningiomas. There are also reports of its performance in second staged surgery.^[24]

CSF leakage and infectious complications should also be considered. In Case 2, cosmetic cranioplasty was planned during a second surgery with artificial skull bone. Hydrocephalus and subcutaneous CSF collection developed after the first resection surgery, but a lumbar peritoneal shunt improved the condition. The nature of fluid dynamics within the brain parenchyma is a focus of study. The meningeal lymphatic vessels were recently demonstrated as an important player in the complex circulation and exchange of soluble contents between the CSF and the interstitial fluid.^[29,30] Visanji *et al.*^[31] provided evidence of the presence of lymphatic vessels in human dura obtained at autopsy at the level of the SSS in four individuals. Thus, broad dural deficits around the SSS may lead to absorption disorder of CSF. The broader deficit in Case 2 than in Case 1 may have led to hydrocephalus. Careful postoperative management of CSF is required.

Conclusions

We treated two rare cases of giant intraosseous meningioma originating from the cranial diploic layer with a marked osteoblastic mass that invaded the subcutaneous layer and intradural region. The radiological characteristics and surgical tips described in this report provide a good reference for the future treatment of similar diseases.

Acknowledgment

A part of case presentation of case 1 has been already published with different radiological findings for a single case report from the same department in Nishijima Y *et al.* *Jpn J Neurosurg (Japanese)* 21:32-38,2012. I would like to thank the authors. There is no same figure in this report, the secretary of *Jpn J Neurosurg* approved our report.

Declaration of patient consent

The authors certify that they have obtained all appropriate patient consent forms. In the form the patient(s) has/have given his/her/their consent for his/her/their images and other clinical information to be reported in the journal. The patients understand that their names and initials will not be published and due efforts will be made to conceal their identity, but anonymity cannot be guaranteed.

Financial support and sponsorship

Nil.

Conflicts of interest

There are no conflicts of interest.

References

1. Younis G, Sawaya R. Intracranial osteolytic malignant meningiomas appearing as extracranial soft-tissue masses. *Neurosurgery* 1992;30:932-5.
2. Zhang H, Zhang N, Dong L, She L, Wang X, Xu E, *et al.* Rare giant bilateral calvarial hyperostosis across the superior sagittal sinus secondary to brain meningioma: A case report. *Oncol Lett* 2014;8:281-4.
3. Gupta SK, Mohindra S, Radotra BD, Khosla VK. Giant calvarial hyperostosis with biparasagittal en plaque meningioma. *Neurol India* 2006;54:210-2.
4. Crawford TS, Kleinschmidt-DeMasters BK, Lillehei KO. Primary intraosseous meningioma. Case report. *J Neurosurg* 1995;83:912-5.
5. Politi M, Romeike BF, Papanagiotou P, Nabhan A, Struffert T, Feiden W, *et al.* Intraosseous hemangioma of the skull with dural tail sign: Radiologic features with pathologic correlation. *AJNR Am J Neuroradiol* 2005;26:2049-52.
6. Muzumdar DP, Vengsarkar US, Bhatjiwale MG, Goel A. Diffuse calvarial meningioma: A case report. *J Postgrad Med* 2001;47:116-8.
7. Nishijima Y, Utsunomiya A, Suzuki S, Inoue T, Ezura M, Uenohara H, *et al.* A case of Intraosseous and subcutaneous meningioma transforming head like a rugby ball. *Jpn J Neurosurg* 2012;21:32-8.
8. Hoye SJ, Hoar CS Jr., Murray JE. Extracranial meningioma presenting as a tumor of the neck. *Am J Surg* 1960;100:486-9.
9. Lang FF, Macdonald OK, Fuller GN, DeMonte F. Primary extradural meningiomas: A report on nine cases and review of the literature from the era of computerized tomography scanning. *J Neurosurg* 2000;93:940-50.
10. Tokgoz N, Oner YA, Kaymaz M, Ucar M, Yilmaz G, Tali TE. Primary intraosseous meningioma: CT and MRI appearance. *AJNR Am J Neuroradiol* 2005;26:2053-6.
11. Marwah N, Gupta S, Marwah S, Singh S, Kalra R, Arora B. Primary intraosseous meningioma. *Indian J Pathol Microbiol* 2008;51:51-2.
12. Bassiouni H, Asgari S, Hübschen U, König HJ, Stolke D. Dural involvement in primary extradural meningiomas of the cranial vault. *J Neurosurg* 2006;105:51-9.
13. Arana E, Diaz C, Latorre FF, Menor F, Revert A, Beltrán A, *et al.* Primary intraosseous meningiomas. *Acta Radiol* 1996;37:937-42.
14. Yun JH, Lee SK. Primary osteolytic intraosseous atypical meningioma with soft tissue and dural invasion: Report of a case and review of literatures. *J Korean Neurosurg Soc* 2014;56:509-12.
15. Lopez DA, Silvers DN, Helwig EB. Cutaneous meningiomas—A clinicopathologic study. *Cancer* 1974;34:728-44.
16. Inagaki K, Otsuka F, Matsui T, Ogura T, Makino H. Effect of etidronate on intraosseous meningioma. *Endocr J* 2004;51:389-90.
17. Agrawal V, Ludwig N, Agrawal A, Bulsara KR. Intraosseous intracranial meningioma. *AJNR Am J Neuroradiol* 2007;28:314-5.
18. Devi B, Bhat D, Madhusudhan H, Santhosh V, Shankar S. Primary intraosseous meningioma of orbit and anterior cranial fossa: A case report and literature review. *Australas Radiol* 2001;45:211-4.
19. Changhong L, Naiyin C, Yuehuan G, Lianzhong Z. Primary intraosseous meningiomas of the skull. *Clin Radiol* 1997;52:546-9.
20. Jayaraj K, Martinez S, Freeman A, Lyles KW. Intraosseous meningioma—A mimicry of Paget's disease? *J Bone Miner Res*

- 2001;16:1154-6.
21. Kudo H, Maeda S, Takamoto T, Tamaki N. Intraosseous meningioma with a dural defect. *Neurol Med Chir (Tokyo)* 1998;38:229-31.
 22. Lee WH, Tu YC, Liu MY. Primary intraosseous malignant meningioma of the skull: Case report. *Neurosurgery* 1988;23:505-8.z
 23. Yamazaki T, Tsukada A, Uemura K, Satou H, Tsuboi K, Nose T. Intraosseous meningioma of the posterior fossa—Case report. *Neurol Med Chir (Tokyo)* 2001;41:149-53.
 24. Sundblom J, Nowinski D, Casar-Borota O, Ryttefors M. Removal of giant intraosseous meningioma followed by cranioplasty using a custom-made bioceramic implant: Case report. *J Neurosurg* 2018;131:735-9.
 25. Carolus A, Weihe S, Schmieder K, Brenke C. One-step CAD/CAM titanium cranioplasty after drilling template-assisted resection of intraosseous skull base meningioma: Technical note. *Acta Neurochir (Wien)* 2017;159:447-52.
 26. Paul T, Münch E, Horn P, Piegras A, Schmiedek P, Schürer L. Management of severe traumatic brain injury by decompressive craniectomy. *Neurosurgery* 2000;47:315-23.
 27. Whitfield PC, Patel H, Hutchinson PJ, Czosnyka M, Parry D, Menon D, *et al.* Bifrontal decompressive craniectomy in the management of posttraumatic intracranial hypertension. *Br J Neurosurg* 2001;15:500-7.
 28. Wang X, Wu R, Zhang P, Zhang C, Song G, Gao Z. Superior sagittal sinus obstruction by giant meningiomas: Is total removal feasible? *World Neurosurg* 2016;94:111-9.
 29. Aspelund A, Antila S, Proulx ST, Karlisen TV, Karaman S, Detmar M, *et al.* A dural lymphatic vascular system that drains brain interstitial fluid and macromolecules. *J Exp Med* 2015;212:991-9.
 30. Louveau A, Smirnov I, Keyes TJ, Eccles JD, Rouhani SJ, Peske JD, *et al.* Structural and functional features of central nervous system lymphatic vessels. *Nature* 2015;523:337-41.
 31. Visanji NP, Lang AE, Munoz DG. Lymphatic vasculature in human dural superior sagittal sinus: Implications for neurodegenerative proteinopathies. *Neurosci Lett* 2018;665:18-21.