

## Case Report

# The Unusual Origin of the Sternocleidomastoid Artery from the Lingual Artery

Tae Hong Kim, M.D.,<sup>1</sup> Seung Eun Chung, M.D.,<sup>2</sup> Yong Soon Hwang, M.D.,<sup>1</sup> Sang Keun Park, M.D.<sup>1</sup>

*Department of Neurosurgery,<sup>1</sup> College of Medicine, Inje University, Sanggye Paik Hospital, Seoul, Korea*

*Department of Radiology,<sup>2</sup> Chungdam Wooridul Spine Hospital, Seoul, Korea*

The sternocleidomastoid (SCM) artery supplying blood to the SCM muscle has different origins according to its anatomical segment. The authors performed cadaveric neck dissection to review the surgical anatomy of neurovascular structures surrounding the carotid artery in the neck. During the dissection, an unusual finding was cited in which the SCM artery supplying the middle part of the SCM muscle originated from the lingual artery (LA); it was also noted that it crossed over the hypoglossal nerve (HN). There have been extremely rare reports citing the SCM artery originated from the LA. Though the elevation of the HN over the internal carotid artery was relatively high, the vascular loop crossing over the HN was very close to the carotid bifurcation. Special anatomical consideration is required to avoid the injury of the HN during carotid artery surgery.

**Key Words** : Lingual artery · Carotid artery surgery · SCM artery · Hypoglossal nerve.

## INTRODUCTION

During carotid neck surgery, meticulous dissection technique and detailed anatomical knowledge must be applied in order to avoid injuries of neurovascular structures surrounding the carotid artery. Extracranial hypoglossal nerve injuries were not uncommon and occurred in 2-17% of cases<sup>7</sup>. The sternocleidomastoid (SCM) artery plays a role to identify the hypoglossal nerve during carotid neck surgery but its origin sites are various<sup>13</sup>. The aims of our research are to describe the SCM artery originated from the lingual artery and to review its clinical importance.

## CASE REPORT

Carotid neck dissection was performed on a formalin-fixed adult cadaver head. Specimen was fixed in 10% formaldehyde solution. Anatomical specimen was examined using 10× magnifications with a Lexica (St. Louis, MO, USA) surgical microscope. This case showed that the SCM artery originated from the lingual artery and it crossed over the hypoglossal nerve (HN) (Fig. 1). The distance between carotid bifurcation and the

lingual artery was 14.8 mm. The course of the HN was parallel to ECA. The distance between carotid bifurcation and the HN over the ECA was 21.7 mm. The distance between carotid bifurcation and the HN over the ICA was 26 mm. The carotid bifurcation was located at the level of 5th cervical vertebra. This case showed that the SCM artery displaced the HN inferiorly, and the arterial loop over the HN was very close to the carotid bifurcation.

## DISCUSSION

During carotid neck surgery, it is very important to know anatomical details in order to avoid neurovascular injuries. Because of various neurovascular courses surrounding the carotid artery in the neck, numerous extracranial cranial nerve injuries have been reported with an incidence rate of 3-47.5%<sup>4,15,16</sup>. Among those injuries, hypoglossal nerve injuries were most common<sup>7</sup>. Even though the HN has various running courses in the neck, different landmarks have been proposed to recognize the level of the HN<sup>1-3,5,12,13,17,20</sup>. Characteristic vascular loop crossing over the HN is mainly made by the OA itself or the SCM artery originated from the OA. The SCM artery as well as the occipital ar-

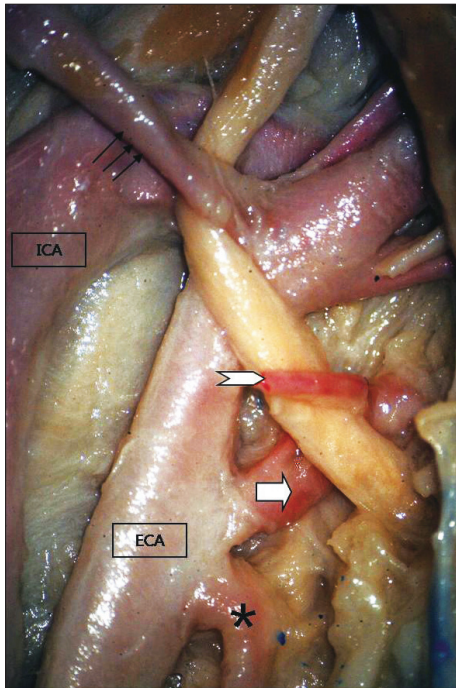
• Received : March 10, 2011 • Revised : June 24, 2011 • Accepted : January 8, 2012

• Address for reprints : Tae Hong Kim, M.D.

• Department of Neurosurgery, College of Medicine, Inje University, Sanggye Paik Hospital, 1342 Donggil-ro, Nowon-gu, Seoul 139-707, Korea

• Tel : +82-2-950-1035, Fax : +82-2-950-1040, E-mail : seth72@paik.ac.kr

• This is an Open Access article distributed under the terms of the Creative Commons Attribution Non-Commercial License (<http://creativecommons.org/licenses/by-nc/3.0>) which permits unrestricted non-commercial use, distribution, and reproduction in any medium, provided the original work is properly cited.



**Fig. 1.** Right side of neck. The HN is hooked by the OA (black arrow) and the SCM artery (white arrow, narrow) arising from the LA (white arrow, wide). The superior thyroid artery (\*) is located very close to the LA inferiorly. HN : hypoglossal nerve, SCM : sternocleidomastoid, LA : lingual artery.

tery plays a role as a good landmark for the identification of the HN but the origin site of the SCM artery is not always consistent<sup>13</sup>. Antonius et al. and Luis BF et al. reported that the blood supply to the SCM muscle can be categorized into 3 parts : upper, middle, and lower<sup>8,11</sup>. The upper third of the SCM muscle was found to be constantly supplied by branches of the occipital artery. The middle third of the SCM muscle receives its blood supply from a branch of the superior thyroid artery (42%), the ECA (23%), or both (27%). In most cases, the lower third is supplied by a branch arising from the suprascapular artery (>80%). In this case, the SCM artery supplying the middle part of the SCM muscle originated from the lingual artery; it is extremely rare case. Antonius et al. reported only one case during 31 necks (61 preparations) dissection<sup>11</sup>. The lingual artery (LA) is one of the main arteries supplying the tongue and the floor of the mouth. It usually originates from ECA at the level of the posterior tubercle of the hyoid bone<sup>19</sup>. It also originates from the superior thyroid artery in 1-2%<sup>10,18</sup>. In 10% to 20% of cases, the LA shares a common trunk with the facial artery, typical from 4 branches : suprahyoid branch, dorsal lingual branch, deep lingual branch, and sublingual artery<sup>14</sup>. The LA also has various levels on the ECA<sup>13</sup> : average distance from the carotid bifurcation to the lingual artery was  $9.99 \pm 6.60$  mm on the right side and  $12.63 \pm 8.36$  mm on the left side. In total, 4 cases showed that the lingual artery was level with or lower than the carotid bifurcation<sup>13</sup>. In general, the LA is not a limiting factor in exposing the carotid bifurcation during carotid neck surgery. How-

ever, if vascular loop by the SCM artery originated from the LA go over the HN, displacing and positioning the HN inferiorly like this case, we should take into consideration in order not to injure the HN because the location of the HN hooked by the SCM artery arising from the LA was closer to the carotid bifurcation than in the case where the SCM artery arising from the OA crossed over the HN. We also found that the carotid bifurcation was located at the level of C5 vertebra on fluoroscopy, relatively lower than in the usual cases. The level of the carotid bifurcation is variable, but by means of angiography, the carotid bifurcation is usually located at the level of C4<sup>6</sup>, whereas anatomically, the bifurcation is most frequently located at the level of the disc between C3 and C4<sup>9</sup>. In general, if the level of the carotid bifurcation is relatively low, the risk of the HN injury can be low. However, if the HN is displaced and positioned inferiorly by the SCM artery from the lingual artery like this case, the HN injury can occur more easily during carotid neck surgery.

## CONCLUSION

We report a very rare case of unusual origin of the SCM artery from the lingual artery. As we expose the carotid bifurcation, ICA and ECA during carotid endarterectomy, we must take into consideration the anomalous course of the HN and various vascular anomalies.

## References

1. Aldoori MI, Baird RN : Local neurological complication during carotid endarterectomy. *J Cardiovasc Surg (Torino)* 29 : 432-436, 1988
2. Bademci G, Batay F, Vural E, Avci E, Al-Mefty O, Yaşargil MG : Microsurgical anatomical landmarks associated with high bifurcation carotid artery surgery and related to hypoglossal nerve. *Cerebrovasc Dis* 19 : 404-406, 2005
3. Bademci G, Yaşargil MG : Microsurgical anatomy of the hypoglossal nerve. *J Clin Neurosci* 13 : 841-847, 2006
4. Ballotta E, Da Giau G, Renon L, Narne S, Saladini M, Abbruzzese E, et al. : Cranial and cervical nerve injuries after carotid endarterectomy : a prospective study. *Surgery* 125 : 85-91, 1999
5. Curto FS Jr, Suarez F, Kornblut AD : The extracranial hypoglossal nerve : 112 cadaver dissection. *Ear Nose Throat J* 59 : 94-99, 1980
6. Dilenge D, Heon M : The internal carotid artery in Newton TH, Potts DG (eds) : *Radiology of the Skull and Brain*, ed 2. Saint Louis : CV Mosby, 1974, pp1202-1245
7. Fernando DA, Lord RS, Ozmen J : The blood supply of the hypoglossal nerve and its relevance to carotid endarterectomy. *Cardiovasc Surg* 7 : 287-291, 1999
8. Fróes LB, Castro De Tolosa EM, Camargo RD, Pompeu E, Liberti EA : Blood supply to the human sternocleidomastoid muscle by the sternocleidomastoid branch of the occipital artery. *Clin Anat* 12 : 412-416, 1999
9. Gray H : The carotid system of arteries in Williams PL, Warwick R (eds) : *Gray's anatomy*, ed 36. New York : Churchill Livingstone, 1980, pp676-692
10. Hayashi N, Hori E, Ohtani Y, Ohtani O, Kuwayama N, Endo S : Surgical anatomy of the cervical carotid artery for carotid endarterectomy. *Neurol Med Chir (Tokyo)* 45 : 25-29; discussion 30, 2005
11. Kierner AC, Aigner M, Zelenka I, Riedl G, Burian M : The blood supply

- of the sternocleidomastoid muscle and its clinical implications. *Arch Surg* 134 : 144-147, 1999
12. Kim DD, Caccamese JF Jr, Ord RA : Variations in the course of the hypoglossal nerve : a case report and literature review. *Int J Oral Maxillofac Surg* 32 : 568-570, 2003
  13. Kim T, Chung S, Lanzino G : Carotid artery-hypoglossal nerve relationships in the neck : an anatomical work. *Neurol Res* 31 : 895-899, 2009
  14. Lewis WH : **Anatomy of the human body**, ed 20. New York : Bartleby, 2000, pp553
  15. Liapis CD, Satiani B, Florance CL, Evans WE : Motor speech malfunction following carotid endarterectomy. *Surgery* 89 : 56-59, 1981
  16. Maniglia AJ, Han DP : Cranial nerve injuries following carotid endarterectomy : an analysis of 336 procedures. *Head Neck* 13 : 121-124, 1991
  17. Nathan H, Levy J : The course and relations of the hypoglossal nerve and the occipital artery. *Am J Otolaryngol* 3 : 128-132, 1982
  18. Osborn AG : **Cerebral angiography**, ed 2. Philadelphia : Lippincott Williams & Wilkins, 1999, pp31-55
  19. Troupis TG, Dimitroulis D, Paraschos A, Michalinos A, Protogerou V, Vlasis K, et al. : Lingual and facial arteries arising from the external carotid artery in a common trunk. *Am Surg* 77 : 151-154, 2011
  20. Weinstein GS, May M : Anomaly of the hypoglossal nerve : embryologic, anatomic, and surgical considerations. *Ann Otol Rhinol Laryngol* 99 : 304-306, 1990