


Case Report

Successful laparoscopic resection of a paraganglioma immediately behind the inferior vena cava and bilateral renal veins

Tomoaki Hakariya,¹  Yohei Shida,¹ Hidenori Ito,¹ Yasufumi Ueda,¹ Hiroki Kurata,¹ Asato Ohtsubo,¹ Yasuyoshi Miyata,¹ Hideki Sakai¹ and Bungo Furusato²

Departments of ¹Urology, and ²Pathology, Nagasaki University Graduate School of Biomedical Sciences, Nagasaki, Japan

Abbreviations & Acronyms

CT = computed tomography

IVC = inferior vena cava

Correspondence: Tomoaki Hakariya M.D., Ph.D., Department of Urology, Nagasaki University Graduate School of Biomedical Sciences, 1-7-1 Sakamoto, Nagasaki 852-8501, Japan. Email: thakariya@nagasaki-u.ac.jp

How to cite this article:

Hakariya T, Shida Y, Ito H *et al.* Successful laparoscopic resection of a paraganglioma immediately behind the inferior vena cava and bilateral renal veins. *IJU Case Rep.* 2019; 2: 261–4.

This is an open access article under the terms of the Creative Commons Attribution-NonCommercial License, which permits use, distribution and reproduction in any medium, provided the original work is properly cited and is not used for commercial purposes.

Received 13 March 2019;
accepted 30 May 2019.
Online publication 22 June 2019

Introduction: Paragangliomas have a rich blood flow and are located around large vessels; thus, resection is often difficult. We herein report a case of a paraganglioma that was located immediately behind the inferior vena cava and bilateral renal veins and successfully resected by laparoscopic surgery.

Case presentation: A 72-year-old man was incidentally diagnosed with a 7-cm retroperitoneal mass immediately behind the inferior vena cava and bilateral renal veins by computed tomography. The mass was diagnosed as a retroperitoneal paraganglioma. The patient underwent laparoscopic surgery in the left lateral decubitus position. The tumor was dissected completely with no complications.

Conclusion: Resection of retroperitoneal paragangliomas is often a surgical challenge. The feasibility of the laparoscopic approach to such paragangliomas was demonstrated in the present case.

Key words: abdominal aorta, inferior vena cava, laparoscopic surgery, paraganglioma, retroperitoneal tumor.

Keynote message

Resection of retroperitoneal paragangliomas is often a surgical challenge. This case illustrates the feasibility of the laparoscopic approach to such a paraganglioma with careful preoperative preparation.

Introduction

Paragangliomas are distributed along the sympathetic and parasympathetic chains and frequently present as a retroperitoneal mass around the abdominal aorta.¹ Surgical resection is the only available curative treatment for paragangliomas. The laparoscopic approach has been proven safe and effective for resection of retroperitoneal tumors. However, the difficulty of laparoscopic surgery is highly dependent on the vascularity and location of the target. Paragangliomas have a rich blood flow and are located around large vessels; thus, resection is often difficult. We herein report a case of a paraganglioma that was located immediately behind the IVC and bilateral renal veins and was successfully resected by laparoscopic surgery.

Case presentation

History

A 72-year-old man was incidentally diagnosed with a 7-cm retroperitoneal mass immediately behind the IVC and bilateral renal veins by CT and visited our institution. He had no history of hypertension or subjective symptoms and no family history.

Diagnosis

Contrast-enhanced CT revealed a hypervascular tumor located immediately behind the IVC and bilateral renal veins, on the ventral side of the right renal artery and on the right side of the abdominal aorta (Fig. 1).

Magnetic resonance imaging revealed a heterogenous retroperitoneal mass with high intensity on the T2-weighted image, and a paraganglioma was suspected. Hormonal study revealed urinary metanephrine and normetanephrine levels of 4.89 mg/day (reference range, 0.04–0.18 mg/day) and 4.11 mg/day (reference range, 0.04–0.28 mg/day), respectively.

^{123}I -MIBG scintigraphy showed a high level of accumulation in the retroperitoneal mass (Fig. 2). On the basis of the above results, we diagnosed the tumor as a paraganglioma.

Operation

For preoperative preparation, doxazosin was gradually increased to 16 mg in an attempt to increase the circulating blood volume.

Laparoscopic surgery was performed in the left lateral decubitus position. Port placement is shown in Figure 3. After mobilizing the ascending colon and duodenum, the tumor was found to be squeezing the IVC from the posterior side (Fig. 3).

After detaching the tumor from the lower side of the liver, the tumor was dissected from the right renal vein, left renal vein, right kidney, and abdominal aorta, respectively. No adhesion was present between the liver and right adrenal gland or between the liver and tumor. The right renal vein and left renal vein were secured with vascular tape to avoid injury. At this time, we identified two drainage veins from the tumor flowing into the IVC and cut it. While the abdominal aorta and tumor were being separated, two arteries supplying the tumor were observed and cut with a sealing device. When all these dissections were completed, the mobility of the tumor increased and dissection from the IVC became possible.

While dissecting the tumor from the IVC, the latter was squeezed to the left side by an assistant using gentle manipulation. After release of the tumor from the IVC, it became possible to flip the tumor from the head side. The right renal

artery was then recognized on the back of the tumor, and the tumor was finally completely removed from the surrounding tissue (Fig. 4). The intraoperative blood pressure transiently increased to 180/60 mmHg, but this was not sustained, and no hypertensive crisis occurred. All other circulatory parameters were stable. The operation time was 231 min, estimated blood loss was 200 mL, and the weight of the removed tumor was 61 g.

Pathological diagnosis

The tumor cells showed strong positive immunohistochemical staining with chromogranin and synaptophysin, and the sustentacular cells at the periphery of the Zellballen stained with S100. These findings were compatible with the characteristics of paraganglioma. The tumor cells showed intermediate cellularity, and the Ki-67 labeling index was 1–2%. Thus, the Grading system for Adrenal Pheochromocytoma and Paraganglioma score was 2.

Outcome

No perioperative complications occurred. The urinary metanephrine and normetanephrine levels normalized after surgery. No obvious recurrence was observed 1 year postoperatively.

Discussion

Paraganglioma is a neuroendocrine tumor that arises from the sympathetic ganglion and may cause various complications due to overproduction of catecholamines.

The most common site of the development of paragangliomas is around the large vessels of the retroperitoneum.¹ Thus, the location of the paraganglioma greatly affects the difficulty of the operation. Several reports have described the challenges of resection of paragangliomas.

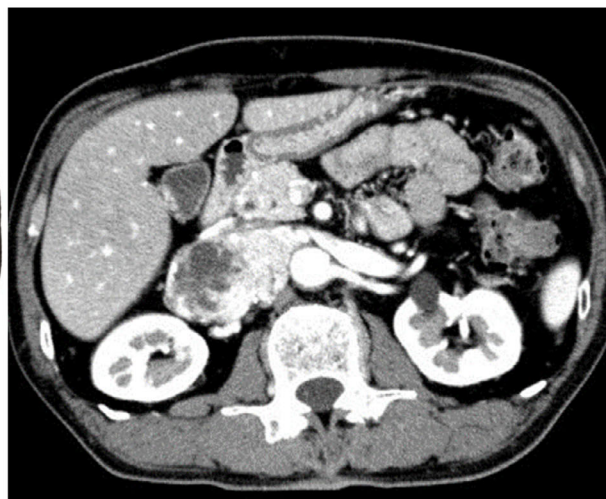
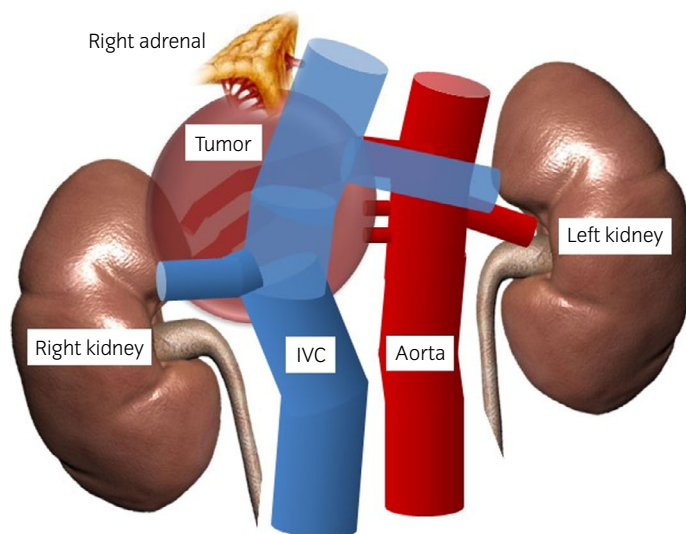


Fig. 1 Schema and CT scan of the present case. An approximately 7-cm tumor with high vascularity was located immediately behind the IVC and bilateral renal veins, on the ventral side of the right renal artery and on the right side of the abdominal aorta.

Fig. 2 ^{123}I -MIBG scintigraphy revealed high uptake in the tumor.

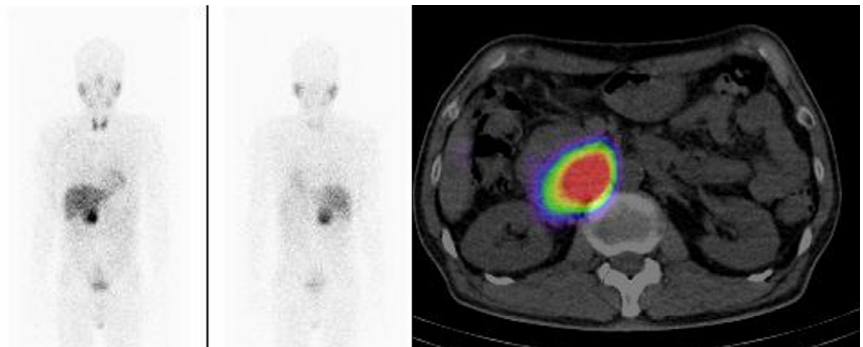


Fig. 3 Intraoperative findings during tumor resection and port placement. After mobilizing the ascending colon and duodenum, the tumor (white dotted line) was found to be squeezing the IVC and bilateral renal veins (yellow lines) from the posterior side.

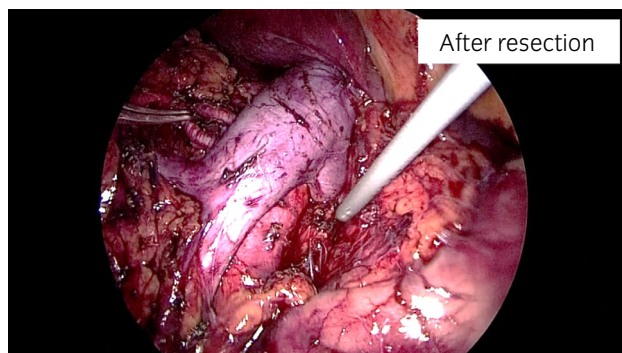
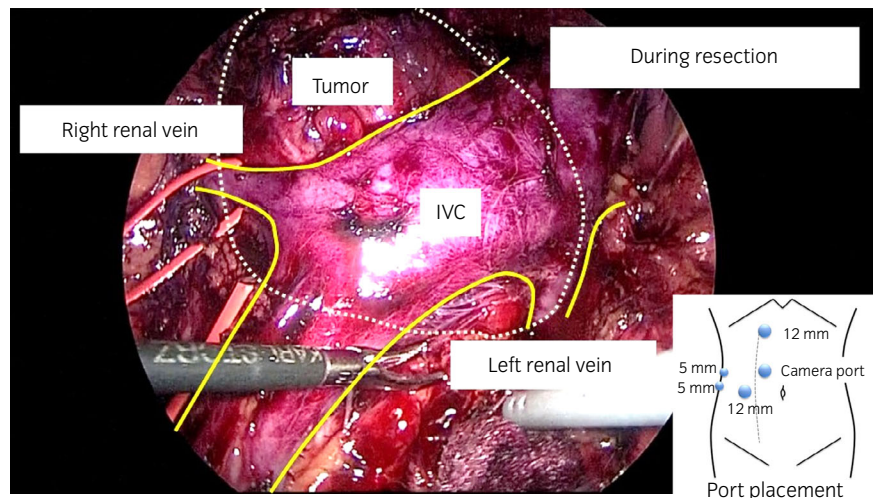


Fig. 4 Intraoperative findings after tumor resection. The tumor was removed completely with no complications.

Bacalbasa *et al.*² reported a case involving invasion of the celiac artery in which the paraganglioma and celiac artery were resected *en bloc* and the common hepatic artery was anastomosed to the abdominal aorta. Ogawa *et al.*³ described a paraganglioma arising on the back of Spiegel's lobe in a woman with kyphosis, and resection was performed by laparoscopic surgery. Heinze *et al.*⁴ reported laparoscopic one-step resection of suspected paragangliomas that had not been preoperatively diagnosed. Additionally, Cai *et al.*⁵ reported a paraganglioma involving the renal hilum that was

resected under robot-assisted surgery. These reports suggest that resection of paragangliomas is relatively difficult.

However, several reports have described the safety of laparoscopic surgery for retroperitoneal tumors,^{6,7} indicating that the laparoscopic approach is feasible in experienced hands. In our hospital, laparoscopic surgery is usually performed by an operator who is proficient in retroperitoneal tumor resection.

In the present case, the most difficult and dangerous step in the surgical procedure seemed to be the dissection of the tumor from the IVC. Therefore, to safely release the tumor from the back of the IVC, we dissected the tissue around the tumor and obtained tumor mobility before manipulation of the IVC. Additionally, the tumor was sandwiched between the right renal vein (ventral side of the tumor) and right renal artery (dorsal side of the tumor), and these vessels had to be preserved. Dissection of the right renal artery from the tumor was the last step of the procedure because the right renal artery was present on the dorsal-most side. Thus, we flipped the tumor from the head side to the cauda side to observe the posterior surface of the tumor after dissection of the tumor from the IVC. To avoid damage during these operations, we secured the main blood vessels with vascular tape during the procedure. Additionally, the CT and magnetic resonance imaging findings were carefully evaluated before surgery, and we discussed the surgical strategy in a preoperative

conference. Through careful preoperative planning, surgical safety was secured and complications avoided.

In this case, we chose the transperitoneal approach. Shiraishi *et al.*⁸ reported that the retroperitoneal approach is feasible, safer, and faster than the transperitoneal approach for large right-sided adrenal pheochromocytomas because early transection of the feeding artery is beneficial to managing the tumor and reducing the risk of bleeding. However, for paragangliomas such as those in our case, we choose the transperitoneal approach over the retroperitoneal approach because it can provide a wide operative space, preparations for open conversion can be simultaneously made during the surgical procedure, we can more easily recognize the anatomical relationship between the tumor and abdominal organs, and hand-assisted surgery is inappropriate when securing a wide operative space.

Preoperative alpha blockage is necessary to avoid a hypertensive crisis in cases such as this.

Conclusion

We herein described a patient with a paraganglioma immediately behind the IVC and bilateral renal veins that was successfully resected by laparoscopic surgery. This is the first reported case to illustrate the feasibility of the laparoscopic approach for such a paraganglioma.

Acknowledgment

We thank Angela Morben, DVM, ELS, from Edanz Group (www.edanzediting.com/ac), for editing a draft of this manuscript.

Conflict of interest

The authors declare no conflict of interest.

References

- 1 Feng N, Zhang WY, Wu XT. Clinicopathological analysis of paraganglioma with literature review. *World J. Gastroenterol.* 2009; **15**: 3003–8.
- 2 Bacalbasa N, Balescu I, Tanase A *et al.* Successful resection of a non-functional paraganglioma with celiac trunk invasion followed by common hepatic artery reimplantation – a case report and literature review. *In Vivo* 2018; **32**: 911–4.
- 3 Ogawa H, Nakahira S, Kishimoto T *et al.* Laparoscopic resection of retroperitoneal paraganglioma behind the Spiegel lobe in a kyphotic patient: a rare case report. *Asian J. Endosc. Surg.* 2018; <https://doi.org/10.1111/ases.12631>.
- 4 Heinze A, Nikomanis P, Petzold F *et al.* Undiagnosed paraganglioma: a challenge during laparoscopic retroperitoneal resection. *Arch. Ital. Urol. Androl.* 2019; **90**: 297–8.
- 5 Cai PY, Golan R, Yanke B *et al.* Retroperitoneal paraganglioma involving the renal hilum: a case report and literature review. *Urology* 2018; **122**: 24–7.
- 6 Abe T, Sazawa A, Harabayashi T *et al.* Laparoscopic resection of paraaortic/paracaval neurogenic tumors: surgical outcomes and technical tips. *Surg. Endosc.* 2016; **30**: 4640–5.
- 7 Ping W, HongZhou M, Jie Q *et al.* Laparoscopic resection of retroperitoneal paragangliomas: a comparison with conventional open surgical procedures. *J. Endourol.* 2016; **30**: 69–74.
- 8 Shiraishi K, Kitahara S, Ito H *et al.* Transperitoneal versus retroperitoneal laparoscopic adrenalectomy for large pheochromocytoma: comparative outcomes. *Int. J. Urol.* 2019; **26**: 212–6.