

# Emergency endovascular coiling of a ruptured giant splenic artery aneurysm

Erika Wernheden, MD,<sup>a</sup> Anne-Sofie Brenøe, MD,<sup>b</sup> and Saeid Shahidi, MD,<sup>a</sup> *Slagelse and Odense, Denmark*

## ABSTRACT

Splenic artery aneurysms (SAAs) are the third most common abdominal aneurysm. Endovascular treatment of SAAs is preferred, and coiling is the most commonly used technique. Ruptured giant (>5 cm) SAAs are usually treated with open surgery including splenectomy. We present a rare case of a ruptured 15-cm giant SAA in an 84-year-old woman treated successfully with emergency endovascular coiling. To our knowledge, this is one of the few reports of emergency endovascular treatment for ruptured giant SAA. (*J Vasc Surg Cases and Innovative Techniques* 2017;3:240-2.)

Splenic artery aneurysms (SAAs) are the most common of the visceral aneurysms and the third most common abdominal aneurysm after aortic and iliac aneurysms. SAAs are four times more common in women than in men, and 80% occur in patients older than 50 years.<sup>1</sup> They are usually solitary, saccular, and localized to the distal third of the artery.<sup>2</sup> False SAAs can occur, for example, in association with pancreatitis or instrumentation.<sup>3</sup>

True SAAs are associated with conditions of increased flow, such as pregnancy, arterial venous fistulas and malformations, and portal hypertension.<sup>4</sup> The reported prevalence of SAAs varies according to the group of patients. In women of childbearing age, the prevalence is <0.1%.<sup>5</sup> By contrast, the prevalence of SAA in patients with liver cirrhosis and portal hypertension is 7% to 20%.<sup>4</sup>

SAAs are often asymptomatic and in most cases (80%) diagnosed incidentally in relation to radiologic intervention.<sup>2</sup> We present a case of a 15-cm large ruptured SAA treated with embolization. The patient has given her consent to the publication of this report.

## CASE REPORT

An 84-year-old woman with a history of paroxysmal atrial fibrillation and hypertension was admitted to the emergency department after being found unconscious with a Glasgow Coma Scale score of 4. On arrival at the emergency department, the patient was awake; she had a Glasgow Coma Scale score of 15 and complained of abdominal and lower back pain. She was pale and hypotensive, with an initial blood

pressure of 80/45 mm Hg, which dropped briefly to a systolic pressure of 56 mm Hg but increased with the Trendelenburg position. Clinical examination showed abdominal distention and diffuse abdominal tenderness. Hemoglobin level was 8.7 g/dL, and lactate level was 52 mg/dL. The patient was receiving anticoagulant therapy with warfarin, but the international normalized ratio was within the therapeutic level at 2. Gastrointestinal bleeding was initially suspected, and the patient received 3 units of blood and Octaplex (human prothrombin complex; Octapharma, Vienna, Austria). Bedside ultrasound examination showed free fluid in the abdomen and a large inhomogeneous cavity.

Computed tomography (CT) angiography was performed and revealed a 15- × 12-cm large SAA with signs of rupture (Fig 1). The lower wall of the aneurysm was not clearly defined, and there was free fluid or hematoma in the abdomen around the liver and in the fossa of Douglas.

Based on the anatomy of the aneurysm and the patient's age, it was determined that the aneurysm could be treated endovascularly. The patient was acutely transported to Odense University Hospital, where acute endovascular treatment is available. Total time of transport was about 40 minutes. During transportation, the patient's blood pressure dropped to a systolic pressure of 70 mm Hg, and she received another unit of blood. On arrival, the patient further received 4 units of blood and blood components and became more hemodynamically stable. The patient was sedated and intubated after arrival.

## PROCEDURE

Abdominal angiography was performed through the right femoral artery, and selective angiography of the celiac trunk showed an abnormal-looking splenic artery, which on the previous CT angiogram was seen to supply the aneurysm. The inflow to the SAA was embolized by placing microcoils in the splenic artery proximal to the aneurysm, with smaller coils placed within larger ones to completely occlude the artery (Fig 2). It was not technically possible to selectively visualize the outflow of the aneurysm, but to ensure that there was no backperfusion into the aneurysm, selective angiography of the left gastric artery, the gastroduodenal artery, and the pancreaticoduodenal artery was performed. This showed

From the Department of Vascular Surgery, Slagelse Hospital, Slagelse<sup>a</sup>; and the Department of Radiology, Odense University Hospital, Odense.<sup>b</sup>

Author conflict of interest: none.

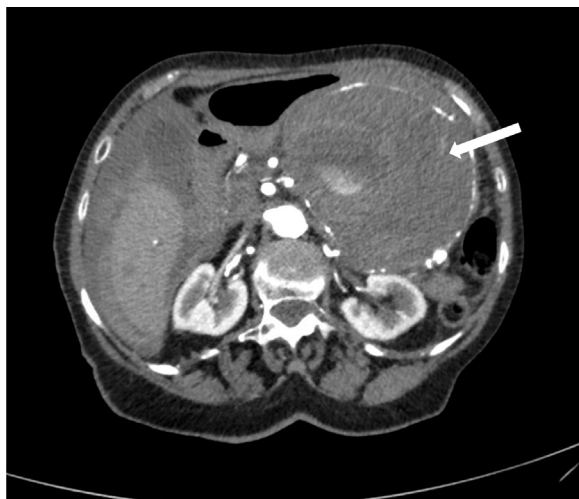Correspondence: Erika Wernheden, MD, Department of Vascular Surgery, Slagelse Hospital, Faelledvej 13, Slagelse 4200, Denmark (e-mail: [erika.w@hotmail.com](mailto:erika.w@hotmail.com)).

The editors and reviewers of this article have no relevant financial relationships to disclose per the Journal policy that requires reviewers to decline review of any manuscript for which they may have a conflict of interest.

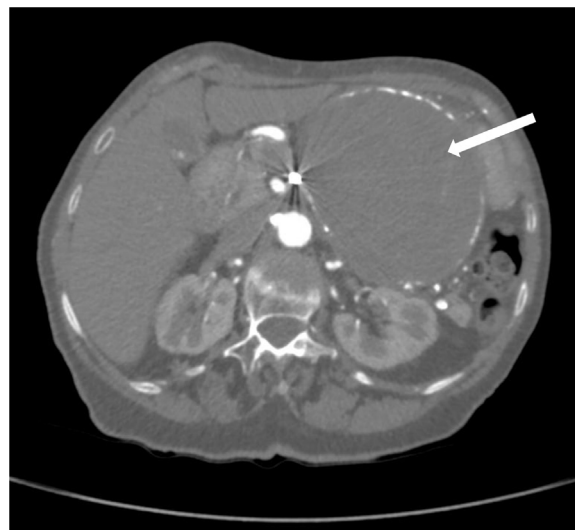
2468-4287

© 2017 The Authors. Published by Elsevier Inc. on behalf of Society for Vascular Surgery. This is an open access article under the CC BY-NC-ND license (<http://creativecommons.org/licenses/by-nc-nd/4.0/>).

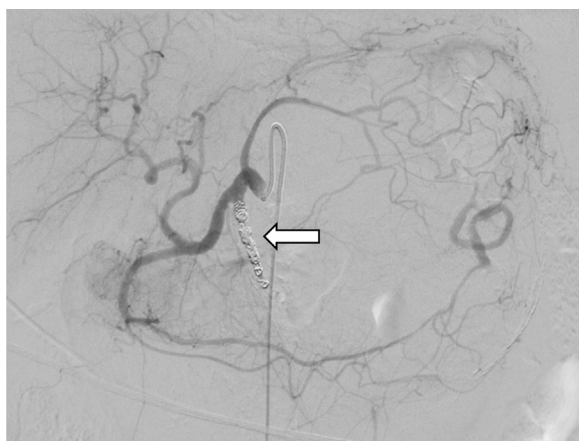
<https://doi.org/10.1016/j.jvscit.2017.10.008>



**Fig 1.** Computed tomography (CT) angiogram with the ruptured splenic artery aneurysm (SAA) and free fluid in the abdomen around the liver and in the fossa of Douglas.



**Fig 3.** Control computed tomography (CT) angiogram 3 months postoperatively.



**Fig 2.** Postembolization angiography without contrast fluid in the splenic artery aneurysm (SAA).

collateral vessels lateral to the aneurysm, and these were also embolized with microcoils. Nester coils (Cook Medical, Bloomington, Ind; size 18, 7, 3 and 18, 14, 4), VortX Diamond coils (Boston Scientific, Marlborough, Mass; size 3, 3.3), and Figure coils (Boston Scientific; size 2, 5 mm) were used.

Control angiography at the end of the procedure showed no filling of the aneurysm with contrast material.

### POSTOPERATIVE COURSE

Postoperatively, the patient was treated in the intensive care unit for 3 days because of high-frequency atrial fibrillation, atelectasis, infection, and decreased diuresis. Hemoglobin level was stable throughout the postoperative recovery, without the need for further blood transfusions. The patient was transferred to the general ward and discharged on postoperative day 10. There were no compressive symptoms.

Three months postoperatively, a control CT angiogram (Fig 3) showed that the aneurysm had shrunk to 13 × 11 cm. It also showed that the spleen was well perfused, although a hypodense area that could represent an infarction of the spleen was observed. There was no coil migration.

### DISCUSSION

Rupture of an SAA is associated with severe abdominal pain and hemodynamic instability and requires acute intervention. There are only a few reports of endovascular treatment of ruptured giant SAA as ruptured SAAs are usually treated with surgery including splenectomy.

Endovascular treatment is gentler and has a lower perioperative morbidity compared with open surgery.<sup>6</sup> Although endovascular treatment is increasingly performed and preferred to open surgery if possible, it is primarily used in smaller and nonruptured SAAs.<sup>2,6</sup> Coiling is the most frequently used endovascular technique; other options are covered stent and glue embolization. Covered stent has the advantage that it preserves splenic perfusion, although anatomic challenges, such as tortuous arteries, limit the application of this technique.<sup>2,7</sup> The recommended technique in embolization is to place coils both proximal and distal to the aneurysm or alternatively to place large coils within the aneurysm.

In this case, we assessed that the aneurysm was too large to be packed with coils, and we were not able to visualize the distal part of the artery. Besides proximal embolization, collateral vessels lateral to the aneurysm were found and embolized to prevent backperfusion. Furthermore, Herskowitz et al<sup>8</sup> previously presented a case of successful treatment of a giant nonruptured SAA solely by proximal embolization.

Endovascular treatment was considered the first choice in this case as the patient was elderly and the aneurysm was found to be accessible for endovascular coiling.

As the literature on treating ruptured SAAs, especially of this size, is limited, there is no consensus for optimal management at present, although there is a general consensus on the indication for intervention in patients with symptomatic aneurysms and all aneurysms with a diameter >2 cm. The choice of treatment depends on anatomic characteristics, local expertise, and the individual's preference.

## CONCLUSIONS

To our knowledge, this is one of a few reports on emergency endovascular treatment of a giant ruptured SAA. Endovascular treatment is gentler compared with open surgery in elderly patients and can be performed with local anesthesia. We suggest considering endovascular treatment as the first choice in these cases, depending on local expertise and anatomic characteristics.

## REFERENCES

1. Abbas MA, Stone WM, Fowl RJ, Gloviczki P, Oldenburg WA, Pairolero PC, et al. Splenic artery aneurysms: two decades experience at Mayo Clinic. *Ann Vasc Surg* 2002;16:442.
2. Akbulut S, Otan E. Management of giant splenic artery aneurysm: comprehensive literature review. *Medicine (Baltimore)* 2015;94:e1016.
3. Dave SP, Reis ED, Hossain A, Taub PJ, Kerstein MD, Hollier LH. Splenic artery aneurysm in the 1990s. *Ann Vasc Surg* 2000;14:223-9.
4. Pulli R, Dorigo W, Troisi N, Pratesi G, Innocenti AA, Pratesi C. Surgical treatment of visceral artery aneurysms: a 25-year experience. *J Vasc Surg* 2008;48:334-42.
5. McMahon DP, Ward WH, Harwood JL, Moore EM. An institutional review of splenic artery aneurysm in childbearing-aged females and splenic artery aneurysm rupture during pregnancy. Is screening justified? *Mil Med* 2012;177:96-8.
6. Björck M, Koelemay M, Acosta S, Bastos Goncalves F, Kölbl T, Kolkman JJ, et al. Editor's choice—management of the diseases of mesenteric arteries and veins: clinical practice guidelines of the European Society of Vascular Surgery (ESVS). *Eur J Vasc Endovasc Surg* 2017;53:460-510.
7. Pescarus R, Montreuil B, Bendavid Y. Giant splenic artery aneurysms: case report and review of the literature. *J Vasc Surg* 2005;42:344-7.
8. Herskowitz MM, Safriel Y, Gillego V. Successful treatment of a giant splenic artery aneurysm solely by proximal coil embolisation. *EJVES Extra* 2002;3:52-3.

Submitted Jun 9, 2017; accepted Oct 24, 2017.