



## Takotsubo cardiomyopathy in an 81-year-old woman after injection of bone cement during hemiarthroplasty: An orthogeriatric case report



Paolo Mazzola<sup>a,b,\*</sup>, Domenico Picone<sup>a</sup>, Alessandra Anzuini<sup>a</sup>, Maurizio Corsi<sup>a</sup>, Giuseppe Bellelli<sup>a,b</sup>, Giorgio Annoni<sup>a,b</sup>

<sup>a</sup> Department of Medicine and Surgery, University of Milano-Bicocca and Geriatric Clinic, San Gerardo University Hospital, 20900 Monza-MB, Italy

<sup>b</sup> NeuroMI-Milan Center for Neuroscience, Clinical Neurosciences Research Area, 20126 Milano-MI, Italy

### ARTICLE INFO

#### Article history:

Received 20 May 2015

Received in revised form

24 November 2015

Accepted 24 November 2015

Available online 27 November 2015

#### Keywords:

Takotsubo

Transient cardiomyopathy

Hip fracture

Elderly

Orthogeriatric

### ABSTRACT

**INTRODUCTION:** Takotsubo cardiomyopathy is a syndrome characterized by transient cardiac ischemia-like symptoms, such as chest pain, increase of myocardial necrosis markers, electrocardiographic changes, and temporary left ventricular apical ballooning without significant coronary artery disease, often triggered by a particularly stressful situation. The association between Takotsubo and hip fracture surgery has been rarely reported in the literature.

**PRESENTATION OF CASE:** An 81-year-old woman was hospitalized with a diagnosis of right femoral neck fracture. During the surgical procedure, she displayed acute coronary symptoms a few minutes after the injection of bone cement, in the absence of coronary lesions. Due to the time relationship, bone cement implantation syndrome – not uncommon to observe – was considered in the differential diagnosis. However, the instrumental findings and the transient nature of the abnormalities guided us toward a diagnosis of Takotsubo. The treatment with Levosimendan, Amiodarone, and Metoprolol allowed gradual and satisfactory recovery of the cardiac function within a few days. The follow-up performed two and six months after surgery revealed complete cardiac recovery, and ability to walk at home comparable to the pre-fracture situation.

**DISCUSSION:** Takotsubo cardiomyopathy is more common in women during the postmenopausal phase, especially if undergoing stressful physical or emotional stimuli. In this case, the sequence of hip fracture, pain, hospitalization, and surgery could easily be intended as a strong stressful event with high physical/psychological burden.

**CONCLUSION:** Despite the good prognosis associated with early recognition, Takotsubo represents a life-threatening adverse event. Considering its possible pathogenesis, a “gentle care” approach and the optimization of pain control must be pursued in elderly subjects with hip fracture, aiming at reducing the stress of the hospitalization and related procedures.

© 2015 Published by Elsevier Ltd. on behalf of IJS Publishing Group Ltd. This is an open access article under the CC BY-NC-ND license (<http://creativecommons.org/licenses/by-nc-nd/4.0/>).

### 1. Introduction

Takotsubo [1] cardiomyopathy, or “transient apical ballooning syndrome”, is a non-ischemic cardiomyopathy that mimics the onset of an acute myocardial infarction. Its incidence was recently reported to be 1.7–2.2% among patients presenting with acute coronary syndrome [2]. Takotsubo is also called “broken heart syndrome” because a strong emotional psychological stress may act as a potential trigger. Originally described in Japan in 1990, its eponym

was coined using the two Japanese terms *tako* (octopus) and *tsubo* (pot), due to the resemblance between the cardiac apical ballooning (hallmark of the syndrome) and the octopus trap (a kind of ceramic pot) used by Japanese fishermen [3].

The acute functional and instrumental abnormalities accompanying Takotsubo cardiomyopathy occur in the absence of significant coronary alterations, and could be completely recovered within a few weeks up to two months [4]. If promptly recognized and correctly managed, despite the severity of its onset and the potentially life-threatening characteristics (those of a cardiogenic shock), this syndrome normally presents a good prognosis with low morbidity and in-hospital mortality rates [2,5,6]. This paper reports a rare case of association between Takotsubo and hip fracture surgery, which has been described only by two previous studies [7,8]. The present case has been reported in line with the CARE guidelines [9].

\* Corresponding author at: Department of Medicine and Surgery, University of Milano-Bicocca, via Cadore 48, 20900 Monza (MB), Geriatric Clinic, San Gerardo University Hospital, via Pergolesi 33, 20900 Monza (MB), NeuroMI-Milan Center for Neuroscience, 20126 Milano (MI), Italy. Fax: +39 039 233 2220.

E-mail addresses: [paolo.mazzola@unimib.it](mailto:paolo.mazzola@unimib.it), [paolo.mazzola@gmail.com](mailto:paolo.mazzola@gmail.com) (P. Mazzola).

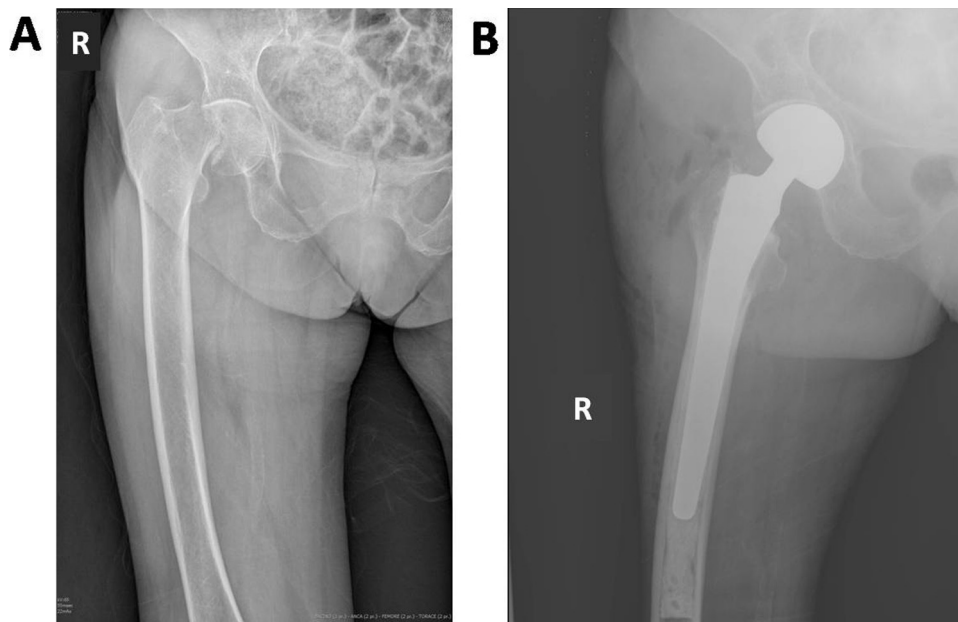


Fig. 1. Plain X-ray of the right hip (antero-posterior view) showing femoral neck fracture before (A) and after (B) the surgical procedure.

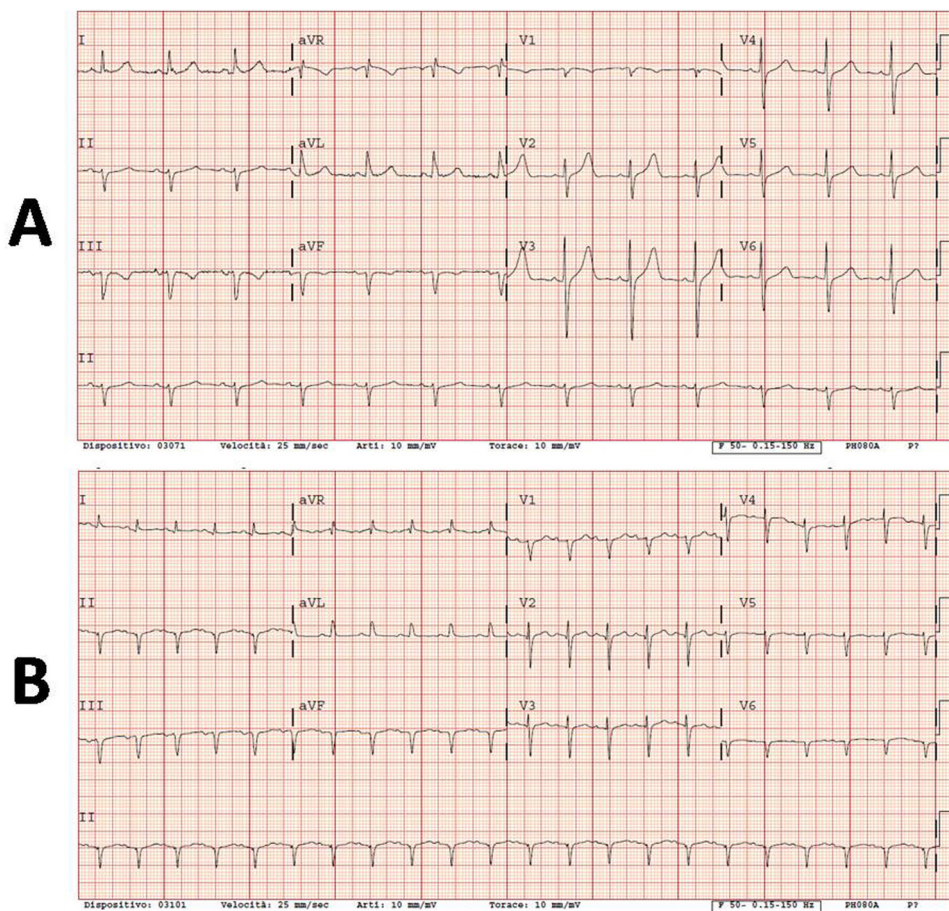


Fig. 2. Electrocardiograms of the patient performed on admission (A), and after resuscitation post-Takotsubo (B). After the event (B), the electrocardiographic tracing evidenced signs of myocardial infarction in the inferior leads.

**2. Presentation of case**

The female patient we describe, an 81-year-old Caucasian woman living at home with a son, was completely independent

in Katz’s basic activities of daily living (ADL [10]=6/6) and Lawton’s instrumental activities of daily living scales (IADL [11]= 8/8) before the hospitalization. Her clinical history evidenced osteoporosis with multiple previous vertebral incomplete collapses, in

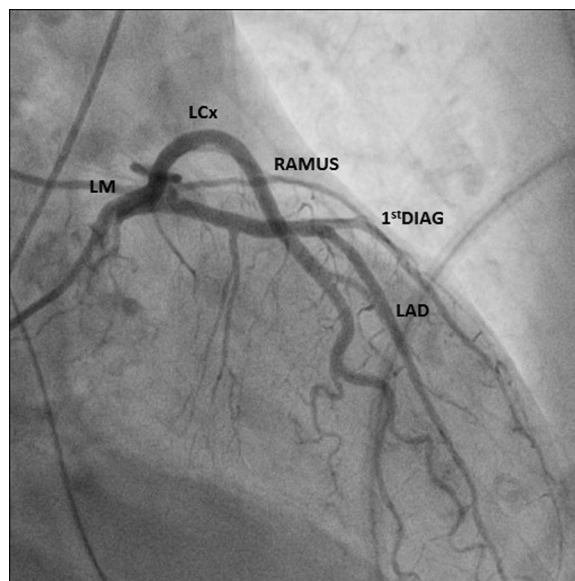
treatment with oral calcium and vitamin D, hypertension controlled with ramipril, and dyslipidemia for which she took statins. Her son reported an anxious temperament, but she was never pharmacologically treated. She had no cognitive decline (normal score at IQCODE questionnaire [12]), allergies, or weight loss.

The woman was admitted during night time in the Emergency Department (ED) of San Gerardo University Hospital after an accidental fall at home, reporting trauma of the right hip. The X-ray showed a right upper cervical femur fracture (Fig. 1A) and partial collapse of multiple vertebrae, the latter without evidence of recent fractures. No significant abnormalities were reported at the blood examinations (*i.e.*, blood count, electrolytes, liver and kidney function indexes, protein electrophoresis, coagulation parameters, blood gases) or at the standard electrocardiogram (ECG, Fig. 2A). The patient was firstly admitted in the orthopedic ward, and then transferred to the orthogeriatric unit (OGU, within the Geriatric ward) the day after, once the geriatricians confirmed the eligibility criteria for admission.

The comprehensive geriatric assessment did not reveal cognitive deterioration or delirium (4AT score [13] = 2/12). The pain was on average well controlled with the standard protocol of treatment (acetaminophen 1 g three times intravenously/day). After the evaluation of the anesthetist, she was scheduled for surgery (A.S.A. score = 2), which was performed 60 h after the admission. The woman underwent a right cemented hemiarthroplasty procedure under spinal anesthesia. Ten minutes after the injection of cement, when the orthopedic surgeons were performing haemostatic maneuvers and a check of joint movements, the surgical act was complicated by severe bradycardia and cardiogenic shock with consequent cardio-pulmonary arrest. Without perturbing the sterility of the surgical site, the patient was placed supine and promptly treated with cardiopulmonary resuscitation maneuvers, oro-tracheal intubation, and intravenous administration of atropine and epinephrine, obtaining return of spontaneous circulation after 7 min. The ECG showed signs of myocardial infarction in the inferior leads (Fig. 2B). Upon restoration of spontaneous circulation, the surgical procedure was completed with saline washing, local instillation of tranexamic acid, layered suture, and plain medication with plaster.

The first suspected diagnosis, considering the time relationship with cement injection, was “bone cement implantation syndrome (BCIS)”. The patient was then transferred from the operating theater to the intensive care unit (ICU), where Dopamine (5.33 mcg/kg/min, increased to 16 mcg/kg/min) and Norepinephrine (0.06–0.13 mcg/kg/min) were administered intravenously reaching treatment maximization. Hydroelectrolytic solutions (3500 mL) were infused to increase the circulating volume and furosemide 40 mg iv was administered to stimulate the diuresis. In the absence of clinical benefits, due to the persistence of hypotension (systolic blood pressure = 80 mmHg, mean arterial pressure = 50 mmHg) and the presence of sinus tachycardia, the anesthetist added bisoprolol 1.25 mg four times/day.

The echocardiography revealed akinesia of the apex and the mid segment of the septum, extending to the anterior and infero-lateral cardiac wall, accompanied by apical ballooning and significant reduction of the left ventricular ejection fraction (LVEF = 25%–30% during amine iv infusion). The coronary angiography (Fig. 3) did not show significant stenosis or structural abnormalities. Additional examinations excluded the presence of cerebrovascular diseases, myocarditis, hypertrophic cardiomyopathy, and pheochromocytoma. These results oriented toward a diagnosis of Takotsubo syndrome, so that the cardiologist prescribed iv treatment with heparin (2000 UI in bolus + 20,000 UI in 24 h), gradually reduced and discontinued the aminic support, and positioned an intraortic balloon pump.



**Fig. 3.** Coronary angiography performed in the ICU, which did not show significant coronary stenosis or structure abnormalities potentially likely to determine myocardial infarction (LM: left main stem, LCx: left circumflex, LAD: left anterior descending, 1<sup>st</sup>DIAG: first diagonal, RAMUS: ramus intermedius).

The day after surgery, despite an observed initial reduction of the Troponin T levels (cTnT = 185 ng/mL after 24 h, 154 ng/mL after 32 h), the echocardiography showed further reduction of the LVEF (20%) with apical akinesia *in toto*. The finding of anemia (Hb = 8.5 g/dL, MCV = 78.5 fL) was corrected with the transfusion of 2 units of concentrated red blood cells.

On the second post-operative day, considering the persistence of low cardiac output and atrial tachycardia, the patient started iv treatment with Levosimendan 0.1 mcg/kg/min for 7 h, Amiodarone 907 mcg/day and Metoprolol 2 mg, with gradual amelioration of cardiac output and heart rate. During the third post-operative day we discontinued iv treatment with heparin, we removed the intraortic balloon pump and the oro-tracheal device, supporting the patient with low-intensity oxygen by mask. Treatment with Amiodarone was shifted from intravenous to oral administration. Therapy with Acetylsalicylic acid 100 mg/day and Captopril 6.25 mg three times/day was initiated.

On the fourth post-operative day the blood pressure reached the normal range. Captopril oral administration was optimized (25 mg three times/day). The recovery of consciousness was overall satisfactory. We report a single episode of hyperactive delirium occurred during the night, efficiently managed with the administration of Haloperidol 2 mg intramuscular + Quetiapine 50 mg *per os*.

During the fifth post-operative day she was transferred to the cardiology ICU, where she underwent echocardiography re-evaluation that showed significant restore of the contractile function (LVEF = 56%). On the seventh post-operative day the patient was transferred back to the OGU, where she started specific physical therapy oriented towards passive and active mobilization of the right leg, achievement and maintenance of the standing position, and ambulation with the support of a walker. Before discharge, the hemoglobin levels were stabilized (Hb = 12.3 g/dL). During the hospital stay, the treatments and instrumental evaluations were overall well tolerated by the patient.

She was discharged sixteen days after the operation and the Takotsubo syndrome, in good physical and mental conditions (MMSE score [14] before discharge = 25/30), able to walk

(walker + supervision) without pain in the surgical area. She went back home with a schedule of domiciliary physiotherapy.

The follow-up performed two months after surgery revealed absence of cardiac symptoms and good recovery of the walking ability with a walking stick. We suggested to continue strengthening the lower limb muscles with domiciliary physiotherapy and allowed walking without any aid. At the 6-month follow-up, the woman was still asymptomatic from a cardiovascular point of view. She reached a functional level comparable with the pre-fracture status (Katz's ADL = 6/6, Lawton's IADL = 7/8). She was able to walk without aids at home, but she needed a walking stick when going outside because of a residual fear of falling. Finally, the echocardiogram confirmed good cardiac function (LVEF = 55%) in the absence of other abnormalities. Her son, the caregiver living with her, confirmed an overall good functional and nutritional status and no signs of cognitive decline compared with the pre-fracture status.

### 3. Discussion

The patient fulfills several criteria for a diagnosis of Takotsubo syndrome: physically stressful event as a trigger, female elderly patient (at higher risk than young subjects and males), apical ballooning with akinesia (echocardiogram), ST-segment alterations immediately after the onset (electrocardiogram), lack of significant coronary artery stenosis, recovery of the left ventricular function [15]. Indeed, approximately 90% of the cases occur in the female population, mostly between 58 and 75 years of age, though it is not uncommon among older individuals [16,17].

In this case report, the symptomatology seemed to be triggered by the injection of pressurized cement during the hemiarthroplasty procedure, mimicking a BCIS of grade 3 (the more severe grade) with acute myocardial infarction, accompanied by the classic instrumental cardiac findings. BCIS was previously reported to be a sporadic adverse event of bone cement injection, still incompletely understood, and was defined only recently [18]. It is characterized by the association of multiple signs of different severity, which contribute to a heterogeneous presentation: hypoxia, hypotension, alteration of vascular pulmonary resistance, cardiac arrhythmias, and cardiac arrest [18]. However, in this case, the coronary angiography did not show major obstructions or arterial abnormalities, and the echocardiography did not demonstrate the presence of emboli, thus suggesting a different diagnosis and orienting the physicians toward Takotsubo cardiomyopathy. The instrumental alterations resulted to be transient and recovered in the following days.

This is the second case of Takotsubo we recently encountered in our medical practice, the first being described in 2012 in an 80-year-old woman with severe Alzheimer's disease [17]. Pathophysiological mechanisms underlying Takotsubo are still not well understood, and the reported cases suggest a number of potential etiologies. In several cases a multifactorial mechanism might be involved, and different variants of the classic Takotsubo syndrome have been progressively described [19–21]. Altogether, a single pathophysiological mechanism does not clarify the existence of several Takotsubo's variants.

Hospitalization is a stressful event *per se* among the elderly. Hip fracture and the related surgery are even more stressful experiences: healthcare professionals working in this area should be aware of the severe physical (pain, immobility, functional disability) and psychological/emotional (transfers, total dependence, anxiety) burden that affects the geriatric population.

Strength of our approach was the availability and coordination of multiple specialists as consultants 24/24 h, with the geriatrician as the primary attendant according to our orthogeriatric protocol of co-management. These allowed to set up promptly the necessary

support therapies and instrumental evaluations in order to identify the potentially life-threatening diagnosis. Limitations include the initially wrong diagnostic orientation and the resources required to complete the differential diagnosis before confirming the Takotsubo.

### 4. Conclusion

Despite being a rare condition, Takotsubo syndrome is a possible differential diagnosis of the BCIS, which recently emerged – regardless its severity – as a frequent complication of surgical orthopedic procedures involving the pressurized injection of bone cement, with a prevalence of about 25–30% [22,23]. Moreover, Porto et al. [24] recently reviewed the correlation between neurologic disorders and transient left ventricular dysfunction, called neurogenic stunned myocardium and characterized by findings which resemble the classic Takotsubo cardiomyopathy. The authors concluded that the available literature suggests treating them as different entities.

To the best of our knowledge, the association of Takotsubo syndrome with hip fracture in the preoperative phase [7] or after surgery [8] has been rarely reported (two cases).

Takotsubo syndrome represents a life-threatening adverse event. Considering its possible pathogenesis, the correct management of elderly subjects could potentially reduce the stress experience related with hip fracture. Promoting the “gentle care” approach and optimizing pain control is mandatory in this age group.

### Conflict of interest

None.

### Funding

The authors declare that the present manuscript was unfunded.

### Ethical approval

Informed consent for the acquisition of data to present in this case report was obtained during the hospitalization, and signed by the patient itself. The consent form is stored in the archive of San Gerardo University hospital (Monza, Italy). This report was approved by the Ethics Committee of the same hospital.

### Consent

Written informed consent was obtained from the patient for publication of this case report and accompanying images. A copy of the written consent is available for review by the Editor-in-Chief of this journal on request. All demographic and patient-specific personal information have been de-identified according to the Italian law for the privacy and protection of personal information (“Codice in materia di protezione dei dati personali, D. Lgs. n.196/2003”).

### Authors' contributions

DP, MC, and GB took care of the patient during the hospitalization and obtained informed consent for this report. DP, PM, GB and GA designed the case report. PM, AA, and MC reviewed the literature. PM, DP, and AA collected the data from the hospital charts. PM, DP, and AA drafted the manuscript. MC, GB, and GA critically revised the manuscript. All authors have read and approved the final version of this manuscript.

## Guarantor

Guarantors for this manuscript are Dr. P. Mazzola, MD, and Prof. G. Annoni, MD.

## Acknowledgment

Sincere appreciation to Justin S. Brathwaite, BA, for reviewing the English version of this manuscript.

## References

- [1] K. Dote, H. Sato, H. Tateishi, T. Uchida, M. Ishihara, Myocardial stunning due to simultaneous multivessel coronary spasms: a review of 5 cases, *J. Cardiol.* 21 (2) (1991) 203–214.
- [2] P. Eshtehardi, S.C. Koestner, P. Adorjan, et al., Transient apical ballooning syndrome-clinical characteristics, ballooning pattern, and long-term follow-up in a Swiss population, *Int. J. Cardiol.* 135 (July 3) (2009) 370–375.
- [3] S. Kurisu, Y. Kihara, Tako-tsubo cardiomyopathy: clinical presentation and underlying mechanism, *J. Cardiol.* 60 (December 6) (2012) 429–437.
- [4] Z.R. Brenner, J. Powers, Takotsubo cardiomyopathy, *Heart Lung* 37 (January–February (1)) (2008) 1–7.
- [5] S. Kurisu, Y. Kihara, Clinical management of takotsubo cardiomyopathy, *Circ.* J. 78 (June (7)) (2014) 1559–1566.
- [6] T.M. Pilgrim, T.R. Wyss, Takotsubo cardiomyopathy or transient left ventricular apical ballooning syndrome: a systematic review, *Int. J. Cardiol.* 124 (March (3)) (2008) 283–292.
- [7] M.J. Daly, L.J. Dixon, Takotsubo cardiomyopathy in two preoperative patients with pain, *Anesth. Analg.* 110 (March (3)) (2010) 708–711.
- [8] B.H. Joe, H.J. Hwang, C.B. Park, et al., Takotsubo cardiomyopathy recurrence with left ventricular apical ballooning following isolated right ventricular involvement: a case report, *Exp. Ther. Med.* 6 (July 1) (2013) 260–262.
- [9] J.J. Gagnier, G. Kienle, D.G. Altman, D. Moher, H. Sox, D. Riley, The CARE guidelines: consensus-based clinical case report guideline development, *J. Clin. Epidemiol.* 67 (January (1)) (2014) 46–51.
- [10] S. Katz, T.D. Downs, H.R. Cash, R.C. Grotz, Progress in development of the index of ADL, *Gerontologist* Spring 10 (1) (1970) 20–30.
- [11] M.P. Lawton, E.M. Brody, Assessment of older people: self-maintaining and instrumental activities of daily living, *Gerontologist* Autumn 9 (3) (1969) 179–186.
- [12] A.F. Jorm, A short form of the informant questionnaire on cognitive decline in the elderly (IQCODE): development and cross-validation, *Psychol. Med.* 24 (February (1)) (1994) 145–153.
- [13] G. Bellelli, A. Morandi, D.H. Davis, et al., Validation of the 4AT, a new instrument for rapid delirium screening: a study in 234 hospitalised older people, *Age Ageing* (March (14)) (2014).
- [14] M.F. Folstein, S.E. Folstein, P.R. McHugh, Mini-mental state: a practical method for grading the cognitive state of patients for the clinician, *J. Psychiatr. Res.* 12 (November (3)) (1975) 189–198.
- [15] S. Kawai, A. Kitabatake, H. Tomoike, Guidelines for diagnosis of takotsubo (ampulla) cardiomyopathy, *Circ. J.* 71 (June 6) (2007) 990–992.
- [16] A. Prasad, A. Lerman, C.S. Rihal, Apical ballooning syndrome (Tako-Tsubo or stress cardiomyopathy): a mimic of acute myocardial infarction, *Am. Heart J.* 155 (March 3) (2008) 408–417.
- [17] A.P. Cerri, F. Teruzzi, M. Gregorio, G. Bellelli, G. Annoni, Takotsubo cardiomyopathy in an elderly patient with severe Alzheimer's disease: a case report, *J. Am. Med. Dir. Assoc.* 13 (March (3)) (2012) 207–209.
- [18] A.J. Donaldson, H.E. Thomson, N.J. Harper, N.W. Kenny, Bone cement implantation syndrome, *Br. J. Anaesth.* 102 (January 1) (2009) 12–22.
- [19] A.A. Elesber, A. Prasad, K.A. Bybee, et al., Transient cardiac apical ballooning syndrome: prevalence and clinical implications of right ventricular involvement, *J. Am. Coll. Cardiol.* 47 (Mar 5) (2006) 1082–1083.
- [20] B.E. Stahlhli, F. Ruschitzka, F. Enseleit, Isolated right ventricular ballooning syndrome: a new variant of transient cardiomyopathy, *Eur. Heart J.* 32 (July (14)) (2011) 1821.
- [21] S. Kurisu, I. Inoue, T. Kawagoe, et al., Variant form of tako-tsubo cardiomyopathy, *Int. J. Cardiol.* 119 (July 2) (2007) e56–e58.
- [22] F. Olsen, M. Kotyra, E. Houltz, S.E. Ricksten, Bone cement implantation syndrome in cemented hemiarthroplasty for femoral neck fracture: incidence, risk factors, and effect on outcome, *Br. J. Anaesth.* 113 (November 5) (2014) 800–806.
- [23] Anaesthesia Sprint Audit of Practice (ASAP). National Hip Fracture Database 2014. Full text at [http://www.nhfd.co.uk/20/hipfractureR.nsf/vwContent/asapReport/\\$file/onlineASAP.pdf](http://www.nhfd.co.uk/20/hipfractureR.nsf/vwContent/asapReport/$file/onlineASAP.pdf), (2015) (accessed October 21st).
- [24] I. Porto, R. Della Bona, A. Leo, et al., Stress cardiomyopathy (tako-tsubo) triggered by nervous system diseases: a systematic review of the reported cases, *Int. J. Cardiol.* 167 (September (6)) (2013) 2441–2448.

## Open Access

This article is published Open Access at [sciendo.com](http://sciendo.com). It is distributed under the [IJSCR Supplemental terms and conditions](#), which permits unrestricted non commercial use, distribution, and reproduction in any medium, provided the original authors and source are credited.