

Dermoscopy of Klippel-Trenaunay Syndrome in a 6-month-old Infant

A 6-month-old female born out of non-consanguineous marriage was brought with complaints of disproportionately increasing length and girth of the right upper limb with overlying reddish raised lesions since birth. There was a history of intermittent bleeding from the lesions. On examination, the circumference of the right forearm (12 cm) was greater than the left forearm (8 cm). The length of the right upper limb was also markedly greater than the left upper limb. There were multiple well-demarcated red non-blanchable patches and plaques with a smooth surface extending up to the mid-arm region on the right upper limb. Some areas showed visible ulceration with superficial crusting [Figure 1]. No bruit was heard on auscultation. Dermoscopy was performed using a 3Gen Dermlite DL3 (CA, USA) 10× polarized mode, and photographs were taken using iPhone X. Biopsy was not done because the parents were apprehensive regarding an invasive procedure.

On dermoscopy, various distinctive features were seen: (i) red dilated linear arborizing vessels; (ii) multiple red lacunae present against homogenous pink to red background [Figure 2]; (iii) on compression, vessels partially blanched with few areas revealing an underlying brown pigment network [Figure 3].

Klippel-Trenaunay Syndrome (KTS) is a rare entity characteristically presenting with asymmetrical overgrowth in girth and length of an extremity with a vascular lesion consisting of combined capillary, lymphatic, and venous malformation since birth. It is a clinical diagnosis, sometimes requiring imaging. The most commonly associated capillary malformation is port wine stain. Dermoscopically it presents as dotted and globular vessels and linear vessels.^[1] Other dermoscopic features

described till date for KTS include white veil around red to purple lacunae classical of angiokeratoma circumscriptum, and white to yellow lacunae with hypopyon classical of lymphangioma circumscriptum, both of which were not observed in our patient.^[2]

Here, the dermoscopy revealed both superficial vascular pattern in the form of red globules and lacunae and deep vascular pattern in the form of linear dilated arborizing vessels. It has been shown in multiple studies that superficial moderate sized vessels (red globules and lacunae) have good to moderate response to pulsed dyed laser, while deeper vessels with a smaller diameter (linear vessels) show the poorest clinical response.^[3] The assessment of these vascular patterns can aid in determining therapeutic approach and gauging expected outcome.

An additional feature in the form of a brown pigment network has never been described in relation to KTS. This brown pigment network possibly corroborates with underlying collection of mast cells. Angiogenic factor with G-patch and FHA domain 1 (AGGF1) is described in KTS and is highly expressed by the mast cells.^[4] This theory is supported by similar dermoscopic findings seen in urticarial pigmentosa and papular mastocytosis, wherein it was postulated that high concentration of mast cells growth factors stimulated melanogenesis and melanocyte proliferation explaining the observed findings. In a report by Gandon *et al.*, a similar pigment pattern with branched linear vessels was described in relation to capillary malformation associated with arteriovenous malformation, but it lacked the superficial globules and lacunae.^[5]

These new dermoscopic findings will add to the existing literature but further studies

Trashita Hassanandani, Maitreyee Panda, Akash Agarwal

Department of Dermatology, IMS and SUM Hospital, Bhubaneswar, Odisha, India

Address for correspondence:

*Dr. Akash Agarwal,
Department of Dermatology,
IMS and SUM Hospital,
K-8 Kalinga Nagar,
Bhubaneswar - 751 003,
Odisha, India.
E-mail: akash.22.1995@gmail.com*

Access this article online

Website: www.idoj.in

DOI: 10.4103/idoj.IDOJ_607_20

Quick Response Code:



How to cite this article: Hassanandani T, Panda M, Agarwal A. Dermoscopy of Klippel-Trenaunay Syndrome in a 6-month-old infant. *Indian Dermatol Online J* 2022;13:824-5.

Received: 29-Jul-2020. **Revised:** 05-Sep-2020.

Accepted: 06-Sep-2020. **Published:** 21-Jun-2021

This is an open access journal, and articles are distributed under the terms of the Creative Commons Attribution-NonCommercial-ShareAlike 4.0 License, which allows others to remix, tweak, and build upon the work non-commercially, as long as appropriate credit is given and the new creations are licensed under the identical terms.

For reprints contact: WKHLRPMedknow_reprints@wolterskluwer.com

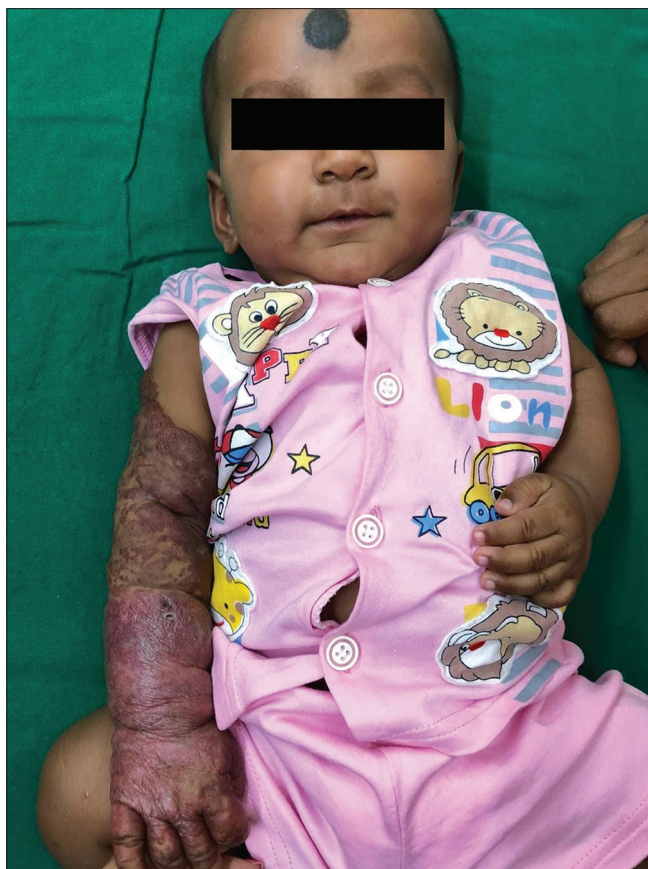

Figure 1: Marked hypertrophy of right upper limb compared to left upper limb with well demarcated red non blanchable patches and plaques with smooth surface extending upto the mid arm region

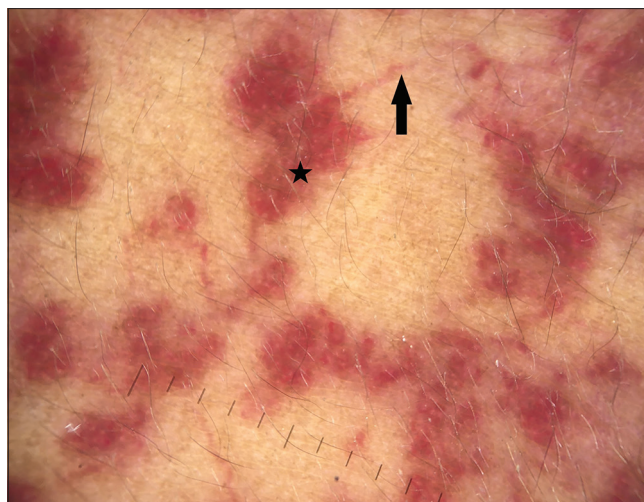


Figure 2: Dermoscopy showing multiple dilated linear arborizing vessels (black arrow) interspersed with multiple red lacunae (black star). [Dermoscopy 3Gen Dermlite DL3 (CA, USA) 10× polarised mode, photographs taken using Iphone X]

Declaration of patient consent

The authors certify that they have obtained all appropriate patient consent forms. In the form, the patient(s) has/have given his/her/their consent for his/her/their images and other clinical information to be reported in the journal. The patients understand that their names and initials will not be published and due efforts will be made to conceal their identity, but anonymity cannot be guaranteed.

Financial support and sponsorship

Nil.

Conflicts of interest

There are no conflicts of interest.

References

1. Shirakawa M, Ozawa T, Wakami S, Ishii M, Harada T. Utility of dermoscopy before and after laser irradiation in port wine stains. *Ann Dermatol* 2012;24:7-10.
2. Supekar BB, Chopkar AD, Wankhade VH, Singh RP, Bhat DM, Suresh P. Klippel-Trenaunay syndrome with arterio-veno-lymphatic malformation: A rare presentation. *Indian Dermatol Online J* 2020;11:404-8.
3. Savas JA, Ledon JA, Franca K, Chacon A, Nouri K. Pulsed dye laser-resistant port-wine stains: Mechanisms of resistance and implications for treatment. *Br J Dermatol* 2013;168:941-53.
4. Ayhan E, Ucmak D, Akkurt Z. Vascular structures in dermoscopy. *An Bras Dermatol* 2015;90:545-53.
5. Gandon C, Bonniaud B, Collet E, Dalac S, Jeudy G, Vabres P. A typical vascular and pigmentary dermoscopic pattern of capillary malformations in capillary malformation-arteriovenous malformation syndrome: Report of four cases. *Pediatr Dermatol* 2016;33:337-41.

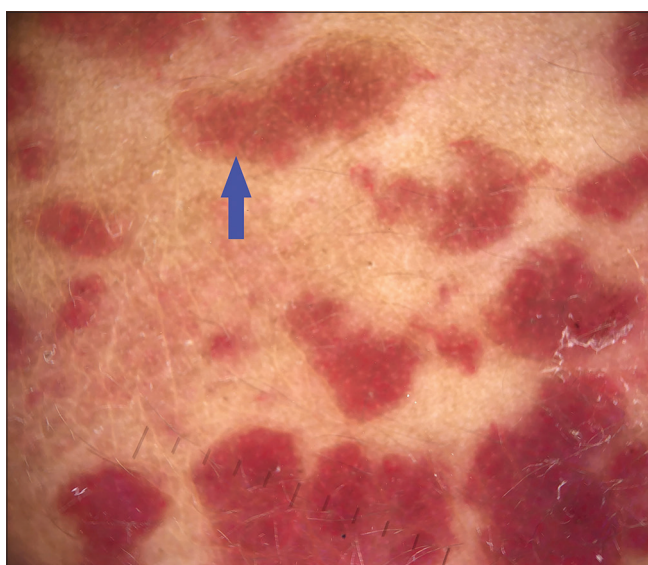


Figure 3: Dermoscopy shows underlying brown pigment network (blue arrow) on compression. [Dermoscopy 3Gen Dermlite DL3 (CA, USA) 10 × polarised mode, photographs taken using Iphone X.]

are needed to analyze the various vascular patterns in KTS in pediatric population.