



Primary fibrosarcoma of the urinary bladder in a cat: follow-up after incomplete surgical excision

Valentina Greci¹, Paola M Rocchi¹, Antonio F Sontuoso¹, Daniela Olivero², Angelo Capasso¹ and Vera Raiano¹

Journal of Feline Medicine and Surgery Open Reports
1–5

© The Author(s) 2017

Reprints and permissions:

sagepub.co.uk/journalsPermissions.nav

DOI: 10.1177/2055116917714881

journals.sagepub.com/home/jfmsopenreports

This paper was handled and processed by the European Editorial Office (ISFM) for publication in *JFMS Open Reports*



Abstract

Case summary An 11-year-old female spayed domestic shorthair cat was presented with haematuria of 2 months' duration followed by pollakiuria and stranguria. A firm, non-painful mass in the urinary bladder was palpated. Abdominal radiographs and ultrasound were suggestive of a urinary neoplasia. During explorative laparotomy, a partial cystectomy and surgical debulking were performed. Histopathology and immunostaining were consistent with a fibrosarcoma. The cat was discharged 10 days after surgery with a residual mass of about 1.8 cm on ultrasound re-examination. The cat was not given adjuvant therapy. The cat was euthanased 8 months after surgery because of tumour invasion of the urinary trigone and subsequent ureter dilation, hydronephrosis and severe azotaemia.

Relevance and novel information Malignant urinary fibrosarcoma in this cat appeared to be only locally invasive. Palliative surgery without adjuvant postoperative chemotherapy in this cat resulted in an 8 month period of good quality of life.

Accepted: 12 May 2017

Introduction

In feline and canine species, urinary bladder tumours are rare and the majority are epithelial in origin with transitional cell carcinoma (TCC) the most common. Non-epithelial tumours are represented by leiomyoma, leiomyosarcoma, fibroma, haemangioma, haemangiosarcoma, lymphoma, histiocytic sarcoma, nerve sheath tumour and lipoma.^{1–8} Fibrosarcoma of the urinary bladder has been known to affect only dogs until recently.^{2,6,9–11} Fibrosarcomas of the urinary bladder in dogs have been rarely reported and show a poor prognosis secondary to widespread metastases, resulting in the death of the patient.^{6,10,11} In the recent case described of feline urinary bladder fibrosarcoma, it was suggested that the tumour might have a different behaviour than in dogs; this cat was reported to be free of clinical signs 16 months after surgery with disease-free margins.⁹

The aim of this work is to describe a case of primary urinary bladder fibrosarcoma in a cat that was treated only by partial cystectomy and debulking.

Case description

An 11-year-old female spayed domestic shorthair cat was referred to the Veterinary Hospital Gregorio VII, Rome, Italy, because of a history of meloxicam-responsive haematuria of 2 months' duration complicated by the acute onset of pollakiuria and stranguria after an unsuccessful attempt at cystocentesis.

On abdominal palpation a firm, non-painful mass was palpated in the caudal abdomen.

Haematology and biochemistry showed increased aspartate aminotransferase (63 UI/l; reference interval [RI] 0–40 UI/l), alanine aminotransferase (81 UI/l; RI

¹Veterinary Hospital Gregorio VII, Rome, Italy

²Laboratory Analisi BiEsseA, Milan, Italy

Corresponding author:

Valentina Greci DVM, PhD, Veterinary Hospital Gregorio VII,

Piazza di Villa Carpegna 52, 00167, Rome, Italy

Email: valentina.greci@gmail.com



Creative Commons Non Commercial CC-BY-NC: This article is distributed under the terms of the Creative Commons

Attribution-NonCommercial 4.0 License (<http://www.creativecommons.org/licenses/by-nc/4.0/>) which permits non-commercial use, reproduction and distribution of the work without further permission provided the original work is attributed as specified on the SAGE and Open Access pages (<https://us.sagepub.com/en-us/nam/open-access-at-sage>).




Figure 1 (a) Right lateral caudal abdomen projection: note the over-distended urinary bladder with irregular caudoventral margins (black arrows); air in the urinary bladder, likely iatrogenic, and kidney calcification are also visible. (b, c) Ascendant urinary tract contrast study, right lateral caudal abdomen projection: (b) normal urethra. (c) Note the filling defect and the irregular margins of the caudoventral portion of the urinary bladder

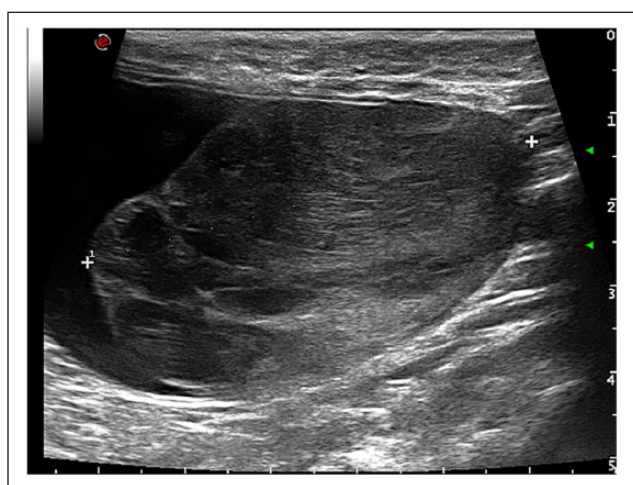


Figure 2 Longitudinal scan of the urinary bladder at the level of the neck and body: note the presence of a 5.3 cm × 3.5 cm inhomogeneous oval expansive intraluminal mass; a few small irregular fluid-filled hypoechoic areas are evident. Loss of the normal structure of the dorsal wall of the urinary bladder is also visible

0–50 UI/l), urea (81 mg/dl; RI 20–60 mg/dl) and creatinine (1.91 mg/dl; RI 0.35–1.50 mg/dl). Urine specific gravity was 1.035 (RI 1.001–1.065), but a complete urinalysis was not processed because of our inability to collect an adequate urine sample.

Right lateral abdominal radiograph projection showed an over-distended urinary bladder with irregular margins (Figure 1a); retrograde contrast urethrocytogram was suggestive of a urinary neoplasia (Figure 1b, c).

The cat was scheduled for abdominal ultrasound the following day. On abdominal ultrasound, the urinary bladder was over-distended by the presence of an oval, vascularised mass of mixed echogenicity measuring 3.5

× 5.2 cm (Figure 2); the lesion raised from the craniodorsal aspect of the urinary bladder wall and the trigone appeared not to be involved.

Signs of chronic bilateral kidney disease, kidney mineralisation, a reduced-sized left kidney (2.8 cm) and bilateral pyelectasia (1 mm) were also detected. Ultrasonographic findings were consistent with degenerative kidney disease and urinary bladder neoplasia.

Thoracic radiographs were unremarkable. The owner declined CT and opted for explorative laparotomy.

The cat was anaesthetised and a ventral midline coeliotomy was performed. The urinary bladder appeared over-distended and firm, with an irregular dorsal wall on palpation. The urinary bladder was filled by a large mass of fibroelastic consistency (Figure 3a). Stay sutures were placed in the apex of the bladder and paramedian along the ventral aspect to the level of the bladder neck and proximal urethra. The urinary bladder was isolated from the remainder of the abdominal cavity with laparotomy sponges. A ventral cystotomy was performed to examine the bladder mucosa and the mass was found to be infiltrating the craniodorsal wall of the urinary bladder and extending into the lumen. The mass was close to the ureter openings; therefore, after urethra catheterisation (Figure 3b) a partial cystectomy with gross debulking was performed. After debulking, there was visible residual tumour ventral to the trigone. All vital parameters remained stable during anaesthesia.

On gross examination, the mass was white to pink-reddish in colour, irregular in shape and smooth but not encapsulated; the mass measured 5 cm × 4.2 cm × 3 cm, and few scattered ulcerations and haemorrhages were noted on the surface. The mass was routinely fixed in buffered 10% formalin and stained with haematoxylin and eosin.

Histologically the mass was composed of a proliferation of spindle cells with a nucleus to cytoplasm ratio of

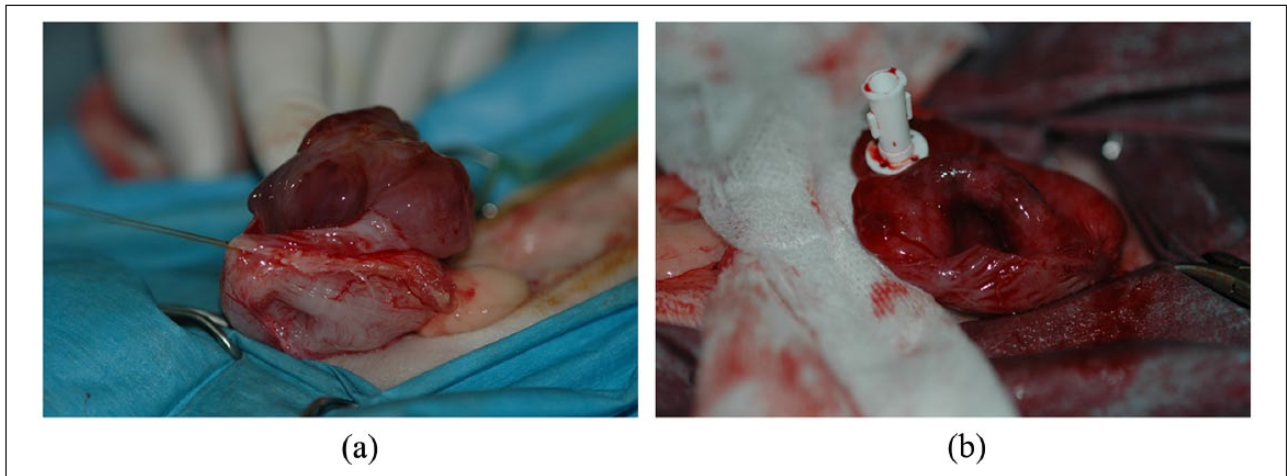

Figure 3 (a) Macroscopic aspect of the urinary mass during intraoperative exposure: the mass was white to pink-reddish in colour with a few areas of erosion and haemorrhages on the surface; the mass was fibro-elastic in consistency. Note the thickened urinary bladder wall. (b) Macroscopic aspect of the urinary bladder wall after partial cystectomy and debulking; note the irregular aspect of the urinary bladder wall close to the urethra, which was catheterised for better visualisation during surgery

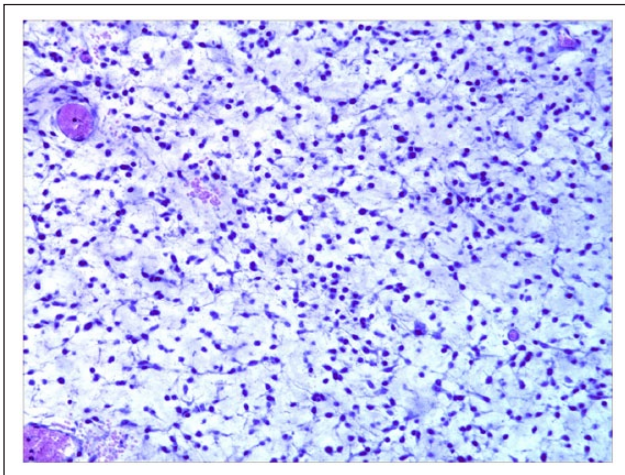


Figure 4 Microscopic findings: presence of a proliferation of spindle cells loosely and irregularly arranged in bundles with interposition of an interstitial basophilic matrix (haematoxylin and eosin, X 20)

2:1; cytoplasm was scant, basophilic and frequently bipolar. The nuclei were pleomorphic, ovoidal and basophilic; one or two nucleoli were evident. The cells were loosely and irregularly disposed in bundles with interstitial basophilic matrix interposed (Figure 4); new diffuse vascularisation with red blood cell engorgement and focal haemorrhages were also seen. The mitotic index at 10 high-power fields was <5.

Histological examination was consistent with a malignant, moderately differentiated mesenchymal tumour suggestive of a fibrosarcoma. Immunohistochemistry was performed and was strongly positive for vimentin

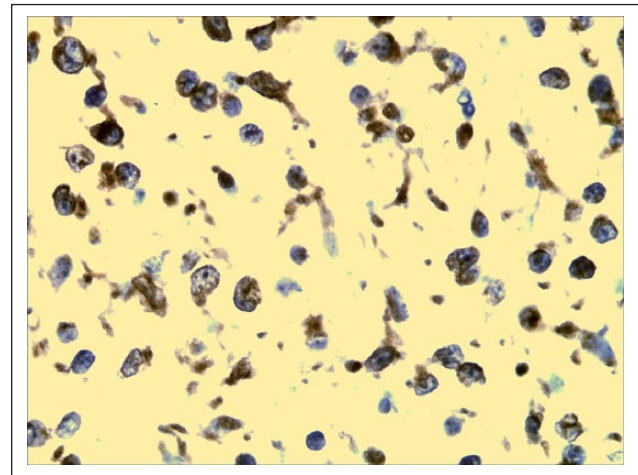


Figure 5 Immunohistochemical staining with vimentin: note the diffuse positive staining of the cytoplasm (X 40)

(Vimentin Ab-2, 1:100 in antibody diluent; Thermo Fisher Scientific) (Figure 5) and negative for S-100 protein (Mouse S-100 Ab-1; Thermo Fisher Scientific), Desmin (Desmin Ab-2; Thermo Fisher Scientific) and smooth muscle actin (Perossidasi DAB detection; Dako), confirming the diagnosis of fibrosarcoma.

The cat was hospitalised on supportive care, fluid take over, meloxicam (0.05 mg/kg q24h SC, Metacam; Boehringer Ingelheim), amoxicillin/clavulanic acid (20 mg/kg q12h IV, Synulox; Pfizer) and methadone hydrochloride (0.2 mg/kg q6h IM, Metadone Cloridrato; Molteni). A 5 Fr Foley (SurgiVet; Smiths Medical) catheter was placed. The cat exhibited severe gross haematuria over the first 48 h of hospitalisation with subsequent severe

Table 1 Packed cell volume (PCV), azotaemia and phosphorus values during hospitalisation and at 5 months after discharge

	Day 3	Day 5	Day 7	Day 9	Day 150
PCV (24–48%)	14.1%		26.6%		41%
BUN (20–60 mg/dl)	176	319	68	65	72
Creatinine (0.35–1.5 mg/dl)	3.22	9.78	2.28	2.22	2.18
Phosphorus (2.0–6.0 mg/dl)	7.0	15.5	6.1	6.0	5.1

BUN = blood urea nitrogen

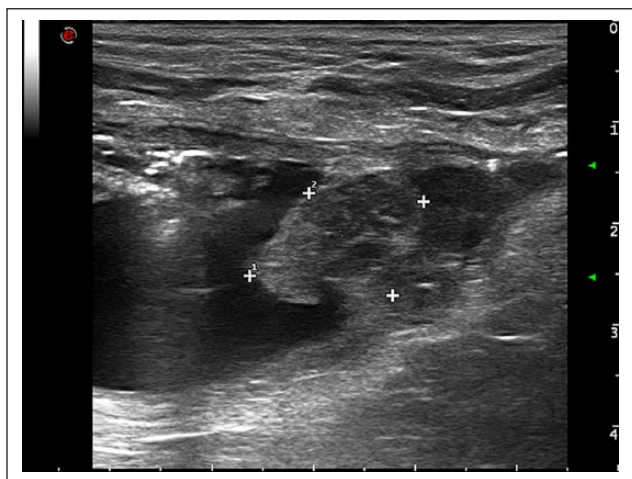


Figure 6 Longitudinal scan at the site of neck and body at time of discharge: note the persistence of a 1.86 cm × 1.30 cm residual mass arising from the dorsal wall of the urinary bladder

anaemia (packed cell volume [PCV] 14%). At the same time, on repeated blood work, an increased azotaemia was noted (Table 1). Worsening of azotaemia was considered secondary to acute kidney injury due to hypovolaemia and hypotension secondary to urinary blood loss. After blood typing and cross-matching, the cat received two packed red blood cell transfusions. Haematuria and azotaemia improved over the following days. The cat was discharged 10 days after surgery with a PCV of 26% and mild azotaemia (Table 1). Abdominal ultrasound re-examination at time of discharge was characterised by the presence of a 1.86 cm × 1.30 cm inhomogeneous mass arising from the dorsal aspect of the urinary bladder wall (Figure 6).

Given the ongoing chronic kidney disease, low-dose metronomic chemotherapy with cyclophosphamide was proposed but declined by the owner. The cat was regularly re-checked after discharge.

On subsequent physical examination, the owner reported the absence of any clinical signs; however, ultrasound re-examination at 4 months after surgery detected a small increase in the size of the residual mass.

Eight months after surgery, the cat was euthanased because of acute onset of gross haematuria followed by

stranguria; biochemistry and ultrasound examination repeated by the referring veterinarian were consistent with severe azotaemia and progression of the tumour that was causing bilateral ureteral obstruction and hydronephrosis.

Discussion

A primary fibrosarcoma of the urinary bladder in a cat has been recently described and it has been hypothesised that it might have a different behaviour than in dogs.^{6,9–11}

Clinical signs associated with urinary bladder tumours are similar to clinical signs of other lower urinary tract diseases and are mainly characterised by haematuria, pollakiuria, dysuria and progressive stranguria, as in the cat reported herein. Other clinical signs, such as lethargy, weight loss, urinary tenesmus mechanical incontinence and rectal prolapse, have been more rarely reported.^{5,8–10}

Blood work changes are non-specific and mainly related to secondary hydronephrosis and secondary urinary infections. In this cat, initial azotaemia was considered to be related to chronic kidney disease. In dogs and cats affected by a urinary bladder tumour, urinalysis can show increase cellularity and signs of infections; tumour cells can only be detected in 30% of patients, on standard urinalysis. The use of a urinary bladder tumour antigen-screening test in the dog has improved this percentage.^{4,5,8–10}

In the cat reported herein, abdominal radiograph changes and ultrasonographic abnormalities were similar to other reports of different urinary bladder tumours and the cat recently diagnosed with a primary urinary bladder fibrosarcoma.^{5,8,9,12,13}

Abdominal ultrasound allows good evaluation of new growths in the urinary bladder; the presence of vascularisation should raise suspicion of neoplasia.^{1,5,9,12}

Diagnosis of urinary tumours can be achieved by the use of fine-needle aspiration biopsy (FNAB), traumatic catheterisation, ultrasound-guided transurethral catheterisation, urinary bladder brushing and full-thickness biopsies obtained surgically or via cystoscopy.^{5,14} FNAB has been associated with the possibility of tumour implantation along the needle tract in the presence of TCC.^{14,15}

The majority of canine and feline urinary bladder tumours are epithelial in origin, with transitional cell carcinoma the most common. Non-epithelial tumours are represented by leiomyoma, leiomyosarcoma, fibroma, haemangioma, haemangiosarcoma and lymphoma. A histiocytic sarcoma in the canine species and a lipoma and a nerve sheath tumour in the feline species have also been reported. Treatment plans depend on location, staging and histopathological diagnosis.^{1,5,8–12}

Urinary bladder fibrosarcomas in the canine species have been rarely reported; all dogs were young and died of widespread metastasis.^{6,10,11} The longest survival time has been 9 months and at the time of death the dog was emaciated.¹¹

The cat reported herein had palliative debulking surgery with partial cystectomy and residual disease at the time of discharge. Although this cat was diagnosed with a malignant fibrosarcoma based on histopathology and immunohistochemistry and did not receive any adjuvant therapy, the cat remained free of clinical signs and in good general condition until the tumour re-growth resulted in bilateral ureters obstruction causing death of the cat at 8 months postoperatively. As a full necropsy was not allowed and metastasis cannot be ruled out, ultrasonographic alterations during repeated re-examination and at time of death were restricted only to the urinary tract.

The likely presence of only local invasion in the cat reported herein, might suggest that urinary bladder fibrosarcoma in the feline species shows a different behaviour than in the canine species.^{6,10,11}

A similar suggestion has already been advanced in the previous case report of a urinary bladder fibrosarcoma in a cat; this cat had been reported to be free of clinical signs 16 months after complete surgical excision without any adjuvant postoperative chemotherapy and a different behaviour of urinary fibrosarcoma in the cat has been hypothesised.⁹

Conclusions

Fibrosarcoma should be considered in the differential diagnosis of the feline urinary bladder tumour. Although more cases should be evaluated, palliative surgery can represent an option providing a good quality of life even after incomplete surgery eradication and without adjuvant postoperative chemotherapy. Postoperative complications such as severe blood haematuria and azotaemia can occur but can resolve if treated promptly.

Funding The authors received no financial support for the research, authorship, and/or publication of this article.

Conflict of interest The authors declared no potential conflicts of interest with respect to the research, authorship, and/or publication of this article.

References

- 1 Benigni L, Lamb LC, Corzo-Menendez N, et al. **Lymphoma affecting the urinary bladder in three dogs and a cat.** *Vet Radiol Ultrasound* 2006; 47: 592–596.
- 2 Burk RL, Meierhenry EF and Schaubhut CW, Jr. **Leiomyosarcoma of the urinary bladder in a cat.** *J Am Vet Med Assoc* 1975; 167: 749–751.
- 3 House HB, Specht AJ and Johnson VS. **What is your diagnosis? Lymphoma of the urinary bladder.** *J Am Vet Med Assoc* 2010; 236: 291–292.
- 4 Khodakaram-Tafti A, Shirian S, Vesal N, et al. **Lipoma of the urinary bladder in a cat.** *J Comp Pathol* 2011; 144: 212–213.
- 5 Mutsaers AJ, Widmer WR and Knapp DW. **Canine transitional cell carcinoma.** *J Vet Intern Med* 2003; 17: 136–144.
- 6 Osborne CA, Low DG, Perman V, et al. **Neoplasms of the canine and feline urinary bladder: incidence, etiologic factors, occurrence and pathologic features.** *Am J Vet Res* 1968; 29: 2041–2055.
- 7 Pavia PR, Havig ME, Donovan TA, et al. **Malignant peripheral nerve sheath tumour of the urinary bladder in a cat.** *J Small Anim Pract* 2012; 53: 245–248.
- 8 Schwarz PD, Greene RW and Patnaik AK. **Urinary bladder tumors in the cat: a review of 27 cases.** *J Am Anim Hosp Assoc* 1985; 21: 237–245.
- 9 Capasso A, Raiano V, Sontuoso AF, et al. **Fibrosarcoma of the urinary bladder in a cat.** *J Feline Med Surg Open Rep* 2015; 1: 1–6.
- 10 Olausson A, Stieger SM, Lofgren S, et al. **A urinary bladder fibrosarcoma in a young dog.** *Vet Radiol Ultrasound* 2005; 46: 135–138.
- 11 Schiller AG, Maksic D, Beamer PD, et al. **Fibrosarcoma of the urinary bladder in the dog.** *J Am Vet Med Assoc* 1958; 133: 594–598.
- 12 Heng HG, Lowry JE, Boston S, et al. **Smooth muscle neoplasia of the urinary bladder wall in three dogs.** *Vet Radiol Ultrasound* 2006; 47: 83–86.
- 13 Park RD. **Radiographic contrast studies of the lower urinary tract.** *Vet Clin North Am Small Anim Pract* 1974; 4: 863–887.
- 14 Nyland TG, Wallack ST and Wisner ER. **Needle-tract implantation following us-guided fine-needle aspiration biopsy of transitional cell carcinoma of the bladder, urethra, and prostate.** *Vet Radiol Ultrasound* 2002; 43: 50–53.
- 15 Wilson HM, Chun R, Larson VS, et al. **Clinical signs, treatments, and outcome in cats with transitional cell carcinoma of the urinary bladder: 20 cases (1990–2004).** *J Am Vet Med Assoc* 2007; 231: 101–106.