

Received: 2010.05.29
Accepted: 2011.02.02

Diagnosis of a cecal tumour with virtual colonoscopy

Jacek Hermann¹, Katarzyna Karmelita-Katulska², Jacek Paszkowski¹, Michał Drews¹, Marek Stajgis²

¹ Department of General, Gastrointestinal and Endocrinological Surgery, Karol Marcinkowski University of Medical Sciences in Poznań, Poznań, Poland

² Department of Radiology, Karol Marcinkowski University of Medical Sciences in Poznań, Poznań, Poland

Author's address: Jacek Hermann, Przybyszewski 49 Str., 60-355 Poznań, Poland, e-mail: jacekhermann@gmail.com

Summary

The authors presented a 75-year-old female patient at high risk, suspected of a cecal cancer (CC) due to discomfort in the inguinal fossa, microcytic anemia (although she was postmenopausal), liquid stools and a positive faecal occult blood test. A standard examination of the large intestine was undertaken. Conventional colonoscopy was not completed and the results of barium enema were questionable. Therefore, virtual colonoscopy (VC) was performed, which helped to localize an accurate operation site. As a result, the patient underwent right hemicolectomy. Postoperative histopathological assessment confirmed an advanced cecal cancer. Traditionally, double-contrast barium enema is used to evaluate the colon in patients after incomplete colonoscopy. However, the accuracy of this test is lower in comparison to endoscopy or VC. An incomplete colonoscopy examination may occur in up to 10% of patients. Tortuous course of the colon, diverticulosis, strictures, obstructing mass and fixation of colonic loops due to adhesions after surgery are the most common causes of incomplete examinations. To sum up, VC can be an alternative method of evaluation of the large bowel in patients after an incomplete colonoscopy examination, as follows from the presented case and the available literature.

Key words: cecal cancer • incomplete colonoscopy • virtual colonoscopy

PDF file: <http://www.polradiol.com/fulltxt.php?ICID=881817>

Background

Colorectal cancer (CRC) is the second most frequent cancer found in both sexes and it is the third most popular cause of cancer deaths in Poland. The effectiveness of CRC treatment in Poland is lower as compared to other developed countries. As a result, the rate of 5-year survival in Poland is half of that in other European countries and it accounts to 25%. A wider access to modern diagnostic tools and regular CRC screening improve the survival rate [1].

Approximately 20% of colorectal tumors develop in the cecum. The clinical presentation of those tumors is late due to a large luminal diameter of the right colon and the form of a polyp in the cecum. Right-sided pains and mass, as well as microcytic anemia constitute a frequent triad of cecal cancer signs [2].

Endoscopic examination of the colon with biopsy for histopathological assessment and double-contrast bowel enema constitute a standard work-up in CRC diagnostics. The

clinical stage of CRC is estimated with chest X-ray, ultrasonography (US), computed tomography (CT) and magnetic resonance imaging (MRI) [3]. Virtual colonoscopy (VC), a kind of CT, is a new and non-invasive radio diagnostic tool. The examination is performed after cleansing and insufflating the air or carbon dioxide into the bowel. VC is well tolerated by patients because it takes a short period of time and anesthesia is not necessary. The role and position of VC in CRC diagnostics has not been established yet. There is a promising role for VC in approximately 10% of patients with incomplete colonoscopy [4].

The aim of this study was to present a female patient suspected of the cecal cancer, who underwent VC after a failed standard CRC diagnostic work-up. This examination localized the operation site precisely.

Case Report

A female patient, B.B., aged 75, case report No. 10466/2009 was admitted to the Clinic on the 27th of May 2009 because

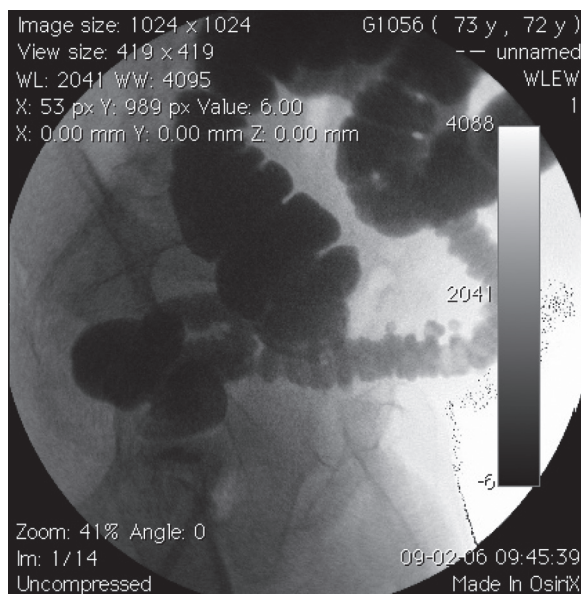


Figure 1. Double-contrast barium enema, caecum dilated with barium contrast.

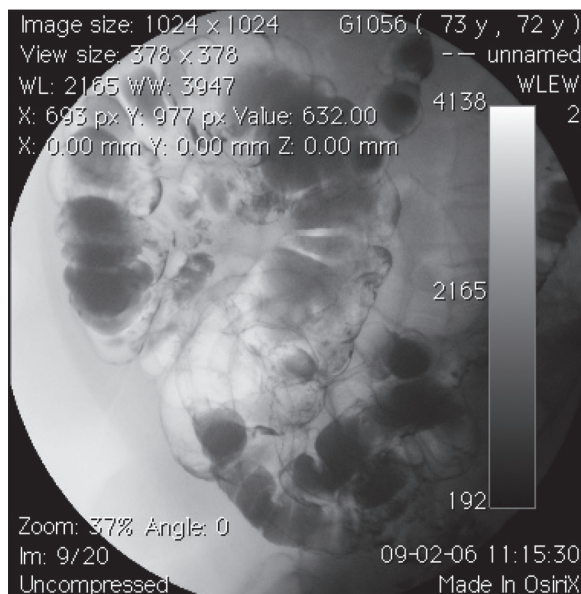


Figure 2. Double-contrast barium enema, caecum dilated with air.

of a cecal tumor. She complained of right inguinal fossa pains and discomfort, as well as recurrent diarrhea, present since November 2008. A standard examination of the large intestine was undertaken. On the 15th of December, she underwent a colonoscopy which was not completed due to diverticulosis within the sigmoid colon and adhesions after a previous hysterectomy and appendectomy. In the meantime, faecal occult blood test proved positive. Next, an experienced endoscopist failed in an attempt to perform another colonoscopy for aforementioned reasons. Double-contrast barium enema carried out on the 6th of February 2009 showed a small deformity of the cecal wall, diagnosed as 'scar after appendectomy' (Figures 1, 2). Because the results of barium enema were questionable, VC was performed on the 8th of May 2009 and revealed a tumor of the cecum, 4 cm in diameter (Figures 3, 4). Breath-hold supine

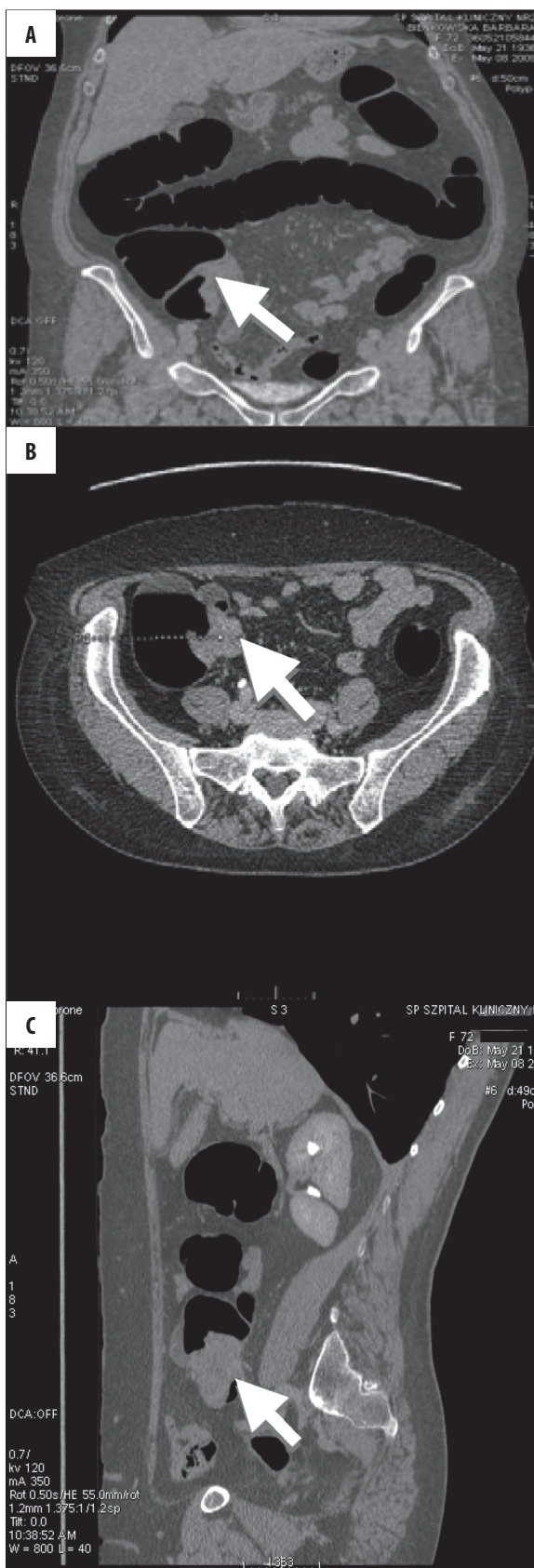


Figure 3. Virtual colonoscopy (A) coronal, (B) transverse, (C) sagittal, two-dimensional (2D), MIP reconstruction with soft tissue window-level settings shows a cecum tumour.

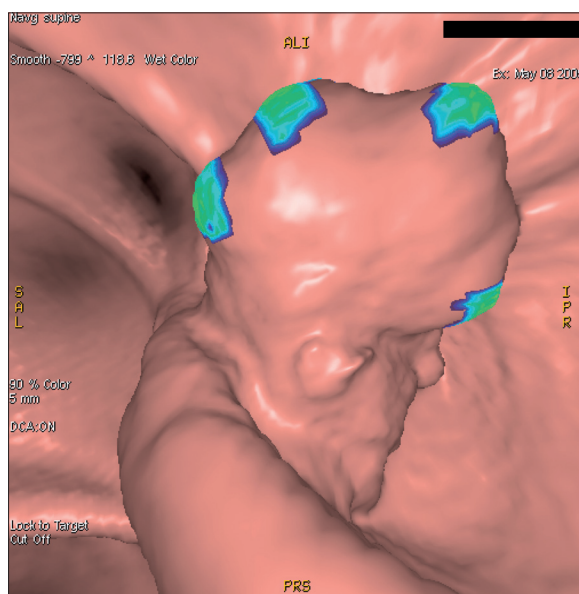


Figure 4. Virtual colonoscopy, three-dimensional (3D), VR endoluminal image shows the simulated endoscopic appearance of the lesion.

and prone CT acquisitions were obtained with 64-channel multidetector scanners (GE LightSpeed Series; General Electric Medical Systems). The CT technique entailed: 1.25-mm collimation, 0.6-mm reconstruction interval. Secondary diseases, such as obesity and coronary failure, were diagnosed. A physical examination on admission revealed only scars after former operations. An abdominal examination was difficult to perform due to patient's obesity, and therefore the cecal tumor was not palpable. Hemoglobin level was too low, i.e. 10.7 g/dl (normal range: 11.8–15.8). After bowel cleansing and administration of prophylactic antibiotics, that is amoxicillin with clavulanic acid, she underwent right hemicolectomy with a regional dissection of the lymph nodes on the 4th of June, for cecal tumor, 4 cm in diameter. Diverticulosis of the sigmoid colon was found, without indications for surgery. The postoperative course was complicated by transient respiratory failure. The patient was discharged home after wound healing, in a good general condition, on the 15th of July. The postoperative histopathological assessment revealed an advanced cecal cancer which was 2.8/3.7/0.9 cm in diameter and

was located in the Bauhin's valve region, infiltrating all layers of the intestinal wall. One lymph node from among 10 excised proved to be positive for metastasis. (Dukes C, Astler-Coller C2).

Discussion

The authors presented a 75-year-old female patient suspected of a cecal cancer due to postprandial pains and discomfort in the right inguinal fossa, microcytic anemia (postmenopausal patient), liquid stools and a positive faecal occult blood test. A standard examination of the large intestine was undertaken. A conventional colonoscopy was not completed and the results of barium enema were questionable. Therefore, virtual colonoscopy was performed which helped to find an accurate location of the operation site.

The presented case and the literature proved that VC is indicated in patients who failed a complete colonoscopic examination. Traditionally, such patients used to be referred for a double-contrast barium enema. However, both the standard and the virtual colonoscopy are more accurate than the barium enema. What is more, VC can be performed immediately after an incomplete colonoscopy, without any additional preparation [5]. The incomplete colonoscopy examination may occur in up to 10% of patients. Tortuous course of the colon, diverticulosis, strictures, obstructing mass and fixation of colonic loops due to adhesions after a previous surgery are the most common causes of incomplete colonoscopies [6,7]. There are also general contraindications for classic colonoscopy, such as old age, coronary failure, exacerbation of asthma and coagulation abnormalities.

Most patients with a positive result of virtual colonoscopy should undergo the classic examination for a verification of any visualized lesions, collection of biopsy specimens or to have polypectomy. However, preoperative histopathological assessment in case of the cecal tumor is not obligatory [8].

Correctness of the evaluation of the large intestine can be questioned due to a delayed diagnosis of advanced cancer and its surgical treatment. However, that delay was a result of inappropriate organization of the health care system, rather than multiplication of unnecessary examination methods. Moreover, patients at high risk should not be referred for surgery without a confirmed diagnosis.

References:

1. Didkowska J, Wojciechowska U, Tarkowski W: Nowotwory złośliwe w Polsce w 1999 roku. Krajowy Rejestr Nowotworów. Warszawa, 2002
2. Góral R: Chirurgia okrężnicy i odbytnicy. Warszawa: PZWL, 1993
3. Bipat S, Glas: Rectal cancer-local staging and assessment of lymph node involvement with endoluminal UC, CT and MR imaging-a meta analysis. *Radiology*, 2004; 232: 773–83
4. Barish MA, Soto JA, Ferrucci JT: Consensus on current clinical practice of virtual colonoscopy. *Am J Roentgenol*, 2005; 184: 786–92
5. Morrin MM, Kruskal JB, Farrell RJ: Endoluminal CT colonography after incomplete endoscopic colonoscopy. *AJR. Am J Roentgenol*, 1999; 172: 913–18
6. Fenlon HM, McAneny DB, Nunes DP: Occlusive colon carcinoma: Virtual colonoscopy in the preoperative evaluation of the proximal colon. *Radiology*, 1999; 210: 423–28
7. Shah HA: Factors associated with incomplete colonoscopy: a population-based study. *Gastroenterology*, 2007; 132: 2297–303
8. Summerton S, Little E, Cappell MS: CT colonography: current status and future promise. *Gastroenterol Clin N Am*, 2008; 37: 161–89