

# INTRAVITREAL INJECTION OF PERFLUOROPROPANE IS MORE EFFICACIOUS THAN SULFUR HEXAFLUORIDE IN RELEASING VITREOMACULAR TRACTION

Neža Čokl<sup>1</sup> and Mojca Globočnik Petrovič<sup>1,2</sup>

<sup>1</sup>Eye Hospital, University Medical Centre Ljubljana, Ljubljana, Slovenia;

<sup>2</sup>Faculty of Medicine, University Ljubljana, Ljubljana, Slovenia

**SUMMARY** – The aim was to compare the efficacy of a single intravitreal injection of perfluoropropane (C3F8) and sulfur hexafluoride (SF6) in releasing vitreomacular traction (VMT). This prospective study included two groups of patients with symptomatic VMT confirmed by spectral-domain optical coherence tomography (SD-OCT). Patients from both groups received a single intravitreal injection of expansile gas. One group (29 eyes) received 0.3 mL of 100% C3F8, and the other group (28 eyes) received 0.3 mL of 100% SF6. Eyes without VMT release one month after SF6 injection were secondarily injected with C3F8. The primary outcome was the ratio of eyes in each group with complete VMT release on OCT one month following primary treatment. The secondary outcome was the ratio of reinjected eyes with complete VMT release on OCT one month following second injection. Additional outcome was the ratio of VMT release in eyes with specific clinical characteristics. One month after the application, complete release of VMT on OCT was recorded in 18 out of 29 eyes (62%) in the C3F8 group, in 6 out of 28 eyes (21.4%) in the SF6 group, and in 7 out of 14 (50%) reinjected eyes. There was no statistically significant difference in age, width of vitreomacular attachment (WVMAT), central retinal thickness and presence of additional features between the two groups. In eyes with WVMAT <500 microns, there was no statistically significant difference between the two gases in releasing VMT. In eyes with WVMAT >500 microns, C3F8 was more efficacious ( $p=0.001$ ). According to the results of our study, intravitreal C3F8 injection seems to be more efficacious in releasing VMT than SF6 in eyes with WVMAT larger than 500 microns.

**Key words:** *Intravitreal Injections; Retinal Diseases; Prospective Studies; Tomography, Optical Coherence; Outcome Assessment (Health Care)*

## Introduction

Vitreoretinal interface diseases are thought to occur due to an anomalous or incomplete posterior vitreous detachment (PVD), i.e. separation of the vitreous cortex from the internal limiting membrane. In 2013, the International Vitreomacular Traction Study Group defined and classified vitreoretinal interface diseases

according to optical coherence tomography (OCT)-based anatomic findings in vitreomacular adhesion (VMA), vitreomacular traction (VMT) and macular hole<sup>1</sup>. VMA was defined as perifoveal vitreous separation with the remaining vitreomacular attachment and unperturbed foveal morphological features. It is an OCT finding that is almost always the result of normal vitreous aging<sup>1</sup>. VMT is characterized by anomalous posterior vitreous detachment accompanied by anatomic distortion of the fovea, which may include pseudocysts, macular schisis, cystoid macular edema, and subretinal fluid<sup>1</sup>. Primary full-thickness macular hole (FTMH) was defined as a foveal lesion with in-

Correspondence to: *Mojca Globočnik Petrovič, MD, PhD*, Eye Hospital, University Medical Center Ljubljana, Grablovičeva 46, 1000 Ljubljana, Slovenia

E-mail: [mgpetrovic@yahoo.com](mailto:mgpetrovic@yahoo.com)

Received April 27, 2018, accepted May 14, 2018

Table 1. Studies investigating the efficacy of intravitreal SF6 or C3F8 injection in causing PVD in eyes with different pathologies

Authors	Journal	Pathology	Gas used	Volume (n)	PVD success rate	Complications
Ochoa Contreras D <i>et al.</i>	Acta Ophthalmol Scand. 2000 Dec	Nonproliferative diabetic retinopathy	0.5 mL 100% SF6	20	100%	No complications
Day S <i>et al.</i>	Retina. 2016 Apr	VMT (WVMAT <520 microns, no ERM)	0.3 mL 100% SF6	9	56%	Peripheral retinal tear in 1 patient (11%)
Total			SF6	29	78%	Complication in 1 patient (2%)
Mori K <i>et al.</i>	Ophthalmology. 2007 Jan	Idiopathic macular hole (stage II)	0.3 mL 100% C3F8	20	9%; hole closed in 50%	No complications
McHugh D <i>et al.</i>	Clin Ophthalmol. 2011 Oct	Diabetic macular edema (no ERM or PRDR)	0.3 mL 100% C3F8	5	100%	Vitreous hemorrhage in 1 patient (20%)
Kang HM <i>et al.</i>	Graefe Arch Clin Exp Ophthalmol. 2016 Jan	ARMD + VMA	0.3 mL 100% C3F8 + Ranibizumab	23	96%	Peripheral retinal tear in 1 patient (4%)
Rodrigues IA <i>et al.</i>	Am J Ophthalmol. 2013 Feb	VMT (50% idiopathic, 50% associated with diabetes)	0.3 mL 100% C3F8	15	40% in 1 month, 60% in 6 months	No complications
Steinle NC <i>et al.</i>	Retina. 2017 Apr	VMT	0.3 mL 100% C3F8	30	83%	Pupillary block in 1 patient
Total			C3F8	93	83%	Complication in 3 patients (3.2%)

ARMD = age related macular degeneration; ERM = epiretinal membrane; PRDR = proliferative diabetic retinopathy; PVD = posterior vitreous detachment; VMA = vitreomacular adhesion; VMT = vitreomacular traction; WVMAT = width of vitreomacular attachment

ruption of all retinal layers from the internal limiting membrane to the retinal pigment epithelium, caused by vitreous traction<sup>1</sup>.

Anatomical changes of the fovea induced by VMT can lead to typical symptoms of reduced visual acuity, decreased reading vision, metamorphopsia, and micropsia. The natural history of patients with VMT is not well established, but it is thought that 11%-40% of symptomatic VMT dissolve spontaneously in 8-12 months, although restoration of foveal anatomy is uncertain<sup>2</sup>. Other symptomatic patients with persistent VMT may undergo further progression into macular

hole, persistent macular edema, foveal detachment, macular atrophy, and severe deterioration of visual function and quality of life<sup>3-5</sup>.

The standard treatment for severe VMT is pars plana vitrectomy. The goal of vitreous surgery is to eliminate anteroposterior and tangential traction, thereby relieving attachment of the vitreous to the macula. Vitreolysis is achieved in 100% of cases, with good anatomical outcome and some improvement of vision in most cases<sup>6</sup>, but the surgery itself is not without risk. Intraoperative retinal tears occur in up to 1.6% and postoperative retinal detachment in up to

4.6%; in about two-thirds of phakic eyes, cataract develops within 2 years of surgery<sup>7</sup>.

Since 2012, ocriplasmin has been approved as a non-surgical, pharmacologic agent for the treatment of symptomatic VMT, but vitreolysis is only achieved in 25%-50%<sup>8,9</sup>, with a high incidence of side effects<sup>8</sup> and at a high cost.

In the last years, pneumatic vitreolysis has started to show promise as a new treatment option for VMT.

In the past two decades, there have been quite a few studies investigating the efficacy of a single intravitreal gas injection in causing PVD in eyes with different pathologies, such as nonproliferative diabetic retinopathy<sup>10</sup>, diabetic macular edema<sup>11</sup>, stage II macular holes<sup>12</sup>, and wet macular degeneration<sup>13</sup>. The success rate was 95%-100% with very few complications.

Recently, at least three small case studies investigated pneumatic vitreolysis also in eyes with VMT. Rodrigues *et al.* demonstrated that a single intravitreal injection of perfluoropropane (C3F8) could cause VMT resolution in 5/7 (70%) eyes with isolated VMT and in 3/6 (50%) eyes with concurrent diabetic macular edema<sup>14</sup>. There were no complications. Day *et al.* obtained VMT release in 5/9 (55.6%) patients after a single intravitreal injection of sulfur hexafluoride (SF6). A peripheral retinal tear occurred in one patient (11%), and no other complications were noted<sup>15</sup>. In a study more recently published by Steinle *et al.*, complete release after intravitreal injection of up to 0.3 mL of 100% C3F8 occurred in 25 out of 30 eyes (83%) with symptomatic VMT. They had the same success rate in eyes with concurrent epiretinal membrane (ERM) (5 out of 6 eyes, 83%) and in eyes previously treated with ocriplasmin (5 out of 6 eyes, 83%)<sup>16</sup>. According to these studies, a single intravitreal gas injection seems to be efficacious in causing PVD and could therefore be a promising treatment option for VMT with a high success rate and very high safety profile. However, the total number of patients and the power of studies were rather low. In most of the studies, either SF6 or C3F8 was used, and hexafluoroethane (C2F6) was also used in one study<sup>17</sup>.

Table 1 presents specific and combined success rates achieved in the studies using SF6 or C3F8. SF6 was used in a total of 29 eyes and PVD was obtained in 78% of cases. C3F8 was used in 93 eyes in total, with PVD occurring in 83% of cases.

According to these studies, intravitreal SF6 and C3F8 injections seem to be almost equally efficacious

in causing PVD, even though they have different specific qualities. A pure SF6 bubble expands to about double the volume injected within 24 to 48 hours, and stays in the eye for 1 to 2 weeks. A pure C3F8 bubble expands to about 4 times its original volume within 72 to 96 hours, and persists in the vitreous cavity for 6 to 8 weeks. Since SF6 is reabsorbed from the vitreous much faster and it is much less of a burden for the patient, we wanted to check whether, despite its lower expansibility, it is really as effective in releasing VMT as C3F8.

The purpose of our study was to directly compare the efficacy of intravitreal injections of SF6 and C3F8 in causing PVD, and additionally to evaluate the visual acuity success rate after pneumatic PVD in patients with VMT.

## Patients and Methods

This prospective comparative study included 57 eyes of consecutive patients aged 57-91 years with symptomatic VMT and primary FTMH stage II. Patient enrolment and treatment took place at the Eye Hospital of the University Medical Center Ljubljana. Preoperatively and postoperatively, the routine comprehensive ophthalmological examination (including best corrected visual acuity (BCVA) using Snellen charts, biomicroscopy and funduscopy) and spectral domain OCT (SD-OCT) of the macula were performed with Heidelberg Spectralis in all patients.

The width of vitreomacular attachment (WV-MAT), central retinal thickness (CRT), integrity of external limiting membrane (ELM) and ellipsoid zone, and the presence of ERM were noted. Postoperatively, we looked for the presence of PVD; restoration of foveal contour and CRT were noted.

The inclusion criteria were any symptomatic VMT with deterioration of visual acuity of at least 2 Snellen lines and the duration of symptoms for at least 3 months (or less if the deterioration was very rapid, at least 2 or more Snellen lines in 0.5 months), and primary FTMH stage II according to Gass.

The only exclusion criterion were completely disrupted outer retinal layers on OCT.

Twenty-nine eyes from the C3F8 group received a single intravitreal injection of 0.3 mL of 100% C3F8, and 28 eyes from the SF6 group received a single intravitreal injection of 0.3 mL of 100% SF6. The gas

Table 2. Comparison of patient clinical characteristics

Characteristic	C3F8 group	SF6 group	p-value
Age (years)	57-89, mean 73.28 ( $\pm$ 1.81)	60-91, mean 77.29 ( $\pm$ 1.50)	0.094
CRT ( $\mu$ m)	140-861, mean 463.28 ( $\pm$ 35.43)	230-840, mean 429.68 ( $\pm$ 30.08)	0.474
WVMAT ( $\mu$ m)	50-3500, mean 770.31 ( $\pm$ 148.80)	110-2500, mean 610.43 ( $\pm$ 98.01)	0.377
No. of eyes with ERM/all eyes (%)	10/29 (34.5%)	9/28 (32.1%)	1.000
No. of eyes with CME/all eyes (%)	21/29 (72.4%)	25/28 (89.2%)	0.179
No. of eyes with FTMH /all eyes (%)	4/29 (13.8%)	0/28 (0%)	0.112
No. of eyes with subretinal fluid/all eyes (%)	6/29 (20.6%)	3/28 (10.7%)	0.470
No. of pseudophakic eyes/all eyes (%)	10/29 (34.5%)	8/28 (28.6%)	0.777

CME = cystoid macular edema; CRT = central retinal thickness; ERM = epiretinal membrane; FTHM = primary stage II full-thickness macular hole; WVMAT = width of vitreomacular attachment

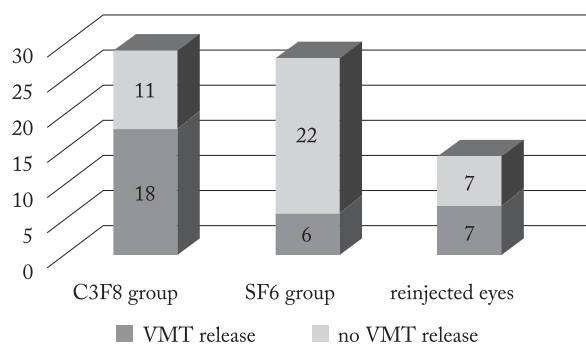


Fig. 1. Vitreomacular traction (VMT) release one month after gas injection.

was injected in an operating theatre under sterile conditions. Paracentesis with aqueous humor leakage was performed right after the injection to release the intraocular pressure. No medications were used intra- or postoperatively. Patients were then asked to nod their head occasionally in the next few days and/or hold prone position for a few consecutive minutes 5-10 times a day. Follow-up visits were performed at week 1, month 1, month 3 and month 6 after the injection.

Eyes from the SF6 group that showed no PVD on SD-OCT one month after the injection were reinjected with 0.3 mL of 100% C3F8. They were followed by the same protocol.

The primary outcome was the ratio of eyes with complete VMT release on SD-OCT one month following the primary injection. The secondary outcome was the ratio of reinjected eyes with complete release on SD-OCT one month after the second injection.

Additional outcomes were the ratio of VMT release in eyes with different WVMAT, CRT, integrity of external ELM, ellipsoid zone, and the presence of ERM.

T-test was used to compare preoperative characteristics of the C3F8 and SF6 groups (age, WVMAT and CRT). The  $\chi^2$ -test was used to compare VMT release after one month between the C3F8 and SF6 groups and between the subgroups with specific clinical characteristics.

## Results

There was no statistically significant difference in age, WVMAT and CRT, or the presence of additional features between the two groups (Table 2).

One month after the application, complete release of VMT on SD-OCT was recorded in 18 out of 29 eyes (62%) in the C3F8 group and in 6 out of 28 eyes (21.4%) in the SF6 group, yielding a statistically significant difference ( $p=0.003$ ). In the reinjected group, complete release of VMT demonstrated by SD-OCT one month after reinjection was recorded in 7 out of 14 eyes (50%) (Fig. 1).

Most of the eyes with VMT release from both groups had VMT release already in the first week (12 out of 18 (66.6%) eyes from the C3F8 group and 5 out of 6 (83.3%) eyes from the SF6 group). In the reinjected group, PVD was noted after 1 week in only 2 out of 7 (28.6%) eyes. In this group, another eye showed VMT release at the month 3 visit. No other

VMT release was noted in the additional 3-month follow-up period in either group.

In 4 eyes with preoperative stage II primary FTMH (160–310 microns, mean 223 microns) from the C3F8 group, VMT release occurred in 4/4 (100%) eyes. In one eye (25%), the hole closed; its size was 160 microns. The other three patients proceeded to surgery; the hole was successfully closed after first vitrectomy.

Table 3 shows the ratio of VMT release in groups of eyes with specific clinical characteristics. The efficacy in VMT release in narrower WVMAT was similar in both groups; however, intravitreal C3F8 injection was more efficacious than SF6 in releasing VMT in eyes with WVMAT larger than 500 microns ( $p=0.001$ ). In the ERM subgroup, VMT release was present in 2/10 (20%) eyes after C3F8 and in none after SF6 injection.

Table 3. VMT release ratio after gas injection in groups of eyes with specific clinical characteristics

	Number of eyes with VMT release/all eyes (percentage of VMT release)		p-value
	C3F8 group	SF6 group	
Epiretinal membrane	2/10 (20.0%)	0/9 (0%)	0.4737
WVMAT 1000–3500 $\mu\text{m}$	2/6 (33.3%)	0/2 (0%)	1.000
WVMAT 500–1000 $\mu\text{m}$	5/7 (71.4%)	0/14 (0%)	0.001
WVMAT >500 $\mu\text{m}$	7/13 (53.8%)	0/16 (0%)	0.001
WVMAT <500 $\mu\text{m}$	11/16 (68.6%)	6/12 (50%)	0.4410

VMT = vitreomacular traction; WVMAT = width of vitreomacular attachment

Considering complications, there was a peripheral retinal tear with localized retinal detachment in one eye and a small FTMH with a diameter of 220 microns in another eye seen one week after C3F8 injection. After one month, another eye with a macular hole of 330 microns was found in this group (complication rate: 3/29 eyes, 10.3%). A small macular hole with a diameter of 225 microns was also found in one eye from the SF6 group at one-week follow-up (1/28 eyes,

3.6%). Three patients proceeded to vitrectomy, in all the retina was attached and macular hole closed after first vitrectomy. One patient declined the operation. No other significant complications were observed.

## Discussion

In our group of eyes, complete VMT release was achieved in 62% of eyes with a single intravitreal injection of 0.3 mL of 100% C3F8 and with the same volume of 100% SF6 only in 21.4% of eyes. Since there was no statistically significant difference in the preoperative features between the two gas groups, this result alone implies that C3F8 is more efficacious in releasing VMT than SF6. Obtaining PVD with secondary intravitreal C3F8 injection in 50% of eyes that failed to respond to primary injection with SF6 backs up this implication.

Analyzing the effect of the two gases on VMT release according to WVMAT, C3F8 and SF6 were equally effective in the narrower width of attachment (<500 microns,  $p=0.4410$ ), while C3F8 was much more effective than SF6 in releasing VMT in the group with greater WVMAT (>500 microns,  $p=0.001$ ). It also seemed to be more successful in eyes with ERM; with the intravitreal injection of SF6 we did not achieve a single release in this subgroup.

According to the literature, our study that included 57 eyes seems to be the largest one investigating pneumatic vitreolysis so far. It was also the first study directly comparing the efficacy of the two gases (SF6 and C3F8). The number of eyes was large enough to prove that C3F8 in general was superior to SF6 in releasing VMT and equally effective in narrower WVMAT.

Comparison of our results and those reported from other studies investigating pneumatic vitreolysis in eyes with different pathologies<sup>10–16</sup> reveals that we had a lower overall PVD rate with either gas injection. In these studies, PVD was achieved in 56%–100% (mean 78%) with SF6 and in 40%–100% (mean 83%) with C3F8. This may be due to the less narrow patient selection in our study; the included patients were consecutively recruited patients that met the inclusion criteria notwithstanding the WVMAT or any of the additional features. Certain clinical characteristics such as patient age<sup>11,15,16</sup> and phakic/pseudophakic ratio<sup>15,16</sup> were, to our knowledge, similar to other studies,

but unfortunately, many of the previous studies failed to provide data on WVMAT and presence of ERM, so these characteristics could not be compared.

The reason for this PVD success rate difference may as well lie in the lower number of patients in previous studies or in different vitreoretinal pathology. It is reasonable to believe that the strength of adhesion in eyes with VMT is much firmer than in eyes with VMA (which by definition is without vitreal traction) and could therefore explain the lower rate of pneumatically induced PVD in eyes with VMT. When comparing our results only with those from the studies investigating eyes with VMT<sup>14-16</sup>, we were equally effective, at least with C3F8. PVD rate in those studies was 40%-84% (mean 61.5%), whereas in ours it was 62%.

Day *et al.* obtained PVD in 56% of eyes with VMT with the intravitreal injection of SF6<sup>15</sup>, compared to our 21.4%, but they had only 9 eyes and in all 5 eyes with postoperative PVD WVMAT was less than 521 microns and none had ERM.

In our study, C3F8 appeared to be superior to SF6 also in the subgroup with ERM but the numbers were too small to prove it statistically significant. Our results are comparable to previous studies, even though the number of eyes included in those studies was also very low. Day *et al.* had 2 eyes with ERM, and none had PVD after intravitreal SF6<sup>15</sup>. On the other hand, Steinle *et al.* had 6 eyes with ERM and achieved PVD in 5 of those with intravitreal C3F8<sup>16</sup>.

In our study, 4 eyes with primary stage II FTMH (160-310 microns, mean 223 microns) were included in the C3F8 group. PVD was obtained in 4/4 (100%) eyes, but only in one the hole closed (25%). Its size was 160 microns, while the size of the hole in the remaining three eyes was >200 microns. All patients with the remaining hole proceeded to surgery and the hole was successfully closed after first vitrectomy.

Steinle *et al.* had 3 stage II FTMH; in 2 (66.6%), the hole closed after PVD<sup>16</sup>. Mori *et al.* had similar success<sup>12</sup>; they had 20 patients with stage II FTMH, in 50% the hole closed after PVD. The size of the hole in all patients from both studies was less than 200 microns. Concluding from these data, the size of the hole being less than 200 microns may be an important prognostic factor for hole closure after successful pneumatic PVD in primary stage II FTMH.

Most of our patients from the SF6 group presented with a very small bubble or even no gas at all at the first

follow-up (week 1). In all these eyes, gas was absent at the second follow-up (month 1). On the contrary, in most patients from the C3F8 group, gas was filling up to one-third of their vitreal cavity at the first follow-up and in all at least a small bubble was present at the second follow-up. Unlike the SF6 patients, patients that received C3F8 were complaining immensely about the gas bubble interference with their vision. They reported having troubles walking down the stairs, preparing their meals and reading. However, what they found most annoying, some of them even completely unbearable, was the duration of troubles. The average time for PVD to appear after the injection was 13 days in the study by Steinle *et al.*<sup>16</sup>. Since also in our study more than 60% of eyes with VMT release had PVD already one week after the injection, it seems that the efficacy of C3F8 might be more due to the expandability rather than its persistence. We wonder would the results have been different also in the subgroups with ERM or larger attachments if we had used 0.5 mL of 100% SF6 instead. The maximum expanded volume would then match that of C3F8 and might therefore exert the same effect, but with the advantage of faster clearance from the eye.

Ochoa-Contreras *et al.*<sup>10</sup> used 0.5 mL of SF6 in their study on patients with nonproliferative diabetic retinopathy with a PVD success rate of 100%, but they had no ERM and unfortunately data on WVMAT are not provided in the published article.

Since according to previous studies and our own, it can now be said with certainty that gas injection is sufficiently effective in causing VMT release in eyes with WVMAT smaller than 1000 microns and in the absence of epiretinal membrane, we believe that due to its seemingly high safety profile, low cost and easy accessibility, it would seem reasonable in certain situations to at least try it as a first line treatment in VMT patients that meet the above criteria. The waiting time for vitrectomy as a traditional way of treatment in some parts of the world exceeds six months. Postponing treatment for such a long time can result in photoreceptor damage and irreversible vision loss. The costs of vitrectomy vary in different countries and hospitals, but generally amount to several hundred Euros. Intravitreal gas injection, on the other hand, can be applied at an office visit in just a few minutes and at minimal cost.

We suggest using SF6 in eyes with WVMAT smaller than 500 microns and C3F8 in those with WVMAT larger than 500 microns.

## Conclusion

According to the results of our study, intravitreal C3F8 injection appears to be as efficacious as SF6 in releasing smaller vitreomacular attachment and more efficacious in releasing larger vitreomacular attachment in eyes with VMT.

## References

1. Duker JS, Kaiser PK, Binder S, *et al.* The International Vitreomacular Traction Study Group Classification of Vitreomacular Adhesion, Traction, and Macular Hole. *Ophthalmology*. 2013;120:2611-9. <http://dx.doi.org/10.1016/j.ophtha.2013.07042>.
2. Hikichi T, Yoshida A, Trempe CL. Course of vitreomacular traction syndrome. *Am J Ophthalmol*. 1995;119:55-61.
3. Zhang Z, Dong F, Zhao C, *et al.* Natural course of vitreomacular traction syndrome observed by spectral-domain optical coherence tomography. *Can J Ophthalmol*. 2015;50:172-9. <http://dx.doi.org/10.1016/j.jco.2014.12.003>
4. Tzu JH, John VJ, Flynn HW Jr, Smiddy WE, Jackson JR, Isenrhagen BA, Carver A, Leonard R, Tabandeh H, Boyer DS, *et al.* Clinical course of vitreomacular traction managed initially by observation. *Ophthalmic Surg Lasers Imaging Retina*. 2015;46:571-6. <http://dx.doi.org/10.3928/23258160-20150521-09>.
5. Bottos J, Elizalde J, Rodrigues EB, Farah M, Maia M. Vitreomacular traction syndrome: postoperative functional and anatomic outcomes. *Ophthalmic Surg Lasers Imaging Retina*. 2015;46:235-42. <http://dx.doi.org/10.3928/23258160-20150213-14>.
6. Witkin AJ, Patron ME, Castro LC, *et al.* Anatomic and visual outcomes of vitrectomy for vitreomacular traction syndrome. *Ophthalmic Surg Lasers Imaging*. 2010;41:425-31. <http://dx.doi.org/10.3928/15428877-20100525-07>.
7. Jackson TL, Nicod E, Angelis A, Grimaccia F, Prevost AT, Simpson AR, Kanavos P. Pars plana vitrectomy for vitreomacular traction syndrome. *Retina*. 2013;33:2012-7. <http://dx.doi.org/10.1097/IAE.0b013e3182a6b3e2>.
8. Stalmans P, Benz MS, Gandorfer A, *et al.* MIVI-TRUST Study Group. Enzymatic vitreolysis with ocriplasmin for vitreomacular traction and macular holes. *N Engl J Med*. 2012;367:606-15. <http://dx.doi.org/10.1056/NEJMoa1110823>.
9. Sharma P, Juhn A, Houston SK, Fineman M, Chiang A, Ho A, Regillo C. Efficacy of intravitreal ocriplasmin on vitreomacular traction and full-thickness macular holes. *Am J Ophthalmol*. 2015;159:861-7. <http://dx.doi.org/10.1016/j.ajo.2015.01.034>.
10. Ochoa-Contreras D, Delsol-Coronado L, Buitrago ME, Velasco-Barona C, Quiroz-Mercado H. Induced posterior vitreous detachment by intravitreal sulfur hexafluoride (SF6) injection in patients with nonproliferative diabetic retinopathy. *Acta Ophthalmol Scand*. 2000;78:687-8.
11. McHugh D, Gupta B, Saeed M. Intravitreal gas injection for the treatment of diabetic macular edema. *Clin Ophthalmol*. 2011;5:1543-8. <http://dx.doi.org/10.2147/OPTH.S25348>.
12. Mori K, Saito S, Gehlbach PL, Yoneya S. Treatment of stage 2 macular hole by intravitreal injection of expansile gas and induction of posterior vitreous detachment. *Ophthalmology*. 2007;114:127-33.
13. Kim YM, Lee SJ, Koh HJ. Gas-assisted release of vitreomacular adhesion in wet age-related macular degeneration. *Retina*. 2011;31:2123-4. <http://dx.doi.org/10.1090/IAE.0B013E31822F5720>.
14. Rodrigues IA, Stangos AN, McHugh DA, Jackson TL. Intravitreal injection of expansile perfluoropropane (c(3)f(8)) for the treatment of vitreomacular traction. *Am J Ophthalmol*. 2013;155:270-6. <http://dx.doi.org/10.1016/j.ajo.2012.08.018>.
15. Day S, Martinez JA, Nixon PA, *et al.* Intravitreal sulfur hexafluoride injection for the treatment of vitreomacular traction syndrome. *Retina*. 2016;36:733-7. <http://dx.doi.org/10.1097/IAE.0000000000000760>.
16. Steinle NC, Dhoot DS, Quezada Ruiz C, *et al.* Treatment of vitreomacular traction with intravitreal perfluoropropane (C3F8) injection. *Retina*. 2017;37:643-50. <http://dx.doi.org/10.1097/IAE.0000000000001237>.
17. Clause MG, Feron E, Veckeneer M. Pneumatic release of focal vitreomacular traction. *Eye*. 2017;31:411-6. <http://dx.doi.org/10.1038/eye2016.231>.

## Sažetak

## INTRAVITREALNO INJEKTIRANJE PERFLUOROPROPANA JE UČINKOVITIJE OD SUMPORNOG HEKSAFLUORIDA U OTPUŠTANJU VITREOMAKULARNE TRAKCIJE

*N. Čokl i M. Globočnik Petrović*

Cilj istraživanja bio je usporediti učinkovitost intravitrealne injekcije perfluoropropana (C3F8) i sumpornog heksafluorida (SF6) u otpuštanju vitreomakularne trakcije (VMT). Ova prospektivna studija uključivala je dvije skupine bolesnika sa simptomatskom VMT potvrđenom spektralnom optičkom koherentnom tomografijom (*spectral domain optic coherent tomography*, SD-OCT). Bolesnici obje skupine primili su jednu intravitrealnu injekciju ekspanzibilnog plina. Jedna skupina (29 očiju) primila je 0,3 mL 100%-tnog C3F8, a druga skupina (28 očiju) 0,3 mL 100%-tnog SF6. Kod očiju gdje otpuštanje VMT nije nastupilo jedan mjesec od injekcije SF6 primijenjena je dodatna injekcija C3F8. Primarni ishod bio je omjer očiju u svakoj skupini s potpunim otpuštanjem VMT na OCT jedan mjesec od primarnog liječenja. Sekundarni ishod bio je omjer ponovno injektiranih očiju s potpunim otpuštanjem VMT na OCT jedan mjesec nakon druge injekcije. Dodatni ishod bio je omjer otpuštanja VMT kod očiju sa specifičnim kliničkim obilježjima. Jedan mjesec od primjene lijekova potpuno otpuštanje VMT na OCT zabilježeno je u 18 od 29 (62%) očiju u skupini koja je primila C3F8, u 6 od 28 (21,4%) očiju u skupini koja je primila SF6 te u 7 od 14 (50%) očiju s ponovljenom injekcijom. Između dviju skupina nije bilo statistički značajne razlike u dobi, širini vitreomakularnog spoja (*width of vitreomacular attachment*, WVMAT), debljini središnje mrežnice i prisutnosti dodatnih obilježja. Kod očiju s WVMAT <500 mikrona nije bilo statistički značajne razlike između dva plina u otpuštanju VMT. Kod očiju s WVMAT >500 mikrona C3F8 se pokazao učinkovitijim ( $p < 0,001$ ). Prema rezultatima ovoga istraživanja izgleda da je injekcija C3F8 učinkovitija od SF6 u otpuštanju VMT kod očiju s WVMAT većom od 500 mikrona.

Ključne riječi: *intravitrealne injekcije; retinalne bolesti; prospektivne studije; tomografija, optička koherentna; ishod zdravstvene skrbi, ocjena*