



## Case report

# First case of cervical epidural abscess caused by brucellosis in Saudi Arabia: A case report and literature review

Meshal Alyousef<sup>a,\*</sup>, Rabia Aldoghaither<sup>b</sup>

<sup>a</sup> Department of adult infectious diseases, King Fahad Medical City, P.O. Box 59046, Riyadh, Saudi Arabia

<sup>b</sup> Department of adult infectious diseases, Sheikh Khalifa Medical City, P.O. Box 51900, Abu Dhabi, United Arab Emirates

## ARTICLE INFO

## Keywords:

Brucellosis  
Spinal  
Epidural abscess  
Medical  
Treatment

## ABSTRACT

Spinal epidural abscess (SEA) is an extremely rare and disastrous musculoskeletal complication of spondylodiscitis and sacroiliitis secondary to brucellosis infection. Few case reports and retrospective studies have been published reporting patients with epidural abscesses mainly lumbar, and thoracic while cervical abscess are rare. Management of spinal epidural abscess due to *Brucella* species is not standard and remains controversial. To the best of our knowledge this is the first case of brucellar cervical epidural abscess reported in Saudi Arabia. In this paper, we review the literature and report a case of a 67-year-old Saudi gentleman, who presented with fever and back pain. Further evaluation revealed cervical epidural abscess and a positive serology for brucellosis. Following 6 months of antibiotic therapy alone against brucellosis, he showed significant clinical and radiological improvement. Spinal epidural abscess caused by brucellosis is a rare condition, difficult to diagnose, and can be complicated by disastrous neurological or vascular complication if left untreated. Brucellosis must be considered as a possible cause of spinal epidural abscess in patients from endemic area. Hence, early detection and initiation of appropriate medical treatment alone is crucial in preventing permanent neurological complication, and possibly avoid surgical intervention.

## Background

Human brucellosis is one of the most common widespread zoonotic infections worldwide with more than 500,000 new cases reported annually [1,2]. Brucellosis remains endemic in Saudi Arabia with an incidence rate of 12.80 per 100,000 cases and 4062 reported cases in 2016 compared to 3661 cases in 2012 based on a Saudi national registry of MOH [3]. Despite its control in many developed countries, it constitutes a major public health problem and economic burden in Saudi Arabia [4]. Brucellosis is a systemic disease caused by bacteria of the genus *Brucella*, a gram-negative aerobic coccobacillus. *Brucella-melitensis* is the most common species responsible for the most invasive, and severe diseases worldwide followed by *brucella abortus*, *brucella suis* and *brucella canis* [7]. Humans are infected by three primary sources either by direct contact with meat or tissue of infected animals, consumption of unpasteurized dairy products from infected animals or laboratory exposure to *Brucella* isolates [5]. Brucellosis is a systemic infection with a wide range of clinical spectrum of symptoms and signs; it can involve any organs system. Osteoarticular manifestation is the most common complication and usually is presented as arthritis, sacroiliitis, spondylitis or osteomyelitis. [6,7]. It can rarely cause spinal epidural

abscess, which is difficult to diagnose, may be complicated by potentially disastrous neurological and vascular complication if left untreated [8]. Management of spinal epidural abscess is controversial. However, several cases of successful treatment with antibiotic alone have been reported in particular in patients with stable neurological condition. In our case, patient had no neurological deficit and was successfully treated with antibiotic for 6 months with significant clinical and radiological improvement. Brucellar spinal epidural abscess's recovery with medical treatment can be achieved without the need for surgical approaches and its complications, especially if detected and treated early. Herein, we review the literature and describe a case of brucellar spinal epidural abscess in which the patient achieved a complete recovery with only medical treatment.

## Case presentation

A 67-year-old Saudi gentleman with a medical history of diabetes mellitus, hypothyroidism, vitiligo, benign prostatic hypertrophy and a prior history of brucellosis, presented to our emergency department with four-month history of fever, night sweats, loss of appetite, back pain, anorexia, fatigue, nausea and vomiting. He also reported contact

\* Corresponding author.

E-mail address: [maayousef@kfmc.med.sa](mailto:maayousef@kfmc.med.sa) (M. Alyousef).

with camels and ingestion of unpasteurized milk in the past. One month prior to admission, he had a motor vehicle accident for which he was diagnosed with compression fractures at thoracolumbar region involving T12 – L3. On clinical examination, he looked comfortable but in mild pain with a temperature of 38.2 °C; pulse rate of 114 beats per minutes; blood pressure 116/68 mmHg; and respiratory rate of 21 breaths per minute. Pertinent findings on physical exam are local tenderness over cervical and lumbar vertebrae and hepatomegaly. No neurological deficit or meningeal signs were noted.

Laboratory investigation showed white blood cell count  $3.79 \times 10^9/L$ ; hemoglobin 11.10 g/dL; platelet count  $156 \times 10^9/L$ ; ESR 55 mm/H; CRP 152 mg/L; alanine transaminase 59 U/I; aspartate transaminase 88 U/I; alkaline phosphatase 97 U/I; gamma GT 95 U/I; total bilirubin 0.7 mg/dL; albumin 30 g/L; total protein 72 g/L; creatinine 1.3 mg/dL; urea 6 mmol/L. Brucella serology using enzyme-linked immunosorbent assay was positive for IgG (17.9) and negative for IgM with positive agglutination titer of 1/ 2560. Blood cultures were negative. Magnetic resonance imaging of the cervical spine showed evidence of spondylodiscitis at C5–C7 with posteriorly located intraspinal epidural collection measuring  $1.8 \times 2.2 \times 4$  cm and extending from C5 to C7 causing moderate spinal stenosis without spinal cord compression (Fig. 1).

Given his clinical presentation, prior history of brucellosis, raw milk ingestion, camel contact and a positive brucella serology test, he was diagnosed as a case of acute brucellosis and he was started on doxycycline and an aminoglycoside. Later, his magnetic resonance imaging of cervical spine showed spinal epidural abscess and rifampicin was added as a third agent. Few days following treatment, all his symptoms recovered with exception to his cervical back pain which was gradually improving.

Patient's condition was discussed with spine surgeon to evaluate the need for surgical intervention and it was decided to continue on medical treatment alone, as there was no neurological deficit.

During his regular follow-ups in ID clinic, his back pain started to

improve gradually, his brucella agglutination titer and inflammatory markers were trending down slowly and eventually normalized. Following 6 month of therapy, his repeated magnetic resonance imaging (MRI) showed interval improvement in epidural collection in C5–C7 and at that point his antibiotics were stopped after completing six months of therapy (Fig. 2).

The patient continued to follow up in ID clinic for 1 year and during that time, he remained symptoms free with a normal brucella agglutination titer.

## Discussion

Osteoarticular complications secondary to brucellosis like sacroiliitis, spondylitis, peripheral arthritis and osteomyelitis are the most common and frequent of the disease. However, brucellar spinal epidural abscess is a rare complication, which is usually due to spondylitis [9,10].

To the best of our knowledge, no case of spinal epidural abscess associated with brucellosis has been reported in Saudi Arabia before. Moreover, Literature review using PubMed/MEDLINE (1950–2017) yielded 52 adult cases of brucellar epidural abscess published in the English literature to date, in which complete recovery was achieved with medical treatment only in 18 cases. The rest were treated with surgical approach combined with medical treatment. Baseline demographics, risk factors, involved location, antibiotic regimen and duration are shown in (Table 1).

We identified 19 patients, 10 males (58.8%) and 7 females (41.7%), with a mean age of 49.5 years at the time of diagnosis (range, 31–70 years). The most epidemic countries were Spain (47%), Turkey (23.5%) followed by Korea, Tunisia, Greece, Italy and Saudi Arabia. Unpasteurized milk ingestion (23.5%) was the most common risk factor. The frequency of spinal involvement was seen at Lumbar (40.9%), cervical (31.8%), thoracic (13.6%), sacral (13.6%), respectively. *B. melitensis* was the most common isolated specie (18.1%).

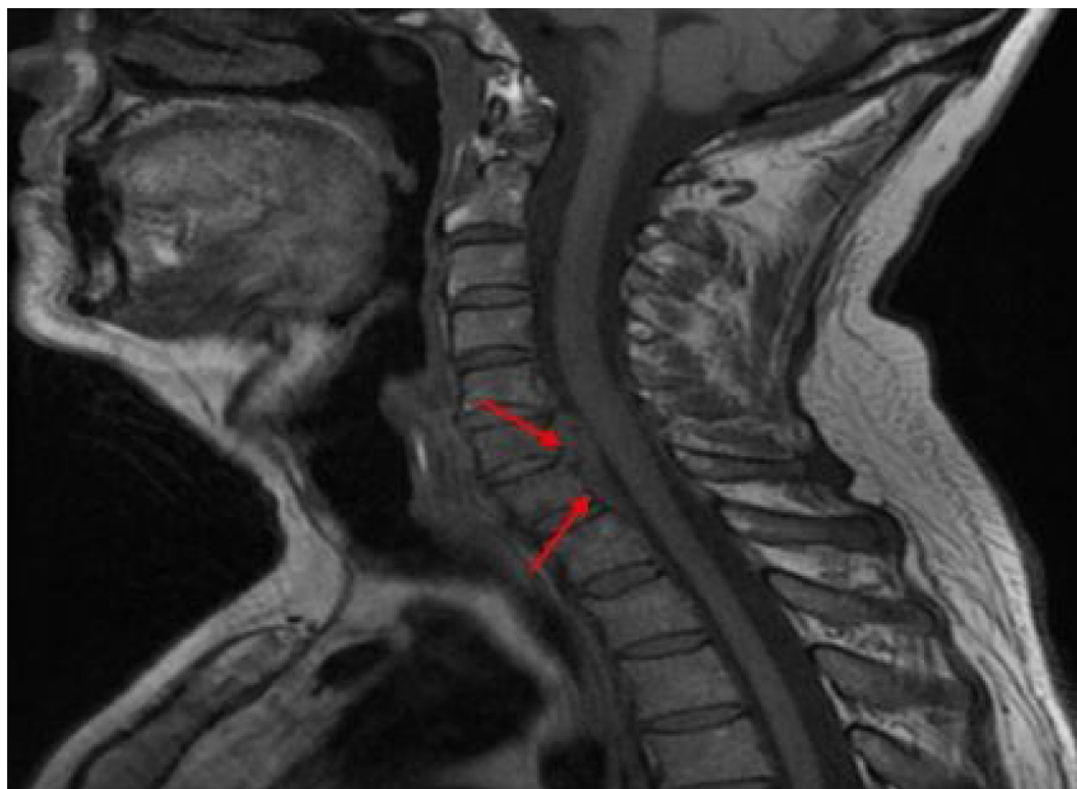


Fig. 1. Sagittal cervical T1 weighted magnetic resonance imaging (MRI) showing epidural collection along the posterior aspect of C5–C7 vertebral bodies causing moderate spinal stenosis.

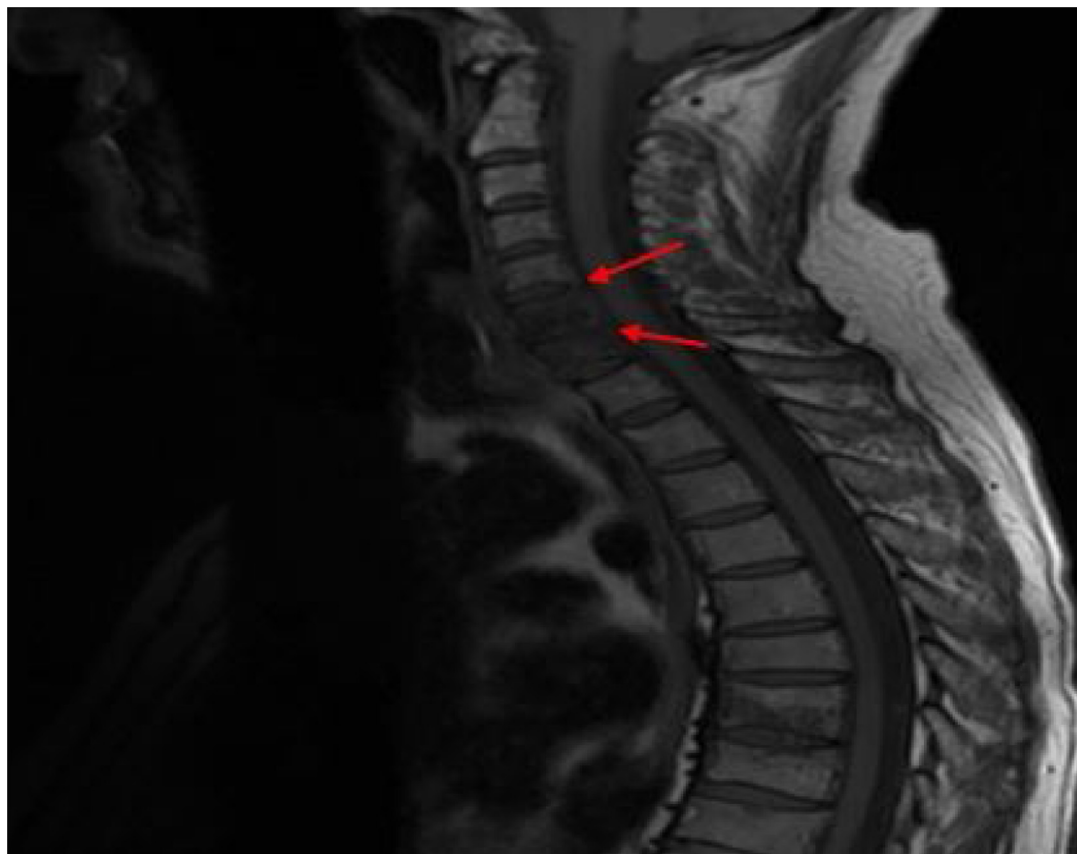


Fig. 2. Control Sagittal cervical T1 weighted magnetic resonance imaging (MRI) showing significant improvement of the epidural collection.

Spinal cord compression was observed in 52.6% of patients. Triple-regimen (Doxycycline + Rifampicin + streptomycin or gentamicin or cotrimoxazole) was used in more than half of patients (52.9%, n = 9) followed by double regimen (41.1%, n = 7) and monotherapy (5.8%, n = 1). The median duration of antimicrobial therapy against brucellosis was 2 months (range, 2–6 months). Complete recovery was achieved in all patients and mortality was not seen in any of the patients.

Normally, the reticuloendothelial system eliminates the organism from the bloodstream. However, sometimes organisms can proliferate away from the primary focus in immunocompromised patients with diabetes mellitus, chronic kidney disease, alcoholism, previous infection, leading to hematogenous spread of the organism from other focus of infection into the epidural space, especially the posterior space as it contains small arteries and the venous plexus [23].

Secondary spinal epidural abscess occurs usually after manipulation of the spinal column by spinal interventions, surgeries or trauma. In our patient, it seems that he has had acute brucellosis that was manifested after he had a road traffic accident that manipulated his spinal column one month prior to admission.

Signs of brucellar epidural abscess are non-specific, but can vary from fever, spinal tenderness, lower limb weakness, sensory loss or sphincter loss due to spinal cord compression and subsequent spinal stenosis in case of delayed diagnosis. Spinal tenderness is the commonest sign seen on examination [23]. Fever is absent in half of patients [23,24]. In our case, the patient presented with fever, back pain with local tenderness along the cervical vertebrae only with no motor or sensory deficit.

Magnetic resonance imaging is the best imaging modality for SEP detection. It is superior to compute tomography as it has the ability to detect anatomical information related to epidural space and spinal cord [25]. MRI findings of brucella spondylitis can be seen within 30 days

after the onset of symptoms [34].

Theodore Gouliouris et al and his colleagues, stated that brucellar spondylitis affects predominantly the lumbar spine, particularly the L4-L5 level, which was also observed in this case series. Characteristic features of brucellar epidural abscess includes, anterior superior endplate and disc involvement, hyper intense signals in the intervertebral disc on T2-weighted and contrast-enhanced images, Peri-lesional bone formation with osteophytosis and osteophyte formation at the anterior vertebral endplate (parrot's beak) [26].

The optimal antibiotic regimen and duration of treatment for brucellar spinal abscess is still controversial in the literature. In general, combination therapy of doxycycline plus streptomycin for at least 12 weeks is accepted by WHO and still the first line [27]. However, side effects, possible drug-drug interaction, patient's clinical and radiological response should be addressed when choosing the antibiotics and its duration [28].

In spinal brucellosis, Emine Alp and his colleagues concluded that Ciprofloxacin-rifampicin regimen is as effective as the classical regimen doxycycline-rifampicin as the duration of the therapy and clinical response were not different in their study between both, but quinolones has higher cost rates [29]. In another study, It was also shown that doxycycline-streptomycin regimen is more effective than doxycycline-rifampicin in brucellosis treatment [30]. Adding a third agent will give higher frequency of clearance of brucella DNA from blood based on an observational study [31]. However, in a systematic review and meta-analysis of randomized clinical trials, triple therapy should not be considered the current treatment of choice for human brucellosis [32]. In our patient, complete recovery was achieved with doxycycline-streptomycin regimen plus rifampicin for 6 months.

Follow up magnetic resonance imaging should not be obtained routinely to assess the response to anti-microbial therapy if there is no clinical deterioration, as Kowalski et al concluded in a retrospective

**Table 1**  
Baseline demographics, risk factors, involved location, antibiotic regimen and duration of patients.

Case number	Author	Published year	Country	Number of cases	Age/Sex	Risk factors	Co-morbidities	location	Antibody titer	Isolate	Spinal cord compression	Antibiotics regimen	Duration	Outcome
1	perez-calvo et al. [11]	1994	Spain	1	62/male	N/A	Free	L5-S1	1/5120	B.melitensis	Yes	Doxycycline Rifampicin	6 weeks	Recovery
2	perez-calvo et al. [11]	1994	Spain	1	34/male	N/A	Free	L5-S1	1/2560	B.melitensis	Yes	Streptomycin <sup>a</sup> Doxycycline Rifampicin	6 months	Recovery
3	Solera et al. [12]	1999	Spain	2	N/A	N/A	N/A	C5-C6 C6-C7	N/A	N/A	No	Cotrimoxazole N/A	N/A	Recovery
4	Pha et al. [13]	2001	Spain	1	53/female	Farmer	Free	C5-C6	1/80	N/A	No	Doxycycline Rifampicin	4 months	Recovery
5	Malavolta et al. [14]	2002	Italy	1	45/female	N/A	Free	L4-L5	1/640	N/A	Yes	streptomycin <sup>a</sup> Doxycycline	8 weeks	Recovery
6	Ugarriza et al. [15]	2005	Spain	5	47/female 56/female 31/male 55/male 34/male	Unpasteurized milk ingestion	Free	C5-T1	160/1 <	B.melitensis	Yes	Rifampicin Doxycycline Rifampicin	8 weeks	Recovery
7	Guzey FK et al. [16]	2007	Turkey	1	61/male	N/A	Free	C2-C3	1/640	Brucella abortus	Yes	Doxycycline Rifampicin	24 weeks	Recovery
8	Nas et al. [17]	2007	Turkey	1	35/female	raw goat's milk cheese	Free	C1-C2	1/320	N/A	Yes	Streptomycin <sup>a</sup> Doxycycline Rifampicin	6 months	Recovery
9	Sengul et al. [18]	2008	Turkey	1	37/male	Farmer	Free	C7-T1	1/160	N/A	Yes	Cotrimoxazole Doxycycline Rifampicin	3 months	Recovery
10	Kim et al. [19]	2008	Korea	1	56/male	Farmer and cow breeding	Free	L4-L5	1/320	N/A	No	Streptomycin <sup>a</sup> Doxycycline Rifampicin	7 weeks	Recovery
11	Chelli bouaziz et al. [20]	2010	Tunisia	1	66/male	N/A	Free	L2-L3	1/240	N/A	Yes	Gentamycin Rifampicin Rovamycin	8 weeks	Recovery
12	Christos et al. [21]	2012	Greece	1	70/female	Farmer and sheep breeding	Hypertension	C4-C5	- ve	N/A	Yes	Doxycycline Rifampicin	4 months	Recovery
13	Ahmet et al. [22]	2013	Turkey	1	33/female	Unpasteurized milk ingestion	Free	L3-L4	1/160	N/A	Yes	Streptomycin <sup>a</sup> Doxycycline	16 weeks	Recovery
14	Our patients	2017	Saudi Arabia	1	67/male	Unpasteurized milk ingestion	DM	C5-C7	1/2560	N/A	No	Rifampicin Doxycycline Rifampicin Gentamicin <sup>b</sup>	6 months	Recovery

<sup>a</sup> Streptomycin was given for 21 days.

<sup>b</sup> Gentamicin was given 10–15 days.

cohort study involving One-hundred seventy-five, that there was no significant correlation between clinical status and MRI findings in 4–8 weeks follow up. However, if there is, demonstrating diminished soft tissue inflammation will be the first sign of improvement [33].

Surgical treatment is indicated in case of persistence or progression of neurological deficit, spinal instability and progressive collapse of vertebrae and non-responsiveness to antimicrobial therapy [30].

## Conclusion

Acute brucellosis should be highly suspected in patients with spinal epidural abscess along with staphylococcus aureus and tuberculosis, especially in endemic areas. Brucellar spinal epidural abscess can be treated medically if there is no neurological deficit. Early recognition and treatment is critical to avoid serious sequela, surgical intervention and its complications. Anti-brucellar treatment should be extended particularly in case of spinal epidural abscess.

## Acknowledgment

None.

## References

- Pappas G, Papadimitriou P, Akritidis N, Christou L, Tsianou EV. The new global map of human brucellosis. *Lancet Infect Dis* 2006;6(2):91–9. [http://dx.doi.org/10.1016/S1473-3099\(06\)70382-6](http://dx.doi.org/10.1016/S1473-3099(06)70382-6).
- Aturi VL, Xavier MN, De Jong MF, Den Hartigh AB, Tsolis REM. Interactions of the human pathogenic *Brucella* species with their hosts. *Annu Rev Microbiol* 2011;65:523–41. <http://dx.doi.org/10.1146/annurev-micro-090110-102905>.
- The statistical yearbook of notifiable infectious diseases; incidence rates and reported cases of brucellosis. Saudi ministry of health, Saudi Arabia, 2016.
- Elbeltagy KE. An epidemiological profile of brucellosis in Tabuk Province, Saudi Arabia. *East Mediterr Health J* 2001;7(4-5):790–8.
- Traxler RM, Lehman MW, Bosserman EA, Guerra MA, Smith TL. A literature review of laboratory-acquired brucellosis. *J Clin Microbiol* 2013;51(September (9)):3055–62. <http://dx.doi.org/10.1128/JCM.00135-13>. Epub 2013 July 3.
- Gür A, Geyik MF, Dikici B, Nas K, Cevik R, Sarac J, Hosoglu S. Complications of brucellosis in different age groups: a study of 283 cases in southeastern Anatolia of Turkey. *Yonsei Med J* 2003;44(1):33–44. <http://dx.doi.org/10.3349/ymj.2003.44.1.33>.
- Andriopoulos P, Tsironi M, Deftereos S, Aessopos A, Assimakopoulos G. Acute brucellosis: presentation, diagnosis, and treatment of 144 cases. *Int J Infect Dis* 2007;11(1):52–7. <http://dx.doi.org/10.1016/j.ijid.2005.10.011>.
- Mehanic S, Baljic R, Mulabdic V, Huric-Jusufović I, Pinjo F, Topalovic-Cetkovic J, et al. Osteoarticular manifestations of brucellosis. *Clinic for infectious diseases, Clinical Center of University of Sarajevo, Bosnia and Herzegovina. Med Arch* 2012;66(3 Suppl. 1):24–6.
- Spink WW. *The nature of brucellosis*. Minneapolis: Univ of Minnesota Press; 1956.
- Gonzalez-Gay MA, Garcia-Porrúa C, Ibanez D, Garcia-Pais MJ. Osteoarticular complications of brucellosis in an Atlantic area of Spain. *J Rheumatol* 1999;26:141–5.
- Pérez-Calvo Juan, Matamala Carlos, Sanjoaquin Isabel. Epidural abscess due to acute *Brucella melitensis* infection. *Arch Intern Med* 1994;154(12):1410. <http://dx.doi.org/10.1001/archinte.1994.00420120142015>.
- Solera J, Lozano E, Martínez-Alfaro E, Espinosa A, Castillejos ML, Abad L. Brucellar spondylitis: review of 35 cases and literature survey. *Clin Infect Dis* 1999;29:1440–9.
- Pina MA, Modrego PJ, Uroz JJ, et al. Brucellar spinal epidural abscess of cervical location: report of four cases. *Eur Neurol* 2001;45:249–53.
- Malavolta N, Frigato M, Zanardi M, et al. Brucella spondylitis with paravertebral abscess due to *Brucella melitensis* infection: a case report. *Drugs Expt Clin Res* 2002;28:95–8.
- Uqarriza LF, Porras LF, Lorenzana LM, et al. Brucellar spinal epidural abscesses. Analysis of eleven cases. *Br J Neurosurg* 2005;19:235–40.
- Güzey FK, Emel E, Sel B, Bas NS, Ozkan N, Karabulut C, Solak O, Esenyel M. Cervical spinal brucellosis causing epidural and prevertebral abscesses and spinal cord compression: a case report. *Spine J* 2007;7:240–4.
- Nas Kemal, Tasdemir Nebahat, Cakmak Erkan, Kemaloglu Mustafa Serdar, Bukte Yasar, Geyik Mehmet Faruk. Cervical intramedullary granuloma of Brucella: a case report and review of the literature. *Eur Spine J* 2007;16(Suppl. 3):S255–9. <http://dx.doi.org/10.1007/s00586-006-0252-3>.
- Sengul G, Akar A, Alper F, Uslu H. Nonsurgically treated cervical brucellar epidural abscess causing spinal cord compression. *J Clin Neurosci* 2008;15:1411–4.
- Kim Dae-Hyun, Cho Young-Dae. A case of spondylodiscitis with spinal epidural abscess due to *Brucella*. *J Korean Neurosurg Soc* 2008;43:37–40.
- Chelli Bouazziz M, Bougamra I, Kaffel D, Hamdi W, Ghannouchi Mehdi, Kchir MM. Non contiguous multilevel spondylitis: an exceptional presentation of spinal brucellosis. *Tunis Med* 2010;88(n°4):280–4.
- Lampropoulos Christos, Kamposos Panagiotis, Papaioannou Ioanna, Niarou Vasiliki. Cervical epidural abscess caused by brucellosis. *BMJ Case Rep* 2012. <http://dx.doi.org/10.1136/bcr-2012-007070>.
- Boyaci A, Boyaci N, Tutoglu A. Spinal epidural abscess in brucellosis. *BMJ Case Rep* 2013. <http://dx.doi.org/10.1136/bcr-2013-200946>.
- Sendi P, Bregenzner T, Zimmerli W. Spinal epidural abscess in clinical practice. *Q J Med* 2008;101(no. 1):1–12.
- Ulu-Kilic A. Update on treatment options for spinal brucellosis. *Clin Microbiol Infect* 2014;20(February (2)):O75–82. <http://dx.doi.org/10.1111/1469-0691.12351>. Epub 2013 October 1.
- Modic MT, Feiglin DH, Piraino DW, Boumpfhey F, Weinstein MA, Duchesneau PM, Rehm S. Vertebral osteomyelitis: assessment using MR. *Radiology* 1985;157:157–66.
- Gouliouris T, Aliyu SH, Brown NM. Spondylodiscitis: update on diagnosis and management. *J Antimicrob Chemother* 2010;65(November (Suppl. 3)):iii11–24. <http://dx.doi.org/10.1093/jac/dkq303>.
- Young EJ. *Brucella species*. Mandell GL, Bennett JE, Dolin R, editors. *Principles and practice of infectious diseases*. 6, vol. 2. Philadelphia: Churchill Livingstone; 2005. pp. 2669–2674.
- Ulu-Kilic A. Update on treatment options for spinal brucellosis. *Clin Microbiol Infect* 2014;20(February (2)):O75–82. <http://dx.doi.org/10.1111/1469-0691.12351>. Epub 2013 October 1.
- Alp E, Doganay M. Current therapeutic strategy in spinal brucellosis. *Int J Infect Dis* 2008;12(November (6)):573–7. <http://dx.doi.org/10.1016/j.ijid.2008.03.014>. Epub 2008 June 9.
- Solera J. Doxycycline-rifampin versus doxycycline-streptomycin in treatment of human brucellosis due to *Brucella melitensis*. *Antimicrob Agents Chemother* 1995;39(September (no. 9)):2061–7. <http://dx.doi.org/10.1128/AAC.39.9.2061>.
- Vrioni Georgia, Bourdakis Adamantios, Pappas Georgios, Pitiriga Vassiliki, Mavrouli Maria, Pournaras Spyros, Tsakris Athanassios. Administration of a triple versus a standard double antimicrobial regimen for human brucellosis more efficiently eliminates bacterial DNA load. *Antimicrob Agents Chemother* 2014;58(no. 12):7541–4.
- Soli 's Garcı́a del Pozo J, Solera J. Systematic review and meta-analysis of randomized clinical trials in the treatment of human Brucellosis. *PLoS One* 2012;7(2):e32090. <http://dx.doi.org/10.1371/journal.pone.0032090>.
- Kowalskia TJ, Laytonb KF, Berbaria EF, Steckelberg JM, Huddlestonc PM, Waldbd JT, Osmona DR. Follow-up MR imaging in patients with pyogenic spine infections: lack of correlation with clinical features. *AJNR* 2007;28(April):693–9.
- Pina MA, Ara JR, Modrego PJ, Juyol MC, Capablo JL. Brucellar spinal epidural abscess. *Eur J Neurol* 1999;2013:87–9.