

Received: 2022.07.25

Accepted: 2022.10.28

Available online: 2022.11.09

Published: 2022.11.27

Combined Intrathoracic and Abdominal Splenosis

Authors' Contribution:

Study Design A
Data Collection B
Statistical Analysis C
Data Interpretation D
Manuscript Preparation E
Literature Search F
Funds Collection GE **Min Gyeong Choi**
F **Wongi Woo**
B **Joon Young Chang**
F **Bong Jun Kim** 
A **Youngwoong Kim**
E **Duk Hwan Moon**
A **Sungsoo Lee**Department of Thoracic and Cardiovascular Surgery, Gangnam Severance Hospital,
Yonsei University College of Medicine, Seoul, South Korea

Corresponding Author: Duk Hwan Moon, e-mail: PUPUPUCK@yuhs.ac
Financial support: None declared
Conflict of interest: None declared

Patient: Male, 50-year-old
Final Diagnosis: Thoracic splenosis
Symptoms: Chest pain
Medication: —
Clinical Procedure: —
Specialty: Surgery

Objective: Rare disease

Background: Splenosis refers to autotransplantation of splenic tissue after splenic injury or splenectomy, most frequently occurring in the abdominal and pelvic cavities. Thoracic splenosis is a rare condition associated with a history of simultaneous rupture of the spleen and diaphragm resulting from trauma. To the best of our knowledge, only a limited number of cases have been reported for combined intrathoracic and abdominal splenosis.

Case Report: We present a case of a 50-year-old man with a history of splenectomy and left nephrectomy 15 years ago due to an accident, who had experienced chest pain for the past month. A 1-cm focal pleural thickening in the left posterior pleura was revealed on the chest computed tomography (CT) scan. We found this to be suspicious for a solitary fibrous tumor. Based on this information, surgery was performed for tumor removal, and the pathologic examination confirmed splenic tissues. The patient was then discharged without any complications. Further abdominopelvic CT showed several contrast-enhanced lesions, suggestive of intraperitoneal splenosis.

Conclusions: We would like to emphasize the importance of thorough history-taking to avoid misdiagnosis and unnecessary procedures with respect to the rarity of splenosis. Moreover, appropriate use of diagnostic tools, including radionuclide imaging studies, is recommended to establish an accurate diagnosis of thoracic splenosis.

Keywords: Splenectomy • Splenosis

Full-text PDF: <https://www.amjcaserep.com/abstract/index/idArt/937902>



1198



—



4



9



Background

Thoracic splenosis is a rare condition in which the splenic tissues are autotransplanted into the pleural cavity, usually followed by splenic rupture or splenectomy. The splenic tissue is usually found in the left hemithorax, particularly attached to the parietal or visceral pleura [1,2]. Furthermore, to the best of our knowledge, only a limited number of cases of combined intrathoracic and abdominal splenosis have been reported [3-5]. Herein, we report a case of a 50-year-old man with previous trauma history who was diagnosed with combined intrathoracic and abdominal splenosis.

Case Report

A 50-year-old man patient presented to our institution with chest pain that started a month ago. He underwent splenectomy with left nephrectomy 15 years ago due to an accident, and a posterior interbody fixation 12 years ago due to a T3 compression fracture. No other medical history or recent trauma history was present. The physical examination was unremarkable, and laboratory tests were normal. Chest radiography showed an old fracture on the left 7th rib. A chest computed tomography (CT) scan was performed for further evaluation, showing a 1-cm focal pleural thickening in the left costal pleura (Figure 1), which was suspicious for an early solitary fibrous tumor or localized pleural thickening.

Video-assisted thoracoscopic surgery (VATS) was performed for pathologic confirmation and symptom alleviation. Due to the pleural adhesion, which may have resulted from previous chest tube insertion, adhesiolysis was done. A chest wall mass, as observed on chest CT, was identified; it appeared to

be soft, well-circumscribed, and highly vascularized. Visual inspection also revealed multiple nodules diffusely distributed on the surface of the lung and diaphragm (Figure 2). An excisional biopsy for frozen section was taken for the mass in the left costal pleura, confirming a lymph node with reactive hyperplasia. Wedge resection of the left lower lobe was performed to obtain a pathological result of dispersed nodules. Then, the chest tube was inserted after applying the anti-adhesive, completing the operation.

On the gross examination, the nodule on the left lower lobe was 0.5 cm, with a well-demarcated oval shape (Figure 3). The histological analysis of both specimens from the left costal pleura and the left lower lobe confirmed the presence of accessory splenic tissue. The patient's postoperative course was uneventful; the chest tube was removed and the patient was discharged on the next day. On the 7-day postoperative follow-up, several well-enhanced soft-tissue lesions, up to 2.6 cm in size, on the left upper abdomen, right posterior subphrenic space, and right pelvic cavity were revealed by an abdominopelvic CT (at least 12 lesions). This suggested the possibility of splenosis related to the patient's previous splenectomy (Figure 4). The patient was seen 2 more times, with a 1-week interval between visits. He recovered well, without any clinical symptoms, and no more follow-ups were needed. The patient provided written informed consent for publication of his clinical details and images.

Discussion

Thoracic splenosis is a rare condition in which the splenic tissues are autotransplanted into the pleural cavity, usually followed by both splenic and diaphragmatic injury. Although the

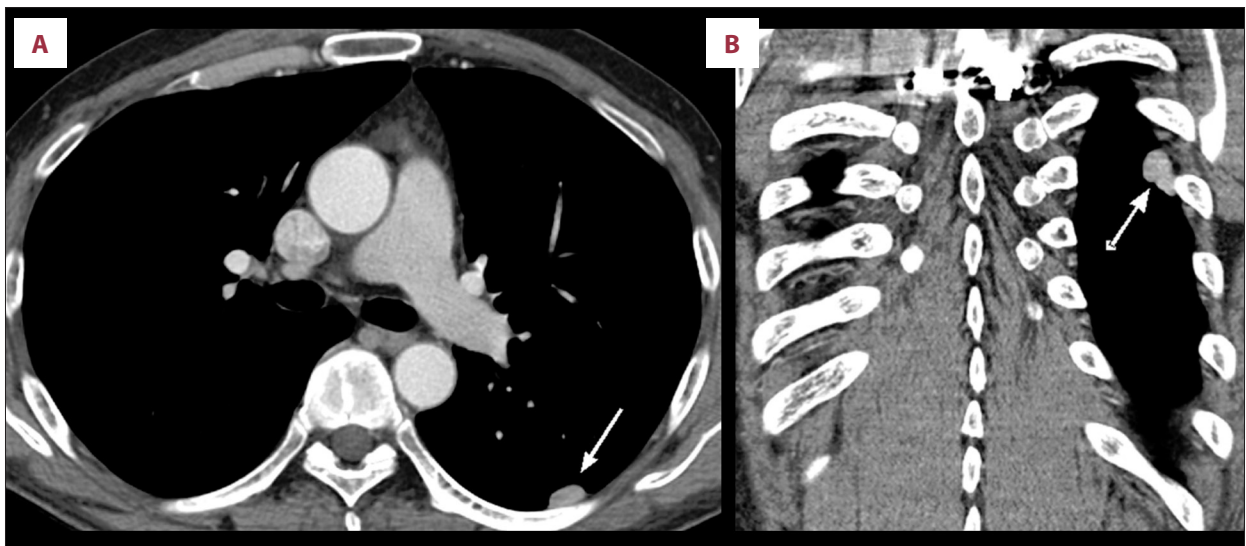


Figure 1. Coronal (A) and sagittal (B) chest CT revealing 1-cm focal pleural thickening in left pleura (arrows).

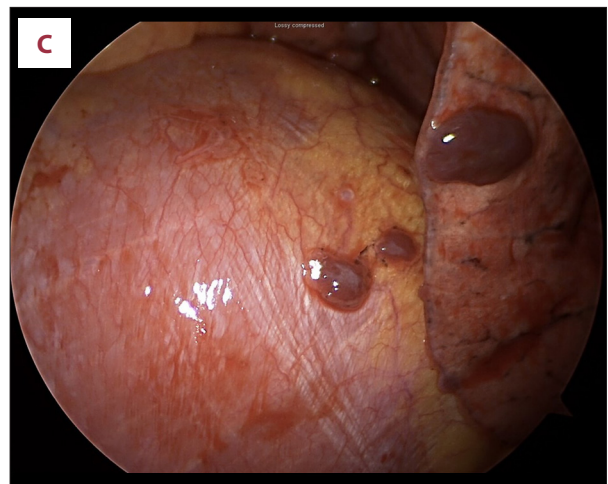
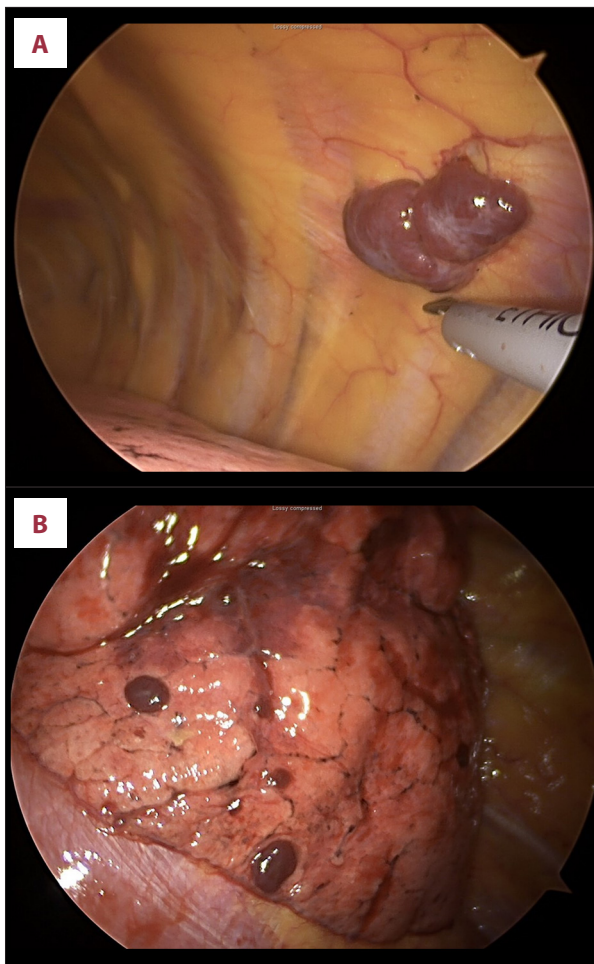


Figure 2. A soft, well-circumscribed, red mass was identified on the chest wall (A). Multiple soft, red nodules were diffusely distributed on the surface of the lung and diaphragm (B, C).

patient could not remember the exact procedures he had undergone for the previous accident, the pleural adhesion we found in the operating room suggested diaphragmatic injury and subsequent chest tube insertion after the accident. However, it is also possible that after trauma to the spleen, peritoneal blood flow through normal diaphragmatic foramina caused the implantation of splenic tissue within the thorax [6].

Patients with thoracic splenosis are commonly asymptomatic and discovered incidentally; however, in less than 10-15% of cases, patients present with chest pain, hemoptysis, or cough [2]. In our case, although the patient had an old rib fracture from previous trauma, it was not likely to be the main source of the chest pain that had recently developed. We suspected that the chest pain was due to ectopic splenic tissue caused by mechanical irritation or pressure. The disappearance of pain after the surgery has reinforced our presumption.

Making the diagnosis of splenosis is challenging without a specific history of splenic trauma. In chest CTs, a solitary pleura-based nodule is found in 25% of thoracic splenosis cases, and multiple nodules are found in the remaining 75% of cases [1]. If splenosis is not suspected, needle- or video-assisted thoracic surgery is commonly performed for biopsy, as pleura-based nodules can be malignant [7]. Pleural metastases, lymphoma, localized fibrous tumor of the pleura, malignant

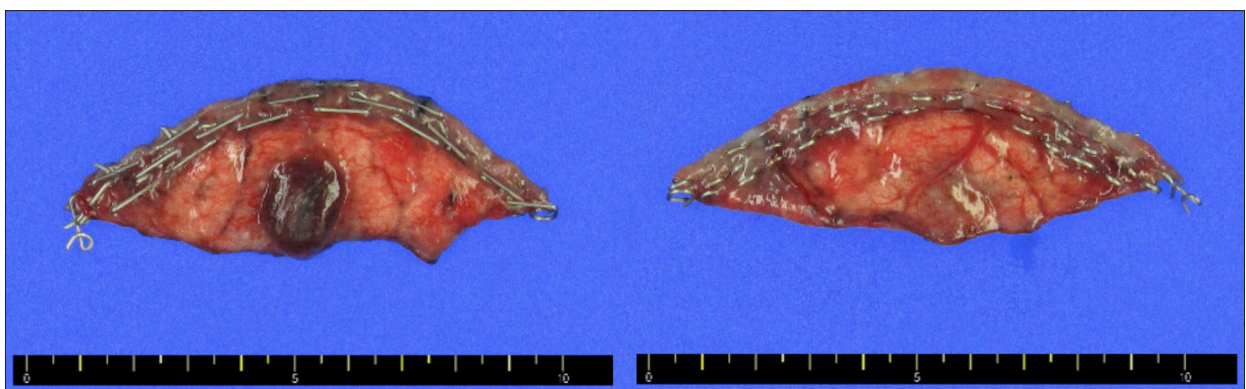


Figure 3. The specimen from a wedge resection of the left lower lobe of the lung, measuring 2.7×0.8×0.4 cm. The nodule was 0.5 cm, with a well-demarcated oval shape. Each interval of the scale indicates 0.3 cm, and the power of magnification is 1: 0.3.

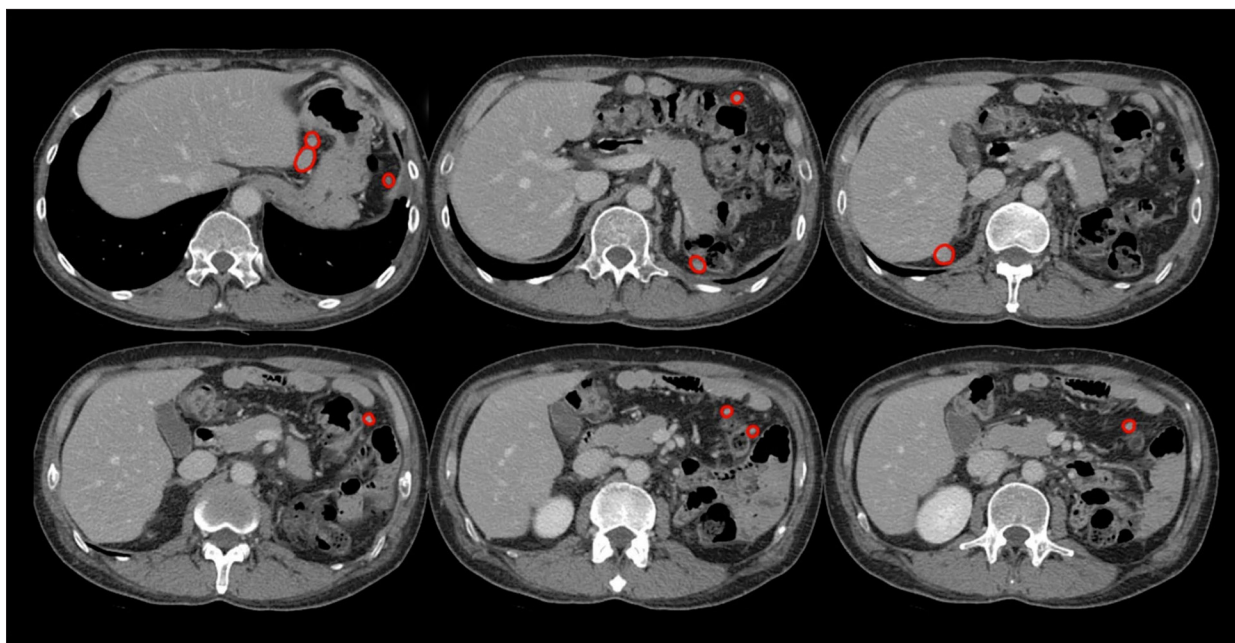


Figure 4. Abdominopelvic CT showing multiple soft-tissue lesions caused by the previous splenectomy. Several well-enhanced, soft-tissue lesions up to 2.6 cm in size were found in the left upper abdomen, right posterior subphrenic space, and right pelvic cavity (circled in red).

mesothelioma, and invasive thymoma should be considered in the differential diagnosis of splenosis [8].

However, biopsy is not recommended for splenosis itself; it can lead to a misdiagnosis if the pathologist is not aware of the patient's history of splenic trauma [5], and the quality of the specimen may be inadequate to accurately assess the detailed structure of the splenic tissue [7]. Therefore, when the possibility of splenosis is considered, radionuclide imaging studies are suggested to minimize unnecessary biopsies or surgical procedures [5]. Tc-99m sulfur colloid is sequestered in the reticuloendothelial system of ectopic splenic tissue, and can be used to make a diagnosis. Indium-111-labeled platelets and Tc-99m-labeled heat-damaged red blood cells are the optimal imaging techniques for splenosis due to their high sensitivity and specificity for splenic sequestration and phagocytosis [5]. The absence of Howell-Jolly bodies, erythrocyte pitting, and siderocytes in the peripheral blood smear also demonstrate the presence of residual splenic tissue [9].

If there are no symptoms, surgical removal of the ectopic splenic tissue is generally not recommended, as it can lead to systemic encapsulated bacterial infection, which can be a lethal to asplenic patients [6]. Surgery is indicated only in symptomatic patients or in those for whom pathologic diagnosis is necessary [8]. Our patient was experiencing chest pain due to the mass, and regardless of the diagnosis made via core-needle biopsy, surgery was needed for symptom relief. Therefore, the

biopsy was omitted and the surgery was carried out immediately for both diagnosis and treatment. Magnetic resonance imaging (MRI) was not performed, not only because it is not the criterion standard for the diagnosis of solitary fibrous tumor, but also because there was no suspicion of severe pleural adhesion based on the CT findings, which would make the surgery difficult. Since VATS is less invasive than thoracotomy, and the cost of surgery is much lower than that of performing an MRI in Korea, it was reasonable to choose surgery over other diagnostic evaluations for accurate diagnosis and rapid symptom relief.

Although the multiple masses found in the abdominal space were not resected for histologic confirmation in our case, the likelihood of them being intraperitoneal splenosis was very high based on the CT findings and the histopathology of the thoracic mass.

Conclusions

As thoracic splenosis is rare and often overlooked, a thorough history-taking is essential. In most cases, this is an incidental post hoc diagnosis, and surgery is generally not necessary if the condition is diagnosed before an intervention is performed. Surgery may be performed when there is diagnostic uncertainty or for symptom relief. Radionuclide imaging studies may help if this condition is suspected.

Declaration of Figures' Authenticity

All figures submitted have been created by the authors who confirm that the images are original with no duplication and have not been previously published in whole or in part.

References:

1. Lake ST, Johnson PT, Kawamoto S, et al. CT of splenosis: Patterns and pitfalls. *Am J Roentgenol*. 2012;199(6):W686-93
2. Tulinský L, Ihnát P, Mitták M, et al. Intrathoracic splenosis – lesson learned: A case report. *J Cardiothorac Surg*. 2016;11(1):72
3. Javadrashid R, Paak N, Salehi A. Combined subcutaneous, intrathoracic and abdominal splenosis. *Arch Iran Med*. 2010;13(5):436-39
4. Kosydar SR, Sanchirico PJ, Pfeiffer DC. A case of thoracoabdominal splenosis. *Radiol Case Rep*. 2020;15(1):7-10
5. Moon C, Choi YJ, Kim EY, et al. Combined intrathoracic and intraperitoneal splenosis after splenic injury: Case report and review of the literature. *Tuberc Respir Dis*. 2013;74(3):134-39
6. Buchino JJ, Buchino JJ. Thoracic splenosis: *South Med J*. 1998;91(11):1054-56
7. Kim K, Choi HJ, Kim YM, et al. Thoracic Splenosis: A case report and the importance of clinical history. *J Korean Med Sci*. 2010;25(2):299-303
8. Lopes B, Almeida LR, Vicente AA, et al. Thoracic splenosis as a differential diagnosis of juxtapleural nodules. *Respir Med Case Rep*. 2014;11:1-3
9. Khan AM, Manzoor K, Malik Z, et al. Thoracic splenosis: Know it – avoid unnecessary investigations, interventions, and thoracotomy. *Gen Thorac Cardiovasc Surg*. 2011;59(4):245-53