



## Outcomes of reverse shoulder arthroplasty following failed superior capsular reconstruction

Kevin M. Magone, MD<sup>a</sup>, Yaniv Pines, MD<sup>a</sup>, Dan Gordon, MD<sup>a</sup>, Erel Ben-Ari, MD<sup>a,b</sup>, Young W. Kwon, MD, PhD<sup>a</sup>, Joseph D. Zuckerman, MD<sup>a</sup>, Mandeep S. Virk, MD<sup>a,\*</sup>

<sup>a</sup>Department of Orthopedic Surgery, New York University Langone Orthopedic Hospital, New York, NY, USA

<sup>b</sup>Division of Orthopedic Surgery, Tel-Hashomer "Sheba" Medical Center, Sackler School of Medicine, Tel-Aviv University, Ramat Gan, Israel

### ARTICLE INFO

#### Keywords:

Superior capsular reconstruction (SCR)  
Irreparable rotator cuff tear  
Rotator cuff tear  
Reverse total shoulder arthroplasty  
Failed superior capsular reconstruction  
Failed rotator cuff repair

Level of evidence: Level III; Retrospective Cohort Comparison; Treatment Study

**Background:** History of prior rotator cuff repair (RCR) may adversely affect the outcomes of reverse total shoulder arthroplasty (RTSA), but there is no information regarding the influence of prior superior capsular reconstruction (SCR) surgery on the outcomes of RTSA. The purpose of this study is to evaluate the outcomes of RTSA following failed arthroscopic SCR.

**Methods:** All patients who underwent RTSA for failed SCR (SCR cohort) at our institution were identified from our institutional database. A comparative cohort of patients who had RTSA with a history of failed RCR (Control cohort) was also reviewed. Demographic information, 90-day complication rate, 90-day emergency department visits, length of stay, and outcome scores (patient-reported outcomes measurement information system [PROMIS] physical function upper extremity, Visual Analog Scale score, and range of motion) were compared.

**Results:** From 2015 to 2020, 87 arthroscopic SCRs were performed at our institution and of these, 13 patients underwent RTSA at a mean time of 14.6 months (5.8–32.4) after SCR and were followed up for an average of 17.9 months (1.6–44.6). The average number of shoulder surgeries prior to RTSA was 2.8 (1–7), with the last surgery being SCR. During the same period, we identified 15 patients who underwent an RTSA after a failed RCR (control cohort). The RTSA in the control cohort was performed on average at 12.8 months (1.5–39.5) following the last RCR, and patients were followed up for an average of 27.7 months (2.8–53.9). The average number of shoulder surgeries before the RTSA in the control cohort was 1.4 (1–3). Although the SCR cohort had significant improvements in pain scores and forward flexion (FF), there was only a modest functional improvement with PROMIS scores and no meaningful improvement with external rotation. Complications (23%) in the SCR cohort included 1 periprosthetic joint infection requiring 2-stage revision, 1 acromion stress fracture, and 1 ulnar neuritis. Overall, compared to the SCR cohort, patients in the control cohort had better function (PROMIS physical function upper extremity), lower Visual Analog Scale score, and greater range of motion (FF and external rotation) preoperatively and at last follow-up, but there were no differences in the length of stay and 90-day emergency department visits, infection, and complication rate between the 2 cohorts.

**Conclusion:** RTSA after failed SCR improves pain and FF but is associated with modest functional improvements and high complication rates. However, these findings will require confirmation in a larger cohort with longer follow-up.

© 2022 The Author(s). Published by Elsevier Inc. on behalf of American Shoulder and Elbow Surgeons. This is an open access article under the CC BY-NC-ND license (<http://creativecommons.org/licenses/by-nc-nd/4.0/>).

Superior capsular reconstruction (SCR) is a graft reconstruction of the superior capsule of the glenohumeral joint and provides a static restraint to proximal migration of humeral head in a superior

rotator cuff deficient shoulder. The static restraint function of SCR centers the humeral head on the glenoid during active elevation and allows the remaining, intact rotator cuff and deltoid to provide overhead elevation.<sup>10</sup> Although the indications for SCR are continuously evolving, it is an attractive treatment option in younger patients without advanced glenohumeral arthritis (Hamada classification 1 and 2) and a painful shoulder due to an irreparable superior rotator cuff tear (RCT).<sup>1–5,10,17</sup> Although this procedure was initially described with an autograft, allograft is more popular in

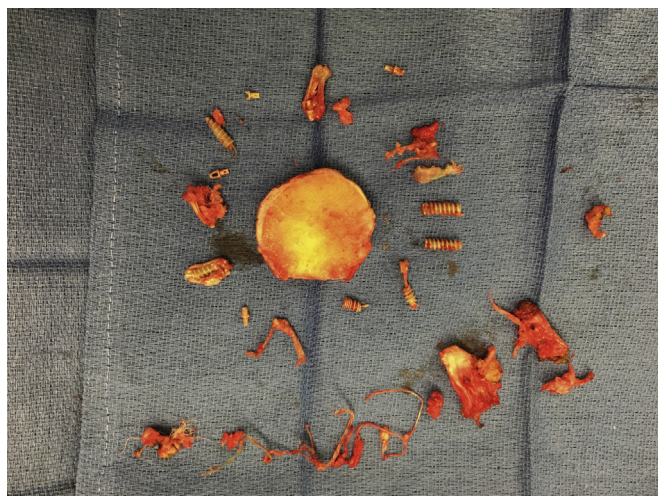
This study was approved by the New York University School of Medicine Institutional Review Board (study 17 Number i19-01959).

\*Corresponding author: Mandeep S. Virk, MD, 246 East 20th Street, New York, NY 10003, USA.

E-mail address: [mandeep.virk@nyulangone.org](mailto:mandeep.virk@nyulangone.org) (M.S. Virk).

<https://doi.org/10.1016/j.jseint.2021.11.019>

2666-6383/© 2022 The Author(s). Published by Elsevier Inc. on behalf of American Shoulder and Elbow Surgeons. This is an open access article under the CC BY-NC-ND license (<http://creativecommons.org/licenses/by-nc-nd/4.0/>).



**Figure 1** Humeral-sided anchors and hardware from previous arthroscopic SCR.

the United States.<sup>10</sup> However, even with the recent success of this operation, up to 55% of SCR surgeries have been reported to fail, retear, or have nonhealing of the graft.<sup>1–3,5,17</sup> Additionally, 5% of patients undergoing SCR require revision surgery, and 20% of patients undergoing this operation report being dissatisfied.<sup>1,2,5</sup>

The initial indications for reverse total shoulder arthroplasty (RTSA) were primarily limited to the treatment of cuff tear arthropathy and good to excellent outcomes have been reported for this indication.<sup>6,14,16</sup> The indications for RTSA have since then gradually expanded to include conditions other than cuff tear arthropathy such as treatment of failed rotator cuff repair (RCR) or irreparable RCTs without arthritis, revision arthroplasty, and non-reconstructable proximal humerus fractures.<sup>3,9,11,14,16</sup> With increased utilization of RTSA, risk factors have been identified that can adversely affect the outcomes of RTSA and include a history of prior shoulder surgery, young age (<50), axillary nerve dysfunction, greater preoperative function, higher expectations and demands, and more recently reported, history of prior arthroscopic RCRs.<sup>6,9,13,15</sup>

Although RTSA is a salvage operation for failed SCR,<sup>17</sup> to our knowledge, the outcomes of RTSA following failed SCR have not been reported previously. Therefore, the aim of this study is to determine the outcomes of patients undergoing RTSA with a history of an ipsilateral SCR. The null hypothesis of this study was that outcomes of RTSA after a failed ipsilateral arthroscopic SCR would be similar to the outcomes of RTSA with a history of failed ipsilateral arthroscopic RCR.

**Methods**

*Study design*

This is a retrospective case-control study (Level of evidence: III).

*Patient identification and study design*

An institutional review board approval was obtained for this retrospective case-control study. The SCR cohort was identified from our institutional database by screening for patients who had a history of SCR but subsequently underwent an RTSA due to persistent pain and/or compromised shoulder function. The control cohort was identified in a similar manner from our institutional database by screening for patients who underwent an RTSA for a failed RCT but did not have advanced radiographic changes

(Hamada grade <3) prior to RTSA. The Hamada grade was determined in 2 ways. First, when available, data were extracted from patients’ medical records according to the preoperative notes of the operating surgeons. Additionally, all pre-RTSA radiographs were reviewed retrospectively by the first author during screening and analysis of cases.

The control cohort was selected because patients with prior shoulder surgery, including arthroscopic RCR, have been shown to negatively affect the outcomes after RTSA. Since all the patients in the SCR cohort had a history of prior RCR, this control cohort of RTSA after failed RCR would more closely isolate the SCR procedure as an independent variable<sup>6,13,15</sup> to assess its effect on outcomes after RTSA.

*Data collection*

Baseline demographics, radiographic characteristics, clinical outcomes, complications, and 90-day emergency department (ED) visits and readmissions were collected and reported. Baseline demographics that included age at the time of RTSA, gender, arm dominance, number of prior RCR surgeries, time to RTSA following the last shoulder surgery, and length of stay were collected. Pre-operative radiographic Hamada grading,<sup>8</sup> clinical outcome measures including patient-reported outcomes measurement information system (PROMIS) physical function upper extremity score, Visual Analog Scale score (VAS) for pain, and range of motion (ROM) (forward flexion [FF] and external rotation [ER]) were collected. Ninety-day ED visits and readmissions, and 90-day complications including superficial and deep infections, wound drainage, and hematomas, as well as other complications through the entirety of the follow-up were reported.

*Surgical technique*

All patients were indicated for an RTSA following failure of nonsurgical treatment for continued pain and/or shoulder dysfunction (pseudoparalysis) following their previous shoulder surgery (arthroscopic SCR or RCR). Once all the nonoperative measures failed, patients underwent RTSA via a standard deltopectoral approach in the beach chair position. A subscapularis tenotomy was performed if subscapularis was present and intact and was repaired at the conclusion of the case. The humeral-sided anchors from the previous arthroscopic procedures were removed prior to reaming and broaching of the medullary canal (Fig. 1). Some of the anchors, especially the lateral row anchors, can mechanically interfere with broaching and result in varus placement of the humeral component. The SCR allograft was removed during glenoid preparation. The glenoid-sided anchors were removed if they were in the way during reaming or implantation of the glenoid component. Depending on surgeon’s preference, RTSA with

**Table 1**  
Demographic and radiographic comparison between SCR and control cohort.

	SCR cohort	Control cohort	P value
N	13	15	
Age (yr)	62.5 (43–78)	67.7 (51–84)	.22
Gender (F/M; %F)	6/7; 46.2%	6/9; 40%	.71
Arm dominance	6 (46.2%)	7 (46.7%)	1.00
Preoperative Hamada class	1.9	1.7	.60
Number of prior surgeries	2.7 (1–7)	1.4 (1–3)	.03
Days to RTSA	436.7 (174–971)	383.9 (44–1185)	.71
Average follow-up (mo)	17.9 (1.6–44.6)	27.7 (2.8–53.9)	N/A

SCR cohort, reverse total shoulder replacement after failed superior capsular reconstruction; Control cohort, reverse total shoulder replacement after failed rotator cuff repair; F, female; M, male; RTSA, reverse total shoulder arthroplasty; N/A, not applicable.

**Table II**  
Clinical outcomes comparison between SCR and control cohort.

		Preoperative	P value	Postoperative	P value	Δ (preoperative to postoperative change)	P value
PROMIS PFUE	SCR (N = 12)	24.5 (21.6–29.8)	.08	29.1 (24.2–41.4)	.04	+4.6	.12
	Control (N = 15)	30.3 (24.6–42.5)		34.9 (20.8–43.4)		+4.6	.13
VAS	SCR (N = 12)	7.8 (3–10)	.01	4.3 (0–7)	.30	–3.5	.02
	Control (N = 15)	4.1 (0–10)		2.9 (0–10)		–1.2	.15
Forward flexion (°)	SCR (N = 12)	76 (40–130)	.3	119 (90–165)	.25	+43	.02
	Control (N = 15)	94 (30–170)		138 (70–170)		+44	.01
External rotation (°)	SCR (N = 12)	22 (0–60)	.16	29 (0–50)	.07	+7	.23
	Control (N = 15)	32 (0–50)		45 (20–50)		+13	.09

SCR cohort, reverse total shoulder replacement after failed superior capsular reconstruction; PROMIS PFUE, patient-reported outcomes measurement information system physical function upper extremity; Control cohort, reverse total shoulder replacement after failed rotator cuff repair; VAS, visual analog scale for pain.

onlay or inlay humeral stems as well as intermediate and lateralized glenosphere designs were utilized (Exactech Inc., Gainesville, FL, USA; DJO Surgical, Dallas, TX, USA). Drains were used in all cases and removed on postoperative day #1. A standardized institutional postoperative rehabilitation protocol was used for these patients, which included immobilization in a sling postoperatively for up to 4 weeks. Passive shoulder ROM (FF as tolerated and ER to 20°) and isometric deltoid strengthening exercises were started on the first postoperative day. Active-assisted and active ROM and isometric ER exercises were started at 4–6 weeks. RTSA precautions were used for all patients during the first 6 weeks after surgery.

*Statistical analysis*

Standard descriptive summaries (means, standard deviations, percentages) were utilized for baseline demographics and radiographic characteristics. For clinical comparison of the 2 cohorts, chi-squared test and Student’s t-test were utilized for categorical and numerical data. A P value of <.05 was considered statistically significant. All statistical analyses were done using GraphPad Prism 5 (GraphPad, La Jolla, CA, USA) and stored using Excel software (Microsoft Corporation, Richmond, WA, USA).

**Results**

*Demographics*

From 2015 to 2020, 87 arthroscopic SCR reconstructions were performed at our institution. The year 2015 was the first year identified that a patient underwent an RTSA following a failed arthroscopic SCR procedure. One patient (1.1%) had 2 revision arthroscopic SCR procedures prior to the RTSA operation. Thirteen patients (~15%, SCR cohort) subsequently underwent RTSA on average 14.6 months (5.8–32.4) following the SCR procedure and were followed up for an average of 17.9 months (1.6–44.6). The average number of shoulder surgeries prior to RTSA was 2.8 (1–7), with the last surgery being SCR. During the same period, we screened all the RTSAs performed at our institution and identified 31 patients who underwent an RTSA for failed RCR. Of these 31 cases, only 15 patients had a history of failed RCR and Hamada grading <3 and were included in the control cohort. The control cohort patients underwent RTSA on average 12.8 months (1.5–39.5 months) following the last shoulder surgery, and patients were followed up for an average of 27.7 months (2.8–53.9). The average number of shoulder surgeries before the RTSA in the control cohort was 1.4 (1–3). Table I shows the demographic and radiographic information comparing both cohorts. There were no differences between baseline demographics or radiographic characteristics (P > .05), except for the number of prior arthroscopic RCR surgeries, which were significantly higher in the SCR Cohort (P = .03)

*Clinical outcomes*

Table II compares the clinical outcomes between the SCR and control cohorts for PROMIS physical function upper extremity score, pain (VAS), and shoulder ROM (FF and ER). Compared to the control cohort, the SCR cohort had lower preoperative PROMIS scores (30.3 vs. 24.5, P = .08) and higher preoperative VAS scores (4.1 vs. 7.8, P = .01). Postoperatively, patients in the SCR cohort demonstrated considerable improvements in the pain scores (VAS improved from 7.8 preoperatively to 4.3 postoperatively [Δ = –3.5], P = .02) and FF (from 76° preoperatively to 119° postoperatively [Δ = +43°], P = .02), but there were modest improvements in the PROMIS score (from 24.5 preoperatively to 29.1 postoperatively, P = .12).

Overall, compared to the SCR cohort, patients in the control cohort had better function (PROMIS), lower VAS score, and greater ROM (FF and ER) both preoperatively and at last postoperative follow-up. However, preoperative to postoperative changes in PROMIS scores (Δ = +4.6 for both cohorts) and FF (Δ = +43° [SCR cohort] vs. +44° [control cohort]) were similar in both groups. (Table II)

*Complications*

There were no 90-day complications (superficial and deep infections, hematomas, and wound drainage) for either cohort. There were 3 (~23%) complications in the SCR cohort and 4 complications (~27%) in the control cohort. The complications in the SCR cohort included periprosthetic joint infection (PJI), acromial stress fracture, and ulnar neuritis. The PJI was treated with 2-stage revision, the acromial stress fracture was treated nonsurgically, and the ulnar neuritis symptoms resolved without surgical intervention. Overall complications for the control cohort included 1 patient with acromial stress fracture (treated nonsurgically), 1 patient with PJI (treated with a 2-stage revision), 1 patient with periprosthetic humerus shaft fracture (treated nonsurgically), and 1 postoperative stiffness treated with an arthroscopic capsular release (Table III). There were no differences in the length of stay, ED admission, and revision surgery in the SCR and control cohorts (P > .05; Table III).

**Discussion**

SCR is a treatment option in patients with a symptomatic irreparable posterior-superior RCT with minimal or no glenohumeral arthritis. Although outcomes after SCR have been recently reported, there are no reports on the outcomes of RTSA after a failed SCR. In this study, we report short-term outcomes and early complications of RTSA after failed SCR. We found that RTSA after failed SCR improves pain and FF but is associated with modest functional improvements and high complication rates.



**Table III**  
Postoperative complications in SCR and control cohort.

	SCR cohort (N = 13)	Control cohort (N = 15)	P value
90-d complications	0 (0%)	0 (0%)	N/A
90-d ED visits	2 (15.4%)	4 (26.7%)	.48
90-d readmissions	1 (7.7%)	2 (13.3%)	.64
Overall complications	3 (23%)	4 (26.7%)	.48
Length of stay (d)	1.6 (1-5)	1.5 (1-3)	.68
Revision surgery	1 (7.7%)	2 (13.3%)	.92
	Infection	Infection	

SCR cohort, reverse total shoulder replacement after failed superior capsular reconstruction; Control cohort, reverse total shoulder replacement after failed rotator cuff repair; ED, emergency department; PE, pulmonary embolism; GI, gastrointestinal; N/A, not applicable.

Considering that SCR is a final attempt at shoulder preservation following multiple failed RCRs and commonly involves the use of an allograft and multiple anchors, it was our hypothesis that the complication rates, especially of infection, will be high when RTSA is performed as a salvage operation for failed SCR. In this study, RTSA following a failed SCR improved pain and FF of the shoulder, but there was only modest overall functional improvement and a high complications rate (23%). In order to evaluate SCR as an independent risk factor for poor outcome after RTSA, in this study, we compared the patients who underwent RTSA after failed SCR to patients who had RTSA after failed arthroscopic RCR(s). This control group was essential because all patients who underwent SCR had previous arthroscopic repair(s), and comparing the outcomes of the SCR cohort to this control group will allow us to isolate the role of SCR as an independent risk factor. However, the control group was not age/gender matched and the number of patients in both groups was not large enough to refute or accept our hypothesis. However, patients in the SCR cohort had poor shoulder function as determined by higher VAS score, and lower ROM (FF and ER) preoperatively and at last follow-up compared to the control group. As the number of RTSAs for failed SCR increases in the future, studies with large patient numbers will be feasible to test this hypothesis.

To our knowledge, outcomes of RTSA following SCR have not been reported before. However, previous literature has reported that up to 55% of SCR surgeries fail, re-tear, or have nonhealing of the graft, and 5% undergo a revision SCR procedure, and 20% of patients undergoing this operation are unsatisfied.<sup>2,5</sup> In this study at our institution, 14% of the patients undergoing SCR subsequently underwent RTSA on average 14.6 months following the SCR procedure.<sup>5</sup> More recent reports describing SCR clinical outcomes and risks factors for failure, show 7.1% (1/14) and 5.6% (3/54) conversion from a failed arthroscopic SCR procedure to RTSA but these rates are lower compared to those reported in this study.<sup>7,12</sup> Gilat et al<sup>7</sup> also reported that RTSA was performed 6–12 months following the failed SCR procedure, which is much shorter than what is reported in our study.

Prior shoulder surgery including RCR, is a risk factor that can negatively affect outcomes after RTSA. The patients in the SCR cohort had an average of 3 arthroscopic procedures (excluding the SCR), and their shoulders were painful and stiff prior to the RTSA, which was reflected in their preoperative scores (VAS, PROMIS, and ROM). Intraoperatively, extensive subdeltoid and subacromial scarring were noted for these patients requiring more surgical dissection; therefore, it was not a surprise that these patients had residual pain and poor function despite significant improvements in the pain scores and FF of the shoulder after RTSA. These findings are of clinical importance and should be discussed during patients' preoperative counseling.

There are certain weaknesses in this study, including the inherent bias due to the retrospective design. This would include the recall bias for patient-reported outcomes and data collection. Second, the follow-up in both cohorts is short-term and does not capture the long-term performance of RTSA in these clinical scenarios. Third, the control group was not age and gender matched. Finally, the number of patients in the SCR group is relatively small (13). However, we believe that as more RTSAs will be done for failed SCR studies with higher patient numbers and longer follow-up will be feasible.

## Conclusion

RTSA as a salvage operation following failed SCR improves pain and forward elevation, but improvements in overall function are modest with a high complication rate. Whether failed SCR is an independent risk factor for having poor long-term outcomes after RTSA requires future investigation.

## Disclaimers:

Funding: No funding was disclosed by the authors.  
Conflicts of interest: The authors, their immediate families, and any research foundation with which they are affiliated have not received any financial payments or other benefits from any commercial entity related to the subject of this article.

## References

- Burkhart SS, Hartzler RU. Superior capsular reconstruction reverses profound pseudoparalysis in patients with irreparable rotator cuff tears and minimal or no glenohumeral arthritis. *Arthroscopy* 2019;35:22-8. <https://doi.org/10.1016/j.arthro.2018.07.023>.
- Burkhart SS, Prancun JJ, Hartzler RU. Superior capsular reconstruction for the operatively irreparable rotator cuff tear: clinical outcomes are maintained 2 Years after surgery. *Arthroscopy* 2020;36:373-80. <https://doi.org/10.1016/j.arthro.2019.08.035>.
- Carver TJ, Kraeutler MJ, Smith JR, Bravman JT, McCarty EC. Nonarthroplasty surgical treatment options for massive, irreparable rotator cuff tears. *Orthop J Sports Med* 2018;6:2325967118805385. <https://doi.org/10.1177/2325967118805385>.
- Duchman KR, Mickelson DT, Little BA, Hash TW II, Lemmex DB, Toth AP, et al. Graft use in the treatment of large and massive rotator cuff tears: an overview of techniques and modes of failure with MRI correlation. *Skeletal Radiol* 2020;60:172-6. <https://doi.org/10.1007/s00256-018-3015-4>.
- Emerson CP, Balazs GC, Lee SC, Dines JS, Jose J, Greditzer HG. Magnetic resonance imaging of the failed superior capsular reconstruction. *Clin Imaging* 2020;60:172-6. <https://doi.org/10.1016/j.clinimag.2019.10.006>.
- Erickson BJ, Ling D, Wong A, Eno JJ, Dines JS, Dines DM, et al. Does having a rotator cuff repair prior to reverse total shoulder arthroplasty influence the outcome? *Bone Joint J* 2019;101-b:63-7. <https://doi.org/10.1302/0301-620x.101b1.Bjj-2018-0874.R1>.
- Gilat R, Haunschild ED, Williams BT, Fu MC, Garrigues GE, Romeo AA, et al. Patient factors associated with clinical failure following arthroscopic superior capsular reconstruction. *Arthroscopy* 2021;37:460-7. <https://doi.org/10.1016/j.arthro.2020.09.038>.

8. Hamada K, Yamanaka K, Uchiyama Y, Mikasa T, Mikasa M. A radiographic classification of massive rotator cuff tear arthritis. *Clin Orthop Relat Res* 2011;469:2452–60. <https://doi.org/10.1007/s11999-011-1896-9>.
9. Hartzler RU, Steen BM, Hussey MM, Cusick MC, Cottrell BJ, Clark RE, et al. Reverse shoulder arthroplasty for massive rotator cuff tear: risk factors for poor functional improvement. *J Shoulder Elbow Surg* 2015;24:1698–706. <https://doi.org/10.1016/j.jse.2015.04.015>.
10. Mihata T, Lee TQ, Watanabe C, Fukunishi K, Ohue M, Tsujimura T, et al. Clinical results of arthroscopic superior capsule reconstruction for irreparable rotator cuff tears. *Arthroscopy* 2013;29:459–70. <https://doi.org/10.1016/j.arthro.2012.10.022>.
11. Mulieri P, Dunning P, Klein S, Pupello D, Frankle M. Reverse shoulder arthroplasty for the treatment of irreparable rotator cuff tear without glenohumeral arthritis. *J Bone Joint Surg Am* 2010;92:2544–56. <https://doi.org/10.2106/jbjs.l.00912>.
12. Pashuck TD, Hirahara AM, Cook JL, Cook CR, Andersen WJ, Smith MJ. Superior capsular reconstruction using dermal allograft is a safe and effective treatment for massive irreparable rotator cuff tears: 2-year clinical outcomes. *Arthroscopy* 2021;37:489–496.e481. <https://doi.org/10.1016/j.arthro.2020.10.014>.
13. Sadoghi P, Vavken P, Leithner A, Hochreiter J, Weber G, Pietschmann MF, et al. Impact of previous rotator cuff repair on the outcome of reverse shoulder arthroplasty. *J Shoulder Elbow Surg* 2011;20:1138–46. <https://doi.org/10.1016/j.jse.2011.01.013>.
14. Sellers TR, Abdelfattah A, Frankle MA. Massive rotator cuff tear: when to consider reverse shoulder arthroplasty. *Curr Rev Musculoskelet Med* 2018;11:131–40. <https://doi.org/10.1007/s12178-018-9467-2>.
15. Shields EJW, Koueiter DM, Maerz T, Schwark A, Wiater JM. Previous rotator cuff repair is associated with inferior clinical outcomes after reverse total shoulder arthroplasty. *Orthop J Sports Med* 2017;5:2325967117730311. <https://doi.org/10.1177/2325967117730311>.
16. Virk MS, Nicholson GP, Romeo AA. Irreparable rotator cuff tears without arthritis treated with reverse total shoulder arthroplasty. *Open Orthop J* 2016;10:296–308. <https://doi.org/10.2174/1874325001610010296>.
17. Zerr J, McDermott JD, Beckmann NM, Fullick RK, Chhabra A. Case study: failure of superior capsular reconstruction using dermal allograft. *Skeletal Radiol* 2017;46:1585–9. <https://doi.org/10.1007/s00256-017-2716-4>.