

Final analysis of colorectal cancer patients treated with irinotecan and 5-fluorouracil plus folinic acid neoadjuvant chemotherapy for unresectable liver metastases

C Barone^{*1}, G Nuzzo², A Cassano¹, M Basso¹, G Schinzari¹, F Giuliani², E D'Argento¹, N Trigila¹, A Astone¹ and C Pozzo¹

¹Unit of Medical Oncology, Department of Internal Medicine, Catholic University of Sacred Heart, Rome, Italy; ²Unit of Hepatobiliary Surgery, Department of General Surgery, Catholic University of Sacred Heart, Rome, Italy

We have previously reported that neoadjuvant therapy with modified FOLFIRI enabled nearly a third of patients with metastatic colorectal cancer (mCRC) to undergo surgical resection of liver metastases. Here, we present data from the long-term follow-up of these patients. Forty patients received modified FOLFIRI: irinotecan 180 mg m⁻², day 1; folinic acid, 200 mg m⁻²; and 5-fluorouracil: as a 400 mg m⁻² bolus, days 1 and 2, and a 48-h continuous infusion 1200 mg m⁻², from day 1. Treatment was repeated every 2 weeks, with response assessed every six cycles. Resected patients received six further cycles of chemotherapy postoperatively. Nineteen (47.5%) of 40 patients achieved an objective response; 13 (33%) underwent resection. After a median follow-up of 56 months, median survival for all patients was 31.5 months: for non-resected patients, median survival was 24 months and was not reached for resected patients. Median time to progression was 14.3 and 5.2 months for all and non-resected patients, respectively. Median disease-free (DF) survival in resected patients was 52.5 months. At 2 years, all patients were alive (8 DF), and at last follow-up, eight were alive (6 DF). Surgical resection of liver metastases after neoadjuvant treatment with modified FOLFIRI in CRC patients achieved favourable survival times.

British Journal of Cancer (2007) 97, 1035–1039. doi:10.1038/sj.bjc.6603988 www.bjcancer.com

Published online 25 September 2007

© 2007 Cancer Research UK

Keywords: colorectal cancer; irinotecan; FOLFIRI; liver metastases; neoadjuvant

Worldwide, colorectal cancer (CRC) is the fourth most common malignancy in men and the third most common in women. In 2002, the disease accounted for more than one million new cancer cases and caused 528 978 deaths (Parkin *et al*, 2005). Approximately 25% of CRC patients present with metastatic disease, with the liver being the most common site of metastasis. Over time, 40–50% of newly diagnosed CRC patients will develop metastatic disease (Saltz *et al*, 2000). The 5-year survival rate for patients with metastatic CRC (mCRC) is 5–30% (Van Cutsem *et al*, 2005).

Patients who are able to undergo resection of isolated liver metastases have the chance of cure or improved survival. If cases are carefully selected for surgery, the 5-year survival rate may be as high as 60% (Fernandez *et al*, 2004; Pawlik *et al*, 2005). However, only 10–20% of patients with mCRC are suitable for liver resection at presentation (Adam, 2003). Over the last 10 years, the introduction of two new active cytotoxic chemotherapy drugs and several targeted biological agents has improved the outlook for

patients with mCRC. Median survival times in excess of 20 months can now be expected with the first- and second-line use of irinotecan and/or oxaliplatin in combination with 5-fluorouracil (5-FU)/folinic acid (FA). This compares favourably with the 12–14 months previously achieved with 5-FU/FA alone (Douillard *et al*, 2000; Thirion *et al*, 2004).

These more active chemotherapy regimens are also associated with higher response rates of 39–62% (Bismuth *et al*, 1996; Douillard *et al*, 2000; Saltz *et al*, 2000; Tournigand *et al*, 2004; Alberts *et al*, 2005; Kohne *et al*, 2005). In addition, as many as 68% of responding patients with initially unresectable liver disease have been reported to be subsequently eligible for secondary resection of their metastases (Alberts *et al*, 2005). Indeed, the importance of maximising response rates in this setting was highlighted by the retrospective analysis of Folprecht *et al* (2005), which demonstrated a strong correlation between response and resection rates, especially in selected patients with no disease outside the liver.

The present study previously reported that 32.7% of patients with CRC were able to undergo potentially curative surgical resection of initially unresectable liver metastases following neoadjuvant chemotherapy with an irinotecan/5-FU/FA combination (modified FOLFIRI) (Pozzo *et al*, 2004). This paper reports on the long-term follow-up of these patients, providing data on overall survival, disease-free (DF) survival and time to progression (TTP).

*Correspondence: Dr C Barone, Unit of Medical Oncology, Catholic University of Sacred Heart, Largo Francesco Vito, 1, Rome 00168, Italy; E-mail: carlobarone@rm.unicatt.it

Received 16 May 2007; revised 27 July 2007; accepted 14 August 2007; published online 25 September 2007

MATERIALS AND METHODS

Patients

Patients aged 18–75 years with unresectable colorectal liver metastases were eligible for entry into the study. Other eligibility criteria were no evidence of extrahepatic disease or involvement of more than 70% of the liver; Eastern Cooperative Oncology Group (ECOG) performance status of 2 or less; no previous chemotherapy for advanced disease; any adjuvant chemotherapy completed at least 6 months prior to study entry; no history of other malignancies; adequate bone marrow ($WBC > 3 \times 10^9 l^{-1}$, platelets $> 100 \times 10^9 l^{-1}$, haemoglobin $> 10 g dl^{-1}$), liver (total bilirubin $< 2 mg dl^{-1}$, aspartate aminotransferase or alanine aminotransferase $< 3 \times$ upper limit of normal) and renal function (blood urea nitrogen $\leq 30 mg dl^{-1}$, creatinine clearance $> 60 ml min^{-1}$, serum creatinine $\leq 1.5 mg dl^{-1}$); and a life expectancy of more than 3 months. Written informed consent was provided by all patients.

Chemotherapy

Modified FOLFIRI was administered every 2 weeks and consisted of the following: irinotecan $180 mg m^{-2}$ given i.v. on day 1; 5-FU $1200 mg m^{-2}$ continuous i.v. infusion over 48 h from day 1; FA $200 mg m^{-2}$ i.v. on days 1 and 2 and 5-FU $400 mg m^{-2}$ i.v. bolus on days 1 and 2. Response was assessed every 12 weeks (six cycles). In cases of neutropaenia ($\leq 1.5 \times 10^9 l^{-1}$), thrombocytopenia ($\leq 100 \times 10^9 l^{-1}$) or significant non-haematologic toxicity, treatment was delayed for 1 week. In the event of grade 3/4 neutropaenia or diarrhoea, the doses of irinotecan and 5-FU were reduced by 25%. The dose of 5-FU only was similarly reduced in the event of grade 3/4 stomatitis. Treatment was interrupted for grade 4 haematologic toxicity or grade 4 gastrointestinal toxicity (lasting > 1 week after a previous dose reduction or a delay in dose administration of > 2 weeks).

Chemotherapy was continued until an objective response was achieved (indicating suitability for surgery), or until disease progression or unacceptable toxicity. Those patients who underwent resection of their liver metastases received six further cycles of the same chemotherapy regimen postoperatively. Patients with progressive disease were treated at the discretion of the investigator.

Assessments

Initial unresectability of liver metastases was assessed as described previously, using the criteria set out by the institution at which the study was carried out (Pozzo *et al*, 2004).

RESULTS

Patients

Forty patients were enrolled into the study over 2.5 years up to January 2003. The patients' baseline characteristics are outlined in Table 1. The median age of the patients was 58.7 years (range: 32–75 years) and the majority were male (60%). All but one patient had an ECOG performance status of 0. The majority of patients (67.5%) had synchronous metastases, with the remainder being metachronous. At study entry, 21 patients (52.5%) had less than three metastases and 11 (27.5%) had more than six. Twelve (30%) patients had at least one lesion ≥ 5 cm in diameter and seven (17.5%) patients had metastases that were unfavourably located in the hilum.

Of those patients with liver metastases that were considered to be unresectable, 35% had large numbers of metastases, 25% had large metastases, 5% had inadequate liver reserve and 35% had surgically inaccessible metastases (Table 1).

Table 1 Baseline characteristics of patients

Characteristic	n = 40 patients
Gender (%)	
Male	60
Female	40
Median age, years (range)	58.7 (32–75)
ECOG performance status (%)	
0	97.5
1–2	2.5
Metastases (%)	
Synchronous	67.5
Metachronous	32.5
Number of metastases (%)	
<3	52.5
3–6	20
>6	27.5
Largest metastasis (%)	
≥ 5 cm diameter	30
<5 cm diameter	70
Site of metastasis (%)	
Hilum	17.5
Other sites	82.5
Main cause of unresectability (%)	
Number of metastases	35
Location of metastases	35
Size of metastasis	25
Insufficient liver reserve	5

ECOG = Eastern Cooperative Oncology Group.

Response to chemotherapy

As of December 10 2006, median follow-up was 56 months. All 40 patients had been evaluated for response yielding an objective response rate of 47.5%, including two complete responses. Of the 19 (47.5%) patients who experienced an overall response, 16 were considered to be eligible for surgery (after a median of eight cycles of chemotherapy per patient (range: 6–12)) and 13 underwent resection of their liver metastases. The median overall survival of these patients has not yet been reached. The median survival for all 40 patients was 31.5 months (Figure 1A) and in non-resected patients, 24 months (Table 2). Nine out of 40 patients (22.5% (95% CI: 10.5–34.5%)) were still alive, including one not resected patient. The median TTP for all patients was 14.3 months (range: 2–49), and in non-resected patients, 5.2 months.

Adverse events

The treatment was well tolerated and the adverse events that were observed and described previously were those typical of the cytotoxic agents used (Pozzo *et al*, 2004). There were no delayed onset adverse events. There were no significant differences in the incidence and severity of adverse events experienced by patients during the additional postresection chemotherapy phase compared with those reported for the initial phase of treatment.

Surgery

Among the 13 patients who underwent surgery, there were 13 R0 liver resections. Most of these patients (10 out of 13) underwent multiple segmental resections. As reported previously, the resection rate following chemotherapy was highest in those patients with large (> 5 cm) metastases (6 out of 10) (Pozzo *et al*, 2004).

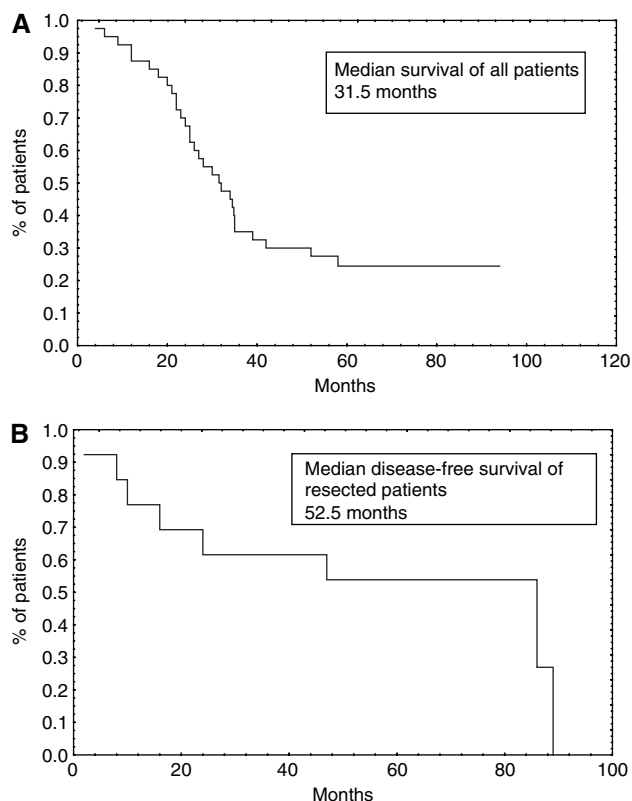


Figure 1 (A) Median overall survival. (B) Median disease-free survival.

Table 2 Survival and time to progression in resected and non-resected patients

	All patients n = 40	Non-resected patients n = 27	Resected patients n = 13
Median survival, months (range)	31.5 (4–92)	24	NR
Median TTP, months (range)	14.3 (2–49)	5.2 (2–13)	52.5
Median DF survival, months (range)	—	—	52.5 (2–89)
<i>Survival (%)</i>			
6 months	97.5	96.2	100 (85% DF)
1-year follow-up	87.5	81.4	100 (77% DF)
2-year follow-up	63.5	55.5	100 (62% DF)
Last follow-up (5 years)	22.5	3.7	62 (46% DF)
	(95% CI: 10.5, 34.5)		(OS 95% CI: 19.3, 72.9) (DF 95% CI: 19.3, 72.9)

CI = confidence interval; DF, disease-free; NR = not reached; OS = overall survival; TTP = time to progression.

Also, there was no postoperative mortality in the 2 months following surgery. One patient experienced anaemia as a consequence of postoperative bleeding (Pozzo *et al*, 2004).

Disease-free survival

The median DF survival of the resected patients was 52.5 months (Figure 1B). At the time of reporting, a median of 56 months from

resection, 6 (46% (95% CI: 19.3–72.9%)) of the 13 radically resected patients were still disease free and 8 (62%) of the 13 were still alive (Table 2).

DISCUSSION

After a median follow-up period of nearly 60 months, the median survival for all patients was 31.5 months. This is one of the highest reported median survival times for a prospective study in similar groups of patients treated with standard combinations of cytotoxic agents. Moreover, currently, the median survival time for those patients who underwent secondary resections of their liver metastases has not yet been reached.

It has been recognised for some time that resection of liver metastases offers the best long-term hope for patients with mCRC. Chemotherapy regimens combining 5-FU/FA with irinotecan and/or oxaliplatin have demonstrated impressive efficacy in the downstaging of liver metastases to permit secondary resection (Van Cutsem *et al*, 2005) and their role in the neoadjuvant setting is now essentially undisputed. However, as yet, there is no consensus about which neoadjuvant regimen will be the most effective, either in general terms or for particular patients (as defined by disease or genotypic variation). Emerging data suggest that the addition of targeted biological agents to such regimens will further improve efficacy. Indeed, Folprecht *et al* (2006) reported a median survival time of 33 months, using cetuximab, an EGFR-targeted monoclonal antibody, in combination with irinotecan/5-FU/FA. In a randomised phase III trial, cetuximab was shown to increase response rate, progression-free survival and resection rate over FOLFIRI alone in patients with advanced CRC, with the PFS benefit being greatest for those patients with liver-only metastases (Van Cutsem *et al*, 2007).

One of the factors that have hindered comparisons between studies of neoadjuvant treatment of initially unresectable colorectal liver metastases is that there is no universally accepted definition of unresectability. Patient selection is a crucial factor, both for maximising the benefits achievable from primary resection (Fong *et al*, 1999) and for enabling the highest resection rates following neoadjuvant therapy (Adam *et al*, 2004a,b; Folprecht *et al*, 2005). In their retrospective analysis, Folprecht *et al* (2005) found that in studies which enrolled patients with metastases confined to the liver, 24–54% of patients were able to undergo resection of their metastases subsequent to chemotherapy, whereas only 1–26% of patients in non-selective trials (patients with hepatic or extrahepatic disease) became eligible for secondary surgery. However, this analysis found a strong correlation between the response rate to neoadjuvant therapy and the resection rate in both the selected ($r = 0.96$, $P = 0.002$) and unselected ($r = 0.74$, $P < 0.001$) patients.

Studies of resection following neoadjuvant therapy have also demonstrated long-term benefits. Giacchetti *et al* (1999) reported that 77 out of 151 (51%) patients had surgery with curative intent following neoadjuvant treatment with 5-FU/FA/oxaliplatin. Complete resection was achieved in 58 patients. The median survival of the operated patients was 48 months (range: 25–71), and the 5-year survival rate was 50% (range: 38–61). A more recent retrospective analysis by Zaniboni *et al* (2005) of oxaliplatin-based chemotherapy found an overall response rate of 78.5% in 105 patients. Ninety-nine patients had liver surgery, with 79% undergoing radical resection. The median survival time for these patients was 42 months.

In a study using a neoadjuvant combination of 5-FU/FA/irinotecan/oxaliplatin (FOLFOXIRI) (Masi *et al*, 2006), there was a response rate of 72% in unselected patients and a 26% (19 patients) hepatic resection rate. In five patients, extrahepatic disease was also resected. The median overall survival of surgical patients was 36.8 months, with a 4-year survival rate of 37%. The

overall survival of patients who responded to chemotherapy but did not undergo surgery was 22.2 months ($P=0.0114$). In a randomised phase III trial, FOLFOXIRI improved response rate, progression-free and overall survival compared with FOLFIRI, with secondary R0 resection rates of 15 vs 6% in non-selected patients and 36 vs 12% in patients with metastases confined to the liver (Falcone *et al*, 2007).

A multicentre phase II study investigated the use of irinotecan with 5-FU/FA (FOLFIRI) as neoadjuvant chemotherapy in selected patients with unresectable liver metastases (Ho *et al*, 2005). The overall response rate was 55% (22 out of 40 patients; 95% CI: 39.5–70.4%). Median overall survival was 20 months (95% CI: 17.7–26.6). Four patients underwent resection of metastases and remained alive at a median follow-up time of 33 months.

In the current study, neoadjuvant treatment with FOLFIRI achieved a response rate of 47.5%, with one-third of patients able to undergo secondary resection of liver metastases. Following resection, patients achieved a worthwhile median DF survival of 52.5 months. Median survival (all patients) was 31.5 months after a median follow-up of 56.0 months, and will be higher in radically resected patients, the median survival not yet having been reached. This compares favourably with Ho *et al* (2005) and other phase II studies in patients with initially unresectable metastases confined to the liver (Folprecht *et al*, 2005) and confirms the benefit of perioperative chemotherapy demonstrated in the EORTC EPOC trial in patients with resectable liver metastases (Nordlinger *et al*, 2007). Furthermore, the median overall survival is approaching twice that for unselected, unresected patients reported for combination therapy in the FOCUS (Seymour *et al*, 2007) and CAIRO trials (Punt *et al*, 2007).

As the use of neoadjuvant therapy has increased, so has the concern about possible long-term adverse effects of chemotherapy, particularly on the liver, where there is some evidence of vascular changes (Rubbia-Brandt *et al*, 2004; Adam *et al*, 2005) and steatohepatitis (Fernandez *et al*, 2005) following chemotherapy. However, although the vascular changes may increase the risk of intraoperative bleeding, it is not thought that they have any significant clinical impact (Adam *et al*, 2005).

Also, a retrospective study by Karoui *et al* (2006) showed that although preoperative chemotherapy was significantly associated with sinusoidal dilatation, atrophy of hepatocytes and/or hepatocytic necrosis (49 vs 25%, $P=0.005$) and increased morbidity, it did not appear to be linked to increased postoperative mortality in those patients who were resected. It is now generally accepted that provided patients are not overtreated with chemotherapy prior to surgery, there is little evidence of increased mortality and morbidity.

Ideally, the overall survival benefit conferred by neoadjuvant treatment needs to be validated in a prospective randomised trial in the palliative setting. Such a trial, in the light of present knowledge, would be ethically unacceptable because it should include a no surgery arm in which patients would not undergo surgery, even if their liver metastases become resectable after chemotherapy. However, prolonged (5 years or more) follow-up of patients, with identification of the particular regimen used to facilitate the resection of liver metastases, may be all that is necessary to fully evaluate the benefits of the different neoadjuvant treatment choices.

What is clear from the results of the current study is that irinotecan combination therapy (FOLFIRI) should be considered for the neoadjuvant treatment of patients with mCRC who have unresectable liver metastases as part of current strategic patient management practices. Future large-scale randomised studies in this setting should therefore include, for comparison, arms that receive irinotecan-based chemotherapy. Additionally, conventional chemotherapy could be combined with one or more molecularly targeted drugs as soon as the data on their role in advanced disease become available (Van Cutsem *et al*, 2007).

ACKNOWLEDGEMENTS

No financial support was received for this independent study. However, editorial assistance was provided by Cancer Communications and supported by Pfizer.

REFERENCES

- Adam R (2003) Chemotherapy and surgery: new perspectives on the treatment of unresectable liver metastases. *Ann Oncol* 14: ii13–ii16
- Adam R, Delvart V, Pascal G, Valeanu A, Castaing D, Azoulay D, Giacchetti S, Paule B, Kunstlinger F, Ghemard O, Levi F, Bismuth H (2004a) Rescue surgery for unresectable colorectal liver metastases downstaged by chemotherapy: a model to predict long-term survival. *Ann Surg* 240: 644–657; discussion 657–658
- Adam R, Pascal G, Castaing D, Azoulay D, Delvart V, Paule B, Levi F, Bismuth H (2004b) Tumor progression while on chemotherapy: a contraindication to liver resection for multiple colorectal metastases? *Ann Surg* 240: 1052–1061; discussion 1061–1064
- Adam R, Sebagh M, Plasse M, Karam V, Giacchetti S, Azoulay D, Bouchahda M, Jasmin C, Castaing D, Levi F (2005) Impact of preoperative systemic chemotherapy on liver histology and outcome of hepatic resection for colorectal cancer liver metastases (CRLM). *J Clin Oncol* 23: 16S
- Alberts SR, Horvath WL, Sternfeld WC, Goldberg RM, Mahoney MR, Dakhil SR, Levitt R, Rowland K, Nair S, Sargent DJ, Donohue JH (2005) Oxaliplatin, fluorouracil, and leucovorin for patients with unresectable liver-only metastases from colorectal cancer: a North Central Cancer Treatment Group phase II study. *J Clin Oncol* 23: 9243–9249
- Bismuth H, Adam R, Levi F, Farabos C, Waechter F, Castaing D, Majno P, Engarran L (1996) Resection of nonresectable liver metastases from colorectal cancer after neoadjuvant chemotherapy. *Ann Surg* 224: 509–520
- Douillard JY, Cunningham D, Roth AD, Navarro M, James RD, Karasek P, Jandik P, Iveson T, Carmichael J, Alakl M, Gruia G, Awad L, Rougier P (2000) Irinotecan combined with fluorouracil compared with fluorouracil alone as first-line treatment for metastatic colorectal cancer: a multicentre randomised trial. *Lancet* 355: 1041–1047
- Falcone A, Ricci S, Brunetti IM, Pfanner E, Allegrini G, Barbara C, Crino L, Benedetti G (2007) Phase III trial of infusional fluorouracil, leucovorin, oxaliplatin, and irinotecan (FOLFOXIRI) compared with infusional fluorouracil, leucovorin, and irinotecan (FOLFIRI) as first-line treatment for metastatic colorectal cancer: the Gruppo Oncologico Nord Ovest. *J Clin Oncol* 25: 1670–1676
- Fernandez FG, Drebin JA, Linehan DC, Dehdashti F, Siegel BA, Strasberg SM (2004) Five-year survival after resection of hepatic metastases from colorectal cancer in patients screened by positron emission tomography with F-18 fluorodeoxyglucose (FDG-PET). *Ann Surg* 240: 438–447; discussion 447–450
- Fernandez FG, Ritter J, Goodwin JW, Linehan DC, Hawkins WG, Strasberg SM (2005) Effect of steatohepatitis associated with irinotecan or oxaliplatin pretreatment on resectability of hepatic colorectal metastases. *J Am Coll Surg* 200: 845–853
- Folprecht G, Grothey A, Alberts S, Raab HR, Kohne CH (2005) Neoadjuvant treatment of unresectable colorectal liver metastases: correlation between tumour response and resection rates. *Ann Oncol* 16: 1311–1319
- Folprecht G, Lutz MP, Schoffski P, Seufferlein T, Nolting A, Pollert P, Kohne CH (2006) Cetuximab and irinotecan/5-fluorouracil/folinic acid is a safe combination for the first-line treatment of patients with epidermal growth factor receptor expressing metastatic colorectal carcinoma. *Ann Oncol* 17: 450–456

- Fong Y, Fortner J, Sun RL, Brennan MF, Blumgart LH (1999) Clinical score for predicting recurrence after hepatic resection for metastatic colorectal cancer: analysis of 1001 consecutive cases. *Ann Surg* **230**: 309–318
- Giacchetti S, Itzhaki M, Gruia G, Adam R, Zidani R, Kunstlinger F, Brienza S, Alafaci E, Bertheault-Cvitkovic F, Jasmin C, Reynes M, Bismuth H, Misset JL, Levi F (1999) Long-term survival of patients with unresectable colorectal cancer liver metastases following infusional chemotherapy with 5-fluorouracil, leucovorin, oxaliplatin and surgery. *Ann Oncol* **10**: 663–669
- Ho WM, Ma B, Mok T, Yeo W, Lai P, Lim R, Koh J, Wong YY, King A, Leow CK, Chan AT (2005) Liver resection after irinotecan, 5-fluorouracil, and folinic acid for patients with unresectable colorectal liver metastases: a multicenter phase II study by the cancer therapeutic research group. *Med Oncol* **22**: 303–312
- Karoui M, Penna C, Amin-Hashem M, Mitry E, Benoist S, Franc B, Rougier P, Nordlinger B (2006) Influence of preoperative chemotherapy on the risk of major hepatectomy for colorectal liver metastases. *Ann Surg* **243**: 1–7
- Kohne CH, van Cutsem E, Wils J, Bokemeyer C, El-Serafi M, Lutz MP, Lorenz M, Reichardt P, Ruckle-Lanz H, Frickhofen N, Fuchs R, Mergenthaler HG, Langenbuch T, Vanhoef U, Rougier P, Voigtmann R, Muller L, Genicot B, Anak O, Nordlinger B (2005) Phase III study of weekly high-dose infusional fluorouracil plus folinic acid with or without irinotecan in patients with metastatic colorectal cancer: European Organisation for Research and Treatment of Cancer Gastrointestinal Group Study 40986. *J Clin Oncol* **23**: 4856–4865
- Masi G, Cupini S, Marcucci L, Cerri E, Loupakis F, Allegrini G, Brunetti IM, Pfanner E, Viti M, Goletti O, Filipponi F, Falcone A (2006) Treatment with 5-fluorouracil/folinic acid, oxaliplatin, and irinotecan enables surgical resection of metastases in patients with initially unresectable metastatic colorectal cancer. *Ann Surg Oncol* **13**: 58–65
- Nordlinger B, Sorbye H, Collette L, Glimelius B, Poston G, Schlag PM, Rougier P, Bechstein W, Walpole E, Gruenberger T (2007) Final results of the EORTC intergroup randomized phase III study 40983 [EPOC] evaluating the benefit of peri-operative FOLFOX4 chemotherapy for patients with potentially resectable colorectal cancer liver metastases. *J Clin Oncol* **25**: 2S, abstract LBA 5
- Parkin DM, Bray F, Ferlay J, Pisani P (2005) Global cancer statistics, 2002. *CA Cancer J Clin* **55**: 74–108
- Pawlik TM, Scoggins CR, Zorzi D, Abdalla EK, Andres A, Eng C, Curley SA, Loyer EM, Muratore A, Mentha G, Capussotti L, Vauthey JN (2005) Effect of surgical margin status on survival and site of recurrence after hepatic resection for colorectal metastases. *Ann Surg* **241**: 715–722; discussion 722–724
- Pozzo C, Basso M, Cassano A, Quirino M, Schinzari G, Trigila N, Vellone F, Giuliante F, Nuzzo G, Barone C (2004) Neoadjuvant treatment of unresectable liver disease with irinotecan and 5-fluorouracil plus folinic acid in colorectal cancer patients. *Ann Oncol* **15**: 933–939
- Punt CJ, Koopman M, Douma J, Wals J, Honkoop AH, Erdkamp FL, de Jong RS, Rodenburg CJM, Mol L, Antonini NF (2007) Sequential compared to combination chemotherapy with capecitabine, irinotecan, and oxaliplatin in advanced colorectal cancer (ACC): a Dutch Colorectal Cancer Group (DCCG) phase III study. *J Clin Oncol* **25**: 166S, abstract 4012
- Rubbia-Brandt L, Audard V, Sartoretti P, Roth AD, Brezault C, Le Charpentier M, Dousset B, Morel P, Soubrane O, Chaussade S, Mentha G, Terris B (2004) Severe hepatic sinusoidal obstruction associated with oxaliplatin-based chemotherapy in patients with metastatic colorectal cancer. *Ann Oncol* **15**: 460–466
- Saltz LB, Cox JV, Blanke C, Rosen LS, Fehrenbacher L, Moore MJ, Maroun JA, Ackland SP, Locker PK, Pirotta N, Elfring GL, Miller LL (2000) Irinotecan plus fluorouracil and leucovorin for metastatic colorectal cancer. Irinotecan Study Group. *N Engl J Med* **343**: 905–914
- Seymour MT, Maughan TS, Ledermann JA, Topham C, James R, Gwyther SJ, Smith DB, Shepherd S, Maraveyas A, Ferry DR, Meade AM, Thompson L, Griffiths GO, Parmar MK, Stephens RJ, FOCUS Trial Investigators; National Cancer Research Institute Colorectal Clinical Studies Group (2007) Different strategies of sequential and combination chemotherapy for patients with poor prognosis advanced colorectal cancer (MRC FOCUS): a randomized controlled trial. *Lancet* **370**: 143–152
- Thirion P, Michiels S, Pignon JP, Buyse M, Braud AC, Carlson RW, O'Connell M, Sargent P, Piedbois P (2004) Modulation of fluorouracil by leucovorin in patients with advanced colorectal cancer: an updated meta-analysis. *J Clin Oncol* **22**: 3766–3775
- Tournigand C, Andre T, Achille E, Lledo G, Flesh M, Mery-Mignard D, Quinaux E, Couteau C, Buyse M, Ganem G, Landi B, Colin P, Louvet C, De Gramont A (2004) FOLFIRI followed by FOLFOX6 or the reverse sequence in advanced colorectal cancer: a randomized GERCOR study. *J Clin Oncol* **22**: 229–237
- Van Cutsem E, Nowacki M, Lang I, Cascinu S, Shchepotin I, Maurel J, Rougier P, Cunningham D, Nippgen J, Köhne C (2007) Randomized phase III study of irinotecan and 5-FU/FA with or without cetuximab in the first-line treatment of patients with metastatic colorectal cancer (mCRC): The CRYSTAL trial. *J Clin Oncol* **25**: 164S, abstract 4000
- Van Cutsem EJ, Oliveira J, Kataja VV (2005) ESMO minimum clinical recommendations for diagnosis, treatment and follow-up of advanced colorectal cancer. *Ann Oncol* **16**(Suppl 1): i18–i19
- Zaniboni A, Torri V, Tinazzi A, Codignola C, Faggiuolo R, Sperti E (2005) Neoadjuvant oxaliplatin-based chemotherapy for liver metastases from colorectal cancer. An Italian survey. *Tumori* **91**: 383–387