



Inflammation and infection

## A severe complication of intravesical bacillus Calmette-Guerin: An effect of different strains

Li Sian Low<sup>\*</sup>, David Scholtz, John Leyland, Shiva Madhwan Nair

Urology Department, Level B1, Waikato Hospital, Hamilton, New Zealand



## ARTICLE INFO

## Keywords:

Complications  
Bacillus camille-guerin  
SII Onco BCG

## ABSTRACT

The use of intravesical BCG has improved the survival and outcomes in the treatment of bladder cancer. However, the worldwide shortage of OncoTice BCG has caused disruption and changes in treatment regimes, leading to use of alternative strains. We describe a severe complication as the result of using intravesical SII Onco BCG for the treatment bladder cancer, in an 82 year old man presenting with granulomatous epididymo-orchitis.

## Introduction

Intravesical bacillus Camille-Guerin (BCG) therapy is the preferred treatment for intermediate and high-grade non muscle invasive bladder cancer. It has been shown to be more effective than Transurethral Resection of Bladder Tumour (TURBT) alone. The commonly used treatment regime involves an induction course and maintenance therapy up to 36 months.<sup>1</sup>

The BCG antigens stimulate a variety of events that facilitate anti-tumour effects, by: 1) increasing induction of and infiltration by macrophages and CD4 T cell; 2) increasing MHC Class II expression on tumour cells to further augment antigen presentation and T-cell activation; 3) triggering release of cytokines that facilitate tumour cell death; 4) directly suppressing tumour growth.<sup>2</sup>

Common self-limiting side effects include urinary frequency and/or urgency, cystitis, fever, and hematuria. More severe complications are reported in less than 5% of cases. Local complications involve inflammation, infection and/or abscess formation within the genitourinary tract organs. Systemic complications occur from extra-urinary dissemination of BCG.<sup>3</sup>

Due to the global shortage of OncoTICE (Merck, USA), we utilised SII Onco BCG (Serum Institute, India) as our substitute. However, we noticed higher discontinuation rates and severe complications in our patients with the use of SII Onco BCG, one of them described with our case below.

## Case presentation

Our case involved an 82-year-old man presenting with a testicular mass, eleven months following commencement of intravesical BCG. In 2019, he developed pTa high grade urothelial cell carcinoma. His medical background included dementia, Type II diabetes, atrial fibrillation, hypertension, and primary hyperparathyroidism.

He started his induction course (SII Onco BCG) two months after diagnosis. Subsequent cystoscopy revealed no evidence of recurrence. Following that, he received his first maintenance course of BCG. However, the patient chose to cease treatment after his final dose of his first maintenance course as he was unable to tolerate his treatment anymore.

He presented a month later with a swollen right testicle with a malignant feel to it on examination. An emergent ultrasound (Fig. 1) was organised which revealed a heterogenous hypoechoic mass at the lower pole of the right testicle, measuring 38.1 ml (testicle volume: 51.3 ml). A radical inguinal orchidectomy was performed, where histology revealed an extensive inflammatory process involving the epididymis and surrounding fibroadipose tissue consistent with granulomatous epididymo-orchitis (Fig. 2). No evidence of malignancy was identified. Special staining for microorganisms showed no mycobacteria nor fungi. He recovered well following surgery and is currently on surveillance for his bladder cancer.

## Discussion

OncoTICE has been our department's preferred strain of intravesical BCG for the treatment of intermediate and high grade non muscle

<sup>\*</sup> Corresponding author.

E-mail addresses: [lisian.low@waikatodhb.health.nz](mailto:lisian.low@waikatodhb.health.nz) (L.S. Low), [David.scholtz@waikatodhb.health.nz](mailto:David.scholtz@waikatodhb.health.nz) (D. Scholtz), [John.Leyland@waikatodhb.health.nz](mailto:John.Leyland@waikatodhb.health.nz) (J. Leyland), [Shiva.Nair@waikatodhb.health.nz](mailto:Shiva.Nair@waikatodhb.health.nz) (S.M. Nair).

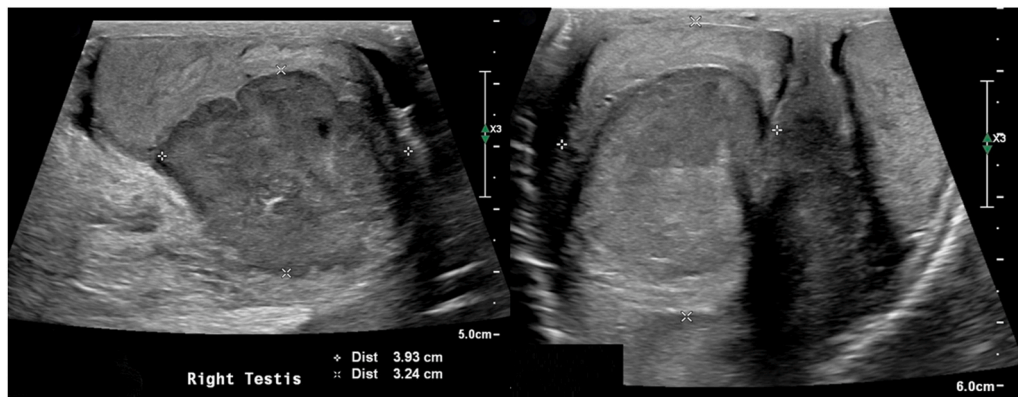
<https://doi.org/10.1016/j.eucr.2021.101592>

Received 13 January 2021; Received in revised form 27 January 2021; Accepted 30 January 2021

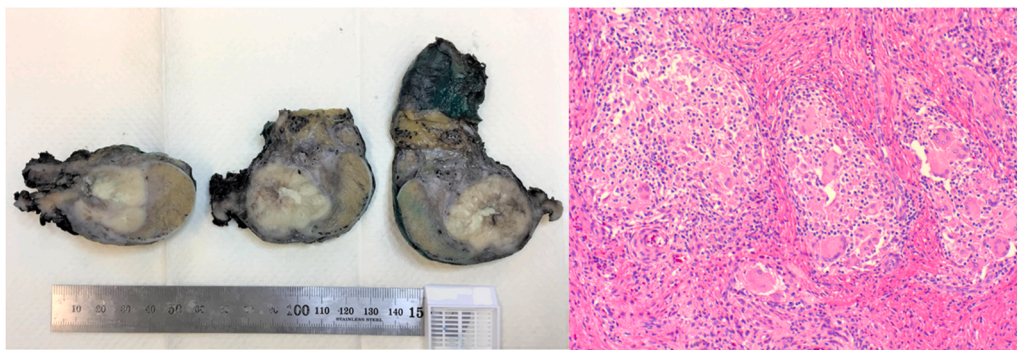
Available online 3 February 2021

2214-4420/© 2021 The Author(s). Published by Elsevier Inc. This is an open access article under the CC BY-NC-ND license

(<http://creativecommons.org/licenses/by-nc-nd/4.0/>).



**Fig. 1.** Ultrasound imaging demonstrating a heterogenous hypoechoic mass at the lower pole of the right testicle.



**Fig. 2.** Gross image showing a lobulated, solid, cream tumour within the testis with central necrosis. Histology shows granulomatous inflammation characterized by aggregates of histiocytes with admixed giant cells and scattered lymphocytes.

invasive bladder cancer. However, due to the worldwide shortage of OncoTICE, we made the decision to use SII Onco BCG as the alternative. We have identified a higher number of new and existing patients describing more symptoms of bladder irritability with the use of SII Onco BCG, leading to the termination of treatment. Severe dysuria/urgency, ongoing hematuria, incapacitating bladder spasms, prolonged malaise are among the symptoms noticed by patients after transitioning to SII Onco BCG. A cystoprostatectomy had to be performed on one of our patients, to relieve him from constant severe symptoms related to bladder contracture, after he transitioned to SII Onco BCG. Prior to the transition, we have not encountered a case of granulomatous orchitis (masquerading as a testicular tumour) nor severe bladder irritation (leading to cystectomy) with the use of OncoTICE.

Chronic inflammation on BCG affected tissue results in granuloma formation, fibrosis, and calcification. Repeated instillations of BCG activate resident lymphocytes from previous treatments causing amplification of the immune-mediated process, which may be affected by genetic differences between BCG substrains. Adverse outcomes of intravesical BCG can range from minor to severe. BCG-related epididymo-orchitis can result in enlargement of the epididymis and testicle. It can present as a heterogenous, hypoechoic, solid mass on ultrasonography and ultimately, this inflammatory mass can mimic malignancy.<sup>4</sup>

The original strain of BCG (*M. bovis*) has undergone genetic evolution as a result of the subculturing process. Studies on DNA sequences revealed that each different strain exhibit extensive differences at the level of surface proteins and antigenic expression, which influence its virulence and reactogenicity. This could explain how each different BCG substrain have the potential to interact differently with the patient.<sup>5</sup>

## Conclusion

Severe adverse reactions to intravesical BCG are rare but can be debilitating to patients. In this case report, we have depicted a severe but rare complication related to the use of SII Onco BCG, highlighting the importance of informing patients of the risks and possibility of severe symptoms prior to commencement of therapy.

## Consent

This manuscript contains no patient identifiable data. Verbal and documented informed consent have been obtained.

## Funding

This research did not receive any specific grant from funding agencies in the public, commercial, or not-for-profit sectors.

## Author contributions

Li Sian Low: Data curation, Methodology, Investigation, Writing-Original Draft, Formal analysis.

David Scholtz: Writing-Editing, Investigation.

John Leyland: Conceptualization, Review/Editing, Supervision.

Shiva Madhwan Nair: Conceptualization, Review/Editing, Supervision.

## Declaration of competing interest

The authors report no conflict of interests.

## Acknowledgements

We would like to thank Dr Nanise Cuthers for the procurement of the histology slides.

## References

1. Lamm DL, Blumenstein BA, Crissman JD, et al. Maintenance bacillus Calmette-Guerin immunotherapy of recurrent TA, T1 and carcinoma in situ transitional cell carcinoma of the bladder: a randomized Southwest Oncology Group Study. *J Urol.* 2000 Apr;163(4):1124–1129.
2. Redelman-Sidi G, Glickman MS, Bochner BH. The mechanism of action of BCG therapy for bladder cancer—a current perspective. *Nat Rev Urol.* 2014 Mar;11(3):153.
3. Green DB, Kawashima A, Menias CO, et al. Complications of intravesical BCG immunotherapy for bladder cancer. *Radiographics.* 2019;39:80–94.
4. Liu Y, Lu J, Huang Y, Ma L. Clinical spectrum of complications induced by intravesical immunotherapy of Bacillus calmette-guérin for bladder cancer. *Journal of Oncology.* 2019;2019:1–11.
5. D'Andrea D, Gontero P, Shariat SF, Soria F. Intravesical bacillus Calmette-Guérin for bladder cancer: are all the strains equal? *Transl Androl Urol.* 2019;8(1):85–93.