

An Experimental Model of Ischemia in Rabbit Hindlimb

This study was performed to establish an experimental model of ischemia for the investigation of new treatment modality of limb-threatening ischemia. We produced ischemia in the hindlimbs of 8 New Zealand white rabbits. Under general anesthesia, the left femoral artery was exposed, freed, and excised from distal external iliac artery to proximal popliteal and saphenous arteries. And then both hindlimbs were serially examined to assess the ischemia according to the time table until postoperative 6 weeks. We assessed clinical observation, blood pressure, radioisotopic perfusion scan, and angiography. Clinical ischemic changes of the operated feet were observed in 63%. The blood pressure of left calves was measurable on postoperative day 3 ($p < 0.05$, vs preoperative day 2) and then gradually increased to reach a plateau in postoperative week 6. Radioisotopic arterial perfusion showed similar profiles as in blood pressure. Angiography of ischemic hindlimbs demonstrated a few collateral vessels arising from the internal iliac artery with the reconstitution of the posterior tibial artery in postoperative week 2. In postoperative week 6, collaterals remained the same in number. However, these became dilated and tortuous and showed reconstitution in distal hind-leg. In conclusion, this is a reproducible, measurable, and economical animal model of hind limb ischemia.

Key Words : Ischemia; Hindlimb; Rabbits

Ju Hee Hong*, Yong-Whee Bahk[†],
Jun Suk Suh[‡], Byung Kook Kwak[§],
Hyung Jin Shim[¶], Jin Soo Kim^{||},
Ho Sung Kim[¶], Young Ho Moon^{**},
Sung Jin Kim^{††}, Jin Wook Chung^{‡‡},
Jae Hyung Park^{‡‡}

Department of Radiology*, and Nuclear Medicine[†],
Sungae General Hospital; Department of Surgery[‡],
Seoul National University College of Medicine;
Cardiovascular Center; Department of Radiology,
Yongsan Hospital, Chung-Ang University College
of Medicine[§]; Department of Plastic Surgery^{||}, and
Surgery[¶], Kwangmyung Sungae General Hospital;
Goodgene Incorporation^{**}; Department of Radiology,
Chungbuk National University College of Medicine^{††};
Department of Radiology^{‡‡}, Seoul National University
College of Medicine, Seoul, Korea

Received : 28 March 2001

Accepted : 1 June 2001

Address for correspondence

Jun Suk Suh, M.D.
Department of Surgery, Seoul National University
College of Medicine, Seoul Municipal Boramae
Hospital, 395 Shindaebang-dong, Dongjak-gu,
Seoul 156-012, Korea
Tel : +82-2-840-2421, Fax : +82-2-840-2886
E-mail : suhjs@snu.ac.kr

*This work was supported by 2000 Guerbet research
fund of Korea Society of Radiology.

INTRODUCTION

There has been a development of surgical, interventional and medical treatments of peripheral vascular diseases, such as atherosclerotic occlusion of arteries, diabetic small vessel disease, and Buerger's disease for the past several decades. However, if these diseases are diffuse and progressive, these patients may eventually require limb amputation. For these reasons, new approaches towards the limb-salvage and the treatment of limb-threatening ischemia have been developed during the last two decades. For example, popliteal arteriovenous reversal in the ischemic limb has been attempted for the revascularization in the calf and vascular proliferation in the thigh (1, 2). Recently many researchers have been interested in the therapeutic angiogenesis (3-10). Their intentions are to increase vascular proliferation and perfusion in the ischemic limb by direct injection of angiogenic factors. So the need for suitable animal ischemic models, which show the measurable and persistent ischemia in the

limb, has been increased for the basis of these studies (11-14).

The characteristics of chronic human ischemia are the involvement of multiple vessels, development of some collaterals, and the long-standing nature. The preparation of a persistent animal ischemic model of the limb that is comparable with chronic human ischemia is difficult. This is because the animals show a remarkable ability to form collaterals and regain the normal arterial perfusion within a short period after ligation of one or two proximal arteries of the limb. The simple ligation of iliac or femoral arteries could not produce adequate ischemia at rest (11-13, 15, 16). The multiple ligation of branches of the iliac, common femoral, and deep femoral arteries shows only a short time of ischemia in a dog model (17). Aortic ligation produces variable results depending on the experimental animals, and it is impossible to use a contralateral limb as a control (18, 19). Moreover, the evaluation of the ischemic model should be measurable by less invasive, objective, and convenient methods.

We made a persistent animal ischemic model, in which

ischemia was induced in the left hindlimb of a rabbit by excision of femoral artery from the distal external iliac artery to the proximal popliteal and saphenous arteries and was persistently maintained for 6 weeks postoperatively. The evaluation of the ischemic left hindlimb was compared with the normal right hindlimb.

MATERIALS AND METHODS

Surgical technique

Eight New Zealand white rabbits (male, 2.0-2.8 kg, mean weight 2.4 kg) were anesthetized with an intramuscular injection of Ketamine (35 mg/kg) and Rompun (xylazine 5 mg/kg). After the sterilization with 95% alcohol, the left femoral artery was exposed through a longitudinal skin incision in the medial thigh, which is extended from the inguinal ligament to the knee. At first, the femoral artery was dissected along its total length and all of its branches (the inferior epigastric, deep femoral, lateral circumflex, and superficial epigastric arteries) were also dissected. Then the dissection of the popliteal and saphenous arteries was done distally and the distal external iliac artery, as well as all of the arteries mentioned above, was ligated. Finally, the left femoral artery was completely excised from the distal external iliac artery to the proximal popliteal and saphenous arteries (Fig. 1). After suture and disinfection of the incision site, all animals received Ceftezole (100 mg/kg/day) intramuscularly for 3 days, beginning on the day of surgery. Analgesic agents were not administered.

Assessments

We serially evaluated 8 rabbits by clinical assessments of both hindlimbs and the measurements of the blood pressure of both calves for a total of 7 times: on preoperative day 2,

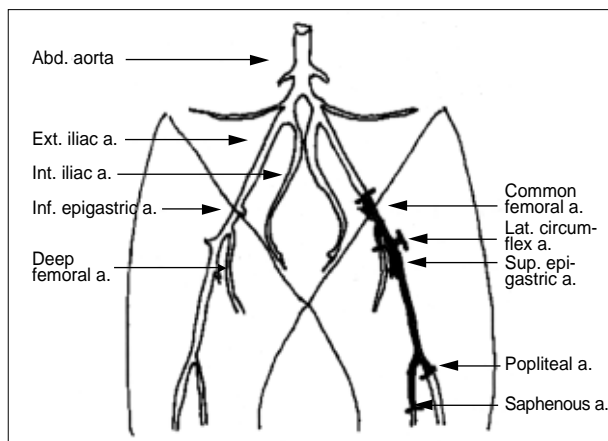


Fig. 1. Schematic drawing of surgical procedure (shaded vessels was ligated and excised).

immediately after the operation, on postoperative day 3 and in postoperative week 1, 2, 4, and 6. Calf radioisotopic perfusion was made on preoperative day 2, postoperative day 3, and in postoperative week 2 and 6, with a total of four times. In 6 animals, angiography of both hindlimbs was performed in postoperative week 2 and 6 (Table 1).

Clinical assessments

We observed the state of operation sites, limping, atrophy of muscle, and changes of hair, nails, and toes for 6 weeks after the operation.

Calf blood pressure

We measured the calf blood pressure through the Oscilloscopic neonatal vital sign monitor, Criticon DINAMAP XL Portable Monitor 8100 (Johnson & Johnson Medical Inc., Florida, U.S.A.), which is more accurate and convenient than the Doppler flowmeter used by other authors. Both hindlimbs were shaved and cleansed. Under light anesthesia, the blood pressure in the calf along the posterior tibial arterial course was measured after being wrapped with a neonatal-sized #3 cuff. Systolic, diastolic, and mean blood pressure were determined and repeated 3 times. Mean blood pressure was used as a calf blood pressure and its ratio of left to right (L/R ratio) was defined.

Calf radioisotopic perfusion scan

For the quantification of arterial perfusion in the calf, we used radioisotope scanning with ^{99m}Tc-04. After the light anesthesia, the marginal vein of the ear was punctured with a scalp vein needle and the radioisotope was injected and pushed by a 2 mL normal saline. Then, dynamic scanning was done for 1 min, at 1 sec interval with the Orbiter Gamma Camera (Siemens, Germany). For the processing of the radioactive counts, we obtained the summation images of a total of 60 dynamic radioisotope (RI)-angiogram images, obtained for 60 sec and from each calf and placed a ROI (regions of interest) in both calves. We drew graphs of the change of counts and compared in both sides. The ratio

Table 1. Time table of assessment

	P/E*	B/P†	RI scan‡	Angiography
Preoperation day	+	+	+	
Operation day	+	+		
3 days	+	+	+	
1 week	+	+		
2 weeks	+	+	+	+
4 weeks	+	+		
6 weeks	+	+	+	

*P/E: physical examination; †B/P: blood pressure; ‡RI scan: radioisotope scan

changes of the counts between operated and control calves (L/R) were compared as one graph (for 10 sec after visualization of abdominal aorta) in all 4 times previously described.

Angiography

Under general anesthesia, the left carotid artery was exposed through a ventral incision in the neck. A 4-F Cobra catheter was introduced into the exposed artery through the Seldinger technique and advanced to 3 cm proximal to the aortic bifurcation. 2 mL lidocaine was injected for the prevention of lower limb cramp and vascular spasm. A total of 8 mL of contrast agent (Visipaque 350, Nycomed, Oslo, Norway) was injected at a rate of 3 mL/sec. The serial filming (1 film per 3 sec) of both hindlimbs was done. Vascularization of the left thigh was quantitated by direct counting of the number of arteries crossing a line, drawn vertically across the mid thigh. Vessel numbers were averaged. We also compared the number of left side vessels with right control side (L/R ratio) and observed the collateral patterns.

Statistical analysis

All data were expressed as the mean \pm SE. Statistical comparisons between the two hindlimbs of each animal was performed using the paired Student t-test. A *p* value of less than 0.05 was accepted as statistically significant.

Table 2. Results of clinical assessment (n=8, %)

Operation day	Operative changes				Limping	Muscle atrophy
	swelling	granuloma	Ischemic color	changes necrosis		
100	0	0	0	0	100	0
3 days	100	0	0	0	100	0
1 week	100	0	0	0	25	0
2 weeks	0	0	0	0	25	13
4 weeks	0	13	25	25	25	25
6 weeks	0	28	25	38	13	25

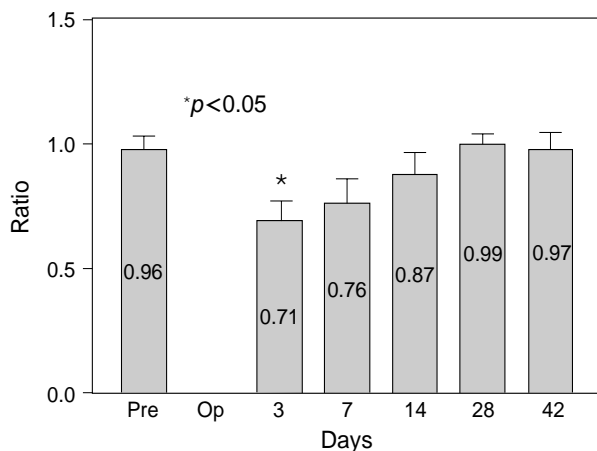


Fig. 2. Calf blood pressure ratio (L/R).

RESULTS

Clinical assessment

Calf muscle atrophy and ischemic changes of the feet including toe necrosis were observed in 25% and 63% of the 8 rabbits, respectively. Ischemic changes were evaluated as only color change group and necrosis group. The clinical observations are summarized in Table 2.

Calf blood pressure

The calf blood pressure was not measurable immediately after the operation. It was measured on postoperative day 3 (*p*<0.05, vs preoperative day 2) and gradually increased to the plateau level of 0.99 and 0.97 in postoperative week 4 and 6, respectively (Fig. 2).

Calf radioisotopic perfusion scan

The L/R ratio of arterial perfusion was significantly reduced on postoperative day 3 (*p*<0.05, vs preoperative day 2) for

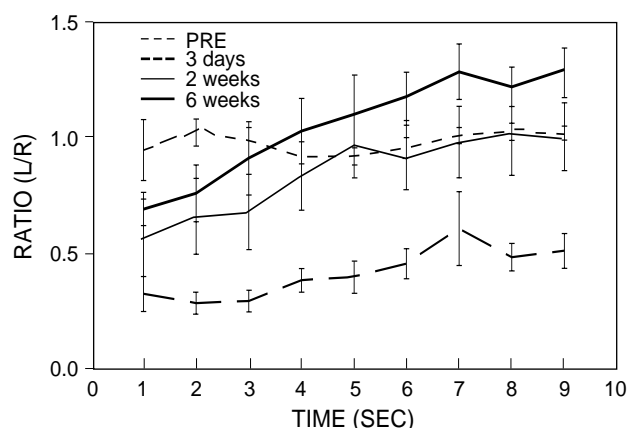


Fig. 3. Calf radioisotope perfusion ratio.

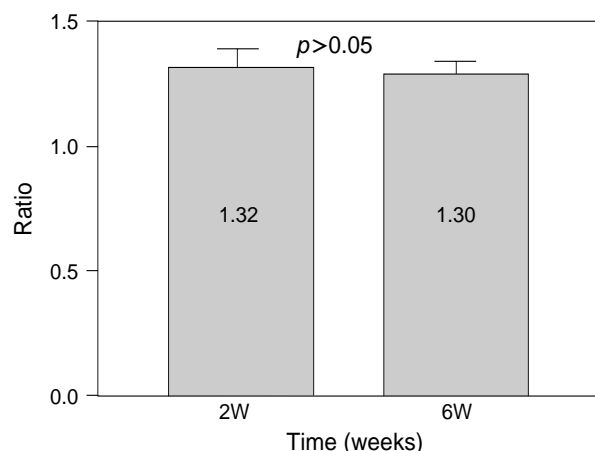


Fig. 4. Vessel number ratio (L/R).

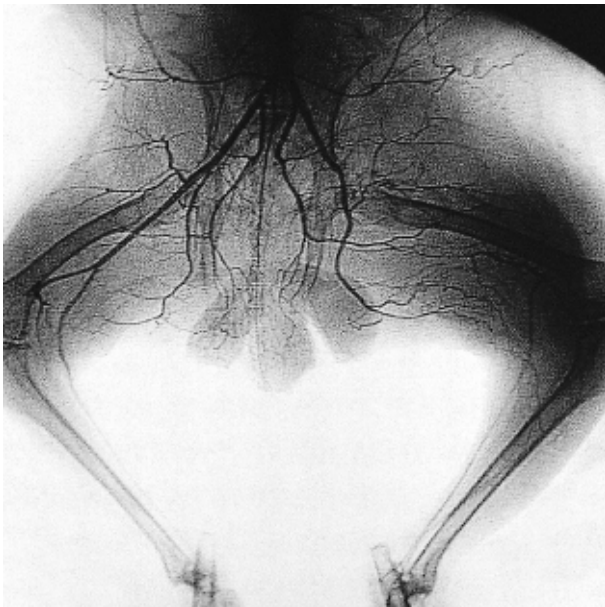


Fig. 5. Angiography of both hindlimbs at 2 weeks.

3-4 sec after the visualization of abdominal aorta in arterial phase. This ratio markedly increased in postoperative week 2 and gradually increased to a plateau for the next 4 weeks (Fig. 3).

Angiography

Angiography, performed in postoperative week 2, demonstrated a few collateral vessels arising from internal iliac artery in the left thigh with the reconstitution of the posterior tibial artery at the knee level. In postoperative week 6, the collateral vessels remained same in number ($p > 0.05$, vs postoperative week 2). However the collaterals became dilated and tortuous. And they showed reconstitution in the distal hindleg (Fig. 4-6).

DISCUSSION

The preparation of an animal model of a persistent limb ischemia that is comparable to chronic extensive human limb ischemia must meet several important criteria. These include reproducibility, stability of ischemia, objective assessment, and comparability with the contralateral normal limb.

Because most animals have the ability of reopening vascular obstruction and recovering perfusion in a short time by making collaterals, the creation of a persistent limb ischemia has been problematic. Even the ligation of a few proximal arteries does not bring the persistent ischemia on the resting hindlimb during the adequate time. So far the animal model of persistent ischemia at rest has been tried in a cat, canine, rabbit, and rat by ligating (or occluding) the vessels.

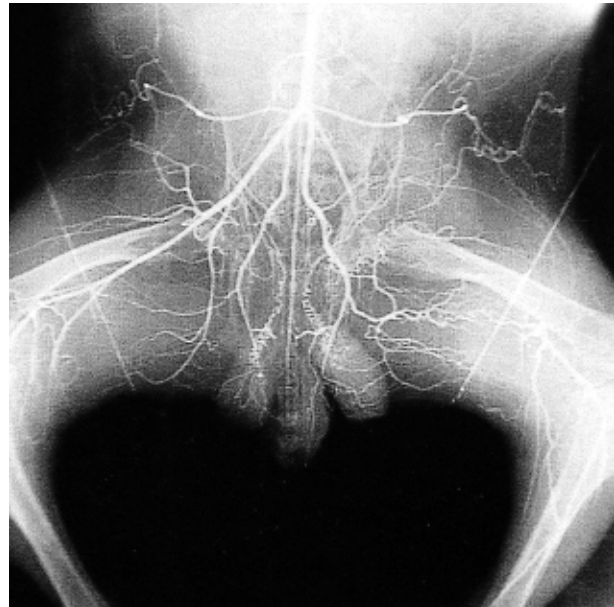

Fig. 6. Angiography of both hindlimbs at 6 weeks.

However, the results were not satisfactory in the anatomic, clinical, and physiological viewpoints (11, 13). Longland (20) occluded the femoral artery of rabbits by long-lasting and probably permanent thrombosis, using thrombin and a sclerosant. He opened the abdomen under anesthesia and made arteriograms of both hindlimbs by injecting thoro-trast (contrast material) into the abdominal aorta, to directly study collateral systems. He thought that this would be a more closely approached to naturally occurring obliterative disease than ligation or excision. He asserted that arterial collaterals would respond promptly by dilatation to blockage of the main artery in the next few hour or days, and by becoming differentiated in many weeks and months thereafter. However, this model was too invasive and followed many animal losses during experiment. After these and other trials and errors, Pu et al. (14) described a persistent hindlimb ischemia model in the rabbit by ligation of the distal external iliac artery and excision of the common and superficial femoral arteries in 1992. The reasons that most studies chose the rabbit for the experimental animals are adequate cost, good management, easy maintenance, and less complete formation of collaterals than the dog.

With Pu et al.'s method, we produced hindlimb ischemia in eight rabbits and assessed for 6 weeks. This model avoided common iliac artery ligation, which required a laparotomy and is less effective in producing ischemia. This model also preserved the inflow to the thigh, especially from the internal iliac and circumflex arteries, important sources of collateral development after surgical procedure. We think that our long segmental excision of femoral artery follows the same concept as Longland's method.

We divided the clinical assessment into postoperative and

ischemic changes. Most postoperative changes were improved. However the ischemic changes were not improved or even advanced. But there were no significant differences between ischemic and nonischemic groups in blood pressure, RI perfusion scans, and angiographic findings (data not shown). These findings suggest that ischemic insult resulted in different clinical response to individual animals but the collateral response might be the same.

We carried out blood pressure measurement and RI perfusion scans of calves as the mirror of postoperative perfusion changes of hindlimbs. In the L/R ratio of RI arterial perfusion, the rise of perfusion in the ischemic limb was blunted after postoperative 2 weeks but, the ischemia persisted for postoperative 6 weeks. These results support persistent ischemic effects after 2 weeks of operation. The reason why we assessed arterial perfusion in the calves was due to the avoidance of the postoperative effect in the thigh. We used nonparticulate ^{99m}Tc -04 as a radioisotope instead of particulate ^{99m}Tc -MAA. The ^{99m}Tc -MAAs that other authors used for determining regional distribution of blood flow are larger particles than capillaries and thus are trapped in the first capillary bed they encounter and distributed in proportion to the perfusion (14, 17, 21). But, the ^{99m}Tc -04 that we used are not particles, so we could get a radioisotopic angiogram for 1 min and evaluate regional dynamic distribution of blood flow. This method is superior to the particle-distribution method in avoiding direct ventricular puncture and particle-induced secondary perfusion disturbance, and for serial comparison of arterial perfusion during the postoperative periods. There was a trend of the paradoxical increase of the postoperative L/R ratio after arterial phase. This was because of the accumulation of radioisotope in the extracellular fluid, even with recirculation and excretion of ^{99m}Tc -04.

We performed arteriogram of both hindlimbs for evaluation of collateral formation, their change, and vascular reconstitution. In postoperative week 2, the development of a few collaterals was noted in the left thigh with reconstitution in the knee level. After 4 weeks, the number of left collaterals were the same but they became tortuous and dilated, showing reconstitution in calf and ankle levels. These findings reflected persistent ischemia in the operated hindlimb from 2 to 6 weeks.

The limitations of the animal ischemic model are acutely induced but persistent vascular occlusion that is mixed acute and non-acute ischemia without a distinct border and no long-term follow up. We did not measure the rise of the femoral venous lactate level, nor examined the histologic changes of muscle such as necrosis or fibrosis because these changes reflect acute ischemic insult before postoperative 10 days (22, 23).

In summary, this animal model of persistent hindlimb ischemia, in which unilateral ischemia was induced by surgical excision of femoral arteries, is reproducible, measur-

able, economical, and comparable with the other side. This animal model is useful for the investigation of alternative therapies for limb-salvage of chronic human limb ischemia.

ACKNOWLEDGMENTS

We thank Mr. Jong Bum Son, Sun Il Suh, and Il Young Lee for technical assistance and Department of Nuclear Medicine, Catholic University of Korea College of Medicine, St Mary's Hospital for providing nuclear scanning equipments.

REFERENCES

- Graham AM, Sniderman A, Jothy S, Homan J, Symes JF. *Staged reversal of venous flow for revascularization of the severely ischemic limb. J Surg Res* 1983; 35: 11-20.
- Graham AM, Baffour R, Burdon T. *A demonstration of vascular proliferation in response to arteriovenous reversal in the ischemic canine hind limb. J Surg Res* 1989; 47: 341-7.
- Pu LQ, Sniderman AD, Arekat Z. *Angiogenic growth factor and revascularization of the ischemic limb: evaluation in a rabbit model. J Surg Res* 1993; 54: 575-83.
- Baffour R, Berman J, Grab JL, Rhee SW. *Enhanced angiogenesis and growth of collaterals by in vivo administration of recombinant basic fibroblast growth factor in a rabbit model of acute lower limb ischemia: dose-response effect of basic fibroblast growth factor. J Vasc Surg* 1992; 16: 181-91.
- Yanagisawa M, Uchida Y, Nakamura F, Tomaru T, Kido H, Kamijo T, Sugimoto T, Kaji K, Utsuyama M, Kurashima C, Ito H. *Salvage of infarcted myocardium by angiogenic action of basic fibroblast growth factor. Science* 1992; 257: 1401-3.
- Pu LQ, Sniderman AD, Brassard R. *Enhanced revascularization of the ischemic limb by angiogenic therapy. Circulation* 1993; 88: 208-15.
- Riessen R, Rahimizadeh H, Blessing E, Isner JM. *Arterial gene transfer using pure DNA applied directly to a hydrogel-coated angioplasty balloon. Hum Gene Ther* 1993; 4: 749-58.
- Mack CA, Magovern CJ, Budenbender KT, Patel SR, Schwarz EA, Zanzonico P, Ferris B, Sanborn T, Isom W, Crystal RG, Rosengart TK. *Salvage angiogenesis induced by adenovirus-mediated gene transfer of vascular endothelial growth factor protects against ischemic vascular occlusion. J Vasc Surg* 1998; 27: 699-709.
- Shyu KG, Manor O, Magner M, Yancopoulos GD, Isner JM. *Direct intramuscular injection of plamid DNA encoding angiopoietin-1 but not angiopoietin 2 arguments revascularization in the rabbit ischemic hindlimb. Circulation* 1998; 98: 2081-7.
- Morishita R, Nakamura S, Hayashi S, Taniyama Y, Moriguchi A, Nagano T, Taiji M, Noguchi H, Takeshita S, Matsumoto K, Nakamura T, Higaki J, Ogihara T. *Therapeutic angiogenesis induced by human recombinant hepatocyte growth factor in rabbit hind limb ischemia model as cytokine supplement therapy. Hypertension* 1999; 33: 1379-84.

11. Seifert FC, Banker M, Lane B, Bagge U, Anagnostopoulos CE. *An evaluation of resting arterial ischemia models in the rat hind limb. J Cardiovasc Surg* 1985; 26: 502-8.
12. Challiss RAJ, Hayes DJ, Petty RFH, Radda GK. *An investigation of arterial insufficiency in rat hindlimb: a combined ³¹P-n.m.r. and blood flow study. Biochem J* 1986; 236: 461-7.
13. Hendricks DL, Pevec WC, Shestak KC, Rosenthal MC, Webster MW, Steed DL. *A model of persistent partial hindlimb ischemia in the rabbit. J Surg Res* 1990; 49: 453-7.
14. Pu LQ, Jackson S, Lachapelle KJ, Arekat Z, Graham AM, Lisbona R, Brassard R. *A persistent hindlimb ischemia model in the rabbit. J Invest Surg* 1994; 7: 49-60.
15. Janda J, Linhart J, Kasalicky J. *Experimental chronic ischemia of the skeletal muscle in the rat. Physiol Bohemoslov* 1974; 23: 521-6.
16. Urbanova D, Janda J, Mihova O, Linhart J. *Enzyme changes in the ischemia of skeletal muscle and the effect of physical conditioning: a histological study. Histochem J* 1974; 6: 147-53.
17. Barie PS, Mullins RJ. *Current research review: experimental methods in the pathogenesis of limb ischemia. J Surg Res* 1988; 44: 284-307.
18. Kelts K, Kaiser K. *Experimental ischemic myopathy. J Neurol Sci* 1979; 40: 23-7.
19. Weiss L. *Aspects of the relation between functional and structural cardiovascular factors in primary hypertension. Acta Physiol Scand (suppl)* 1974; 409: 25-6.
20. Longland CJ. *The collateral circulation of the limb. Ann R Coll Surg Engl* 1953; 13: 161-81.
21. Siegel ME. *Use of radioactive tracers in the evaluation of peripheral arterial disease. In: Cardiovascular nuclear medicine. Strauss HW, Pitt B, eds. St. Louis: Mosby; 1979; 348-72.*
22. Carpenter S, Karpati G. *Pathology of skeletal muscle. New York: Churchill Livingstone, 1984.*
23. Walker PM, Harris KA, Tanner WR, Harding R, Romaschin AD, Mickle DAG. *Laboratory evaluation of patients with vascular occlusive disease. J Vasc Surg* 1985; 2: 892-7.