

# Double vascular ring: a case report of double aortic arch and concurrent pulmonary artery sling

Yoshimi Matsumoto\*, Masahiro Kamada, Naomi Nakagawa, and Yukiko Ishiguchi

Department of Pediatric Cardiology, Hiroshima City Hiroshima Citizens Hospital, 7-33, Motomachi, Naka-ku, Hiroshima City, Hiroshima, Japan

Received 30 September 2018; accepted 28 January 2019; online publish-ahead-of-print 1 April 2019

## Background

Double aortic arch (DAA) and pulmonary artery sling (PAS) are vascular ring formations that present in neonates and infants with symptoms of respiratory stenosis.

## Case summary

The patient was a girl with suspected ventricular septal defect (VSD), right aortic arch (AA), left patent ductus arteriosus, and bilateral superior vena cava (SVC) on foetal echography in the first day of life. The girl was delivered at 40 weeks and 4 days of gestation. Ventricular septal defect, DAA, coarctation of the left AA, and bilateral SVC were diagnosed. Contrast-enhanced computed tomography at Day 16 revealed PAS with concurrent anomalous tracheal branching in addition to DAA. The right A2 segmental artery, which supplies the right upper pulmonary artery, showed abnormal branching from the left pulmonary artery (LPA). At 3 months of age, VSD patching, left AA resection distal to the root of the left subclavian artery, arterial ligament dissection, and LPA replacement were performed.

## Discussion

Pulmonary artery sling coexists with anomalous branching of the trachea and abnormal branching of the right pulmonary artery (RPA). Our patient had an extremely rare case of DAA concurrent with PAS and presented with anomalous tracheal and RPA branching. We were concerned that increased pulmonary blood flow caused by the VSD would exacerbate tracheal displacement. Radical surgery at 3 months of age resulted in good postoperative progress.

## Keywords

Double aortic arch • Pulmonary artery sling • Vascular ring • Case report

## Learning points

- Double aortic arch can be concurrent with pulmonary artery sling, and we define two vascular rings overlap as double vascular ring.
- A case of double vascular ring has high risk of tracheal stenosis. Performing radical surgery in early infancy is likely to be effective.

## Introduction

A double aortic arch (DAA) forms a vascular ring when either the left and right fourth pharyngeal arcuate arteries originating from the

aorta do not regress. DAA surrounds the trachea and oesophagus, causing symptoms such as recurrent upper respiratory tract infections, wheezing, and dysphagia.<sup>1</sup> Pulmonary artery sling (PAS) is an extremely rare anomaly in which the left pulmonary artery (LPA)

\* Corresponding author. Tel: +81 90 4787 9294, Fax: +011 81 82 223 5514, Email: [yoshimi.m.apple@gmail.com](mailto:yoshimi.m.apple@gmail.com)

Handling Editor: Julia Grapsa

Peer-reviewers: Laszlo Gobolos and Julia Grapsa

Compliance Editor: Anastasia Vamvakidou

Supplementary Material Editor: Peysh A. Patel

© The Author(s) 2019. Published by Oxford University Press on behalf of the European Society of Cardiology.

This is an Open Access article distributed under the terms of the Creative Commons Attribution Non-Commercial License (<http://creativecommons.org/licenses/by-nc/4.0/>), which permits non-commercial re-use, distribution, and reproduction in any medium, provided the original work is properly cited. For commercial re-use, please contact [journals.permissions@oup.com](mailto:journals.permissions@oup.com)

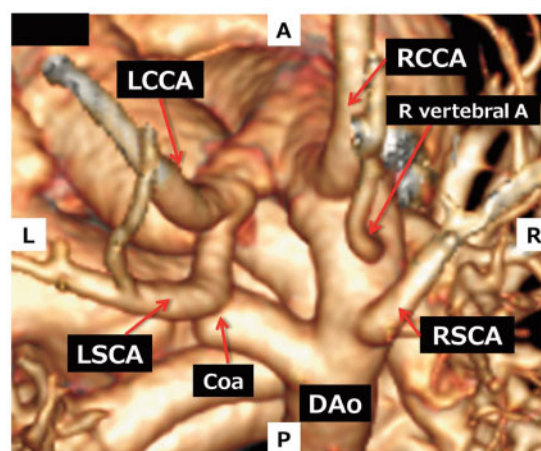
originates from the right pulmonary artery (RPA),<sup>1</sup> displaces the trachea, and causes symptoms of trachea and bronchial tree compression. We believe that this is the first reported case of a patient with concurrent DAA and PAS. Its interest derives from the achieving a good outcome with prompt surgical intervention.

## Timeline

At 37 weeks and 6 days of gestation	Foetal echography revealed findings suggestive of ventricular septal defect (VSD), right aortic arch (AA), left patent ductus arteriosus, and bilateral superior vena cava (SVC).
At 40 weeks and 4 days of gestation	The baby was born weighing 2662 g. Echocardiography led to a diagnosis of VSD, double aortic arch (DAA), coarctation of the left AA, and bilateral SVC.
At 16 days of age	Computed tomography (CT) revealed DAA with concurrent pulmonary artery sling (PAS) and anomalous branching of the trachea. The right A2, which is part of the right upper pulmonary artery, showed abnormal branching of the pulmonary artery from left pulmonary artery (LPA).
At 2 months of age	Cardiac catheterization revealed Qp/Qs of 2.5, mean pulmonary artery pressure of 27 mmHg, and pulmonary vascular resistance of 1.5 WU·m <sup>2</sup> . Repeat CT examination revealed that the angle between the main pulmonary artery and LPA had decreased.
At 3 months of age	Ventricular septal defect patching, left AA resection distal to the root of the left subclavian artery, arterial ligament dissection, and LPA replacement were performed.
At 1 year and 2 months of age	The patient has persistent inspiratory stridor when affected by a common cold; however, her progress is good with no achalasia.

## Case presentation

The patient was referred for treatment after polyhydramnios was detected on foetal ultrasound at 37 weeks and 4 days of gestation. Ultrasound also revealed duodenal obstruction and ventricular septal defect (VSD). Ultrasound at 37 weeks and 6 days of gestation were suggestive of VSD, right aortic arch (AA), left patent ductus arteriosus (PDA), and bilateral superior vena cava (SVC). The baby was born by normal delivery at 40 weeks and 4 days gestation. Her birth weight was 2662 g. Blood pressure was mmHg; heart rate was 110 b.p.m; respiratory rate was 40 per min, and SpO<sub>2</sub> was 97%. Clinical examination revealed that first heart sound and lung auscultation were normal. She didn't have cyanosis and wheezing. Ultrasound

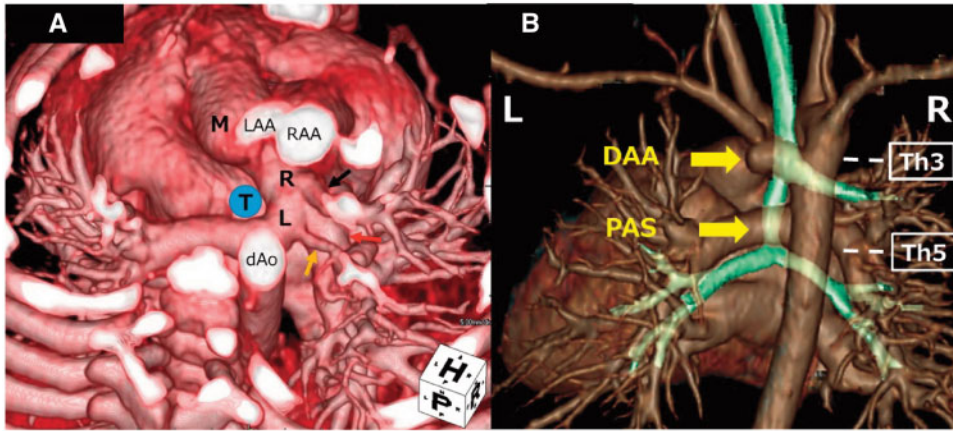


**Figure 1** Right dominant double aortic arch has formed. Coarctation of the left aortic arch is seen immediately after left subclavian artery bifurcation. Coa, coarctation; DAo, descending aorta; LCCA, left common carotid artery; LSCA, left subclavian artery; RCCA, right common carotid artery; R vertebral A, right vertebral artery; RSCA, right subclavian artery.

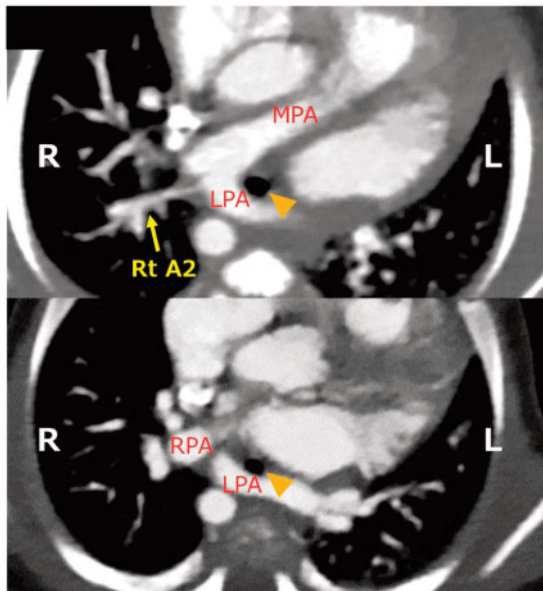
led to a diagnosis of VSD, DAA, coarctation of the left AA, and bilateral SVC. Surgery at 1 day of age corrected the duodenal obstruction. Contrast-enhanced computed tomography (CT) at 16 days of age confirmed DAA (Figure 1) with a concurrent PAS (Figure 2A) and anomalous Wells classification IB tracheal branching (Figure 2B). Furthermore, the right A2, which is part of the right upper pulmonary artery (RUPA), showed abnormal branching of the pulmonary artery from LPA (Figure 3). Oesophagram at 18 days of age revealed the defect in the posterior wall of oesophagus at the level of DAA and the defect in the anterior wall at the level of PAS.

The patient developed mild inspiratory stridor at 2 months of age. There were no feeding issues, vomiting, and recurrent respiratory infections. Cardiac catheterization revealed a Qp/Qs of 2.5, mean pulmonary artery pressure of 27 mmHg, and pulmonary vascular resistance of 1.5WU·m<sup>2</sup>. Repeat CT found that the angle between the main pulmonary artery (MPA) and LPA had decreased (Figure 4). The evaluation suggested that tracheal displacement resulting from increased pulmonary blood flow and enlargement of the pulmonary artery caused by VSD worsened the tracheal compression. VSD patching, left AA resection distal to the root of the left subclavian artery, arterial ligament dissection, and LPA replacement were performed at 3 months of age. LPA was detached from RPA and implanted into MPA with continuous sutures. She was treated by cardiopulmonary bypass through a median sternotomy. Postoperative extubation was followed by an uneventful recovery, and the patient's progress was good.

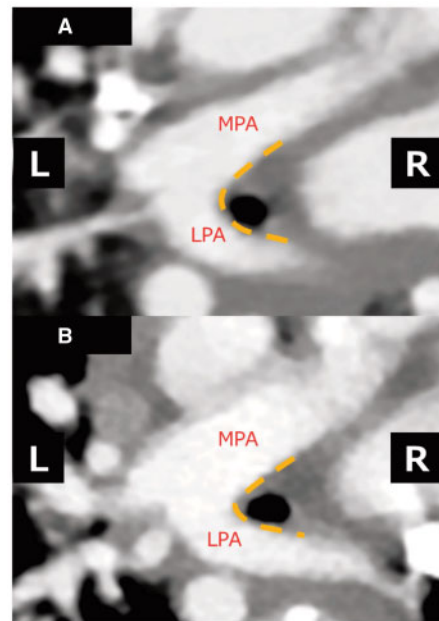
Repeat CT examination at 9 months of age, 6 months after surgery, found LPA stenosis and residual stenosis at the site of tracheal bifurcation (Figure 5). At 1 year and 2 months of age, the patient has persistent inspiratory stridor when she was affected by a common cold. Achalasia is absent, and her progress is good.



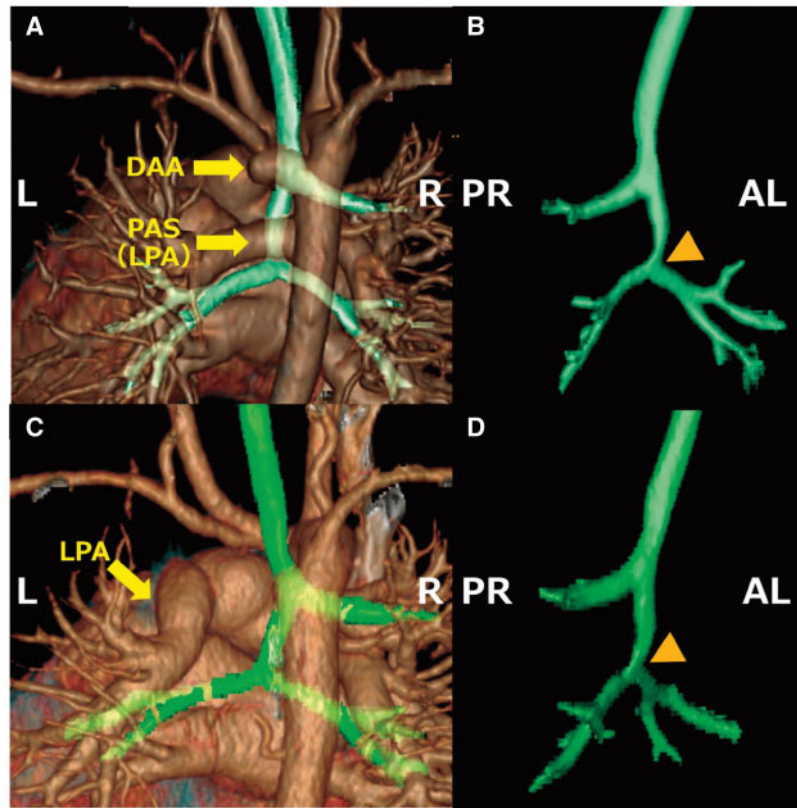
**Figure 2** (A) Left pulmonary artery originates from right pulmonary artery, forming pulmonary artery sling and surrounding the trachea. Right upper pulmonary artery supplying S1 + S3 (A1 + A3: black arrow) originates from right pulmonary artery, and right upper pulmonary artery supplying S2 (A2: yellow arrow) originates from left pulmonary artery. Right middle and lower pulmonary artery originate from right pulmonary artery (red arrow). (B) At the Th3 level, the right upper lobe bronchus branches alone. After the right upper lobe bronchus branches alone, the left and right bronchi branch and the trachea branching form takes on the shape of Wells classification Type IB. In the pulmonary artery sling area, the trachea is pressed by left pulmonary artery immediately above the tracheal bifurcation. DAA, double aortic arch; dAo, descending aorta; L, left pulmonary artery; LAA, left aortic arch; M, main pulmonary artery; PAS, pulmonary artery sling; R, right pulmonary artery; RAA, right aortic arch; T, trachea.



**Figure 3** Left pulmonary artery runs posterior to the trachea (arrowhead), and forms pulmonary artery sling. The right A2 supplying the posterior segment of the right lung (S2) shows abnormal branching of the pulmonary artery from left pulmonary artery. LPA, left pulmonary artery; MPA, main pulmonary artery; RPA, right pulmonary artery.



**Figure 4** (A) Computed tomography at 16 days of age. (B) Computed tomography at 2 months of age revealed that the angle between main pulmonary artery and left pulmonary artery had decreased compared with that at 16 days of age. Tracheal displacement resulting from increased pulmonary blood flow and enlargement of the pulmonary artery caused by ventricular septal defect may have worsened the tracheal compression. LPA, left pulmonary artery; MPA, main pulmonary artery.



**Figure 5** (A) Preoperative computed tomography (at 16 days of age). (B) Preoperative computed tomography revealed anteroposterior oppression of the tracheal bifurcation (arrowhead) caused by pulmonary artery sling. (C and D) Computed tomography at 6 months postoperatively (at 9 months of age) revealed left pulmonary artery stenosis and residual stenosis at the site of tracheal bifurcation. DAA, double aortic arch; LPA, left pulmonary artery; PAS, pulmonary artery sling.

## Discussion

A DAA forms a vascular ring when either the left and right fourth pharyngeal arcuate arteries originating from the aorta, or the eighth segment of the dorsal aorta, do not regress. DAAs account for about 42% of vascular rings<sup>1</sup> and present in neonates and infants with respiratory symptoms, including stridor and respiratory distress, and dysphagia. The right AA is dominant in 80% of cases, the left AA is dominant in 10%, and the contribution is balanced in 10%.<sup>2</sup> As the diagnostic modalities for vascular rings, Backer et al.<sup>1</sup> prefer CT imaging to magnetic resonance imaging (MRI). CT imaging gives clearer picture of the tracheal anatomy and requires a shorter period to obtain than MRI. And they recommend an ultrasound in all patients with a vascular ring because there is a 12% incidence of associated cardiac pathology.<sup>2</sup> Surgical repair is associated with no mortality in patients with DAA and 0-1.3% of these patients required reoperation.<sup>1,3</sup>

A PAS develops when the LPA vascular bud forms between the oesophagus and trachea, originating from the RPA instead of the MPA anterior to the trachea.<sup>1</sup> The LPA branches from the RPA and runs posterior to the trachea, thereby causing tracheal displacement. PAS accounts for 12% of vascular rings<sup>1</sup> and presents in neonates and infants with symptoms such as stridor

and respiratory distress. Postoperative mortality in patients with PAS is 12-21% and 0-12% of these patients required reoperation.<sup>4-6</sup>

Wells et al.<sup>7</sup> described four types of PAS (IA, IB, IIA, and IIB) depending on the level of tracheal bifurcation. Our patient had a Type IB PAS with a right upper lobe bronchus and tracheal bifurcation between the fourth to fifth thoracic vertebrae. This type of PAS is seen in 13% of cases.<sup>8</sup> In this patient, we also observed abnormal branching of RPA from the right A2, which is a part of the RUPA, which originates from LPA. A retrospective evaluation of a series of PAS patients by Xie et al.<sup>8</sup> found that the RUPA portion originated from the LPA in 10% of the Type IB cases. Consequently, we consider our case to be a rare type of PAS.

The coexistence of a PAS, right AA, and aberrant left subclavian artery in cases with two overlapping, or double vascular rings, has been previously reported.<sup>9</sup> There are no previous reports of patients with concurrent DAA and PAS as seen in our patient. Although this condition has a very high risk of tracheal stenosis, this patient presented with relatively mild symptoms, which was attributed to the presence of a Type IB PAS. However, the angle of MPA and LPA decreased, raising concerns that an increase in the pulmonary blood flow would worsen the tracheal displacement. In such cases, radical surgery for VSD in early infancy is likely to be effective.



## Conclusions

To our knowledge, this is the first report of a vascular ring with concurrent DAA and PAS. In this patient, it was inferred that the coexistence of the two conditions carried a high risk of tracheal stenosis. Surgical intervention was performed early and resulted in a good outcome with no complications such as significant respiratory symptoms or dysphagia.

## Supplementary material

[Supplementary material](#) is available at *European Heart Journal - Case Reports* online.

**Slide sets:** A fully edited slide set detailing this case and suitable for local presentation is available online as [Supplementary data](#).

**Consent:** The author/s confirm that written consent for submission and publication of this case report including image(s) and associated text has been obtained from the patient in line with COPE guidance.

**Conflict of interest:** none declared.

## References

1. Backer CL, Mongé MC, Popescu AR, Eltayeb OM, Rastatter JC, Rigsby CK. Vascular rings. *Semin Pediatr Surg* 2016;**25**:165–175.
2. Backer CL, Mavroudis C, Rigsby CK, Holinger LD. Trends in vascular ring surgery. *J Thorac Cardiovasc Surg* 2005;**129**:1339–1347.
3. Ruzmetov M, Vijay P, Rodefeld MD, Turrentine MW, Brown JW. Follow-up of surgical correction of aortic arch anomalies causing tracheoesophageal compression: a 38-year single institution experience. *J Pediatr Surg* 2009;**44**:1328–1332.
4. Fiore AC, Brown JW, Weber TR, Turrentine MW. Surgical treatment of pulmonary artery sling and tracheal stenosis. *Ann Thorac Surg* 2005;**79**:38–46.
5. Oshima Y, Yamaguchi M, Yoshimura N, Sato S, Muraji T, Nishijima E, Tsugawa C. Management of pulmonary artery sling associated with tracheal stenosis. *Ann Thorac Surg* 2008;**86**:1334–1338.
6. Backer CL, Russell HM, Kaushal S, Rastatter JC, Rigsby CK, Holinger LD. Pulmonary artery sling: current results with cardiopulmonary bypass. *J Thorac Cardiovasc Surg* 2012;**143**:144–151.
7. Wells TR, Gwinn JL, Landing BH, Stanley P. Reconsideration of the anatomy of sling left pulmonary artery: the association of one form with bridging bronchus and imperforate anus. Anatomic and diagnostic aspects. *J Pediatr Surg* 1988;**23**:892–898.
8. Xie J, Juan YH, Wang Q, Chen J, Zhuang J, Xie Z. Evaluation of left pulmonary artery sling, associated cardiovascular anomalies, and surgical outcomes using cardiovascular computed tomography angiography. *Sci Rep* 2017;**7**:40042.
9. Lee JW, Printz BF, Hegde SR, Vargas LA, Sun HY. Double trouble: fetal diagnosis of a pulmonary artery sling and vascular ring. *Clin Case Rep* 2016;**4**:1187–1190.