

# Neonatal lethal hypophosphatasia

## A case report and review of literature

Laura Castells, MD<sup>a,\*</sup>, Pía Cassanello, MD<sup>a</sup>, Felix Muñoz, MD<sup>a</sup>, María-José de Castro, MD<sup>b</sup>,  
María L. Couce, MD, PhD<sup>b,\*</sup>

### Abstract

**Rationale:** Hypophosphatasia (HPP) is a very rare metabolic bone disease caused by loss-of-function mutations in the *ALPL* gene encoding the tissue nonspecific alkaline phosphatase. The severe neonatal form is considered lethal but insights into manifestations of the disease can help to increase our knowledge of the natural history for an early initiation of treatment and improvement of survival.

**Patient concerns:** We report the case of a newborn in which his fetal imaging showed findings of skeletal dysplasia disorder, considering initially achondroplasia as a potential diagnosis.

**Diagnosis:** A definitive diagnosis compatible with perinatal lethal HPP was established in the 1st days due to the presentation at birth with thoracic and pulmonary hypoplasia, bone hypomineralization, and undetectable alkaline phosphatase. The genetic analysis identified a new heterozygous c.413G>C mutation and another 1 c.473-2G>C previously described in the *ALPL* gene.

**Outcomes:** The patient died on the 4th day by clinical course complicated without having started enzyme replacement therapy (ERT). Retrospectively, previous analyzes of the parents already showed both a decreased alkaline phosphatase.

**Lessons:** This report highlights the importance of prenatal differential diagnosis of bone dysplasia with the key biochemical marker of alkaline phosphatase in the parents. Substitutive ERT administered very soon after birth, seems to change the prognosis in these patients with neonatal HPP.

**Abbreviations:** ALP = alkaline phosphatase, ERT = enzyme replacement therapy, HPP = hypophosphatasia, PLP = pyridoxal 5'-phosphate, TNSALP = tissue nonspecific alkaline phosphatase.

**Keywords:** alkaline phosphatase, asfotase alfa, respiratory failure, rickets

### 1. Introduction

Hypophosphatasia (HPP) is an inherited “ultra-rare” disease of the bone and mineral metabolism, due to a low activity of the tissue nonspecific isoenzyme of alkaline phosphatase (TNSALP). This enzyme is encoded by *ALPL* gene (1p36.12; MIM 171760), more than 315 different mutations were identified worldwide.<sup>[1]</sup> TNSALP hydrolyzes pyrophosphate phosphodiesterase yielding inorganic phosphate, thereby promoting hydroxyapatite formation. In the brain, TNSALP hydrolyzes the phosphorylated version of pyridoxine, allowing this vitamin to cross the blood-brain barrier.<sup>[2]</sup>

Editor: N/A.

The study was supported by the Fundación IDIS-C012.

The authors have no conflicts of interest to disclose.

<sup>a</sup> Neonatal and Perinatal Unit, Hospital Universitari General de Catalunya Quirónsalud, Sant Cugat del Vallès, Barcelona, <sup>b</sup> Neonatal Service, Metabolic Unit, Department of Pediatrics, Santiago de Compostela University Hospital, IDIS (Health Research Institute of Santiago de Compostela), Ciberer, Spain.

\* Correspondence: María L. Couce, and Laura Castells, Head of Neonatal and Perinatal Unit. Santiago de Compostela University Hospital and Hospital Universitari General de Catalunya, Carrer Pedro i Pons 1, 08190 Sant Cugat del Vallès, Barcelona, Spain (e-mails: maria.luz.couce.pico@sergas.es, lcastells@quironsalud.es).

Copyright © 2018 the Author(s). Published by Wolters Kluwer Health, Inc. This is an open access article distributed under the terms of the Creative Commons Attribution-Non Commercial-No Derivatives License 4.0 (CCBY-NC-ND), where it is permissible to download and share the work provided it is properly cited. The work cannot be changed in any way or used commercially without permission from the journal.

Medicine (2018) 97:48(e13269)

Received: 1 August 2018 / Accepted: 23 October 2018

<http://dx.doi.org/10.1097/MD.0000000000013269>

Neonatal lethal HPP is the most severe form of the disease, with estimated prevalence at 1:300,000 in Europe and 1:182,000 in Japan.<sup>[3,4]</sup> It is radiographically visible in the fetal period as bowed and shorter long bones, low or no skeletal mineralization, and more specific signs such as osteochondral spurs and pretibial dimpling.<sup>[4]</sup> Newborns at birth present respiratory distress due to chest deformities and lung hypoplasia; skeletal alterations with generalized lack of ossification, *caput membranaceum*, short and arched limbs, cup-shaped and “moth-eaten” metaphysis, bone spicules and spontaneous fractures, small rib cage with thin ribs; and vitamin B<sub>6</sub>-dependent epileptic seizures. A pseudo-metabolic alteration can be present: hypercalcemia and hyperphosphatemia and can be complicated by early nephrocalcinosis. A conjunctival bluish color may be observed, enabling differential diagnosis and ruling out osteogenesis imperfecta.<sup>[4–6]</sup> The key biochemical marker is markedly decreased serum alkaline phosphatase (ALP).

Until very recently, severe perinatal HPP was lethal at birth or in the 1st months of life. The treatment with a recombinant enzyme replacement therapy (ERT), asfotase alfa, had substantially improved bone mineralization, survival, and ventilation-free survival, although few cases are known.<sup>[7,8]</sup> According to a PubMed search, just 71 cases of neonatal HPP have been published<sup>[7–28]</sup> since the 1st case was characterized in 1948 by Campbell. Twelve of them received ERT, out of which 10 survived (Table 1) with an average evolution time of 13 months (range from 1 month to 5 years). All the others, except one that his family wanted to go home after 4 days of life,<sup>[16]</sup> were mostly exitus during the 1st month of life. The case presented here is a newborn affected by severe HPP with complicated management. For publishing, informed consent was obtained by the parents and no other ethical accuracies were necessary.

**Table 1****Characteristics and outcome of published hypophosphatasia neonatal cases treated with enzyme replacement therapy.**

Author	Year	Prenatally suspected	Sex	Serum ALP IU/L	TNSALP genotype	Survival	Respiratory support at birth (Y/N)	Radiographic changes after treatment*
Whyte et al <sup>[7]</sup>	2012	-	F	19	c.98C>T/c.98C>T	5 y	Y	Y
Whyte et al <sup>[7]</sup>	2012	Y	M	21	c.119C>T/c.1231A>G	7 mo	Y	Y
Whyte et al <sup>[7]</sup>	2012	-	M	20	c.215T>C/c.881A>C	19 mo	Y	Y
Whyte et al <sup>[7]</sup>	2012	Y	F	6	c.920C>T/c.1171C>T	1 y	Y	Y
Okazaki et al <sup>[25]</sup>	2016	Y	F	2	c.1471G>A/c.1471G>A	18 mo	Y	Y
Costain et al <sup>[27]</sup>	2017	Y	F	Und.	c.1171C>T/c.1348C>T	Exitus 3 mo	Y	-
Kitaoka et al <sup>[28]</sup>	2017	-	M	23	c.1559delT/c.1559delT	84 wk	Y	Y
Kitaoka et al <sup>[28]</sup>	2017	-	F	Und.	c.1559delT/c.1559delT	4 wk	Y	Y
Kitaoka et al <sup>[28]</sup>	2017	-	F	1	c.1471 G>A/c.1471 G>A	120 wk	Y	Y
Kitaoka et al <sup>[28]</sup>	2017	-	F	15	c.1559delT/c.1559delT	24 wk	Y	Y
Kitaoka et al <sup>[28]</sup>	2017	-	F	23	c.1559delT/c.1559delT	12 wk	Y	Y
Kitaoka et al <sup>[28]</sup>	2017	-	F	39	c.1478 C>T/c.1559delT	72 wk	Y	Y

Survival is at time of last visit reflected in each publication.

ALP = alkaline phosphatase, F = female, M = male, TNSALP = tissue nonspecific alkaline phosphatase, Und = undetectable, Y = yes.

\* Radiographic changes are shown in terms of increased mineralization and they were significant in all the cases reported treated with enzyme replacement therapy.

## 2. Case report

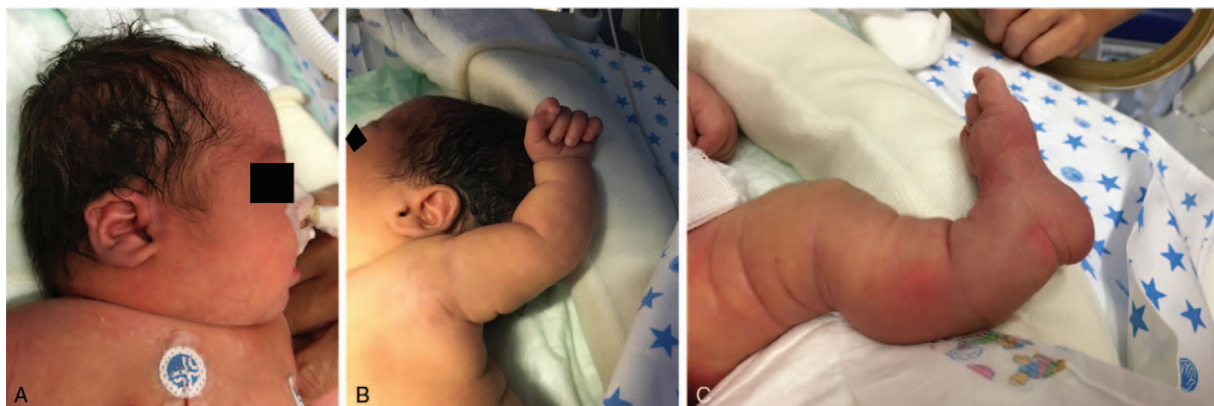A male infant was born by cesarean section due to antenatal history of short long bone at 37 weeks of gestation. This was the 5th pregnancy of the mother, aged 35 years, with a healthy daughter from a previous partner and 3 previous abortions with the current partner. There was no history of consanguinity. The antenatal ultrasound at 29 weeks of gestation had shown a fetus with short long bones and generalized hypomineralization suggestive of skeletal dysplasia disorder, considering initially achondroplasia as a potential diagnosis. The parents chose not to undertake any further genetic or invasive test other than gestational ultrasound follow-up.

The birth weight was 2850 g, head circumference 34 cm (both 50th percentile) whereas his length was 42 cm (10th percentile). The Apgar score was 3 at 1 minute and 5 at 5 minutes after birth. He required intubation and mechanical ventilation immediately upon birth due to severe respiratory insufficiency, and showed generalized hypotonia and hypoactivity; however, he was responsive to stimulus and with spontaneous eye opening. On his physical examination was found to have shortened and bowed arms and legs, *caput membranaceum*, widely open fontanelles, short neck, poor muscle tone, and loose joints. Heart

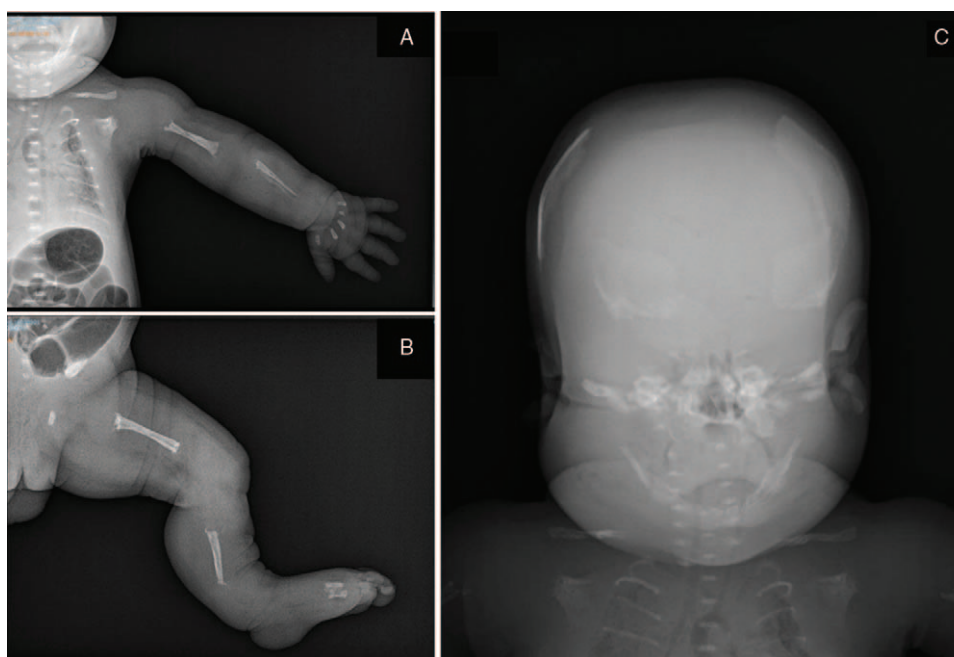
auscultation showed a multifocal systolic murmur II/VI. The external genitalia showed bilateral hydrocele (Fig. 1).

An initial chest X-ray showed thoracic and pulmonary hypoplasia with thin rib bone cortices. Based upon physical examination, prenatal ultrasound and present X-rays, search for hypomineralization defects was initiated. Biochemical analysis showed hypercalcemia (calcium: 11.2 mg/dL) and undetectable serum ALP levels. Urine analysis showed hypercalciuria with increased calcium creatinine ratio (>0.7). Blood count as well as liver function was normal. Further whole-body X-ray was undertaken, showing generalized severe hypomineralization (Fig. 2).

Based on clinical data, the suspected diagnosis was severe perinatal HPP. The data were confirmed by biochemical determination of plasma pyridoxal 5'-phosphate (PLP) levels (>200 nmol/L; normal reference range 23–172 nmol/L) and phosphoethanolamine levels in urine (7567 μmol/g, normal reference below 150 μmol/g). With these data, on the 3rd day treatment with ERT asfotase alfa (approved by EMA in 2015) was indicated obtaining parental informed consent. However, some hours later, the patient died of severe respiratory insufficiency secondary to thoracic hypoplasia.



**Figure 1.** (A) Extreme short neck is showed. (B, C) Pictures of the neonate showing profound deformities and accordion-like skinfolds, explained by no underlying bone mineralization.



**Figure 2.** (A, B) Radiographic features. Skeletal mineralization is nearly absent in this neonate. Pathognomonic metaphyseal “tongues” of radiolucency, gracile ribs, and long-bone deformities are apparent. (C) Almost no mineralization of the cranial skeleton.

Genetic analysis confirmed 2 heterozygous *c.473-2G>C/c.413G>C* (*p.Arg138Pro*) mutations in the *ALPL* gene. The parent DNA identified both of them heterozygous carrier.

### 3. Discussion

We have presented a new case of neonatal lethal HPP with 2 heterozygous *c.473-2G>C/c.413G>C* mutations in the *ALPL* gene. His inheritance pattern was autosomal recessive, like as in severe forms of HPP.<sup>[11]</sup> In the prenatal period, the findings of bone alteration show considerable overlap with other skeletal dysplasia such as achondrogenesis in our case, similar to what is described in the literature, especially with osteogenesis imperfecta types IIA and IIC, and achondrogenesis type IA.<sup>[29]</sup> If present, “spurs” of the limbs and pretibial dimpling are diagnostic for HPP.<sup>[4,29]</sup> In addition, it is also interesting to keep in mind that parental low serum ALP levels of the pregestation and gestation also contributes to the diagnosis of suspicion.<sup>[30]</sup> During the gestation, serum ALP levels increase during the 2nd half of pregnancy at the expense of placental production of ALP, and to a lesser degree, in the production of bone ALP.<sup>[31]</sup> ALP levels of the mother and father were 26 and 32 U/L, respectively (normal range 35–110 IU/L), in the present case.

At birth, skeletal abnormalities, respiratory distress with pulmonary hypoplasia, hypercalcemia established initial suspicion of bone dysplasia. Neurologic signs with epileptic encephalopathy or hemorrhage were not present undetectable PLP in 2 determinations strongly suspected the diagnosis of HPP at 48 hours. In the literature, all the cases published with neonatal lethal HPP have low PLP levels and a correlation between the severity of the disease and the serum PLP level has been reported.<sup>[32]</sup> However, it is important to reflect that in the first 48 hours PLP concentrations may be those of the mother and may not yet be significantly low. Later results confirmed elevated

serum PLP concentration, which represents a sensitive and specific biochemical marker for HPP, elevated phosphoethanolamine levels are also elevated in serum and urine, although less specific.<sup>[33]</sup> Both are substrates of TNSALP that accumulate endogenously in HPP. Genetic study revealed a known pathogenic mutation and a new mutation *c.413G>C* (*p.Arg138Pro*) in exon 5 of the gene, not described in the database [http://www.sesep.uvsq.fr/03\\_hypo\\_mutations.ph](http://www.sesep.uvsq.fr/03_hypo_mutations.ph). Bioinformatic analyzes with SIFT and polyphen 2 algorithms predict harmful and possibly harmful behavior, respectively, for the structure and/or function of the protein.

Before treatment with ERT, no patient reported survived more than 1 year and most died in the 1st days of life, the main cause was respiratory failure and in some cases epileptic encephalopathy.<sup>[13,23]</sup> However, 83.3% of ERT reported cases survived and substantially improved its clinical evolution. Our case died on the 4th day of life without having begun receiving ERT treatment. The HPP in the differential diagnosis was not considered in the pregnancy and the determinations of alkaline phosphatases in the parents were not assessed. This would have facilitated early availability of enzymatic treatment.

In conclusion, earlier diagnosis of perinatal HPP with prenatal recognition and starting ERT as soon as possible after birth may improve outcomes and might have a positive impact on to survival. It is therefore necessary to establish a consensus of recommendations.

### Author contributions

**Conceptualization:** Laura Castells.

**Formal analysis:** Laura Castells, Pía Cassanello.

**Methodology:** Laura Castells, Pía Cassanello, José Félix Muñiz.

**Supervision:** María-Luz Couce.

**Writing – original draft:** Laura Castells, María José De Castro.

**Writing – review & editing:** María-Luz Couce.

## References

- [1] Mornet E. Genetics of hypophosphatasia. *Arch Pediatr* 2017;24:S51–56.
- [2] Orimo H. Pathophysiology of hypophosphatasia and the potential role of asfotase alfa. *Ther Clin Risk Manag* 2016;12:777–86.
- [3] Mornet E, Yvard A, Taillandier A, et al. A molecular-based estimation of the prevalence of hypophosphatasia in the European population. *Ann Hum Genet* 2011;75:439–45.
- [4] Mornet E. Hypophosphatasia. *Metabolism* 2018;82:142–55.
- [5] Baujat G, Michot C, Le Quan Sang KH, et al. Perinatal and infantile hypophosphatasia: clinical features and treatment. *Arch Pediatr* 2017;24:S61–5.
- [6] Martos-Moreno GA, Calzada J, Couce ML, et al. Hypophosphatasia: Clinical manifestations, diagnostic recommendations and therapeutic options. *An Pediatr (Barc)* 2018;88:356e1–1.
- [7] Whyte MP, Greenberg CR, Salman NJ, et al. Enzyme-replacement therapy in life-threatening hypophosphatasia. *N Engl J Med* 2012;366:904–13.
- [8] Whyte MP, Rockman-Greenberg C, Ozono K, et al. Asfotase alfa treatment improves survival for perinatal and infantile hypophosphatasia. *J Clin Endocrinol Metab* 2016;101:334–42.
- [9] Weiss MJ, Cole DE, Ray K, et al. A missense mutation in the human liver/bone/kidney alkaline phosphatase gene causing a lethal form of hypophosphatasia. *Proc Natl Acad Sci U S A* 1988;85:7666–9.
- [10] Shohat M, Rimoin DL, Gruber HE, et al. Perinatal lethal hypophosphatasia; clinical, radiologic and morphologic findings. *Pediatr Radiol* 1991;21:421–7.
- [11] Lorda Sánchez I, Urioste Azcorra M, Martínez Santana S, et al. Perinatal congenital hypophosphatasia: a report of 3 cases, its prevalence in Spain and reflexions on its mode of inheritance [in Spanish]. *An Esp Pediatr* 1996;44:601–4.
- [12] Gehring B, Mornet E, Plath H, et al. Perinatal hypophosphatasia: diagnosis and detection of heterozygote carriers within the family. *Clin Genet* 1999;56:313–7.
- [13] Litmanovitz I, Reish O, Dolfin T, et al. Glu274Lys/Gly309Arg mutation of the tissue-nonspecific alkaline phosphatase gene in neonatal hypophosphatasia associated with convulsions. *J Inherit Metab Dis* 2002;25:35–40.
- [14] Sawai H, Kanazawa N, Tsukahara Y, et al. Severe perinatal hypophosphatasia due to homozygous deletion of T at nucleotide 1559 in the tissue nonspecific alkaline phosphatase gene. *Prenat Diagn* 2003;23:743–6.
- [15] Smilari P, Romeo DM, Palazzo P, et al. Neonatal hypophosphatasia and seizures. A case report. *Minerva Pediatr* 2005;57:319–23.
- [16] Kritsaneepaiboon S, Jaruratanasirikul S, Dissaneevate S. Clinics in diagnostic imaging (112). Perinatal lethal hypophosphatasia (PLH). *Singapore Med J* 2006;47:987–92.
- [17] Brun-Heath I, Chabrol E, Fox M, et al. A case of lethal hypophosphatasia providing new insights into the perinatal benign form of hypophosphatasia and expression of the ALPL gene. *Clin Genet* 2008;73:245–50.
- [18] Balasubramaniam S, Bowling F, Carpenter K, et al. Perinatal hypophosphatasia presenting as neonatal epileptic encephalopathy with abnormal neurotransmitter metabolism secondary to reduced co-factor pyridoxal-5'-phosphate availability. *J Inherit Metab Dis* 2010;33:S25–33.
- [19] Nakamura-Utsunomiya A, Okada S, Hara K, et al. Clinical characteristics of perinatal lethal hypophosphatasia: a report of 6 cases. *Clin Pediatr Endocrinol* 2010;19:7–13.
- [20] Chang KC, Lin PH, Su YN, et al. Novel heterozygous tissue-nonspecific alkaline phosphatase (TNAP) gene mutations causing lethal perinatal hypophosphatasia. *J Bone Miner Metab* 2012;30:109–13.
- [21] Rodriguez E, Bober MB, Davey L, et al. Respiratory mechanics in an infant with perinatal lethal hypophosphatasia treated with human recombinant enzyme replacement therapy. *Pediatr Pulmonol* 2012;47:917–22.
- [22] Leung EC, Mhanni AA, Reed M, et al. Outcome of perinatal hypophosphatasia in manitoba mennonites: a retrospective cohort analysis. *JIMD Rep* 2013;11:73–8.
- [23] Hofmann C, Liese J, Schwarz T, et al. Compound heterozygosity of two functional null mutations in the ALPL gene associated with deleterious neurological outcome in an infant with hypophosphatasia. *Bone* 2013;55:150–7.
- [24] Taketani T, Onigata K, Kobayashi H, et al. Clinical and genetic aspects of hypophosphatasia in Japanese patients. *Arch Dis Child* 2014;99:211–5.
- [25] Okazaki Y, Kitajima H, Mochizuki N, et al. Lethal hypophosphatasia successfully treated with enzyme replacement from day 1 after birth. *Eur J Pediatr* 2016;175:433–7.
- [26] Sağlam H, Erdöl Ş, Dorum S. Clinical and genetic findings of Turkish hypophosphatasia cases. *J Clin Res Pediatr Endocrinol* 2017;9:229–36.
- [27] Costain G, Moore AM, Munroe L, et al. Enzyme replacement therapy in perinatal hypophosphatasia: case report of a negative outcome and lessons for clinical practice. *Mol Genet Metab Rep* 2017;14:22–6.
- [28] Kitaoka T, Tajima T, Nagasaki K, et al. Safety and efficacy of treatment with asfotase alfa in patients with hypophosphatasia: Results from a Japanese clinical trial. *Clin Endocrinol (Oxf)* 2017;87:10–9.
- [29] Zankl A, Mornet E, Wong S. Specific ultrasonographic features of perinatal lethal hypophosphatasia. *Am J Med Genet A* 2008;146A:1200–4.
- [30] Takahashi Y, Sawai H, Murotsuki J, et al. Parental serum alkaline phosphatase activity as an auxiliary tool for prenatal diagnosis of hypophosphatasia. *Prenat Diagn* 2017;37:491–6.
- [31] Whyte MP, Landt M, Ryan LM, et al. Alkaline phosphatase: placental and tissue-nonspecific isoenzymes hydrolyze phosphoethanolamine, inorganic pyrophosphate, and pyridoxal 5'-phosphate. Substrate accumulation in carriers of hypophosphatasia corrects during pregnancy. *J Clin Invest* 1995;95:1440–5.
- [32] Whyte MP, Whyte MP. Hypophosphatasia and the role of alkaline phosphatase in skeletal mineralization. *Endocr Rev* 1994;15:439–61.
- [33] Gennero I, Conte-Auriol F, Salles JP. Laboratory diagnosis of hypophosphatasia. *Arch Pediatr* 2017;24:5S57–60.