

Trichobezoar without a clear manifestation of trichotillomania

Akhilesh Jain¹, Aditi Agrawal¹, Anil K. Tripathi², Roovendra K. Bansod²,
Garima Jain², Kuldeep S. Yadav¹

Departments of ¹Psychiatry and ²Surgery, ESIC Model Hospital, Jaipur, Rajasthan, India

ABSTRACT

Trichophagia is a compulsive condition characterized by eating hair, mostly seen in adolescent females. Persistence of ingestion of hair over many years results in the formation of trichobezoar. Surgical intervention is often needed in the management of large trichobezoars. We present a case of a 23 year old female with trichophagia which led to the formation of gastric trichobezoar. The patient reported with complaints of pain in abdomen for past 1-2 years, and loss of appetite and vomiting post meals for 6 months. On detailed examination, a diagnosis of trichobezoar was formed which was removed by laparotomy with gastrotomy under general anaesthesia. Psychiatric evaluation revealed a history of fluctuating mood symptoms during her childhood and depressive symptomatology presently without any associated urge of plucking hair and subsequent gratification. Hence, the management of the disease requires proper liaison between the surgeon, psychiatrist, and caregivers of the patient; and regular psychiatric follow-up and treatment of the underlying psychopathology to prevent the recurrent formation of bezoar.

Keywords: Depression, trichobezoar, trichophagia

Introduction

Trichophagia is a compulsive condition characterized by eating hair. It is most commonly seen in adolescent females.^[1] The condition is usually associated with underlying psychiatric symptomatology, such as trichotillomania (impulsive hair-pulling), anxiety, depressive disorder, obsessive-compulsive disorder, pica, and anorexia nervosa.^[2]

Persistence of ingestion of hair over many years results in the formation of trichobezoar, a hair ball in stomach. It is a rare cause of gastric obstruction accounting for around 1% of all the individuals with trichophagia.^[3] Human hair resists

digestion and propulsion by gastric peristalsis due to its smooth surface. Hence, it accumulates together with mucus and food within the mucosal folds of stomach, forming a trichobezoar.^[4] It may not be recognized in early stages because of its nonspecific presentation and may extend into the intestine over time, which is known as Rapunzel Syndrome.^[5]

Trichophagia associated with trichotillomania results in lowered self-esteem, reduced quality of life and impaired social functioning of the individual.^[6] Surgical intervention is often needed in the management of large trichobezoars.^[7] If adequate psychiatric intervention and support are not provided to the patient after the surgical treatment, probability of recurrence of trichobezoar are increased.

Here, we report a case of a 23 year old female with trichophagia which led to the formation of gastric trichobezoar.

Address for correspondence: Dr. Anil K. Tripathi,
Department of Surgery, ESIC Model Hospital, Ajmer Road, Jaipur,
Rajasthan -302 001, India.
E-mail: dr.anil.tripathi@esic.nic.in

Received: 02-01-2020

Revised: 11-03-2020

Accepted: 23-03-2020

Published: 31-05-2020

Access this article online

Quick Response Code:



Website:
www.jfmprc.com

DOI:
10.4103/jfmprc.jfmprc_11_20

This is an open access journal, and articles are distributed under the terms of the Creative Commons Attribution-NonCommercial-ShareAlike 4.0 License, which allows others to remix, tweak, and build upon the work non-commercially, as long as appropriate credit is given and the new creations are licensed under the identical terms.

For reprints contact: WKHLRPMedknow_reprints@wolterskluwer.com

How to cite this article: Jain A, Agrawal A, Tripathi AK, Bansod RK, Jain G, Yadav KS. Trichobezoar without a clear manifestation of trichotillomania. J Family Med Prim Care 2020;9:2566-8.

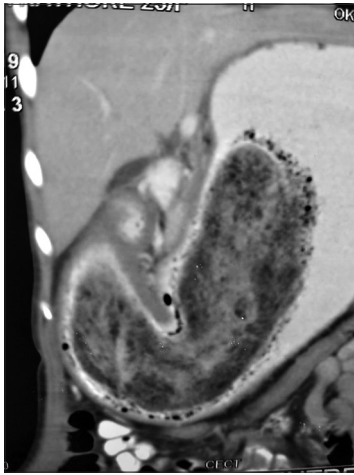


Figure 1: CAT scan image of trichobezoar

Case Presentation

A 23 year old married female presented in the surgical OPD with complaint of pain in abdomen for past 1–2 years, and loss of appetite and vomiting post meals for 6 months. On observation, the patient had thin built and appeared pale with body mass index (BMI) of 13.3 kg/m². On clinical examination, she was found to have a 7 × 3 inches large lump in the epigastric region which was freely mobile. Recent blood investigations revealed Hemoglobin to be 11.6 gm/dL with no electrolyte abnormalities. USG epigastrium revealed a well-defined mixed echogenic mass lesion predominantly hyperechoic in echotexture of size ~ 65 × 75 mm. A contrast enhanced CT scan of whole abdomen was performed which revealed over-distended stomach and large heterogeneous intraluminal mass with mottled appearance and small air pockets. Smooth wall thickening of stomach was also seen. A contrast enhanced CT scan of whole abdomen was performed which revealed over-distended stomach and large heterogeneous intraluminal mass with mottled appearance and small air pockets. Smooth wall thickening of stomach was also seen [Figure 1]. On interviewing, her mother mentioned about patient's habit of eating her hair since the age of 3 years. Hence, a diagnosis of trichobezoar was formed and patient was taken for surgical treatment. Laparotomy with gastrotomy and removal of trichobezoar under general anaesthesia was performed. Laparotomy with gastrotomy and removal of trichobezoar under general anaesthesia was performed. [Figure 2]. Postoperatively, patient was sent for psychiatric consultation.

On psychiatric evaluation, patient reported history of eating hair since childhood. She would keep hair in mouth when stressed but would not realize that she was swallowing the hair too. Parents made her aware about her hair eating behavior when she was around 6 years old. This behavior would increase whenever she was scolded or had an argument with her family. She also provided history of fainting always following stress without any associated injury, tongue bite or urinary incontinence; weakness and; off and on mood symptoms



Figure 2: Removed trichobezoar

during childhood. Temporal lobe epilepsy was also ruled out. Childhood history points towards her being stubborn and short-tempered. However, no such symptoms were reported currently. Physical examination showed no bald patches on scalp suggestive of hair pulling.

The patient remembered her family environment during childhood as hostile. She remembered her father returning drunk from work and beating up her mother. She experiences similar behavior in her married life too; her husband and in-laws being unsupportive and criticizing her on small issues. Currently, the patient complained of sad mood, low interest in pleasurable activities, sleep disturbances, excessive worry for almost more than 6 months which has gradually been worse over a period of time, and during interview she was found to have depressed mood and affect with depressive cognition. A diagnosis of moderate depression was considered under psychiatry. She was prescribed fluoxetine 20 mg and low dose of clonazepam and was informed about her illness. She was counselled for developing healthy coping skills to deal with the stressful situations. Family members were advised to remain observant of her hair eating or any other unhealthy behavior.

Discussion

Trichophagia and trichobezoar are extensively reported in surgical and medical literature,^[1,4,5,7] whereas, only few cases are found in psychiatric literature.^[8,9] Trichophagia is usually associated with many psychiatric disorders, such as anxiety and depressive disorders, obsessive-compulsive neurosis, pica, body dysmorphic disorder, anorexia nervosa, and especially trichotillomania.^[2] Evidence suggests that ~ 10–20% of the individuals with trichotillomania have concurrent trichophagia.^[10] However, few cases have also been reported presenting trichophagia and trichobezoar without the evidence of trichotillomania.^[8,9]

Since evaluation of patient's history did not reveal the characteristic symptoms suggestive of trichotillomania, the

diagnosis trichotillomania could not be established. Hence, the patient's hair eating could be explained as a result of ongoing stress and poor coping skills. This finding was further strengthened by her repeated manifestation of conversion symptoms during childhood and adolescence.

Most patients remain asymptomatic during the initial stages of the disorder. Symptoms manifest as the trichobezoar increases in size. Common complaints include abdominal pain, vomiting, anorexia, weight loss, and other signs of gastrointestinal obstruction.^[1]

The patient described here also had a vague clinical presentation who never recognized herself eating hair. She described a history of fluctuating mood symptoms during her childhood and depressive symptomatology presently. In addition, the family never paid attention to her mental status. Thus, the diagnosis of trichophagia and trichobezoar could not be formed during early stages. Hence, a detailed psychiatric and physical examination should be done focusing on signs and symptoms of trichophagia.

If timely diagnosis and management of a trichobezoar is not done, it may lead to various complications, such as gastric ulceration, obstructive jaundice, acute pancreatitis, gastric emphysema, iron deficiency, and megaloblastic anemia.^[7]

The management of the disease requires proper liaison between the surgeon, psychiatrist, and caregivers of the patient. Various therapeutic procedures employed for trichobezoar include laparotomy, endoscopic removal and laparoscopic removal.^[1] The psychiatric intervention involves medicines and psychotherapy. Drugs such as selective serotonin-reuptake inhibitors, clomipramine, N-acetylcysteine, naltrexone, topiramate, and atypical neuroleptics have been shown to be effective. Simultaneous psychoeducation and cognitive skills training adds to the efficacy of the pharmacotherapy.^[11] Regular psychiatric follow up and treatment of the underlying psychopathology are needed to prevent the recurrent formation of bezoar.

Conclusion

Symptoms like pain abdomen, loss of appetite, and weight loss tend to present frequently in day to day clinical practice. The underlying cause of such symptoms can easily be overlooked by treating physician and caregivers. Hence, it is imperative to understand such case-reports which may lead to serious health consequences if not properly diagnosed.

Declaration of patient consent

The authors certify that they have obtained all appropriate patient consent forms. In the form the patient(s) has/have given his/her/their consent for his/her/their images and other clinical information to be reported in the journal. The patients understand that their names and initials will not be published and due efforts will be made to conceal their identity, but anonymity cannot be guaranteed.

Financial support and sponsorship

Nil.

Conflicts of interest

There are no conflicts of interest.

References

1. Falah SQ, Amanullah A. Huge trichobezoar in the stomach of a young female patient. *Gomal J Med Sci* 2016;14:118-9.
2. Sehgal VN, Srivastava G. Trichotillomania±trichobezoar: Revisited. *J Eur Acad Dermatol Venereol* 2006;20:911-5.
3. Irving P, Kadirkamanathan S, Priston A, Blanshard C. Education and imaging. gastrointestinal: Rapunzel syndrome. *J Gastroenterol Hepatol* 2007;22:2361.
4. Pace AM, Fearn C. Trichobezoar in a 13 year old male: A case report and review of literature. *Malta Med J* 2003;15:39-40.
5. Gupta A, Mittal D, Srinivas M. Gastric trichobezoars in children: Surgical overview. *Int J Trichol* 2017;9:50-3.
6. Houghton DC, Maas J, Twohig MP, Saunders SM, Compton SN, Neal-Barnett AM, *et al.* Comorbidity and quality of life in adults with hair pulling disorder. *Psychiatry Res* 2016;239:12-9.
7. Chahine E, Baghdady R, El Kary N, Dirani M, Hayek M, Saikaly E, *et al.* Surgical treatment of gastric outlet obstruction from a large trichobezoar: A case report. *Int JSurg Case Rep* 2019;57:183-5.
8. Mehra A, Avasthi A, Gupta V, Grover S. Trichophagia along with trichobezoar in the absence of trichotillomania. *JNeurosci Rural Pract* 2014;5(Suppl 1):S55-7.
9. Tiago S, Nuno M, João A, Carla V, Gonçalo M, Joana N. Trichophagia and trichobezoar: Case report. *Clin Pract Epidemiol Ment Health* 2012;8:43-5.
10. Grant JE, Odlaug BL. Clinical characteristics of trichotillomania with trichophagia. *Compr Psychiatry* 2008;49:579-84.
11. Cisoń H, Kuś A, Popowicz E, Szyca M, Reich A. Trichotillomania and trichophagia: Modern diagnostic and therapeutic methods. *Dermatol Ther* 2018;8:389-98.