



Case Report

Endoscopic Cauterization and Sclerotherapy for Airway Obstruction by a Third Branchial Pouch Sinus

M. Matthijs Fockens, MD ; Bernadette S. de Bakker, MD, PhD ; Krijn P. van Lienden, MD, PhD;
Frederik G. Dijkers, MD, PhD; Carlijn E.L. Hoekstra, MD, PhD

Key Words: Airway obstruction, branchial arch anomalies, third and fourth branchial pouch sinus, endoscopic cauterization, sclerotherapy.

Laryngoscope, 131:E1730–E1732, 2021

INTRODUCTION

Third and fourth branchial pouch sinus are rare causes of respiratory distress in neonates.^{1,2} Inflation of these sinus through the opening in the piriform sinus leads to airway obstruction. In literature, surgical excision is advised, although it is associated with a high complication rate in neonates.^{1,2} We present two cases of neonatal airway obstruction due to an air-filled third branchial pouch sinus and offer advice for treatment by combining endoscopic cauterization of the piriform sinus opening with percutaneous sclerotherapy of the residual cyst.

CASE PRESENTATION

Case 1

On the fifth postnatal day, a full-term male neonate was admitted with symptoms of stertor, breath-holding spells, and cyanosis during feeding. Intraoral examination and flexible pharyngolaryngoscopy showed severe left-sided bulging of the posterior oropharyngeal and

hypopharyngeal wall, obstructing the laryngeal view (Fig. 1). Caudal to the swelling, a normal larynx was seen. MRI scanning showed a left-sided air-filled neck mass causing compression of the airway and displacement of the larynx (Fig. 2). On diagnostic rigid pharyngolaryngoscopy, an opening in the base of the left piriform sinus was encountered, establishing the diagnosis of a third branchial pouch sinus. The opening was endoscopically cauterized using electrocautery. In the

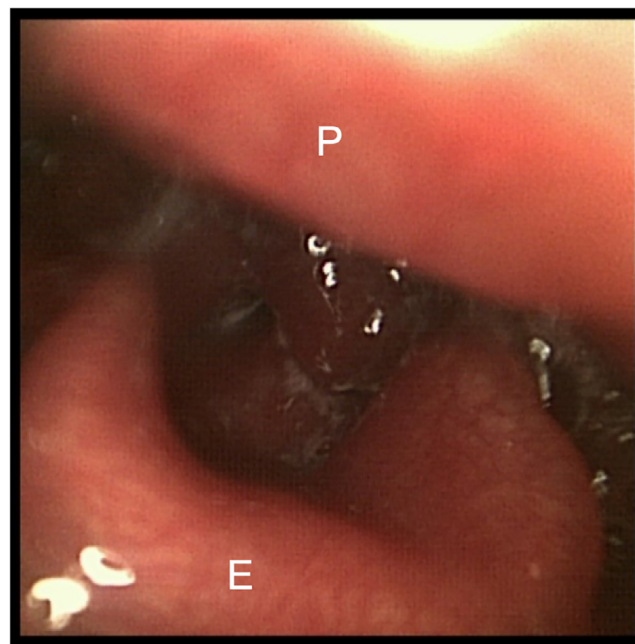


Fig. 1. Flexible pharyngolaryngoscopy of a 5-day-old neonate showing severe left-sided bulging of the posterior oropharyngeal and hypopharyngeal wall obstructing the larynx. E = epiglottis; P = pharyngeal wall.

This is an open access article under the terms of the Creative Commons Attribution-NonCommercial-NoDerivs License, which permits use and distribution in any medium, provided the original work is properly cited, the use is non-commercial and no modifications or adaptations are made.

From the Department of Otorhinolaryngology, Amsterdam UMC (M.M.F., F.G.D., C.E.H.), University of Amsterdam, Amsterdam, The Netherlands; Department of Medical Biology, Section Clinical Anatomy & Embryology, Amsterdam UMC (B.S.B.), University of Amsterdam, Amsterdam, The Netherlands; and the Department of Radiology, Sint Antonius Hospital (K.P.L.), Nieuwegein, The Netherlands.

Editor's Note: This Manuscript was accepted for publication on August 26, 2020

The authors have no funding, financial relationships, or conflicts of interest to disclose.

Send correspondence to C.E.L. Hoekstra, MD, PhD, Department of Otorhinolaryngology, Amsterdam UMC, University of Amsterdam, Meibergdreef 9, 1105 AZ Amsterdam, The Netherlands. E-mail: c.e.hoekstra@amsterdamumc.nl

DOI: 10.1002/lary.29101

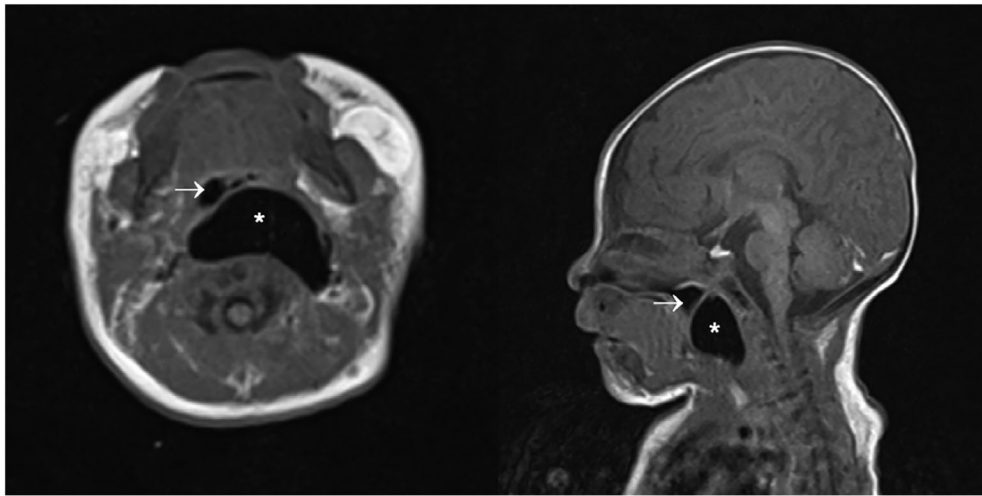


Fig. 2. T₁-weighted axial and sagittal MRI of the same 5-day-old neonate shows an air-filled neck mass (asterisk) in the left oropharynx and hypopharynx causing obstruction of the airway (arrow). The mass measured 16 × 38 × 35 mm in anteroposterior, lateral, and craniocaudal direction. MRI = magnetic resonance imaging; T₁ = longitudinal relaxation time.

following 2 weeks, intubation was required as the sinus recurred despite percutaneous puncture and aspiration. At 1 month, rigid pharyngolaryngoscopy showed closure of the sinus tract opening, and percutaneous sclerotherapy with 2.5 mL of tetracyclin 2.5 mg/mL was performed under ultrasonography guidance. The size of the mass decreased rapidly, and the patient was extubated 2 days later. After 10 days, the patient was discharged without respiratory symptoms. Flexible endoscopy showed complete remission of the third branchial pouch sinus

(Fig. 3); and after 2 years of uneventful follow-up, the patient was discharged from our care.

Case 2

At 38 weeks and 2 days of gestational age, labor of a female neonate was initiated because of a left-sided neck mass on prenatal ultrasonography. On the first day of life, the patient developed respiratory incidents with cyanosis and bradycardia, which required intubation. Ultrasonography showed an air- and fluid-filled mass measuring 20 × 28 × 53 mm in anteroposterior, lateral, and craniocaudal direction, closely related to larynx and

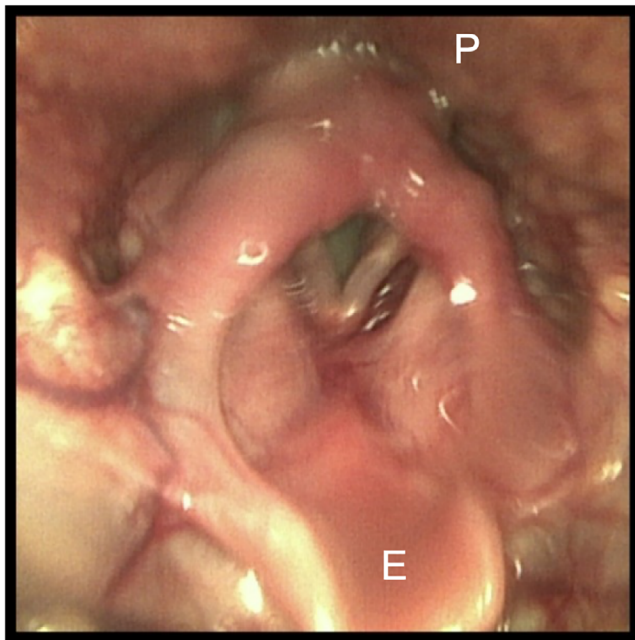


Fig. 3. Flexible pharyngolaryngoscopy of the same child at the age of 2 years, showing a normal larynx and hypopharynx. E = epiglottis; P = pharyngeal wall.

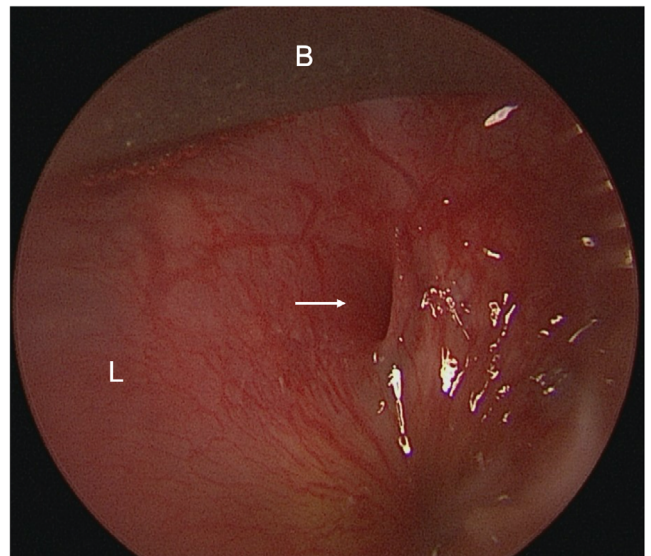


Fig. 4. Rigid diagnostic pharyngoscopy in a 9-day-old neonate showing a sinus tract opening (arrow) in the anteromedial part of the left piriform sinus. B = bevel of Miller laryngoscope blade; L = lateral wall of left piriform sinus.

trachea. Rigid pharyngolaryngoscopy showed a sinus tract in the base of the left piriform sinus confirming a third branchial pouch sinus (Fig. 4) and midtracheal compression. Endoscopic cauterization was performed with application of silver nitrate. Percutaneous puncture of the cyst produced 18 mL of fluid. Despite treatment, the mass recurred and extubation was not possible. Rigid pharyngolaryngoscopy 1 week later showed the sinus tract opening in the left piriform sinus to be closed. The residual cyst was punctured percutaneously, and sclerotherapy with 3 mL of tetracyclin 2.5 mg/mL was performed. The patient was extubated and discharged from the hospital in the following days. The patient did not develop any respiratory symptoms during 2 years of follow-up.

DISCUSSION

Third and fourth branchial arch anomalies are relatively rare, accounting for up to 8% and 4% of all branchial arch anomalies, respectively.^{1,2} They are primarily seen in the first decade of life and for unclear reasons occur predominantly on the left side (89% and 94%, respectively).^{1,2} Third and fourth branchial arch anomalies usually present as an asymptomatic neck mass, recurring neck abscess, cutaneous fistula, or acute suppurative thyroiditis. An air-filled third or fourth branchial pouch sinus causing airway obstruction is rare and only seen in only 5% and 3%, respectively.^{1,2} Although terminology on third and fourth branchial arch anomalies is used inconsistently in literature, the majority of reported cases concern a branchial pouch sinus characterized by an opening in the piriform sinus without connection to the skin (alternatively named congenital piriform sinus tract). Diagnostic pharyngolaryngoscopy can be used to locate the sinus tract in the piriform sinus. An opening cranial in the piriform sinus corresponds to a third branchial pouch sinus, whereas an opening caudal in the piriform sinus corresponds to a fourth branchial pouch sinus.

Literature on treatment considerations for third or fourth branchial pouch sinus is primarily based on patients aged 1 year and older because they generally present with a recurrent neck abscess or suppurative thyroiditis.^{1,2} In recent years, treatment of third and fourth branchial pouch sinus has shifted from surgery to endoscopic cauterization of the piriform sinus opening.³ Endoscopic cauterization has a comparable recurrence rate but a lower complication rate than surgical excision.³ Potential complications of surgery include wound infection; vocal cord paralysis; Horner syndrome; salivary fistula; and paralysis of cranial nerves VII, IX, X, and XII.^{1,2} The risk of surgical complications is higher in neonates (15%–17%) than in children over 1 year of age (4.5%).^{1,2}

Almost all published cases of airway obstruction due to an air-filled third or fourth branchial pouch sinus were treated surgically. Only rarely are percutaneous puncture and electrocautery sufficient to treat an air-filled third or fourth branchial pouch sinus.⁴ It seems reasonable to consider endoscopic cauterization of the piriform sinus opening as the first treatment option for air-filled sinuses because it is minimally invasive and can be performed directly following diagnostic pharyngolaryngoscopy. In our cases, cauterization alone was insufficient to resolve airway obstruction.

In search of an alternative treatment option over surgical excision, we chose sclerotherapy because it is frequently used to treat benign cystic head and neck lesions of different etiology, including branchial arch anomalies.⁵ First, we performed a rigid pharyngolaryngoscopy to confirm adequate closure of the piriform sinus opening to prevent spill of the sclerosing agent in the pharynx. Sclerotherapy was then performed under ultrasonography guidance. To our knowledge, sclerotherapy of a residual cyst of a third branchial pouch sinus has not been published earlier.

CONCLUSION

We successfully treated two neonates with airway obstruction due to a third branchial pouch sinus with a combination of endoscopic cauterization of the piriform sinus opening and tetracyclin sclerotherapy of the residual cyst. Both techniques are minimally invasive and relatively easy to perform. If endoscopic cauterization of a third or fourth branchial pouch sinus fails to resolve airway obstruction, we propose that percutaneous sclerotherapy of the residual cyst should be preferred over surgical excision.

ACKNOWLEDGMENT

The Medical Ethics Review Committee was consulted and formal assessment was waived.

BIBLIOGRAPHY

1. Nicoucar K, Giger R, Jaecklin T, Pope HG, Dulguerov P. Management of congenital third branchial arch anomalies: a systematic review. *Otolaryngol Head Neck Surg* 2010;142:21–22.
2. Nicoucar K, Giger R, Pope HG, Jaecklin T, Dulguerov P. Management of congenital fourth branchial arch anomalies: a review and analysis of published cases. *J Pediatr Surg* 2009;44:1432–1439.
3. Derks LSM, Veenstra HJ, Oomen KPQ, Speleman L, Stegeman I. Surgery versus endoscopic cauterization in patients with third or fourth branchial pouch sinuses: a systematic review. *Laryngoscope* 2016;126:212–217.
4. Patel JB, Kilbride H, Paulson L. Neonatal presentation of an air-filled neck mass that enlarges with Valsalva: a case report. *AJP Rep* 2015;5:e207–e211.
5. Kim J-H. Ultrasound-guided sclerotherapy for benign non-thyroid cystic mass in the neck. *Ultrasonography* 2014;33:83–90.