

Clotting Catastrophies in the Intensive Care Unit

Saswati Sinha¹, Subhash Kumar Todi²

ABSTRACT

Clotting catastrophies are rarely encountered challenges in the Intensive Care Unit (ICU) and their presentation and progress maybe devastating and fulminant. Dramatic onset and involvement of multiple vascular beds should alert the clinician to look for these disorders. Outcomes may be improved with rapid diagnosis and prompt institution of specific therapies and interdisciplinary liaison holds the key to success.

Keywords: Coagulopathy, Intensive Care Unit, Thrombotic microangiopathy

Indian Journal of Critical Care Medicine (2019); 10.5005/jp-journals-10071-23252

INTRODUCTION

Catastrophic thrombotic disorders are uncommon presentations to a critical care unit and may pose significant diagnostic and therapeutic challenges. They are characterized by rapid onset of thromboembolic occlusions affecting diverse vascular beds. These dramatic presentations may occur in a patient with a known underlying prothrombotic disorder or may occur *de novo* in a healthy individual. Having a strong index of suspicion and being able to rapidly identify those disorders which may be rapidly fatal if specific therapy is not instituted forms the crux of management.

What are the Catastrophic Thrombotic Syndromes?

Patients with several distinct disorders may present with multiple thromboembolic events either occurring simultaneously or over days to weeks and this was first called a "thrombotic storm" by Kitchens in 1998 with the following characteristic features:

- Presence of an underlying procoagulant state.
- Identifying a "trigger" which initiates the clotting process.
- Rapid development of new thromboembolic events especially if there is delay in specific therapy.
- Importance of prompt initiation of antithrombotic therapy to achieve a good outcome.
- Good long-term prognosis if the cycle of thrombosis is interrupted early.¹

Several disorders may present in this manner of which the most common are: catastrophic antiphospholipid antibody syndrome (CAPS), disseminated intravascular coagulation (DIC), thrombotic thrombocytopenic purpura (TTP), heparin-induced thrombocytopenia, trousseaus syndrome and coagulation disorders associated with pregnancy. These sometimes not only are challenging to diagnose but may also present therapeutic challenges as the need to anticoagulate in the presence of bleeding risk factors such as thrombocytopenia.

CATASTROPHIC ANTIPHOSPHOLIPID ANTIBODY SYNDROME

Catastrophic antiphospholipid antibody syndrome (CAPS) is a rare variant of antiphospholipid antibody syndrome which presents with widespread microthrombi in multiple vascular fields. The patients might present with multiorgan dysfunction such as encephalopathy, acute respiratory distress syndrome, renal failure, thrombocytopenia and cardiac failure or recurrent pregnancy losses. It was defined in 1992 by Asherson as a vaso-

^{1,2}Department of Critical Care, AMRI Hospital, Dhakuria and Mukundapur, Kolkata, West Bengal, India

Corresponding Author: Subhash Kumar Todi, Department of Critical Care, AMRI Hospitals, Dhakuria and Mukundapur, Kolkata, West Bengal, India, Phone: 91-33-66260000, e-mail: drsubhashtodi@gmail.com

How to cite this article: Sinha S, Todi SK. Clotting Catastrophies in the Intensive Care Unit. *Indian J Crit Care Med* 2019;23(Suppl 3):S197–S201.

Source of support: Nil

Conflict of interest: None

occlusive process involving at least 3 organs with elevated levels of circulating anticardiolipin antibodies or lupus anticoagulation test.² The syndrome may occur with or without concomitant SLE or less commonly other rheumatological disorders and is commonly associated with microangiopathic hemolytic anemia and thrombocytopenia. The commonest cause for ICU admission is progressive cardiopulmonary failure.

Mortality associated with CAPS can be as high as 50%.³ Hence, early recognition and timely intervention holds the key to improving survival. History of previous thrombotic episodes such as deep vein thrombi/ pulmonary embolism, stroke, recurrent fetal losses, HELLP syndrome and thrombotic episodes involving other organs as well as thrombocytopenia can provide valuable clues to this disorder and such clues can be found in up to 2/3rd of patients.⁴

Precipitating Factors

Precipitating factors may be identified in a significant proportion of patients including - infections, trauma, surgical procedures, pregnancy, malignancies, reduction or withdrawal of anticoagulant drugs and certain drugs per se like oral contraceptives and thiazide diuretics have been implicated as triggers.

Diagnosis

There are specific criteria for diagnosis of CAPS which includes (1) Involvement of 3 or more organs, systems or tissues, (2) Simultaneous of development within a week, (3) Histopathological confirmation of microvascular thrombosis, and (4) Laboratory confirmation which includes presence of lupus anticoagulant, medium to high titres of anti cardiolipin antibodies or medium to high titre ant beta 2 microglobulin I on 2 occasions at least 12 weeks apart. Depending on number of criteria fulfilled, the diagnosis of "definite" or "probable" CAPS is made.⁵

Treatment

The treatment is not standardized but may include a combination of organ support and modalities to suppress the ongoing thrombotic process. Therapeutic options include various combinations of anticoagulants, corticosteroids, and plasmapheresis. Intravenous immunoglobulin, cyclophosphamide, rituximab and eculizumab have also been used in patients with varying success.

DISSEMINATED INTRAVASCULAR COAGULATION

Disseminated intravascular coagulation (DIC) often occurs as a complication in several conditions, most common being sepsis, trauma, cancer, obstetric complications such as preeclampsia, acute fatty liver of pregnancy, retained dead fetus, etc.

It occurs as a result of inappropriate thrombin activation which causes fibrinogen to form fibrin, activation of platelets and endothelium and fibrinolysis. It may remain asymptomatic with only laboratory derangements or may present with bleeding, thrombosis (unusual presentation), organ failure or the most severe form of DIC — purpura fulminans.

Thrombosis is mostly venous but arterial thrombi as well as nonbacterial thrombotic endocarditis have also been reported.⁸ Purpura fulminans a rare condition where DIC is associated with extensive tissue thrombosis and hemorrhagic skin necrosis and may occur following a viral infection or meningococemia or any other life threatening infection and the skin lesions may be severe enough to require amputations. There may exist inherited or acquired deficiency of protein C in these patients.

Diagnosis

Diagnosis is based on a combination of clinical and laboratory parameters which include a prolonged PT and aPTT with thrombocytopenia, low fibrinogen and elevated d-dimer. Microangiopathic hemolytic anemia is often present with schistocytes and helmet cells but these changes are less pronounced than in patients with thrombotic thrombocytopenic purpura.

Treatment

Treatment of the underlying cause forms the mainstay of treatment of DIC. Apart from this the support of organ systems, prevention of bleeding and prevention of thrombosis are the other aspects to be addressed. Routine prophylactic administration of platelets and coagulation factors are not recommended in a stable patient who is not bleeding unless the platelet count is less than 10,000–20,000/mm³. However replacement of factors must be done if the patient is bleeding or needs invasive interventions. There is no benefit of administering antithrombin⁹ or recombinant thrombomodulin to a bleeding DIC patient.¹⁰

It is important however to note that antifibrinolytic agents such as tranexamic acid and epsilon amino caproic acid (EACA) are generally contraindicated as they may increase the risk of thrombosis and the same is with prothrombin complex concentrates.

Thrombosis although extremely rare, maybe seen in certain severe infections such as severe malaria and dengue virus infections, including digital gangrene in which case heparin administration may be appropriate. However, no definite recommendations have been widely accepted and monitoring of anticoagulation in this setting maybe particularly challenging as the baseline values of PT and aPTT are elevated. Heparin levels may need to be monitored or

institution specific guidelines need to be in place to address these issues closely watching for the risk of bleeding.¹¹

Patients with purpura fulminans seem to benefit from administration of protein C concentrates with serial monitoring of d dimer until it normalizes or shows a declining trend.¹² 2–3 units of plasma maybe transfused every 6 hours instead of protein C concentrates, however the half life of protein C in plasma is very short.

Prognosis

Prognosis of DIC depends on the treatability of the underlying disorder and the extent or severity of the coagulation abnormalities and the mortality maybe as high as 40–80%.

THROMBOTIC THROMBOCYTOPENIC PURPURA

Thrombotic thrombocytopenic purpura (TTP) presents to the ICU with strokes, intractable seizures or renal insufficiency. Presence of these clinical features with evidence of thrombocytopenia and microangiopathic hemolytic anemia (MAHA) diagnosed by the evidence of hemolysis and schistocytes on a peripheral blood film should act as strong pointers to the diagnosis of this entity.¹³ Having a strong index of suspicion allows timely diagnosis and institution of effective therapy and can prevent misdiagnosis as sepsis, vasculitis or cerebritis. The classic complete “pentad” of MAHA, thrombocytopenia, fever, renal impairment and severe neurological signs is now rare to find with the advent of plasma exchange and the need for all the components for diagnosing TTP is now obsolete.

Many patients with TTP have a deficiency of an enzyme called ADAMTS13 which is a protease and cleaves the von Willebrand factor (vWF) or presence of an inhibitor of this enzyme. ADAMTS13 breaks vWF into small fragments which does not allow spontaneous platelet aggregation.¹⁴ Deficiency of the enzyme allows large multimers of vWF to cause spontaneous aggregation of platelets and leads to the thrombosis in TTP which contributes to organ failure.

Diagnosis

Diagnosis of TTP and initiating therapy with plasma exchange is an urgency. The diagnosis is almost always presumptive based on the clinical features and laboratory parameters. Testing for ADAMTS activity is an important adjunct for the diagnosis but therapy should not be delayed pending the test results and neither should this test be used in isolation to diagnose TTP. The presence of MAHA, thrombocytopenia and ADAMTS deficiency in an appropriate clinical setting is sufficient for TTP diagnosis.

The PLASMIC score¹⁵ has been devised and validated to predict severe ADAMTS deficiency (<10%) in adults and to support the diagnosis and a high score of 6–7 predicted the same with a good predictive value.

Treatment

Options include plasma exchange, steroids, rituximab and caplacizumab. Choice of treatment depends on the clinical presentation and laboratory parameters and the risk – benefit of the modalities which varies from patient to patient.

Therapeutic plasma exchange (TPE)

It forms the mainstay of treatment for patients with presumed or confirmed TTP until their platelet counts recover or an alternative diagnosis is established.¹⁶ This should be instituted urgently because

if untreated, the rapid spiral of worsening organ failure leads to death.¹⁷ TPE has helped to significantly lower the mortality from 90% in the preplasma exchange era to <10%. TPE works by removal of patient's plasma and replacement by donor plasma thereby replacing ADAMTS13 and removing autoantibodies inhibiting the activity of this protease as well as the large circulating multimers of vWF. Correction of ADAMTS13 deficiency will allow cleavage of vWF multimers and prevent the microvascular thrombosis and organ failure secondary to that.^{17,18} It is recommended that one plasma volume (approximately 40 mL/kg) is exchanged per procedure and continued till patient improves or an alternative diagnosis is established.

Timely initiation of TPE can pose significant challenges in terms of basing the diagnosis on clinical parameters only, logistic issues like trained manpower and availability of the apheresis equipment. If TPE is not immediately available, plasma infusion maybe used as a temporizing measure.

Immunosuppressive Agents

Addition of steroids and rituximab is now recommended to all patients with severe ADAMTS13 deficiency or patients with a PLASMIC score of 5–7 because it has been shown to reduce duration of plasma exchange.¹⁹

Steroids: They are thought to reduce the production of ADAMTS inhibitor autoantibody and thereby hasten the recovery. The dose depends on the severity at presentation and in the high risk patients the recommended dose is 1000 mg of methyl prednisolone for 3 days or 125 mg two to 4 times daily and then reduce the dose to 1 mg/kg of prednisone once the patient stabilizes.²⁰

Rituximab: It is an anti-CD20 monoclonal antibody which has proven efficacy in many autoimmune diseases. Its use in TTP is supported at present by efficacy in observational studies where it has shown to prevent relapses and promote early recovery when used initially with plasma exchange. The optimal dose in TTP is still uncertain with studies using 375 mg/m² once weekly for 4 consecutive weeks.²¹ Studies are under progress with smaller dose of 100 mg/m² once weekly for 4 weeks (NCT01554514). The dose of rituximab should be administered after the plasma exchange as it can be removed by the procedure.

Caplicizumab: It is a monoclonal antibody which binds to the vWF and blocks its interaction with platelet glycoprotein Ib-IX-V, thereby reducing vWF multimers causing microthrombi and disease manifestations. It has been recently approved by the US FDA and its exact place in clinical practice is yet to be determined. Its use as a part of the initial therapy in TTP is likely to be reserved for patients who are critically ill or have severe neurological manifestations. The doses in trials have been 10 mg IV followed by 10 mg subcutaneously after the plasma exchange on day 1 followed by 10 mg subcutaneously once daily for 30 days. Monitoring for bleeding needs to be done with this agent.

Monitoring disease progress: Serial monitoring of platelet count, LDH levels in conjunction with improving neurologic and clinical signs governs the duration of therapy with platelet count being the most important and may take several days for the patient to recover.

HEPARIN-INDUCED THROMBOCYTOPENIA WITH THROMBOSIS

It is a life threatening immune mediated prothrombotic disorder which occurs transiently following exposure to unfractionated or

low molecular weight heparin due to formation of autoantibodies directed against endogenous platelet factor 4 (PF4) in complex with heparin. Heparin-induced thrombocytopenia with thrombosis (HIT) affects the venous system more than arterial and large vessels are commonly involved.²² However, involvement of multiple vascular beds may occur in cases of severe HIT with DIC and limb ischemia due to microvascular thrombi may occur with a mortality rate as high as 20%.²³ Early recognition and timely intervention is the key to improving prognosis.

HIT is of 2 types:

Type I is associated with a mild transient decrease in platelet count with the lowest usually not below 1,00,000/mm³ and usually occurs within 2 days of heparin initiation. Platelet count improves spontaneously and usually does not require discontinuation of heparin and is not associated with thrombosis.

Type II occurs due to HIT antibodies or PF4/heparin antibodies and presents with thrombocytopenia with thrombosis and can be life threatening and discontinuation of the incriminating agent with initiation of a nonheparin anticoagulant is the key to management of these patients.

The pathogenic HIT antibodies are usually IgG antibodies and form over days and disappear over time. However heparin should not be used in these patients even after antibodies disappear. Formation of HIT antibodies require at least 4 days of heparin exposure or more.

Clinical presentation of HIT is variable and can occur with any dose or route of heparin, occurs more commonly with unfractionated than low molecular weight heparins and more often in surgical than medical patients and more with therapeutic doses. Females and older patients are also at a higher risk. Thrombotic manifestations include death (likely due to pulmonary embolism, skin necrosis and limb gangrene).

Diagnosis

Diagnosis of HIT includes a combination of clinical and laboratory parameters. A score based on (1) degree of thrombocytopenia (2) timing of platelet fall (3) thrombosis and (4) other causes of thrombocytopenia - 4 Ts score can be calculated (score 0-8). A score of 6–8 is consistent with a high probability of HIT.²⁴

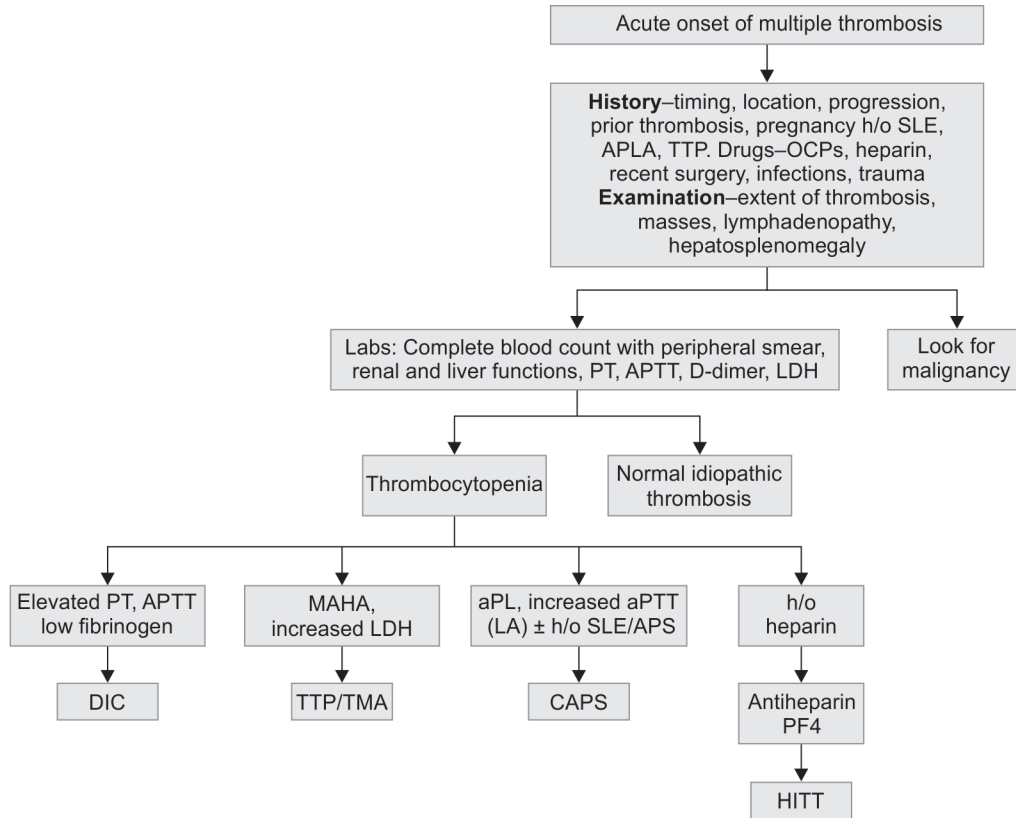
HIT Antibody Testing

There are two types of tests for antiheparin / PF4 antibodies — immunoassay and functional assays. If the 4Ts score is low, there is no need to perform an antibody test as the likelihood of thrombosis is <1%.²⁵ For all patients with intermediate to high 4Ts score, an immunoassay for anti-PF4 — heparin ELISA should be performed and treatment should be initiated without waiting for the results of the assay. Functional assays are reserved for diagnostic uncertainties and when there is a discordance between clinical probability and ELISA results. Serotonin release assay is the gold standard but is limited by its high cost, use of radioactive material, being technically demanding and turn around time being long.

Treatment

Primary treatment of HIT is to stop all heparin exposure and to start a nonheparin parenteral anticoagulant like argatroban or bivalirudin. Titration of anticoagulation with conventional APTT based regimens maybe challenging owing to elevated baseline values. There have been reports of treatment of refractory HIT with plasma exchange and rituximab.

Flowchart 1: Diagnostic approach to catastrophic thrombotic syndromes



SLE, systemic lupus erythematosus; APLA, antiphospholipid antibody; APS, antiphospholipid antibody syndrome; TTP, thrombotic, thrombocytopenic purpura; OCPs, oral contraceptive pills; TMA, thrombotic microangiopathy

CANCER-ASSOCIATED THROMBOSIS

Although thromboembolism is a leading cause of mortality in cancer patients, only a small proportion of patients may present with a catastrophic thrombosis — of note being Trousseau syndrome with migratory thrombophlebitis, arterial thrombosis and non bacterial thrombotic endocarditis. Coexisting DIC often makes anticoagulation particularly challenging.

Cancer patients can also develop catastrophic APS which should be managed like any other patient with CAPS with anticoagulation, plasma exchange and steroids.²⁶

CATASTROPHIC THROMBOSIS IN PREGNANCY

Patients with known APS may present with catastrophic thrombotic events during pregnancy.²⁷ However, patients without APS may also present with thrombotic syndromes and the features might overlap with hemolysis, elevated liver enzymes, low platelets (HELLP).²⁷ Treatment centers around initiation of anticoagulation with LMWH during pregnancy with a switch to unfractionated heparin around delivery. Pregnant patients can be treated with plasma exchange, steroids and IVIg if they present with CAPS. Fetal delivery may be needed in HELLP like syndromes and platelet count may need to be monitored closely.

PRINCIPLES IN MANAGEMENT

Catastrophic thrombotic syndromes need a multifaceted therapeutic approach which includes:

- Therapeutic anticoagulation is the most critical step and unfractionated heparin is usually the agent of choice because

of the ease of dose titration, reversibility and ability to interrupt during procedures.

- Prompt initiation of specific procedures like therapeutic plasma exchange and immune modulating agents in case CAPS or TTP is suspected. An approach to diagnosis is outlined in Flowchart 1.
- Daily review and tailoring of therapy is mandatory based on patient's response, emerging clinical course and laboratory data and complications.
- Multidisciplinary involvement in order to streamline the management which may include diverse therapeutic modalities.

CONCLUSION

Managing catastrophic thrombotic syndromes in the ICU can be challenging and may pose significant diagnostic and therapeutic challenges. Therapeutic anticoagulation is the key which requires close monitoring because of the coexisting thrombocytopenia and coagulopathy in a significant proportion of patients. Having a strong index of suspicion for specific disorders like TTP and CAPS allows prompt institution of specific therapeutic measures which affects survival. Interdisciplinary liaison is the key as the management may involve multiple specialities and some of these patients will need indefinite anticoagulation.

REFERENCES

1. Kitchens CS. Thrombotic storm: when thrombosis begets thrombosis. *Am J Med.* 1998;104(4):381–385.

2. Asherson RA. The catastrophic antiphospholipid syndrome. *J Rheumatol* 1992;19(4):508–512.
3. Asherson RA, Cervera R, Piette JC, Font J, Lie JT, Burcoglu A, et al. Catastrophic antiphospholipid syndrome: clinical and laboratory features of 50 patients. *Medicine (Baltimore)* 1998;77:195–207.
4. Asherson RA, Cervera R, Piette JC, Shoenfeld Y, Espinosa G, Petri MA, et al. Catastrophic antiphospholipid syndrome: clues to the pathogenesis from a series of 80 patients. *Medicine (Baltimore)* 2001;80(6):355–77.
5. Cervera R, Rodríguez-Pintó I, Colafrancesco S, Conti F, Valesini G, Rosário C, et al. 14th International Congress on Antiphospholipid Antibodies Task Force Report on Catastrophic Antiphospholipid Syndrome. *Autoimmun Rev*. 2014;13(7):699-707.
6. Espinosa G, Berman H, Cervera R. Management of refractory cases of catastrophic antiphospholipid syndrome. *Autoimmun Rev*. 2011;10(11):664–668.
7. Kronbichler A, Frank R, Kirschfink M, Szilágyi Á, Csuka D, Prohászka Z, et al. Efficacy of eculizumab in a patient with immunoadsorption-dependent catastrophic antiphospholipid syndrome: a case report. *Medicine (Baltimore)*. 2014;93(26):e143.
8. Sharma S, Mayberry JC, DeLoughery TG, Mullins RJ. Fatal cerebroembolism from nonbacterial thrombotic endocarditis in a trauma patient: case report and review. *Mil Med* 2000;165:83–5.
9. Warren BL, Eid A, Singer P, Pillay SS, Carl P, Novak I, et al. Caring for the critically ill patient. High-dose antithrombin III in severe sepsis: a randomized controlled trial. *JAMA* 2001;286(15):1869.
10. Vincent JL, Francois B, Zabolotskikh I, Daga MK, Lascarrou JB, Kirov MY, et al. Effect of a Recombinant Human Soluble Thrombomodulin on Mortality in Patients With Sepsis-Associated Coagulopathy: The SCARLET Randomized Clinical Trial. *JAMA*. 2019;321(20):1993.
11. Olson JD, Arkin CF, Brandt JT, Cunningham MT, Giles A, Koepke JA, et al. Laboratory monitoring of unfractionated heparin therapy. *Arch Pathol Lab Med* 1998;122:782–798.
12. Goldenberg NA, Manco-Johnson MJ. Protein C deficiency. *Haemophilia*. 2008;14(6):1214.
13. George JN. How I treat patients with thrombotic thrombocytopenic purpura-hemolytic uremic syndrome. *Blood* 2000;96:1223–1229.
14. Levy GG, Nichols WC, Lian EC, Foroud T, McClintick JN, McGee BM, et al. Mutations in a member of the ADAMTS gene family cause thrombotic thrombocytopenic purpura. *Nature* 2001;413:488–494.
15. Jamme M, Rondeau E. The PLASMIC score for thrombotic thrombocytopenic purpura. *Lancet Haematol*. 2017;4(4):e148. Epub 2017 Mar 2. *Lancet Haematol*. 2017;4(4):e148. Epub 2017 Mar 2.
16. Rock GA, Shumak KH, Buskard NA, Blanchette VS, Kelton JG, Nair RC, et al. Comparison of plasma exchange with plasma infusion in the treatment of thrombotic thrombocytopenic purpura. Canadian Apheresis Study Group. *N Engl J Med*. 1991;325(6):393.
17. Amorosi EL, Ultmann JE. Thrombotic thrombocytopenic purpura: Report of 16 cases and review of the literature. *Medicine (Baltimore)*. 1966;45:139.
18. Zheng XL, Kaufman RM, Goodnough LT, Sadler JE. Effect of plasma exchange on plasma ADAMTS13 metalloprotease activity, inhibitor level, and clinical outcome in patients with idiopathic and nonidiopathic thrombotic thrombocytopenic purpura. *Blood*. 2004;103(11):4043. Epub 2004 Feb 24.
19. Som S, Deford CC, Kaiser ML, Terrell DR, Kremer Hovinga JA, Lämmle B, et al. Decreasing frequency of plasma exchange complications in patients treated for thrombotic thrombocytopenic purpura-hemolytic uremic syndrome, 1996 to 2011. *Transfusion*. 2012;52(12):2525. Epub 2012 Apr 15.
20. George JN. How I treat patients with thrombotic thrombocytopenic purpura-hemolytic uremic syndrome: 2010. *Blood*. 2010;116(20):4060. Epub 2010 Aug 4.
21. Scully M, Cohen H, Cavenagh J, Benjamin S, Starke R, Killick S, et al. Remission in acute refractory and relapsing thrombotic thrombocytopenic purpura following rituximab is associated with a reduction in IgG antibodies to ADAMTS-13. *Br J Haematol*. 2007;136(3):451.
22. Greinacher A, Farner B, Kroll H, Kohlmann T, Warkentin TE, Eichler P. Clinical features of heparin-induced thrombocytopenia including risk factors for thrombosis. A retrospective analysis of 408 patients. *Thromb Haemost*. 2005;94(1):132–135.
23. Omran AS, Karimi A, Ahmadi H, Yazdanifard P. Delayed-onset heparin-induced thrombocytopenia presenting with multiple arteriovenous thromboses: case report. *J Med Case Reports*. 2007;1:131.
24. Lo GK, Juhl D, Warkentin TE, Sigouin CS, Eichler P, Greinacher A. Evaluation of pretest clinical score (4 T's) for the diagnosis of heparin-induced thrombocytopenia in two clinical settings. *J Thromb Haemost*. 2006;4(4):759.
25. Raschke RA, Curry SC, Warkentin TE, Gerkin RD. Improving clinical interpretation of the anti-platelet factor 4/heparin enzyme-linked immunosorbent assay for the diagnosis of heparin-induced thrombocytopenia through the use of receiver operating characteristic analysis, stratum-specific likelihood ratios, and Bayes theorem. *Chest*. 2013;144(4):1269–1275.
26. Miesbach W, Asherson RA, Cervera R, Shoenfeld Y, Gomez Puerta J, Bucciarelli S, et al. Members of CAPS Registry Group. The catastrophic antiphospholipid (Asherson's) syndrome and malignancies. *Autoimmun Rev*. 2006;6(2):94–97.
27. Gómez-Puerta JA, Espinosa G, Cervera R. Catastrophic antiphospholipid syndrome: diagnosis and management in pregnancy. *Clin Lab Med*. 2013;33(2):391–400.