

## Herpetic tracheitis in association with rituximab therapy

Lorraine Thong<sup>1</sup>, Barry J Plant<sup>1</sup>, Julie McCarthy<sup>2</sup> & Desmond M Murphy<sup>1</sup>

<sup>1</sup>Department of Respiratory Medicine, Cork University Hospital, Cork, Ireland.

<sup>2</sup>Department of Cytopathology, Cork University Hospital, Cork, Ireland.

### Keywords

Herpes simplex, immunosuppression, non-Hodgkin's lymphoma, rituximab, tracheitis.

### Correspondence

Desmond M Murphy, Department of Respiratory Medicine, Cork University Hospital, Wilton, Cork, County Cork, Ireland. E-mail: Desmond.murphy@hse.ie

Received: 25 November 2015; Revised: 24 February 2016; Accepted: 06 March 2016

*Respirology Case Reports*, 4 (4), 2016, e00158

doi: 10.1002/rcr2.158

### Abstract

A 58-year old lady under active follow-up with the respiratory services at our institution for bronchiectasis secondary to hypogammaglobulinaemia presented with hoarseness and haemoptysis. She was also receiving rituximab maintenance therapy for follicular lymphoma. Bronchoscopy demonstrated vesicular lesions on her vocal cords and trachea, confirmed as herpes simplex virus (HSV) on cytological analysis of brushings. She responded well to intravenous valacyclovir. Rituximab is increasingly utilised in the treatment of haematological and auto-immune disorders. This case highlights the potential of this drug to potentiate susceptibility to infection in an already immunocompromised individual.

### Introduction

Rituximab is a chimeric anti-CD20 antibody increasingly utilised for treating autoimmune diseases and haematological disorders. It works via three independent mechanisms of action: antibody-dependent cellular cytotoxicity, complement-mediated cytotoxicity, and apoptosis. The therapeutic value of rituximab in non-Hodgkin's lymphoma is a result of the expression of CD20 on the cell surface of the majority of B cells [1].

A recently published report examining the long-term safety profile of rituximab therapy in lymphoma concluded that infection-related events were higher in patients treated with rituximab, although overall survival was improved [2]. Herpes simplex virus (HSV)-related infection associated with rituximab therapy has been reported. A male patient with lymphoma treated with rituximab presented with oral pain and odynophagia. He was diagnosed with HSV mucositis [3].

Lower respiratory tract infection by HSV primarily occurs in patients who are profoundly immunocompromised or have sustained trauma to their tracheal epithelium. In an immunocompromised host, the condition can be progressive and fatal. Its pathogenesis remains unclear, with some authors suggesting possible extension or aspiration of oropharyngeal HSV, whilst there is some evidence to support a role for haematogenous spread [4].

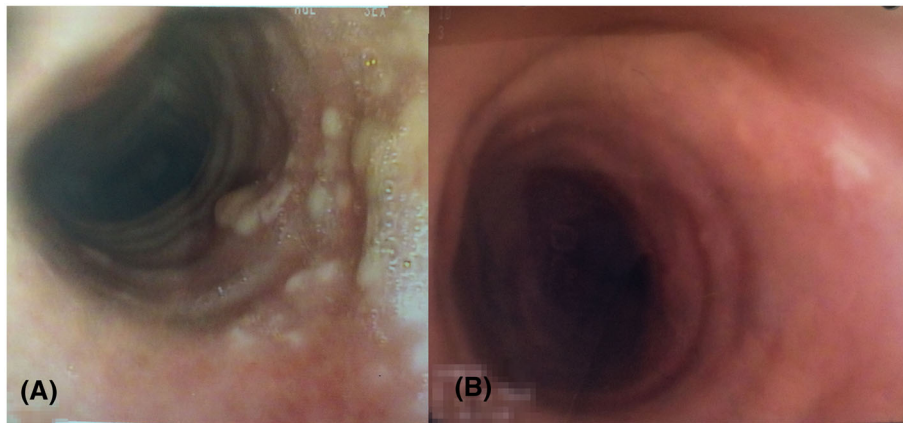
### Case report

A 58-year old lady was under respiratory follow-up at our institution for bronchiectasis, which had developed secondary to hypogammaglobulinaemia. At one of her routine outpatient visits, she complained of a one-week history of hoarseness and general malaise. She had a single episode of haemoptysis. Furthermore, she reported an increased exacerbation frequency in the preceding months. She had received rituximab therapy 1 week prior to her clinic review. She had started on maintenance rituximab therapy approximately 6 months prior to that, and received a total of 3 cycles of same.

Other than her bronchiectasis and follicular lymphoma, her past medical history was notable for cryoglobulinaemia, previous breast cancer, and chronic kidney disease.

Her other regular medications included azithromycin, tiotropium inhaler, montelukast, salmeterol/fluticasone inhaler, pravastatin, and nitrofurantoin.

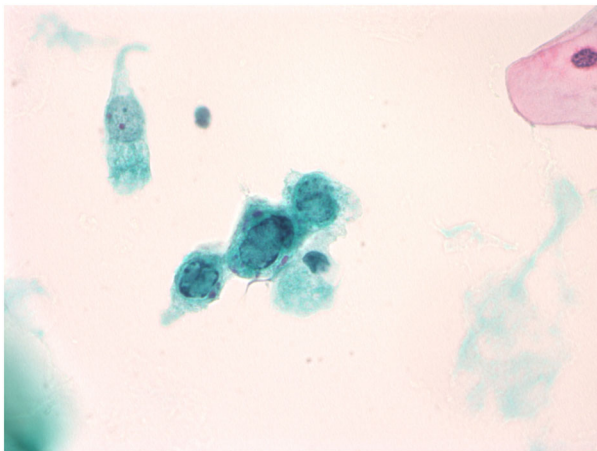
At clinical presentation, the physical examination demonstrated oxygen saturations of 93% on room air, a pulse rate of 90 beats per minute, and a blood pressure of 120/80 mmHg. Apart from mild expiratory wheeze and scattered inspiratory crackles on the auscultation of her lung fields, the physical examination was unremarkable.



**Figure 1.** (A) Vesicular rashes seen on the tracheal wall, consistent with herpetic tracheitis. (B) Resolutions of lesions 2 weeks post-treatment with antiviral therapy.

Initial haematological investigations revealed lymphopenia ( $0.38 \times 10^9/L$ ), raised C-reactive protein (126 mg/L), and lactate dehydrogenase (989 U/L). The computed tomography of the thorax performed was notable for two left upper lobe nodules, one measuring 15 mm with central cavitation, and the second measuring 8 mm with a surrounding ground glass halo.

Intravenous piperacillin/tazobactam was empirically commenced prior to a bronchoscopy. The bronchoscopy revealed the presence of vesicular tracheal lesions (see Fig. 1). Endobronchial brushings confirmed a diagnosis of herpetic tracheitis (see Fig. 2). She was commenced on intravenous valacyclovir. Piperacillin/tazobactam was



**Figure 2.** Photomicrograph of bronchial brushing cytospin preparation stained with Papanicolaou stain ( $\times 60$ ). A mature squamous cell (top right) and normal endobronchial epithelial cell (top left) are seen. Three virally infected cells show ground glass inclusions (nuclear enlargement, smudging of nuclear chromatin, and beading of nuclear membrane). These are typical cytomorphologies of Herpes Simplex Virus (HSV).

continued, and an antifungal agent, intravenous caspofungin, was added to her therapeutic regimen-pending cultures. Bronchoalveolar lavage subsequently grew *Pseudomonas aeruginosa*. She completed a 2-week course of intravenous antimicrobial therapy. A repeat bronchoscopy-performed post-treatment revealed a complete resolution of her tracheal lesions. She was discharged well on long term prophylactic antiviral therapy thereafter, and remained on rituximab therapy.

## Discussion

The diagnosis of lower respiratory tract HSV infection should be based initially on cytological and/or histological findings. Bronchoscopy is valuable for visualizing typical ulcerations or membranes in the respiratory tract, and for improving the sensitivity and specificity of the cytological diagnosis.

Reactivation of viral infection is common in patients with solid tumour or haematological malignancy. Incidence and severity are dependent on the extent of cellular immunosuppression. It is therefore possible that rituximab adds additional risk. Antiviral agents have demonstrated clinical efficacy in treating both mucocutaneous and pulmonary HSV infections. Antiviral prophylaxis may be effective in preventing viral reactivation [5].

In conclusion, we present a case of HSV lower respiratory tract infection in a patient undergoing treatment with rituximab, highlighting the potential of this agent to induce immunosuppression.

## Disclosure statements

No conflict of interest declared.

Appropriate written informed consent was obtained for publication of this case report and accompanying images.

**References**

1. Seyfizadeh N, Seyfizadeh N, Hasenkamp J, et al. 2015. A molecular perspective on rituximab: a monoclonal antibody for B cell non Hodgkin lymphoma and other affections. *Crit. Rev. Oncol. Hematol.* 97:275-290.
2. Vidal L, Gafter-Gvili A, Salles G, et al. 2011. Rituximab maintenance for the treatment of patients with follicular lymphoma: an updated systematic review and meta-analysis of randomized trials. *J. Natl. Cancer Inst.* 103(23):1799–1806.
3. Guerrero MD, Swenson KK. 2014. Herpes simplex virus-related oral mucositis in patients with lymphoma. *Oncol. Nurs. Forum* 41(3):327–330.
4. Legge RH, Thompson AB, Linder J, et al. 1988. Acyclovir-responsive herpetic tracheobronchitis. *Am. J. Med.* 85(4):561–563.
5. Sandherr M, Hentrich M, von Lilienfeld-Toal M, et al. 2015. Antiviral prophylaxis in patients with solid tumours and haematological malignancies—update of the Guidelines of the Infectious Diseases Working Party (AGIHO) of the German Society for Hematology and Medical Oncology (DGHO). *Ann. Hematol.* 94(9):1441–1450.