

Case Report

Delayed rupture of the flexor tendons as a complication of malunited distal radius fracture after nonoperative management: A report of two cases

Shingo Komura^{a,*}, Akihiro Hirakawa^a, Kyosuke Yamamoto^a, Koki Kato^a, Marie Nohara^b, Yasuharu Matsushita^b, Tomihiro Masuda^b, Haruhiko Akiyama^a

^a Department of Orthopaedic Surgery, Gifu University Graduate School of Medicine, Gifu, Japan

^b Department of Rehabilitation Medicine, Gifu University Hospital, Gifu, Japan

ARTICLE INFO

Keywords:

Distal radius fracture

Malunion

Nonoperative treatment

Flexor tendon rupture

Complication

ABSTRACT

Rupture of the flexor tendons is a rare complication following distal radius malunion after nonoperative management. This article presents 2 cases of delayed flexor tendon ruptures following malunited distal radius fracture and discusses the characteristics, operative management, and outcomes of this rare complication by reviewing the previous literature. Our analysis demonstrate that surgical reconstruction of ruptured tendons provides good outcomes when the number of tendon ruptures is small. If multiple tendon ruptures are present, surgical outcomes may be poor despite surgical reconstruction. Osseous surgery would be necessary to prevent additional tendon ruptures; however, less invasive and simple surgeries allowing early rehabilitation would be preferable.

Introduction

Rupture of the flexor tendon is a well-known complication after palmar locking plate fixation for distal radius fractures, and its incidence has been reported as 0.3% to 0.9% [1–3]. However, flexor tendon rupture associated with distal radius fracture after nonoperative treatment is uncommon complication [4–31]. This complication can be managed by reconstruction of the ruptured tendons and surgery for the osseous lesion that caused the tendon ruptures. However, the optimal treatment strategy for this pathological condition has not been established because of the limited number of reported cases. Here, we present 2 cases of delayed flexor tendon ruptures following malunited distal radius fracture after nonoperative management and discuss the mechanism, characteristics, operative management, and outcomes of this rare complication by reviewing the previous literature.

Case reports

Case 1

A 74-year-old female fell down on her left hand and sustained a distal radius fracture. She underwent closed reduction, with cast immobilization for 4 weeks in the primary clinic. Five and a half months after the injury, she experienced sudden loss of active flexion

* Corresponding author at: Department of Orthopaedic Surgery, Gifu University Graduate School of Medicine, Yanagido 1-1, Gifu 501-1194, Japan.

E-mail address: s_komura@gifu-u.ac.jp (S. Komura).

<https://doi.org/10.1016/j.tcr.2019.100198>

Accepted 21 April 2019

Available online 28 April 2019

2352-6440/© 2019 The Authors. Published by Elsevier Ltd. This is an open access article under the CC BY-NC-ND license (<http://creativecommons.org/licenses/by-nc-nd/4.0/>).

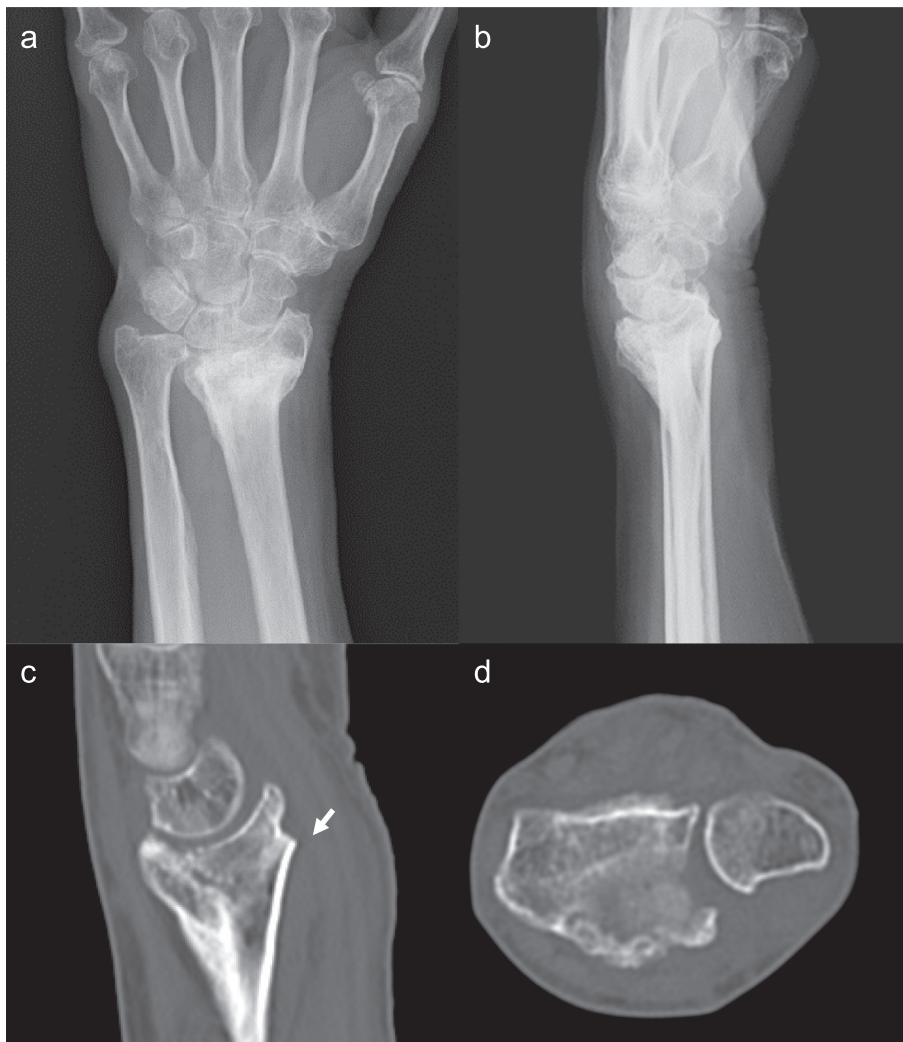

Fig. 1. a and b Posteroanterior and lateral view radiographs of the left wrist of the Case 1, showing dorsally malunited distal radius fracture with 25° of dorsal tilt and 8 mm of positive ulnar variance. c Sagittal view CT of the left wrist, showing the bony prominence at the palmar surface of the distal radius (indicated by white arrow). d Axial view CT shows no palmar dislocation of the ulnar head.

of the distal interphalangeal (DIP) joint of the index finger and was referred to our hospital. Her left wrist had swelling and moderate pain, and wrist pain increased with excessive usage of the hand. Grip strength of the affected hand was 7.3 kg, which was 41% of the contralateral side (17.8 kg), and the range of motion (ROM) of the wrist and forearm were extension 55°, flexion 25°, supination 85°, and pronation 60°, respectively. Visual analog scale (VAS) of pain in the wrist was 70 (range; 0–100). Radiography and computed tomography (CT) revealed dorsally malunited distal radius fracture with bony prominence at the fracture site of the radius (Fig. 1). She had no autoimmune disease, e.g. rheumatoid arthritis.

Surgical exploration revealed that the bony prominence of the distal radius was located distal to the pronator quadratus muscle, and the index FDP tendon was torn over the prominence, but both ends of the ruptured tendon were connected by the synovial tissue (Fig. 2). In addition, the flexor pollicis longus (FPL) tendon and the middle FDP tendon were partially frayed around the bony prominence. This indicated that repetitive attrition with the bony prominence was the main cause of tendon rupture. Open wedge osteotomy with palmar locking plate (Variable Angle LCP Two-Column Volar Distal Radius Plate 2.4., DePuy Synthes, West Chester, PA, USA) and a β -tricalcium phosphate artificial bone graft was performed. Then, tendon transfer, whereby the distal stump of the index FDP tendon was sutured to the middle FDP tendon, was performed in an end-to-side fashion. Rigid fixation with palmar locking plate allowed the patient to undergo early postoperative rehabilitation. Twelve months after surgical reconstruction, active flexion of the DIP joint of the index finger was full, grip strength of the affected hand was 16.0 kg, and ROM of the wrist and forearm were extension 55°, flexion 40°, supination 85°, and pronation 60° (Fig. 3). The Disabilities of the Arm, Shoulder and Hand (DASH) score was 2.59 and VAS of pain in the wrist was 0.

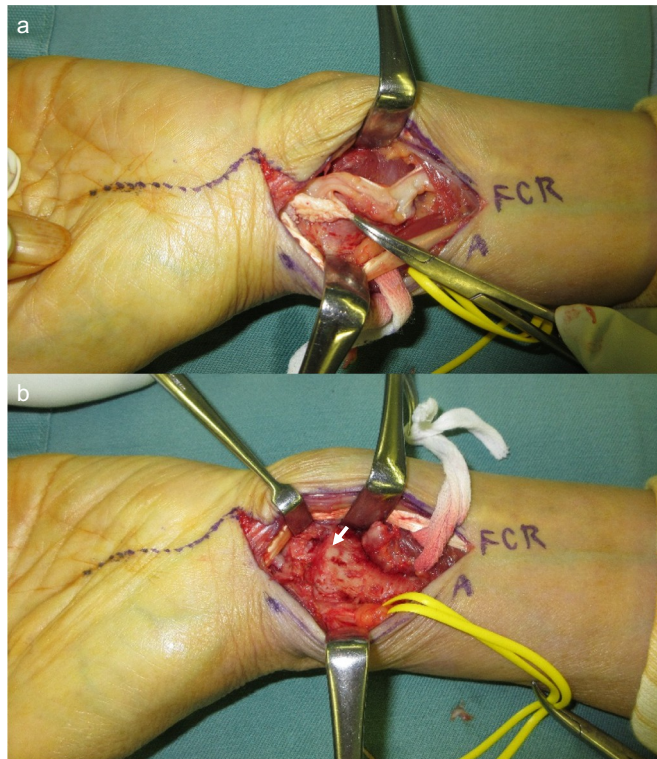


Fig. 2. Intraoperative macropictures of the Case 1 during surgical reconstruction. a Complete rupture of the index FDP was observed, and both ends of ruptured tendon were continued with synovial tissue. b Bony prominence at the palmar surface of the distal radius exists over the ruptured tendon (indicated by white arrow).

Case 2

A 69-year-old female felt painful swelling of the left wrist and an inability to flex her ring and little finger, and visited our hospital. She had Sjögren syndrome and a history of a distal radius fracture 14 years ago, which had been treated with cast immobilization. Physical examination revealed the loss of flexion of the ring and little finger. Grip strength of the affected hand decreased to 7.1 kg, which was 51% of the contralateral side (13.8 kg). The ROM of the wrist and forearm were extension 70°, flexion 35°, supination 85°, and pronation 85°, respectively. Radiograph and CT demonstrated a dorsally malunited distal radius fracture without bony spur of the radius and palmar dislocation of the ulnar head (Fig. 4). The patient was diagnosed with tendon ruptures of the ring and little FDP and FDS caused by a palmarly dislocated ulnar head. Surgical exploration revealed that the rupture of volar capsule of distal radioulnar joint (DRUJ) and palmarly displaced ulnar head, and the middle, ring and little FDP and the ring and little FDP tendons were torn over the ulnar head at the position of finger flexion (Fig. 5). These findings indicated that repetitive attrition with the palmarly displaced ulnar head was the main cause of tendon rupture. Darrach procedure was performed, followed by tendon transfer toward middle FDS tendon for ruptured middle and ring FDP tendons and tendon graft using palmaris longs for ruptured little FDP tendons. Five months after surgical reconstruction, % total active motion of middle, ring and little finger were 120°, 108° and 88°, respectively. Grip strength of the affected hand was 5.7 kg, and ROM of the wrist and forearm were extension 40°, flexion 40°, supination 90°, and pronation 80° (Fig. 6). DASH score was 25.0 and VAS of pain in the wrist was 0.

Discussion

Rupture of the flexor tendons is a rare complication following distal radius malunion after nonoperative management. To date, 27 cases of delayed tendon ruptures (> 4 weeks after injury) have been reported in 23 English articles [4–23,28–30]. We evaluated a total of 29 cases including our reported 2 cases (Table 1) and investigated the mechanism, characteristics, operative management, and outcomes of this complication.

The mean age of 29 cases was 61.8 years (range 15 to 90), and the time from injury to the tendon rupture varied from 1 month to 44 years. The 29 cases we analyzed involved a total of 95 flexor tendon ruptures, including 12 FPLs, 15 index FDPs, 9 middle FDPs, 12

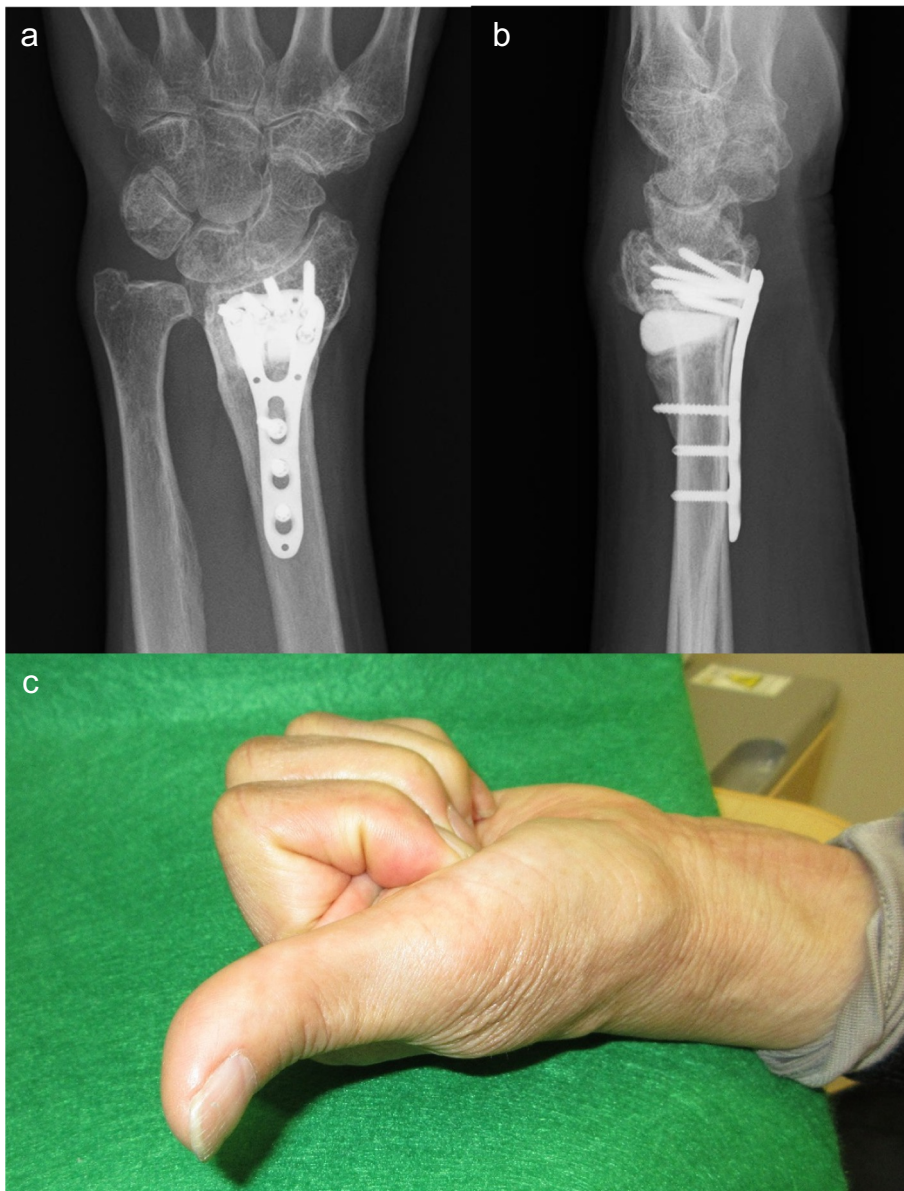


Fig. 3. a and b Postoperative posteroanterior and lateral view radiographs of the left wrist of the Case 1 at 12 months follow-up after corrective osteotomy of the distal radius, showing well-corrected distal radius with 5° of palmar tilt and 1 mm of positive ulnar variance. c Macropicture of the Case 1 after tendon transfer at 12 months follow-up.

ring FDPs, 12 little FDPs, 8 index FDSs, 7 middle FDSs, 10 ring FDSs, and 10 little FDSs (Fig. 7). Although not significant, ruptures of radial flexor tendons tended to occur earlier than ulnar flexor tendon ruptures. According to the previous literature, the main causes of delayed flexor tendon ruptures are “the bony spike at the palmar aspect of the distal radius”, “palmarly displaced ulnar head”, or both simultaneously [23]. As a result of statistical analysis, radial bony spike caused tendon ruptures significantly earlier than palmarly displaced ulnar head (Fig. 7). Consistent with our statistical result, some authors have suggested that cases with “the bony spike at the palmar aspect of the distal radius” harbored radial flexor tendon ruptures, whereas cases with “palmarly displaced ulnar head” harbored ulnar flexor tendon ruptures, moreover a much longer time for onset of tendon rupture is observed owing to the relative smoothness of the displaced ulnar head compared to the sharp spur of the distal radius [16,18,22].

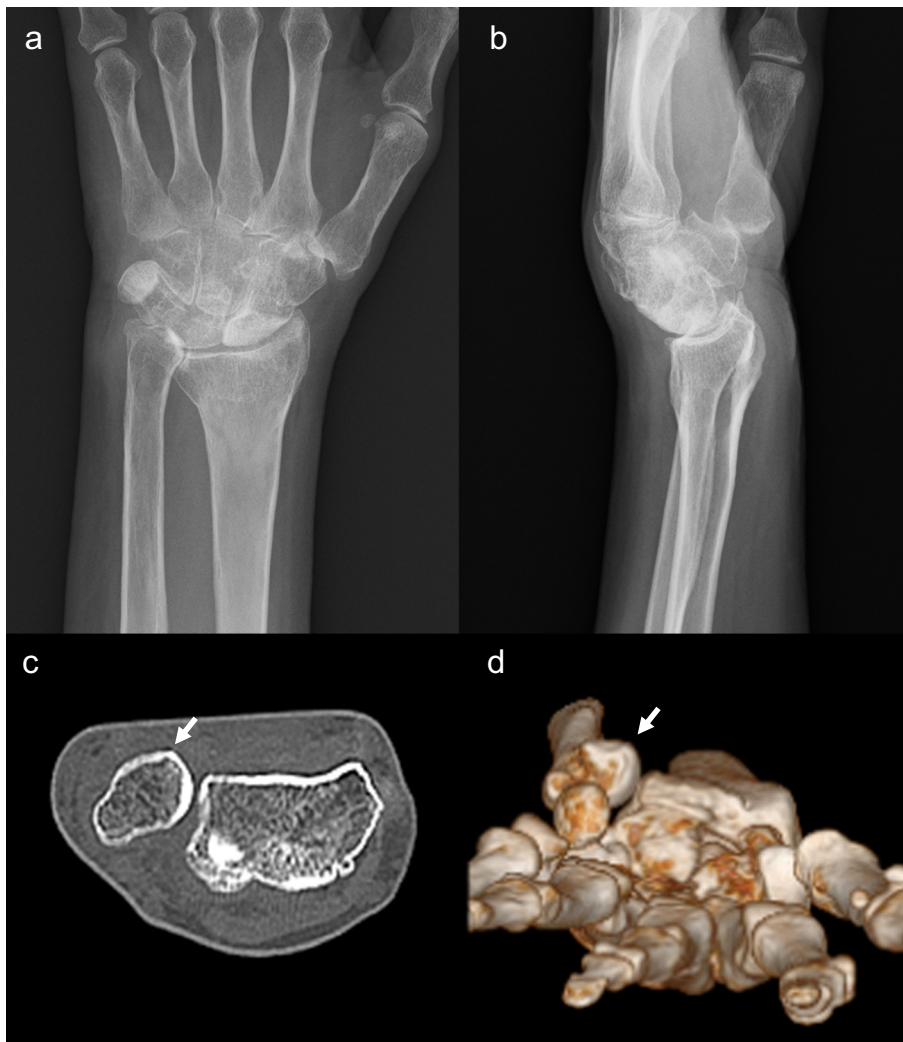


Fig. 4. a and b Posteroanterior and lateral view radiographs of the left wrist of the Case 1, showing dorsally malunited distal radius fracture with 40° of dorsal tilt and 6 mm of positive ulnar variance. c and d Axial view CT and 3D-CT image of the left wrist, showing the palmarly displaced ulnar head (indicated by white arrow).

This disorder generally needs two kinds of surgery. One is reconstruction of the ruptured tendons, and the other is osseous surgery for the bony abnormality associated with malunion which caused the tendon rupture. [Table 1](#) shows that 26 cases were available for analysis regarding tendon reconstruction. In the cases of single tendon rupture, tendon transfer, as well as tendon grafts were performed. More than half of the cases contained multiple tendon ruptures; therefore, a combination of tendon repair, transfer, and graft was often required. The tendon graft was mostly harvested from the palmaris longus, but sometimes harvested from concomitantly ruptured FDS tendons. Both tendon transfer and tendon graft produced comparable results, and there was no consensus regarding a superior procedure for reconstruction. Most of the patients were elderly people; therefore, a simple procedure with easy rehabilitation might be preferable. Indeed, poor results were related to the number of ruptured tendons rather than the surgical procedure. In particular, patients who sustained ruptures of all FDPs and FDSs had a poor prognosis, while patients with one or two ruptured tendons obtained good outcomes [8,14,22,23]. Consistent with this evidence, our Case 1 acquired excellent outcome, whereas Case 2 did not. Considering that progressive tendon rupture could occur in this pathological condition, early reconstruction would be desirable.

Regarding osseous surgery, 22 cases were available for analysis ([Table 1](#)). Of 8 operations for the ulnar head, 6 used the Darrach

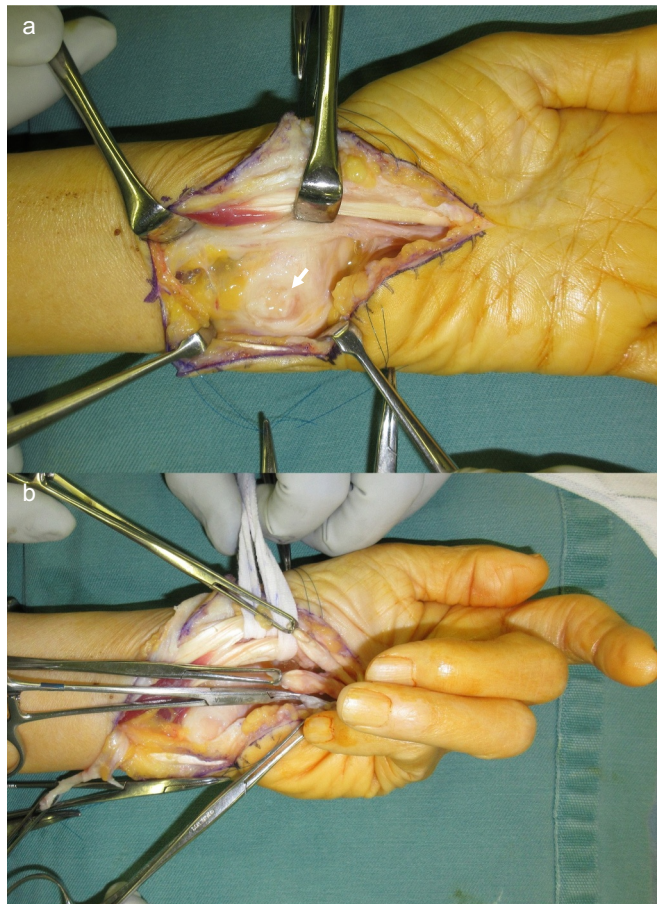


Fig. 5. a and b Intraoperative macropictures of the Case 2 during surgical reconstruction. a Rupture of the volar capsule of the DRUJ and palmarly displaced ulnar head were observed (indicated by white arrow). b. Rupture of the middle, ring and little FDPs and ring and little FDSs was observed.

procedure, including our Case 2 [5,10,14,16,19,21,23], 1 used the Sauve-Kapandji procedure [21], and 1 used debridement of the osteophyte [10]. By contrast, of 14 operations for the radius, 10 used only excision of the bony spike [9,11–13,15,17,20,22,28], and 4 used corrective osteotomy of the distal radius, including our Case 1 [7,20,21]. In one case reported by Murase and Hiroshima, excision of the hook of the hamate was performed because tendon ruptures were caused by friction with the hook, which resulted from malalignment after distal radius fracture [18]. For the rehabilitation of reconstructed tendons, osseous surgeries requiring prolonged immobilization would not be preferable. Most patients with tendon ruptures associated with a palmarly displaced ulnar head complained of wrist pain due to DRUJ arthritis [5,14,16,21,23]. Therefore, a Darrach or Sauve-Kapandji procedure would be appropriate for the relief of wrist pain and the prevention of additional tendon ruptures. Most of the patients with a dorsally malunited radius underwent simple excision of the bony spike of the radius and achieved a good outcome [9,11–13,15,17,20,28]. Therefore, corrective osteotomy of the malunited radius would not be necessary for patients not complaining of wrist pain, limitation of wrist motion, and numbness of the fingers (carpal tunnel syndrome). If we perform corrective osteotomy, rigid fixation with locking plates would be desirable. Importantly, great care should be taken for prevention of implant-induced tendon ruptures because the current article demonstrates that both palmar locking plating and low-profile dorsal locking plating carry equivalent risk of extensor and flexor tendon ruptures [32].

Nevertheless, our study was limited by its retrospective nature and involved a review of previous case reports. In addition, treatment strategies were different for each case. However, because of the rareness of this disorder, it would be difficult to undertake a prospective analysis even in a multicenter setting. We hope that our report provides helpful information for clinicians treating this complication.

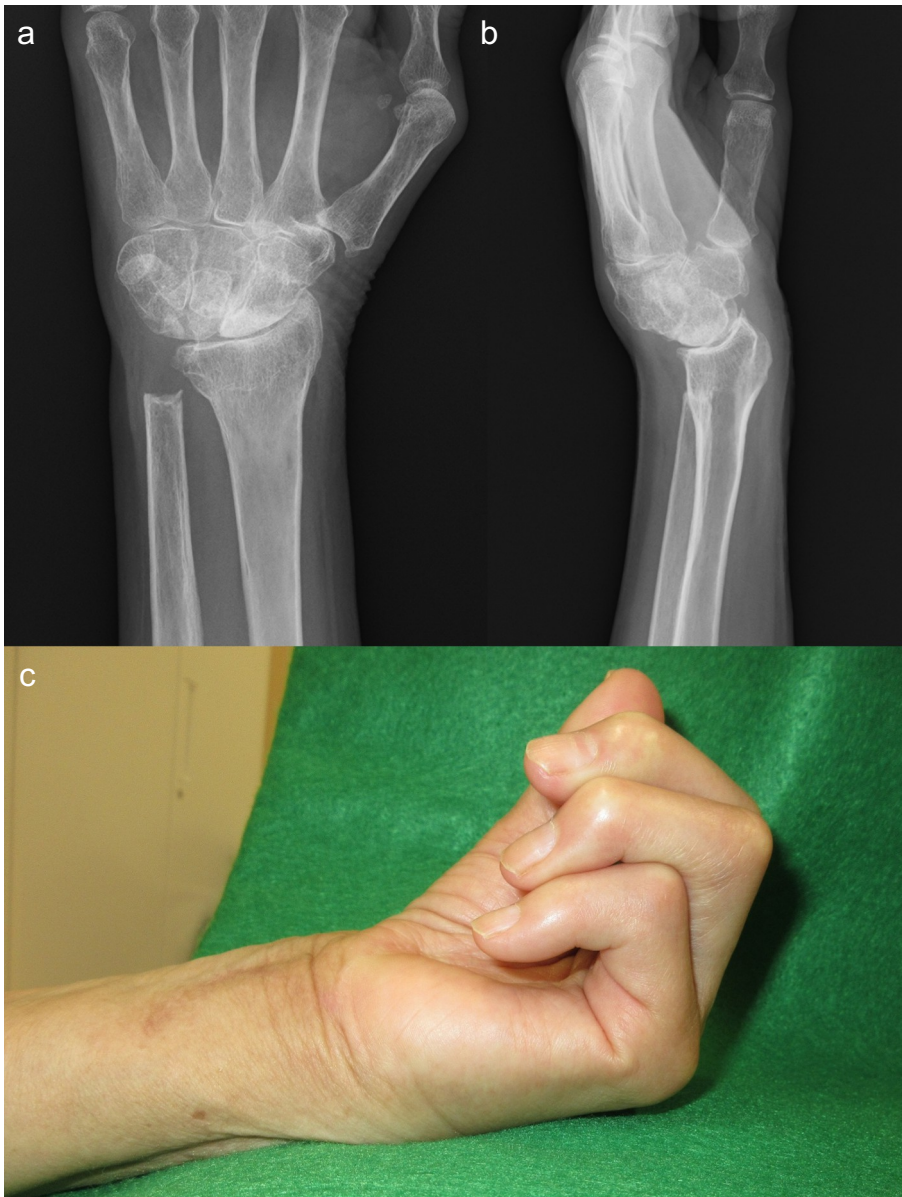


Fig. 6. a and b Postoperative posteroanterior and lateral view radiographs of the left wrist of the Case 2 at 5 months follow-up after Darrach procedure. c Macropicture of the Case 2 after tendon reconstruction at 5 months follow-up.

Conclusions

We have reported 2 cases of delayed rupture of the flexor tendons following malunited distal radius fracture after nonoperative treatment. Surgical reconstruction (i.e., tendon transfer or tendon graft) of the ruptured tendon will provide a good outcome if the number of tendon ruptures is small. If multiple tendon ruptures are present, the surgical outcome may be poor despite surgical reconstruction. Osseous surgery would be necessary to prevent additional tendon ruptures. However, considering that most of the patients are generally elderly people, a less invasive and simple procedure with easy rehabilitation would be preferable.

Table 1
The summarized list of the previous literature.

	First author	Year	Age	Sex	Ruptured tendon	Time from injury to tendon rupture (months)	Cause of tendon rupture	Palmar bony spike of distal radius	Palmar displacement of ulnar head	Surgery for the bone	Reconstruction of the tendons	Postoperative follow up (months)
1	McMaster	1932	35	M	FPL	4	Abrasion over bony prominence at the palmar aspect of the radius	Yes	No	None	Repair: FPL	20
2	Broder	1954	71	M	FDP(3, 4, 5), FDS(4, 5)	24	Palmar displacement of the ulnar head/palmar bony projection of the distal radius	Yes	Yes	None	Graft(FDS); FDP(3, 4, 5)	2
3	Younger	1977	60	F	FDP(5), FDS(4, 5)	12	Eroded ulnar head through the palmar capsule	No	Yes	Darrach	Transfer: FDP(common origin)-FDP(5)	-
4	Cooney	1980	-	-	FPL	3	Bone fragment from displaced fracture	-	-	-	-	-
5	Cooney	1980	-	-	FDP(2)	3	Bone fragment from displaced fracture	-	-	-	-	-
6	Wong	1984	60	M	FPL, FDP(2)	1	Sharp bony spike of the radius	Yes	No	Corrective osteotomy (radius)	None	-
7	Diamond	1987	77	F	FPL, FDP(2, 3, 4), FDS(2, 3, 4, 5)	5	Tendon blood supply was compromised by prolonged pressure over a malunited fracture	No	No	None	Graft(PL); FPL/Repair: FDP(2, 3, 4)	2
8	Rymaszewski	1987	18	M	FDP(2)	8	Bony prominence at the palmar aspect of the radius	Yes	No	Excision of bony spike (radius)	Transfer: FDP(3)-FDP(2)	-
9	Minami	1989	83	F	FDP(3, 4, 5), FDS(4, 5)	528	Sharp spicle bone of the distal part of palmar displaced ulnar head	Yes	Yes	Osseous debridement of ulnar head	Graft(PL & FDS5); FDP(3, 4, 5)	24
10	Roberts	1990	17	M	FPL	2	Sharp bony spur protruded from the lower end of the radius	Yes	No	Excision of bony spike (radius)	Graft(PL);FPL	6
11	Ashall	1991	18	M	FPL	2.5	Bony step at the radial epiphysis	Yes	No	Excision of bony spike (radius)	Transfer: FDS(4)-FPL	1.5
12	Egawa	1993	56	-	FPL	96	-	-	-	-	-	-
13	Santana	1993	15	F	FDP(2), FDS(2, 3)	1.5	Bony prominence of distal radius fracture	Yes	No	Excision of bony spike (radius)	Repair: FDP(2)	1.5
14	Van Loon	1997	62	F	FDP(2, 3, 4, 5), FDS(2, 3, 4, 5)	204	Sharp anterior edge of the anterior dislocated ulnar head	No	Yes	Darrach	Graft(FDS); FDS(2), FDP(3, 4, 5)	-
15	Takami	1997	49	M	FPL, FDP(2)	360	Bony prominence at the palmar rim of the distal radius	Yes	No	Excision of bony spike (radius)	Graft(PL); FPL, FDP(2)	24
16	Wada	1999	74	F	FDP(4, 5), FDS(3, 4, 5)	300	Palmar displacement of the ulnar head	No	Yes	Darrach	Graft(PL); FDP(4, 5)	5
17	Kato	2002	80	F	FDP(2), FDS(2)	240	Sharp bony protuberance on the distal end of radius	Yes	No	Excision of bony spike (radius)	Transfer: FDS(4)-FDP(2)/Reinforce: FDS(3), FDP(3)	3
18	Kato	2002	71	M	FPL, FDP(2)	24	Sharp bony protuberance on the distal end of radius	Yes	No	Excision of bony spike (radius)	Transfer: FDS(4)-FPL/Graft(PL); FDP(2)	6

(continued on next page)

Table 1 (continued)

First author	Year	Age	Sex	Ruptured tendon	Time from injury to tendon rupture (months)	Cause of tendon rupture	Palmar bony spike of distal radius	Palmar displacement of ulnar head	Surgery for the bone	Reconstruction of the tendons	Postoperative follow up (months)
19 Murase	2003	80	F	FDP(4, 5)	120	Friction between the deep flexor tendons and the hook of the hamate, a result of malalignment of the distal radius	No	No	Excision of the hook of the hamate	Transfer: FDS(4)-FDP(4)/Graft(PL); FDP(5)	4
20 Lamas	2004	77	F	FDP(2, 3, 4, 5), FDS(2, 3, 4, 5)	72	Palmar displacement of the ulnar head/dorsally displaced distal radius	No	Yes	Darrach	Transfer: FCR-FDP(2,3)/Graft(PL); FDP(4,5)	-
21 Suppaphol	2007	70	F	FPL	1.5	Acute rupture at the time of injury	-	-	Open wedge osteotomy (VLP) & corticocancellous iliac bone graft	Transfer: FDS(4)-FPL	3
22 Suppaphol	2007	71	F	FPL, FDP(2, 3), FDS(2)	15	Sharp anterior bony spur at the malunion site of distal radius	Yes	Yes	Excision of bony spike (radius)	Transfer: FDS(4)-FDP(2), FDP(4,5)-FDP(3)/Arthrodesis: thumb IPJ	3
23 Ishii	2009	62	F	FDP(2)	48	Sharp bony protrusion at the palmar joint rim in the distal radius	Yes	Yes	Closed wedge osteotomy (VLP) & Sauve-Kapandji	Graft(PL); FDP(2)	16
24 Iyer	2012	90	F	FPL, FDP(2, 3, 4, 5), FDS(2, 3, 4, 5)	6	Sharp bony spur associated with the distal radius fracture	Yes	No	Excision of bony spike (radius)	Graft(FDS); FDP(2,3,4,5)/Repair: FPL	9
25 Proubasta	2014	84	F	FDP(2, 3, 4, 5), FDS(2, 3, 4, 5)	480	Palmarly displaced ulnar head	No	Yes	Darrach	Transfer: FCR-FDP(2, 3, 4)/Graft(PL); FDP(5)	12
26 HuH	2014	74	F	FDP(4, 5)	480	Palmarly displaced ulnar head	No	Yes	None	Transfer: FDP(3)-FDP(4,5)	3
27 HuH	2014	71	F	FDP(4, 5)	48	Excessive prominence of the distal radius palmar tip	Yes	No	Excision of bony spike (radius)	Transfer: FDP(3)-FDP(4,5)	3
28 Present case (Case 1)	2019	74	F	FDP(2)	5.5	Abrasion over bony prominence at the palmar aspect of the radius	Yes	No	Open wedge osteotomy (VLP) + β -TCP	Transfer: FDP(3)-FDP(2)	12
29 Present case (Case 2)	2019	69	F	FDP(3, 4, 5), FDS(4, 5)	168	Palmarly displaced ulnar head	No	Yes	Darrach	Transfer: FDS(3)-FDP(3,4)/Graft(PL); FDP5	5

M = male; F = female; FPL = flexor pollicis longus; FDP = flexor digitorum profundus; FDS = flexor digitorum superficialis; CTS = carpal tunnel syndrome; Ext = extension; Flex = flexion; Sup = supination; Pro = pronation.

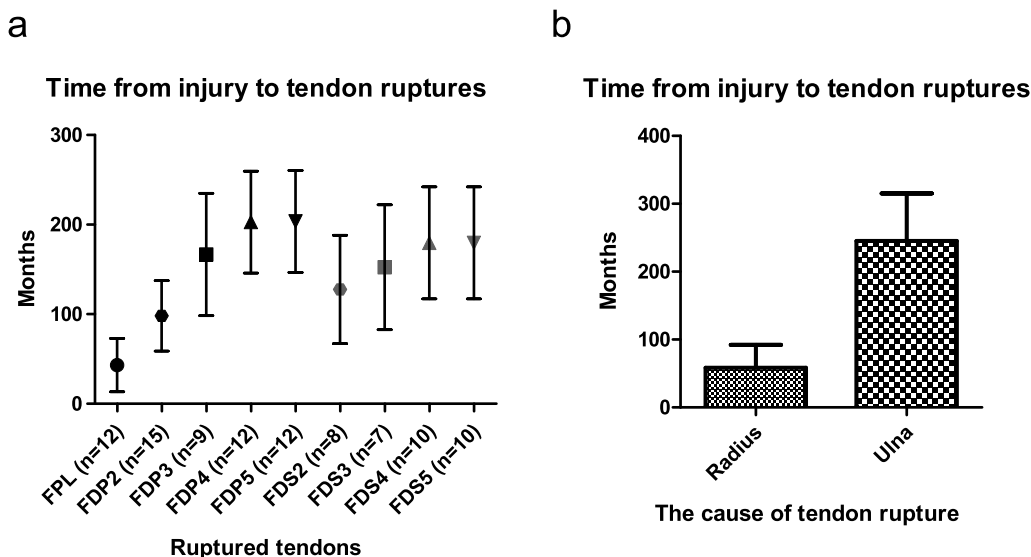


Fig. 7. Statistical analysis of 29 patients in Table 1. Data are presented as means \pm SEM and values for $P < 0.05$ indicated statistical significance. Statistical analysis was performed by GraphPad Prism 7.03. a Radial side tendons (i.e. FPL or index FDP) tend to tear earlier than ulnar side tendons. Kruskal-Wallis test demonstrates that location of the ruptured tendon is not significantly correlated with the time from injury to tendon rupture ($P = 0.0513$). b Palmar dislocation of ulnar head requires significantly longer period for tendon ruptures than bony spike of the radius by Mann-Whitney test ($P = 0.0099$).

Acknowledgements

The authors report no benefits, grants, or assistance from any party.

Conflict of interest

The authors declare that they have no conflict of interest.

Ethical consideration

This article does not contain any studies with human participants or animals performed by any of the authors.

Informed consent

Informed consent was obtained from the patients.

References

- [1] R. Thorninger, M.L. Madsen, D. Wæver, L.C. Borris, J.H.D. Rölfing, Complications of volar locking plating of distal radius fractures in 576 patients with 3.2 years follow-up, *Injury* 48 (2017) 1104–1109.
- [2] L. Tarallo, R. Mugnai, F. Zambianchi, R. Adani, F. Catani, Volar plate fixation for the treatment of distal radius fractures: analysis of adverse events, *J. Orthop. Trauma* 27 (2013) 740–745.
- [3] M. Soong, R. van Leerdam, T.G. Guitton, C. Got, J. Katarincic, D. Ring, Fracture of the distal radius: risk factors for complications after locked volar plate fixation, *J. Hand Surg. [Am.]* 36 (2011) 3–9.
- [4] H. Broder, Rupture of flexor tendons, associated with a malunited Colles' fracture, *J. Bone Joint Surg. Am.* 36 (1954) 404–405.
- [5] C.P. Younger, J.C. DeFiore, Rupture of flexor tendons to the fingers after a colles fracture: a case report, *J. Bone Joint Surg. Am.* 59 (1977) 828–829.
- [6] W.P. Cooney, J.H. Dobyns, R.L. Linscheid, Complications of Colles' fractures, *J. Bone Joint Surg. Am.* 62 (1980) 613–619.
- [7] F.Y. Wong, R.W. Pho, Median nerve compression, with tendon ruptures, after Colles' fracture, *J. Hand Surg. (Br.)* 9 (1984) 139–141.
- [8] J.P. Diamond, J.H. Newman, Multiple flexor tendon ruptures following Colles' fracture: a case report, *J. Hand Surg. (Br.)* 12 (1987) 112–114.
- [9] L.A. Rymaszewski, A.P. Walker, Rupture of flexor digitorum profundus to the index finger after a distal radial fracture, *J. Hand Surg. (Br.)* 12 (1987) 115–116.
- [10] A. Minami, T. Ogino, H. Tohyama, Multiple ruptures of flexor tendons due to hypertrophic change at the distal radio-ulnar joint. A case report, *J. Bone Joint Surg. Am.* 71 (1989) 300–302.
- [11] J.O. Roberts, P.J. Regan, A.H. Roberts, Rupture of flexor pollicis longus as a complication of Colles' fracture: a case report, *J. Hand Surg. (Br.)* 15 (1990) 370–372.
- [12] G. Ashall, Flexor pollicis longus rupture after fracture of the distal radius, *Injury* 22 (1991) 153–155.
- [13] D.R. Santana, L. Deliss, Attrition rupture of flexor tendons at the wrist following epiphyseal fracture of the distal radius, *J. Hand Surg. (Br.)* 18 (1993) 585–587.
- [14] J. Van Loon, L. De Smet, G. Fabry, Rupture of all finger flexor tendons 17 years after a colles fracture: a case report, *J. Hand Surg. [Am.]* 22 (1997) 263–265.
- [15] H. Takami, S. Takahashi, M. Ando, Attritional flexor tendon ruptures after a malunited intra-articular fracture of the distal radius, *Arch. Orthop. Trauma Surg.* 116 (1997) 507–509.

- [16] A. Wada, F. Ihara, H. Senba, S. Nomura, Attritional flexor tendon ruptures due to distal radius fracture and associated with volar displacement of the distal ulna: a case report, *J. Hand. Surg. [Am.]* 24 (1999) 534–537.
- [17] N. Kato, K. Nemoto, H. Arino, T. Ichikawa, K. Fujikawa, Ruptures of flexor tendons at the wrist as a complication of fracture of the distal radius, *Scand. J. Plast. Reconstr. Surg. Hand Surg.* 36 (2002) 245–248.
- [18] T. Murase, K. Hiroshima, Rupture of the flexor tendon after malunited Colles' fracture, *Scand. J. Plast. Reconstr. Surg. Hand Surg.* 37 (2003) 188–191.
- [19] C. Lamas, I. Proubasta, J. Itarte, A. Peiró, J. Majó, Rupture of all the flexor tendons in the hand due to malunion of a distal radius fracture, *Chir. Main* 23 (2004) 45–48.
- [20] S. Suppaphol, P. Woratanarat, T. Channoom, Flexor tendon rupture after distal radius fracture. Report of 2 cases, *J. Med. Assoc. Thail.* 90 (2007) 2695–2698.
- [21] T. Ishii, M. Ikeda, Y. Kobayashi, J. Mochida, Y. Oka, Flexor digitorum profundus tendon rupture associated with distal radius fracture malunion: a case report, *Hand Surg.* 14 (2009) 35–38.
- [22] S. Iyer, I. Basu, R. Kaba, A. Pabari, Rupture of all digital flexors following Colles' fracture, *J. Plast. Reconstr. Aesthet. Surg.* 65 (2012) e290–e292.
- [23] I.R. Proubasta, C.G. Lamas, L. Natera, N. Arriaga, Delayed rupture of all finger flexor tendons (excluding thumb) following nonoperative treatment of Colles' fracture: a case report and literature review, *J. Orthop.* 12 (2015) S65–S68.
- [24] W.W. Southmayd, L.H. Millender, E.A. Nalebuff, Rupture of the flexor tendons of the index finger after Colles' fracture. Case report, *J. Bone Joint Surg. Am.* 57 (1975) 562–563.
- [25] J.R. Hill, R.K. Alluri, A. Ghiassi, Acute isolated flexor tendon laceration associated with a distal radius fracture, *Hand (N Y)* 12 (2017) NP39–NP42.
- [26] L. DiMatteo, J.M. Wolf, Flexor carpi radialis tendon rupture as a complication of a closed distal radius fracture: a case report, *J. Hand. Surg. [Am.]* 32 (2007) 818–820.
- [27] P.J. Chen, A.L. Liu, Concurrent flexor carpi radialis tendon rupture and closed distal radius fracture, *BMJ Case Rep.* 10 (2014).
- [28] S.W. Huh, W.L. Jo, J.Y. Lee, Rupture of flexor tendons as a complication of a distal radius fracture, *J. Plast. Surg. Hand Surg.* 48 (2014) 350–352.
- [29] H. Egawa, Y. Toge, M. Hayashi, S. Danjo, S. Kawahara, Subcutaneous rupture of the flexor tendon, *J. Jpn. Soc. Surg. Hand* 10 (1993) 251–254.
- [30] P.E. McMaster, Late ruptures of extensor and flexor pollicis longus tendons following Colles' fracture, *J. Bone Joint Surg.* 14 (1932) 93–101.
- [31] J.H. Boyes, J.N. Wilson, J.W. Smith, Flexor-tendon ruptures in the forearm and hand, *J. Bone Joint Surg. Am.* 42 (1960) 637–646.
- [32] Y.R. Yu, M.C. Makhni, S. Tabrizi, T.D. Rozental, G. Mundanthanam, C.S. Day, Complications of low-profile dorsal versus volar locking plates in the distal radius: a comparative study, *J. Hand. Surg. [Am.]* 36 (2011) 1135–1141.