

Effects of Dexamethasone Implant on Multifocal Electroretinography in Central Retinal Vein Occlusion

Muhammed Nurullah Bulut, MD; Ümit Çallı, MD; Güzide Akçay, MD; Ulviye Kıvrak, MD
Kezban Bulut, MD; Yusuf Özertürk, MD

Sağlık Bilimleri University Dr. Lütfi Kırdar Kartal Education and Research Hospital Eye Department, Istanbul, Turkey

Abstract

Purpose: To investigate the effect of Ozurdex (dexamethasone intravitreal implant) on multifocal electroretinography (mfERG) findings during the treatment of macular edema secondary to the central retinal vein occlusion (CRVO).

Methods: Fifteen eyes of 15 patients who were treated with Ozurdex implant due to CRVO-related macular edema were included in this study. Best corrected visual acuity (BCVA), central macular thickness (CMT), and mfERG evaluations were performed for all patients before injection of Ozurdex. After the injection, BCVA and CMT were measured at months 3 and 6 and mfERG test was performed at month 6 for all patients.

Results: Pre-implantation mfERG P wave amplitude values of r1, r2, r3, r4 and r5 were 57.8 ± 14.8 , 25.1 ± 10.6 , 17.2 ± 7.3 , 12.0 ± 5.0 and 7.1 ± 3.6 nV/deg², respectively. They increased to 72.9 ± 33.2 , 31.2 ± 9.3 , 22.6 ± 7.6 , 15.6 ± 7.1 and 10.9 ± 5.7 nV/deg², respectively, at month 6. However, these increases were not statistically significant (all $P > 0.05$). Pre-implantation mfERG r1, r2, r3, r4 and r5 P wave implicit times were 40.1 ± 10.9 , 39.4 ± 3 , 38.4 ± 3.4 , 38.2 ± 3.1 and 39.3 ± 2.2 ms, respectively and these values were measured as 38.9 ± 8.2 , 38.4 ± 4.7 , 37 ± 3.8 , 37.5 ± 4.6 and 37.7 ± 4.7 ms at 6 months. Although there were reductions in P wave implicit times in all rings, they were not statistically significant (all $P > 0.05$).

Conclusion: In this prospective study, we found that the Ozurdex implant had no effect on mfERG findings 6 months after insertion for treatment of CRVO-related macular edema.

Keywords: Multifocal Electroretinography; Ozurdex; Vein Occlusion

J Ophthalmic Vis Res 2018; 13 (1): 23-28

INTRODUCTION

Retinal vein occlusion (RVO) is the second most common retinal vascular disease after diabetic retinopathy.^[1] The most common type is branch RVO (BRVO) with a

prevalence of 0.6-1.1%, followed by central RVO (CRVO) with a prevalence of 0.1-0.4%.^[2,3] BRVO usually has a better prognosis in terms of visual acuity.^[4,5] Randomized controlled studies of RVO treatment methods have shown that repeated therapy with laser photocoagulation,^[6] anti-vascular endothelial growth factor,^[7] triamcinolone acetonide^[8] and dexamethasone implant^[9] can control macular edema, prevent neovascularization and provide better visual acuity levels.

Intravitreal dexamethasone implant (Ozurdex®, Allergan Inc., Irvine, California, USA) is a biodegradable

This is an open access article distributed under the terms of the Creative Commons Attribution-NonCommercial-ShareAlike 3.0 License, which allows others to remix, tweak, and build upon the work non-commercially, as long as the author is credited and the new creations are licensed under the identical terms.

For reprints contact: reprints@medknow.com

Correspondence to:

Muhammed Nurullah Bulut, MD. Sağlık Bilimleri University Dr. Lütfi Kırdar Kartal Education and Research Hospital Eye Department, Istanbul 34865, Turkey. E-mail: nurullahbulut@hotmail.com

Received: 21-06-2016

Accepted: 16-07-2017

Access this article online

Quick Response Code:



Website:

www.jovr.org

DOI:

10.4103/jovr.jovr_118_16

How to cite this article: Bulut MN, Çallı Ü, Akçay G, Kıvrak U, Bulut K, Özertürk Y. Effects of dexamethasone implant on multifocal electroretinography in central retinal vein occlusion. *J Ophthalmic Vis Res* 2018;13:23-8.

copolymer of micronized dexamethasone and polylactic acid with glycolic acid that dissolves completely *in vivo* and is eventually converted to carbon dioxide and water.^[10] Several studies demonstrated that Ozurdex could reduce macular edema and that its effect continued for six months.^[11]

Electroretinography (ERG) has been widely used to identify the functional effects of many retinal diseases.^[12] After its initial introduction by Sutter and Tren in 1992,^[13] ERG has been used to evaluate the functional effects of many retinal diseases. Multifocal (mf) ERG, which demonstrates the functional effects of the inner retinal layers between the retinal vascular arcades,^[14] has been utilized to show RVO-related retinal dysfunction.^[15]

The aim of the present study is to investigate the effect of intravitreal Ozurdex on mfERG findings 6 months after treatment of macular edema associated with CRVO.

METHODS

Study Participants

Fifteen eyes of 15 patients who were treated with Ozurdex implant due to CRVO-related macular edema in the Ophthalmology Department of the Kartal Education and Research Hospital between November 2013 and November 2014 were included in this prospective study. Treatment naive patients with a disease duration of no more than 12 weeks were included in the study. Exclusion criteria were history of previous intraocular surgery, peripheral and macular ischemia on fundus fluorescein angiography, previous intravitreal injection, and a history of systemic disease other than hypertension. The study was conducted in accordance with the rules of the Declaration of Helsinki and the approval of the local ethics committee was obtained. All patients were informed about the study procedure and risks of the treatment and informed consent forms were obtained.

Implantation Technique of Ozurdex

Ozurdex (dexamethasone 0.7 mg) implant was injected into each eye intravitreally with its special applicator, from the pars plana region, in the operating room, and under sterile conditions. After the injection, topical antibiotics were given five times a day for one week.

Study Protocol

Baseline best corrected visual acuity (BCVA; by Snellen chart converted to logMAR), intraocular pressure (IOP; by Goldmann applanation tonometer) and mfERG evaluations were performed for all patients before the injection of Ozurdex. IOP was measured again at 1 week and at 1, 3 and 6 months after injection. BCVA and CMT were measured at 3-6 months and mfERG was repeated at 6 months after injection for all patients.

CMT

Macular thickness assessment was performed using third generation OCT (Optos, PLC, Dumpherrline, Scotland), which is a combination of OCT and scanning laser ophthalmoscope (SLO) designed to image vitreo-retinal, retinal and choroidal-retinal structures. Images were acquired in 20 micron sections from a 29 degree area of the fundus at 32 images per minute. Images with SLO quality of 0.7 or higher were included in the analysis.

mfERG Measurements

mfERG was performed according to the guidelines of the International Society for Clinical Electrophysiology of Vision^[16] using RETI Scan multifocal system (Roland-Consult, Brandenburg, Germany). The viewing distance was 26 cm with a viewing angle of approximately 30°. The stimulus consisted of 61 hexagons. The disposable Dawson Trick Litzkow (DTL) electrode was preferred for records. The reference electrode was placed on the glabellar region and the active electrodes were placed on canthus. Pupils were dilated with 1% tropicamide for all of the measurements. Measurements were performed after near addition to the other refractive error corrections. P wave amplitude and P wave implicit times were taken into consideration during evaluation. P wave amplitude was measured as the highest positive wavelength and P implicit time was measured as time interval between negative and positive peak points. P wave amplitude values and P wave implicit times were analyzed in rings [Figure 1].

Statistical Analysis

IBM SPSS Statistics for Windows, Version 22.0. (IBM Corp. Armonk, NY: USA.) software was used for statistical analyses. Comparisons of mean BCVA and CMT were performed using repeated measures ANOVA and the Bonferroni *post hoc* test; comparison of P wave amplitudes and implicit times were performed using the Wilcoxon signed-rank test. Statistical significance was set at $P < 0.05$. Correlations between BCVA, CMT and mfERG P wave amplitudes and implicit times were evaluated using the Spearman correlation analysis.

RESULTS

The mean age of the patients was 55.6 ± 8.7 years. There were 8 males and 7 females. The mean duration of CRVO was 5.4 ± 2.9 weeks. During the study, 4 eyes developed transient ocular hypertension, which was managed successfully with topical anti-glaucomatous drops. Elevated IOP was observed in 1 patient at 1 week after injection (32 mmHg) and in another 3 patients at 1 month follow-up (28, 26 and 26 mmHg). IOP was lowered to less than 21 mmHg within 1 week

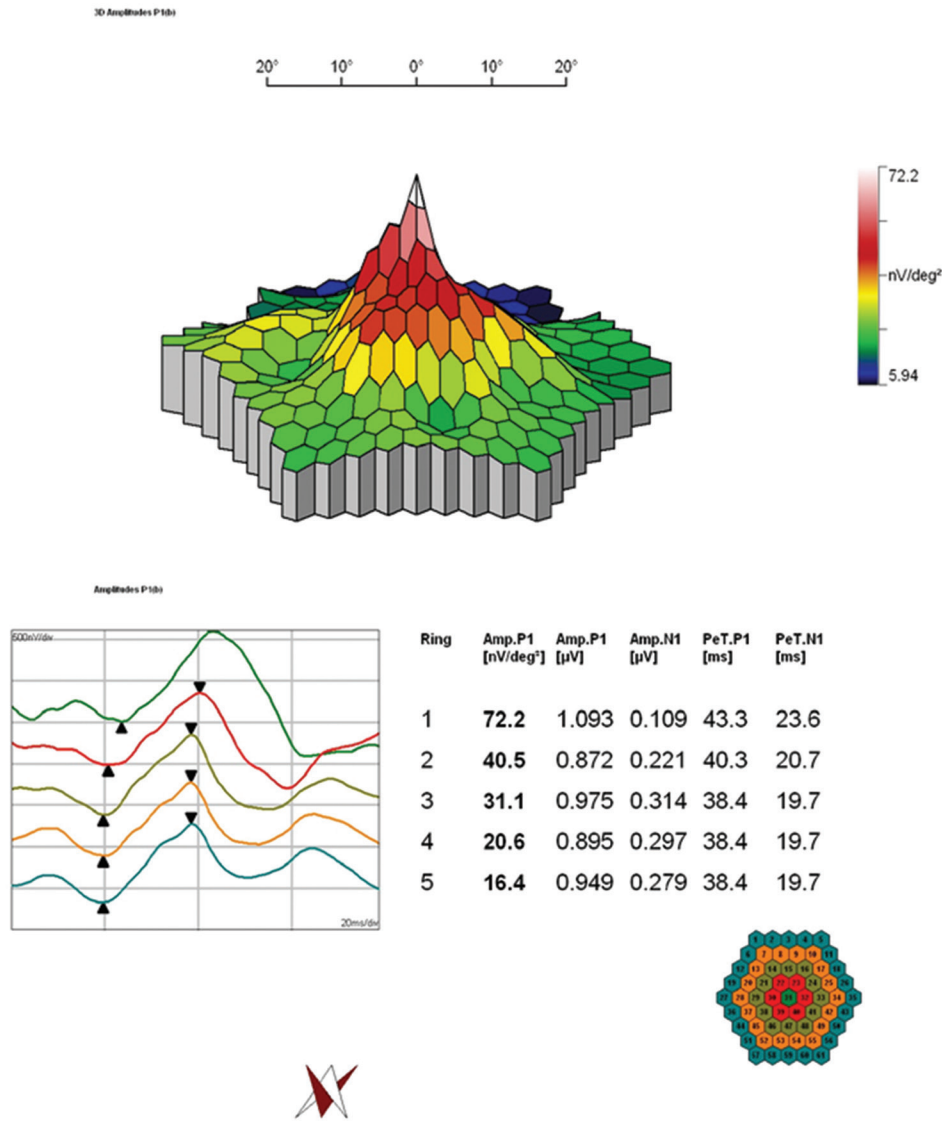


Figure 1. Ring pattern of multifocal electroretinography (mfERG).

using topical brimonidine tartrate/timolol maleate combination drops.

The mean baseline, month 3, and month 6 BCVA values were 1.5 ± 0.8 , 1.02 ± 0.51 , and 1.02 ± 0.58 logMAR, respectively. There was a statistically significant difference between repeated measures (ANOVA; $P = 0.01$). The differences between BCVA at baseline and at both 3 and 6 months were significant (Bonferroni; $P = 0.029$, $P = 0.029$, respectively), whereas the difference between month 3 and month 6 BCVA was nonsignificant (Bonferroni; $P = 0.976$).

The mean CMT was 467.2 ± 126.5 µm at baseline versus 372.4 ± 118.2 µm at month 3 and 400.2 ± 138.3 µm at month 6 follow-up visits. Repeated measures were significantly different (ANOVA; $P < 0.01$), as was the difference between CMT at baseline and 3 months (Bonferroni; $P < 0.01$). However, the differences in CMT between baseline and 6 months and between 3 and 6 months

were statistically nonsignificant (Bonferroni; $P = 0.138$ and $P = 0.189$).

No correlation was detected between baseline BCVA and CMT or mfERG P wave amplitudes or implicit times. There was a moderate correlation between BCVA at 3 months and CMT at 3 months ($P = 0.045$, $r = 0.579$), whereas BCVA at 6 months was not associated with CMT, P wave amplitudes or implicit times.

Baseline mfERG P wave amplitude values of r1, r2, r3, r4 and r5 were 57.8 ± 14.8 , 25.1 ± 10.6 , 17.2 ± 7.3 , 12.0 ± 5.0 and 7.1 ± 3.6 nV/deg², respectively. They increased to 72.9 ± 33.2 , 31.2 ± 9.3 , 22.6 ± 7.6 , 15.6 ± 7.1 and 10.9 ± 5.7 nV/deg², respectively [Table 1] at 6 months post-injection. However, these increases were not statistically significant (all $P > 0.05$) [Figure 2]. Baseline mfERG r1, r2, r3, r4 and r5 P wave implicit times were 40.1 ± 10.9 , 39.4 ± 3 , 38.4 ± 3.4 , 38.2 ± 3.1 , and 39.3 ± 2.2 ms, respectively; at month 6 follow-up these values were

measured as 38.9 ± 8.2 , 38.4 ± 4.7 , 37 ± 3.8 , 37.5 ± 4.6 , and 37.7 ± 4.7 ms [Table 2]. Although there were shortenings in P wave implicit times in all rings, they did not reach statistical significance (all $P > 0.05$) [Figure 1]. P wave amplitude and implicit time values of healthy fellow eyes are given in Table 3.

DISCUSSION

In this prospective study, our patients who received Ozurdex treatment due to central vein occlusion had non-significant improvement on mfERG findings at 6 months. We observed that CMT decreased significantly at month 3 but that this improvement faded by month 6.

Several studies have demonstrated that full-field (ff) ERG changes display functional damage in RVO. ff ERG represents the whole retinal functional condition. Chen et al reported that negative photopic response is informative regarding the functional condition of retina in BRVO.^[17] Fortune et al showed that b-wave implicit time was increased in flicker phase, which represents cone functions.^[12] Unlike ffERG, mfERG indicates the function of only the macular region.^[18,19]

Many authors agree about the abnormality of mfERG in RVO.^[20,21] Dolan et al reported that P wave amplitude was lower and implicit time was longer in CRVO.^[20] Likewise, Ikada et al showed that P implicit time was delayed in both the central region and effected quadrants in BRVO patients.^[21]

Many authors have also reported the impacts of different methods and molecules used in the treatment of RVO on mfERG. Chung et al displayed significant improvements in mfERG of BRVO patients after arteriovenous sheathotomy.^[22] Torres-Sorriano et al detected no statistically significant changes in electrophysiologic responses in mfERG 1 month after the intravitreal injection of bevacizumab. They interpreted that mfERG did not demonstrate any short-term cone photoreceptor toxicity after intravitreal bevacizumab.^[23] Park et al showed that macular functions were significantly improved according to

mfERG and OCT findings after 3 consecutive intravitreal bevacizumab injections with 6 weeks intervals.^[24] Our findings were not in accordance with these previous studies. These differences may be due to different treatment modalities and study designs. Moscos et al showed improvement in mfERG, BCVA and CMT findings after injection of intravitreal triamcinolone from 3 to 6 months; however, these improvements faded after the 6th month.^[25] Similarly, our mfERG findings showed nonsignificant changes at 6 months.

Querques et al reported that in eyes with macular edema secondary to CRVO, Ozurdex implant provided functional benefits as soon as 1 month after the treatment and mfERG measurements also showed non-significant improvement.^[26] In our study, mfERG was measured only at 6 months after the injection because we aimed to investigate the long-term effects on mfERG findings. Querques et al found a positive correlation between CMT and both mfERG N1R1 and N1R2 amplitudes at baseline, and reported that CMT was positively correlated with logMAR BCVA at 1 and 3 months. Similarly, we observed a moderate correlation between CMT and logMAR BCVA at 3 months, though only a weak association emerged between CMT, logMAR BCVA and mfERG P wave amplitude and implicit times at baseline. This difference may be attributable to the lower BCVA levels of our patients.

Limitations of this study include the small patient number and the fact that mfERG was not performed during the first 3 months of treatment, when Ozurdex was most effective. The central macula at 6 months was slightly thicker compared to 3 months and was not significantly different than baseline. mfERG at 3 months may have revealed significant changes compared to baseline. Due to the higher and optimal amplitude values using jet electrode would be better than DTL electrode. The other limitation of this study is the potential effect of iron in haemorrhage that may lead to toxicity to retina^[27] and affect electroretinography outcomes. All of the study patients had some degree of macular haemorrhage and we cannot conclude that haemorrhage has no effect on mfERG findings. In contrast, a strength

Table 1. P wave amplitude changes after Ozurdex injection in rings

	r1aP1 (nv/deg ²)	r2aP1 (nv/deg ²)	r3aP1 (nv/deg ²)	r4aP1 (nv/deg ²)	r5aP1 (nv/deg ²)
Baseline	57.8±14.8	25.1±10.6	17.2±7.3	12.0±5	7.1±3.6
6 th month	72.9±33.2	31.2±9.3	22.6±7.6	15.6±7.1	10.9±5.7
P value*	0.463	0.917	0.513	0.500	0.618

*Wilcoxon signed rank test, r (1-5): rings 1-5, aP: P wave amplitude

Table 2. P wave implicit time changes after Ozurdex injection in rings

	r1iP1 (ms)	r2iP1 (ms)	r3iP1 (ms)	r4iP1 (ms)	r5iP1 (ms)
Baseline	40.1±10.9	39.4±3	38.4±3.4	38.2±3.1	39.3±2.2
6 th month	38.9±8.2	38.4±4.7	37±3.8	37.5±4.6	37.7±4.7
P value*	0.441	0.769	0.644	0.878	0.512

*Wilcoxon signed rank test, r (1-5): rings 1-5, iP: P wave implicit time

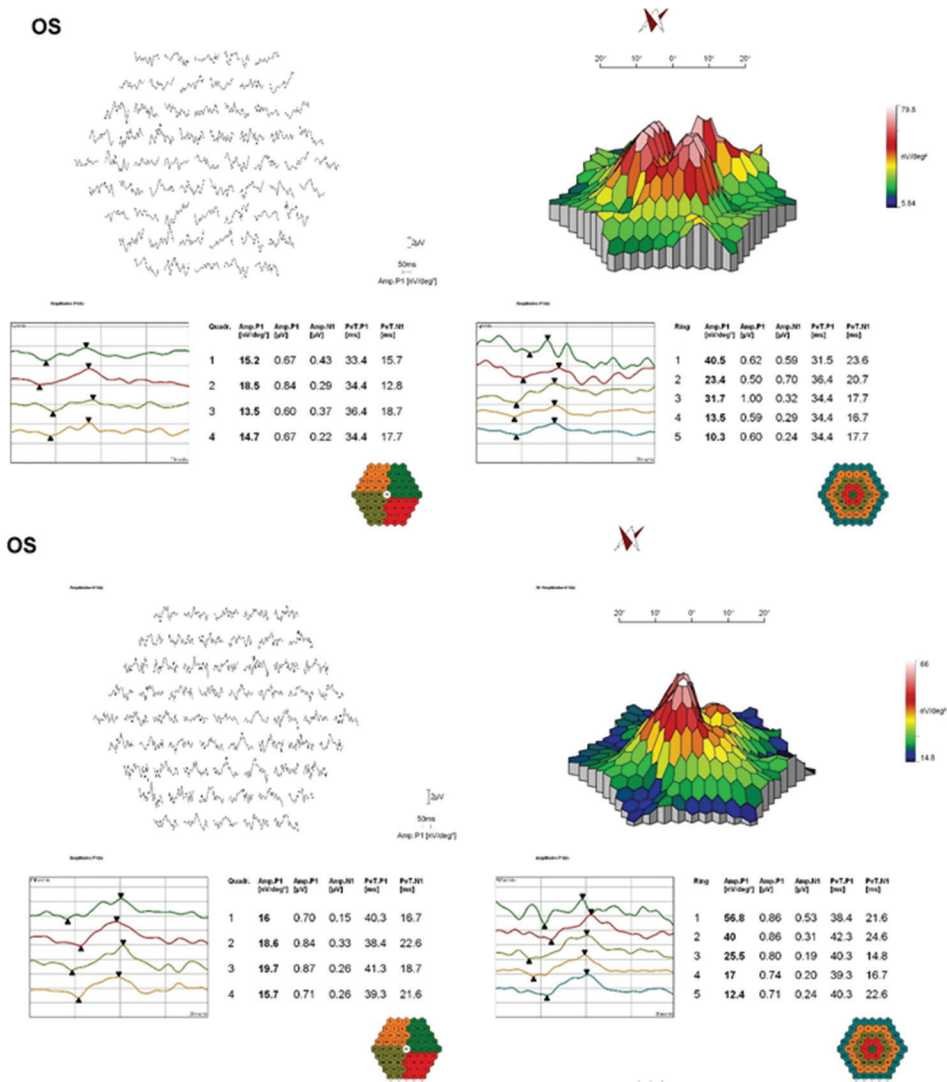


Figure 2. The multifocal electroretinography (mfERG) before and after Ozurdex treatment.

Table 3. P wave amplitude and implicit times in healthy fellow eyes

	aP (nv/deg ²)	iP (ms)
Ring 1	93.5±21.2	36.4±2.1
Ring 2	62.4±12.1	33±2.1
Ring 3	42.7±6.2	32.1±2
Ring 4	27.1±6.2	32.2±1
Ring 5	19.9±4.9	32.1±1.9

aP: P wave amplitude, iP: P wave implicit time

of our study is that, to the best of our knowledge, this is the first study to demonstrate the long-term effect of the Ozurdex implant on mfERG parameters when used to treat CRVO-related macular edema.

CONCLUSION

In conclusion, in the present study, although Ozurdex implant caused improvement in retinal function

measured by mfERG at 6 months when used for the treatment of CRVO-related macular edema, this improvement was not statistically significant. In addition, there were shortenings in implicit times in all rings; however, similarly, these changes were not statistically significant. Functional improvement of CRVO patients under Ozurdex treatment according to the mfERG findings was not significant at 6 months. It is not clear whether this was due to decreasing efficacy of the Ozurdex implant or permanent functional damage of the retina. Further longitudinal studies with repeated injections and more frequent mfERG measurements are required to understand this condition clearly and evaluate mfERG findings.

Financial Support and Sponsorship

Nil.

Conflicts of Interest

There are no conflicts of interest.

REFERENCES

- Branch Vein Occlusion Study Group. Argon laser photocoagulation for macular edema in branch vein occlusion. *Am J Ophthalmol* 1984;98:271-282.
- Mitchell P, Smith W, Chang A. Prevalence and associations of retinal vein occlusion in Australia: The blue mountains eye study. *Arch Ophthalmol* 1996;114:1243-1247.
- Klein R, Klein BE, Moss SE, Meuer SM. The epidemiology of retinal vein occlusion: The beaver dam eye study. *Trans Am Ophthalmol Soc* 2000;98:133-143.
- Brynskov T, Kemp H, Sørensen TL. Intravitreal ranibizumab for retinal vein occlusion through 1 year in clinical practice. *Retina* 2014;34:1637-1643.
- Rehak M, Wiedemann P. Retinal vein thrombosis: Pathogenesis and management. *J Thromb Haemost* 2010;8:1886-1894.
- Central Vein Occlusion Study Group. Natural history and clinical management of central retinal vein occlusion. *Arch Ophthalmol* 1997;115:486.
- Farinha C, Marques JP, Almeida E, Baltar A, Santos AR, Melo P, et al. Treatment of Retinal Vein Occlusion with Ranibizumab in Clinical Practice: Longer-Term Results and Predictive Factors of Functional Outcome. *Ophthalmic Res* 2015;55:10-18.
- Ip MS, Scott IU, VanVeldhuisen PC, Oden NL, Blodi BA, Fisher M, et al. A randomized trial comparing the efficacy and safety of intravitreal triamcinolone with observation to treat vision loss associated with macular edema secondary to central retinal vein occlusion: The Standard Care vs Corticosteroid for Retinal Vein Occlusion (SCORE) study report 5. *Arch Ophthalmol* 2009;127:1101-1114.
- Dugel PU, Capone A Jr, Singer MA, Dreyer RF, Dodwell DG, Roth DB, et al. SHASTA Study Group. Two or more dexamethasone intravitreal implants in treatment-naïve patients with macular edema due to retinal vein occlusion: Subgroup analysis of a retrospective chart review study. *BMC Ophthalmol* 2015;15:118.
- de Smet MD. Corticosteroid intravitreal implants. *Dev Ophthalmol* 2012;51:122-133.
- Haller JA, Bandello F, Belfort R Jr, Blumenkranz MS, Gillies M, Heier J, et al. for the OzurdexGENEVA Study Group. Dexamethasone intravitreal implant in patients with macular edema related to branch or central retinal vein occlusion twelve-month study results. *Ophthalmology* 2011;118:2453.
- Fortune B, Schneck ME, Adams AJ. Multifocal electroretinogram delays reveal local retinal dysfunction in early diabetic retinopathy. *Invest Ophthalmol Vis Sci* 1999;40:2638-2651.
- Sutter EE, Tran D. The field topography of ERG components in man-I. The photopic luminance response. *Vision Res* 1992;32:433-446.
- Hood DC, Frishman LJ, Saszik S. Retinal origins of the primate multifocal ERG: Implications for the human response. *Invest Ophthalmol Vis Sci* 2002;43:1673-1685.
- Abdel-Kader M, El-Dessouky WM. Multifocal electroretinogram in retinal vein occlusion. *Saudi J Ophthalmol* 2010;24:125-132.
- Hood DC, Bach M, Brigell M, Keating D, Kondo M, Lyons JS, et al. International Society For Clinical Electrophysiology of Vision. ISCEV standard for clinical multifocal electroretinography (mfERG) (2011 edition). *Doc Ophthalmol* 2012;124:1-13.
- Chen H, Wu D, Huang S, Yan H. The photopic negative response of the flash electroretinogram in retinal vein occlusion. *Doc Ophthalmol* 2006;113:53.
- Hirose T, Miyake Y, Hara A. Simultaneous recording of electroretinogram and visual evoked response: Focal stimulation under direct observation. *Arch Ophthalmol* 1977;95:1205-1208.
- Miyake Y, Ichikawa K, Shiose Y, Kawase Y. Hereditary macular dystrophy without visible fundus abnormality. *Am J Ophthalmol* 1989;108:292-299.
- Dolan FM, Parks S, Keating D, Dutton GN, Evans AL. Multifocal electroretinographic features of central retinal vein occlusion. *Invest Ophthalmol Vis Sci* 2003;44:4954-4959.
- Ikeda J, Hasegawa S, Suzuki K, Ichibe M, Tanimoto N, Usui T, et al. Multifocal electroretinograms in patients with retinal vein occlusion. *Nippon Ganka Gakkai Zasshi* 2004;108:84-91.
- Chung EJ, Freeman WR, Koh HJ. Visual acuity and multifocal electroretinographic changes after arteriovenous crossing sheathotomy for macular edema associated with branch retinal vein occlusion. *Retina* 2008;28:220-225.
- Torres-Soriano ME, Cubas-Lorenzo V, García-Aguirre G, Hernández-Rojas M, Kon-Jara V, Díaz-Rubio J, et al. Multifocal electrophysiologic findings after intravitreal bevacizumab (avastin) treatment. *Retina* 2012;32:972-976.
- Park S, Cho IH, Park TK, Nam WH, Ohn YH. Extrafoveal changes following intravitreal bevacizumab injections for macular edema secondary to branch retinal vein occlusion: An mfERG and OCT study. *Doc Ophthalmol* 2013;126:137-148.
- Moschos MM, Brouzas D, Loukianou E, Apostolopoulos M, Moschos M. Intraocular triamcinolone acetate for macular edema due to CRVO. A multifocal-ERG and OCT study. *Doc Ophthalmol* 2007;114:1-7.
- Querques G, Lattanzio R, Querques L, Triolo G, Cascavilla ML, Cavallero E, et al. Impact of intravitreal dexamethasone implant (Ozurdex) on macular morphology and function. *Retina* 2014;34:330-341.
- Gnana-Prakasam JP, Martin PM, Smith SB, Ganapathy V. Expression and function of iron-regulatory proteins in retina. *IUBMB Life* 2010;62:363-370.